

University of Wollongong  
**Research Online**

---

Graduate School of Medicine - Papers (Archive)

Faculty of Science, Medicine and Health

---

1-1-2009

## Dapsone hypersensitivity syndrome causing disseminated intravascular coagulation

Melanie Figtree  
*St. George Hospital*

Spiros Miyakis  
*Aristotle University of Thessaloniki, smiyakis@uow.edu.au*

Kumiko Tanaka  
*St. George Hospital*

Linda Martin  
*St. George Hospital*

Pamela Konecny  
*St. George Hospital*

*See next page for additional authors*

Follow this and additional works at: <https://ro.uow.edu.au/medpapers>

 Part of the [Medicine and Health Sciences Commons](#)

---

### Citation

Figtree, Melanie; Miyakis, Spiros; Tanaka, Kumiko; Martin, Linda; Konecny, Pamela; and Krilis, Steven, 2009, Dapsone hypersensitivity syndrome causing disseminated intravascular coagulation, 1-5.  
<https://ro.uow.edu.au/medpapers/553>

Research Online is the open access institutional repository for the University of Wollongong. For further information contact the UOW Library: [research-pubs@uow.edu.au](mailto:research-pubs@uow.edu.au)

---

## Dapsone hypersensitivity syndrome causing disseminated intravascular coagulation

### Abstract

Dapsone hypersensitivity syndrome is an idiosyncratic reaction to this drug and can present with different clinical manifestations of varying severity. We describe a patient with disseminated intravascular coagulation (DIC) as an adverse reaction to dapsone. To the best of our knowledge, this is the first time it has been described in the literature. She presented with fever, rash and abdominal pain; she also had marked eosinophilia and features suggestive of oxidative haemolysis. Her course was complicated by DIC, splenic infarction and gastrointestinal bleeding. Extensive investigations did not reveal any alternative aetiology. She was initially treated with supportive measures and folic acid; steroids were administered later, following clinical deterioration. There was gradual improvement and the steroids were tapered. The patient recovered fully and remains well; her underlying chronic dermatologic condition is under satisfactory control with other medications.

### Disciplines

Medicine and Health Sciences

### Publication Details

Figtree, M. Clare., Miyakis, S., Tanaka, K., Martin, L., Konecny, P. & Krilis, S. (2009). Dapsone hypersensitivity syndrome causing disseminated intravascular coagulation. *BMJ Case Reports*, 2009 1257, 1-4.

### Authors

Melanie Figtree, Spiros Miyakis, Kumiko Tanaka, Linda Martin, Pamela Konecny, and Steven Krilis

Published 10 August 2009

Cite this as: *BMJ Case Reports* 2009 [doi:10.1136/bcr.11.2008.1257]

Copyright © 2009 by the BMJ Publishing Group Ltd.

## Unexpected outcome (positive or negative) including adverse drug reactions

### Dapsone hypersensitivity syndrome causing disseminated intravascular coagulation

Melanie Clare Figtree<sup>1</sup>, Spiros Miyakis<sup>2</sup>, Kumiko Tanaka<sup>1</sup>, Linda Martin<sup>1</sup>, Pam Konecny<sup>1</sup>, Steven Krilis<sup>1</sup>

<sup>1</sup> St George Hospital, Immunology, Allergy and Infectious Disease, Kogarah, Sydney, New South Wales, 2217, Australia

<sup>2</sup> Papageorgiou Hospital, Medicine, Aristotle University of Thessaloniki, Thessaloniki, TK 54267, Greece

Correspondence to:

Melanie Clare Figtree, [melfigtree@yahoo.com.au](mailto:melfigtree@yahoo.com.au)

## SUMMARY

Dapsone hypersensitivity syndrome is an idiosyncratic reaction to this drug and can present with different clinical manifestations of varying severity. We describe a patient with disseminated intravascular coagulation (DIC) as an adverse reaction to dapsone. To the best of our knowledge, this is the first time it has been described in the literature. She presented with fever, rash and abdominal pain; she also had marked eosinophilia and features suggestive of oxidative haemolysis. Her course was complicated by DIC, splenic infarction and gastrointestinal bleeding. Extensive investigations did not reveal any alternative aetiology. She was initially treated with supportive measures and folic acid; steroids were administered later, following clinical deterioration. There was gradual improvement and the steroids were tapered. The patient recovered fully and remains well; her underlying chronic dermatologic condition is under satisfactory control with other medications.

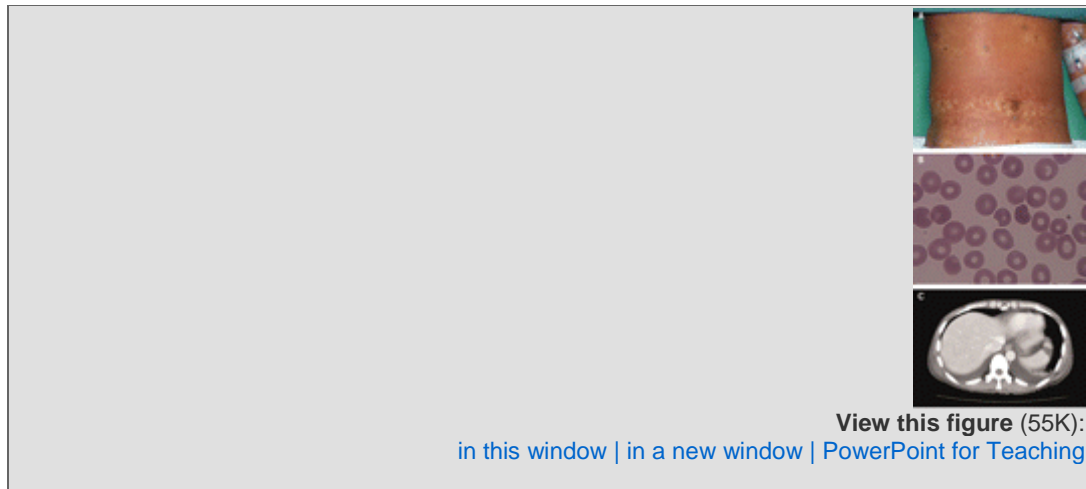
---

## BACKGROUND

This case illustrates the challenges a clinician may face with life threatening adverse reactions from a medication used commonly in various parts of the world, for a variety of indications by doctors of several specialties, as well as general physicians and family practitioners.

## CASE PRESENTATION

A 44-year-old Chinese woman presented with a 6 day history of fatigue, fever, pruritic rash, nausea and abdominal pain. Three weeks earlier she was prescribed dapsone 100 mg daily for dermatitis herpetiformis, which she stopped taking 2 days before admission. Her personal medical and family history was unremarkable. Examination revealed temperature 40°C, blood pressure 90/50 mm Hg, bilateral pleural effusions, scleral icterus, tender upper quadrants bilaterally and inguinal lymphadenopathy. There was a diffuse non-blanching maculopapular exanthem over the abdomen, arms and legs with sparing of the mucosal areas ([fig 1A](#)).



**Figure 1** (A) Exanthem of dapsone hypersensitivity reaction on abdomen. (B) Peripheral blood film showing oxidative haemolysis. (C) Computed tomographic scan of the abdomen showing splenic infarction, bilateral pleural effusions and body wall oedema.

## INVESTIGATIONS

Laboratory testing showed oxidative haemolysis ([fig 1B](#)) (bilirubin 105  $\mu\text{mol/l}$ , lactate dehydrogenase (LDH) 506 IU/l, reticulocytes  $269.2 \times 10^9/l$ ); neutropenia  $0.5 \times 10^9/l$ ; eosinophilia  $1.97 \times 10^9/l$  (normal range  $0.04\text{--}0.44 \times 10^9/l$ ); and elevated alanine aminotransferase (ALT) 432 U/l (normal  $<45$  U/l) and aspartate transaminase (AST) 129 U/l (normal  $<45$  U/l). Skin biopsy showed moderate interface dermatitis with negative IgA/G immunofluorescence. The patient had disseminated intravascular coagulation (DIC) with concurrent splenic infarction ([fig 1C](#)), gastrointestinal bleeding and abdominal wall haemorrhage; international normalised ratio (INR) was 1.6, fibrinogen 1.0 g/l, D-dimers  $>20$   $\mu\text{g/ml}$ , and platelets  $112 \times 10^9/l$ . Glucose-6-phosphate dehydrogenase (G6PD) value was normal.

## DIFFERENTIAL DIAGNOSIS

Thrombotic, septic, vasculitic, and porphyria screen were negative.

## TREATMENT

The patient was managed initially with supportive measures and folic acid. Blood products were not required. Intravenous steroids were introduced on day 5 in response to rising eosinophilia and worsening symptoms. There was marked improvement in temperature and exanthem within 48 hours. The eosinophil count fell to  $0.24 \times 10^9/l$ .

## OUTCOME AND FOLLOW-UP

Oral steroids were tapered over 4 weeks with resolution of exanthem and normalisation of transaminases. Rechallenge was not attempted, in view of the life threatening initial reaction. The patient recovered fully and remains well 1 year after her hospitalisation; her underlying chronic dermatologic condition is under satisfactory control with other medications. Patient consent was

obtained for publication of clinical information and additional peripheral blood mononuclear cell (PBMC) in vitro tests.

The effect of dapsone on PBMC proliferation was assessed in vitro with PBMC from the patient and a healthy volunteer of same age, sex and ethnic origin. PBMC were Ficoll-isolated and  $3 \times 10^5$  PBMC (in triplicate) were incubated for 48 h in 100  $\mu$ l of RPMI-1640 (negative controls) and in the presence of LPS (30  $\mu$ g/ml) (positive control) and dapsone at concentrations of 0.02  $\mu$ M, 0.2  $\mu$ M, 2  $\mu$ M (typical trough value in human serum), 20  $\mu$ M and 200  $\mu$ M. Proliferation was measured using the methyl thiazolyl tetrazolium (MTT) method at 570 nm. Increased proliferation was observed in LPS treated PBMC from both patient (35%) and healthy volunteer (44%) compared to PBMC in media only (negative controls), whereas dapsone at concentrations 0.02–20  $\mu$ M had no significant effect. Dapsone at a concentration of 200  $\mu$ M had a notable inhibitory effect on cell proliferation in PBMC of both patient (–75%) and control (–66%).

## DISCUSSION

Dapsone (4-4'-diaminodiphenylsulphone), a synthetic sulfone, is a potent antimicrobial and anti-inflammatory drug. Dapsone is used in first line multi-drug treatment of leprosy, for actinomycotic mycetoma, and as an alternative agent for prophylaxis against pneumocystosis, toxoplasmosis and malaria. Dapsone is an efficacious anti-inflammatory agent in various dermatological conditions (dermatitis herpetiformis, acne vulgaris, urticarial vasculitis, and immunobullous diseases).

Dapsone has well recognised idiosyncratic and predictable adverse effects.<sup>1,2</sup> The dapsone hypersensitivity syndrome (DHS) is a severe form of DRESS syndrome (drug rash with eosinophilia and systemic symptoms). Originally described as a triad of fever, skin eruption and internal organ involvement, DRESS syndrome has expanded to include painful lymphadenopathy, eosinophilic pulmonary infiltrates and myocarditis. Methaemoglobinaemia and peripheral neuropathy have also been described.<sup>1</sup> DHS incidence is estimated to be 0.01–3%.<sup>3</sup> This idiosyncratic reaction is possibly triggered by antibody formation to haptens from dapsone metabolites,<sup>4</sup> usually within 8 weeks from starting the drug.<sup>2</sup> Failure of physiological dapsone concentrations to activate in vitro PBMC proliferation from this patient further supports the hypothesis for involvement of dapsone metabolites in DHS. However, the possibility of qualitative PBMC alterations in response to dapsone or its metabolites would also be of interest.

DIC has not been previously reported in association with dapsone, despite over 150 cases of DHS described in the literature. DIC in this patient may be a consequence of the hypersensitivity reaction triggering a severe systemic inflammatory response syndrome (SIRS). Severe inflammation induces damaged endothelial and mononuclear cells to express tissue factor which triggers fibrin formation and subsequent DIC. In intensive care units, 2% of DIC cases are attributed to inflammatory reactions to toxins, recreational drugs, poisons, transfusion reaction or transplant rejection.<sup>5</sup> The presence of DIC in SIRS has important prognostic implications as coagulation abnormalities perpetuate the inflammatory response.

The mortality among patients with severe DHS is 12–23%.<sup>3</sup> The management of DHS is largely supportive (fluid and electrolyte balance, haematological, fastidious skin care and prevention of secondary infection). Steroid use remains controversial, despite case reports of benefit. Slow steroid tapering is recommended as dapsons may persist for up to 35 days as a result of protein binding and enterohepatic circulation.<sup>1</sup> Thyroid function should be assessed at 3 months, since hypothyroidism due to antimicrosomal antibodies is a late complication.

It is imperative to reduce the likelihood of DHS, by careful assessment of risk factors predisposing the patient to this adverse event. Patients at increased risk include those with: sulphone allergy, haemolytic anaemia, G6PD deficiency, porphyria, personal or family history of cyanosis, use of concurrent medications metabolised by CYP3A4 and CYP2C9, rapid hydroxylators, and slow acetylators.<sup>4</sup> Awareness of the severe, idiosyncratic nature of dapsons reactions warrants careful monitoring of all patients commencing dapsons therapy for early recognition of symptoms and signs suggesting this complication.

## LEARNING POINTS

- Therapeutic use of dapsons can be complicated by life threatening idiosyncratic adverse reactions, including disseminated intravascular coagulation.
- Careful consideration needs to be given to whether the patient's condition warrants dapsons and whether the patient is at increased risk of an adverse event.
- All patients commencing dapsons should be monitored closely, for early recognition of symptoms and signs suggesting an adverse drug reaction.
- The management of adverse effects from dapsons is supportive, involving management of shock, fluid and electrolyte balance, pancytopenia, fastidious skin care and prevention of secondary infection. Steroids may be used in severe cases not responding to supportive management.

Department of Radiology, St George Hospital, Kogarah Sydney, Australia.

**Competing interests:** none.

**Patient consent:** Patient/guardian consent was obtained for publication

## REFERENCES

1. Kosseifi, SG, Guha, B, Nassour, DN, et al. The Dapsone hypersensitivity syndrome revisited: a potentially fatal multisystem disorder with prominent hepatopulmonary manifestations. *J Occup Med Toxicol* 2006;1:9.[\[CrossRef\]](#)[\[Medline\]](#)

2. Richardus, JH, & Smith, TC. Increased incidence in leprosy of hypersensitivity reactions to dapsone after introduction of multidrug therapy. *Lepr Rev* 1989;60:267–73.[\[Medline\]](#)
3. Pandey, B, Shrestha, K, Lewis, J, et al. Mortality due to dapsone hypersensitivity syndrome complicating multi-drug therapy for leprosy in Nepal. *Trop Doct* 2007;37:162–  
3.[\[Abstract/Free Full Text\]](#)
4. Bluhm, RE, Adedoyin, A, McCarver, DG, et al. Development of dapsone toxicity in patients with inflammatory dermatosis: activity of acetylation and hydroxylation of dapsone as risk factors. *Clin Pharmacol Ther* 1999;65:598–605.[\[CrossRef\]](#)[\[Medline\]](#)
5. Gando, S, Iba, T, Eguchi, Y, et al. A multicentre, prospective validation of disseminated intravascular coagulation diagnostic criteria for critically ill patients: comparing current criteria. *Crit Care Med* 2006;34:625–31.[\[Medline\]](#)