



Chiebao, D. P., Bartley, P. M., Chianini, F., Black, L. E., Burrells, A., Pena, H. F.J., Soares, R. M., Innes, E. A. and Katzer, F. (2021) Early immune responses and parasite tissue distribution in mice experimentally infected with oocysts of either archetypal or non-archetypal genotypes of *Toxoplasma gondii*. *Parasitology*, 148(4), pp. 464-476.

There may be differences between this version and the published version. You are advised to consult the publisher's version if you wish to cite from it.

<http://eprints.gla.ac.uk/227471/>

Deposited on 07 January 2021

Enlighten – Research publications by members of the University of Glasgow
<http://eprints.gla.ac.uk>

Early immune responses and parasite tissue distribution in mice experimentally infected with oocysts of either archetypal or non-archetypal genotypes of *Toxoplasma gondii*

Daniela P. Chiebao^{1,*}; Paul M. Bartley²; Francesca Chianini²; Lauren E. Black²; Alison Burrells²; Hilda F. J. Pena¹; Rodrigo M. Soares¹; Elisabeth A. Innes² and Frank Katzer²

¹Department of Preventive Veterinary Medicine, Faculty of Veterinary Medicine and Animal Science – FMVZ, University of Sao Paulo, 87 Professor Doutor Orlando Marques de Paiva Avenue, 05508-270 São Paulo, Brazil. hfpena@usp.br, rosoares@usp.br and ²Moredun Research Institute, Pentland Science Park, Bush Loan, Edinburgh EH26 0PZ, Scotland, United Kingdom. paul.bartley@moredun.ac.uk, francesca.chianini@moredun.ac.uk, 2079853B@student.gla.ac.uk, alison.burrells@sky.com, lee.innes@moredun.ac.uk, frank.katzer@moredun.ac.uk

***Author for correspondence:** Daniela P Chiebao, E-mail: daniela.chiebao@sp.gov.br

Abstract

In most of the world *Toxoplasma gondii* is comprised of archetypal types (Types I, II and III) however, South America displays several non-archetypal strains. This study used an experimental mouse model to characterize the immune response and parasite kinetics following infection with different parasite genotypes. An oral inoculation of 50 oocysts per mouse from *T. gondii* M4 Type II (archetypal, avirulent), BrI or BrIII (non-archetypal, virulent and intermediate virulent, respectively) for Group (G)2, G3 and G4, respectively was used. Levels of mRNA expression of cytokines, immune compounds, cell surface markers and receptor adapters (IFN γ , IL-12, CD8, CD4, CD25, CXCR3 and MyD88) were quantified by SYBR green RT-qPCR. Lesions were characterized by histology and detection by immunohistochemistry established distribution of parasites. Infection in G2 mice was mild and characterized by an early MyD88-dependent pathway. In G3 there were high levels of expression of pro inflammatory cytokines IFN γ and IL-12 in the mice showing severe clinical symptoms at 8-11 days post infection (dpi), combined with the upregulation of CD25, abundant tachyzoites and tissue lesions in livers, lungs and intestines. Significant longer expression of IFN γ and IL-12 genes, with other Th1 balanced immune responses, like increased levels of CXCR3 and MyD88 in G4, resulted in survival of mice and chronic toxoplasmosis, with occurrence of tissue cysts in brain and lungs, at 14 and 21 dpi. Different immune responses and kinetics of gene expression appear to be elicited by the different strains and non-archetypal parasites demonstrated higher virulence.

Key words: Toxoplasmosis, Virulence, Cytokines, T cells, MyD88, Non-archetypal strains

Introduction

Toxoplasmosis is a zoonotic disease occurring worldwide with a very high prevalence of infection in warm-blooded animals (Dubey, 2010) and is considered a parasitic cause of congenital disease in humans, whilst in livestock the parasite is a major cause of ovine abortion (Watson and Beverley, 1971; Dubey and Beattie, 1988; Hide *et al.*, 2009; Tzanidakis *et al.*, 2012). Genetic studies have shown that *Toxoplasma gondii* comprises mostly three archetypal (clonal) genotypes, Types I, II and III (Howe and Sibley, 1995), although South America and Asia are dominated by genetically distinct non-archetypal strains (Pena *et al.*, 2008; Shwab *et al.*, 2014). Type II genotypes of *T. gondii* are largely found in humans with congenital toxoplasmosis in Europe (Ajzenberg *et al.*, 2002) whereas the non-archetypal types BrI, BrII and BrIII represent the most predominant genotypes found within animal reservoirs in Brazil (Pena *et al.*, 2006; Dubey *et al.*, 2012). Previous research has highlighted that non-archetypal genotypes of *Toxoplasma* may be related to a severe syndrome associated with pulmonary infection including in immunocompetent patients (Elbez-Rubinstein *et al.*, 2009). In mice, archetypal Type I genotypes are considered virulent and lethal, whereas genotypes II and III usually present with intermediate and low virulence (Sibley *et al.*, 1999). Most of the non-archetypal isolates experimentally studied in mice are virulent, causing high levels of morbidity (Pena *et al.*, 2008). Virulence of four Brazilian isolates of *T. gondii*, two BrI and two BrIII genotypes, were studied in mice infected with oocysts. The BrI isolates caused large levels of mortality indicating high virulence. Whereas for the BrIII isolates low to medium levels of dose-dependent mortality was observed, characterizing the virulence as intermediate (Chiebao *et al.*, 2016).

From previous studies in mice it is known that a primary infection with *T. gondii* stimulates the innate immune system, in particular the Toll-like receptors (TLRs), associated with adaptor proteins like myeloid differentiation primary response protein 88 (MyD88),

(Kawai and Akira, 2005) to produce IL-12 and IFN γ . These cytokines will help to elicit an adaptive Th1 type immune response mediated by the proliferation of the CD4⁺ and CD8⁺ T-cells (Innes and Vermeulen, 2006; Miller *et al.*, 2009). However, an uncontrolled inflammatory response can lead to immune mediated pathology, so the host must balance the immune response to minimize tissue damage (Shaw *et al.*, 2006), by the activation of a complex set of immune response components, among them the regulatory T cells (Tregs).

The aim of this study was to characterize inflammatory markers and their association with virulence in mice infected with different isolates of *T. gondii*: either M4 (type II variant, archetypal), BrI or BrIII (non-archetypal) oocysts. The study sheds light on the pathology inflicted by these different genotypes and the role they play in clinical manifestations and parasite kinetics during toxoplasmosis. Novel results are presented addressing the effects of different field isolates of *T. gondii* on the immune response of mice and it correlates this difference with virulence.

Materials and methods

Toxoplasma gondii oocysts

Sporulated oocysts of *T. gondii* South American non-archetypal genotypes BrI (ToxoDB RFLP#6, isolate TgCatBr71) and BrIII (ToxoDB RFLP#8, isolate TgCatBr60) were obtained from the faeces of cats fed brains containing tissue cysts from experimentally infected mice of a previous study (Chiebao *et al.*, 2019), as previously described (Dubey, 2010). The BrI and BrIII strains were originally obtained from naturally infected cats (Pena *et al.*, 2006) and the sporulated oocysts were characterized (Chiebao *et al.*, 2016). The sporulated oocysts of the archetypal M4 strain (type II variant – ToxoDB RFLP#3) were obtained as previously described (Benavides *et al.*, 2011). The concentration of oocysts in suspension was determined using a Neubauer counting chamber and the inoculum was prepared one hour

before use.

Animals and experimental design

One hundred and ten 8 weeks-old female Swiss Webster mice were randomly divided into four groups, one control group (group G1, n = 5) and three inoculated groups (groups G2, G3 and G4, n = 35 each) with five mice per cage being provided with food and water *ad libitum*. Animals were kept at a containment level 2 facility.

All mice from G2, G3 and G4 were orally infected with ~50 *T. gondii* oocysts in 100µl of PBS of either the M4, BrI or BrIII strain, respectively. Animals were monitored twice a day for signs of clinical disease (Table 1). As part of a serial analysis, five animals from groups G2, G3 and G4 were euthanized at 24, 48, 72, 96 hours (h), 7, 14- and 21-days post infection (dpi) by CO₂ inhalation followed by cervical dislocation. The five mice from the control group (G1) were euthanized at the end of the experiment, at 21 dpi. Mice were scored twice daily for coat condition (A) and demeanor (B) and any mouse that reached a morbidity predetermined humane endpoint ($A + B \geq 3$) was euthanized (Table 1).

At post mortem examination samples of spleen and mesenteric lymph nodes (MLN) were collected for RNA analysis; additionally, samples of small intestine (SI), heart, both ocular globes (OG) and brain (cut along central line: ½ for DNA extraction and ½ for pathology) were collected for DNA analysis. Brain, kidneys, lungs, liver, diaphragm and the remaining gastrointestinal tract (stomach, SI and large intestine) were fixed in 10% buffered formalin and paraffin-wax embedded for histological and immunohistochemical studies. Samples for mRNA isolation were immediately placed in a CK28 Precellys tissue homogenization tube (Stretton Scientific, Stretton, UK) containing 1mL of Trizol reagent (Applied Biosystems, Foster City, USA). Samples for DNA extraction were placed into sterile 1.5mL microcentrifuge tubes. All samples for RNA and DNA extraction were stored at

-80°C prior to analysis.

RNA isolation and cDNA synthesis

The spleen and MLN samples were disrupted using a Precellys 24 tissue homogenizer (Stretton Scientific, Stretton, UK) at 5000rpm for 60s. Thereafter, RNA isolation was carried out according to manufacturer instructions for Direct-zol® RNA MiniPrep Kit (Zymo Research Corporation, Irvine, USA). The concentration of the RNA was measured using the Nanodrop ND1000 spectrophotometer (ThermoFisher Scientific, Winsford, UK), cDNA was synthesised from 2µg of total RNA using the advised protocol (MultiScribe® Life Technologies, Waltham, USA) as previously described (Bartley *et al.*, 2013a).

Quantitative real-time RT-PCR

Primers were designed to evaluate mRNA expression of interferon gamma (IFN γ), interleukin 12 (IL-12), T-cells surface markers CD8, CD4 and CD25 as well as receptor adaptors MyD88 and CXCR3 were studied (Table 2). Primers for the control gene Hypoxanthine phosphoribosyltransferase (HPRT) were also generated. Amplification of HPRT from cDNA was used as control for RNA integrity and cDNA synthesis. The amplifications of all analytes were normalized using HPRT. Each cDNA (20ng/reaction) sample was analyzed by RT-PCR in triplicate using standard amplification conditions (Bartley *et al.*, 2013b) using a Real-Time PCR instrument (ABI 7500, Applied Biosystems, Foster City, USA). Each 20µL reaction contained 10µL of 2x fast SYBR green master mix (Applied Biosystems, Foster City, USA), 1µL each forward and reverse primer (10mM), 4µL distilled water (dH₂O) and 4µL (20ng) cDNA with the resultant data being analyzed using the SDS software.

To determine changes in the levels of transcription, we compared the $\Delta\Delta C_t$ values

created after normalization of data of the ΔCt of each analyte against the ΔCt value of the HPRT, as a control reference (Bartley *et al*, 2019). Markers with higher levels of gene expression result in lower Ct values. In some cases, results are displayed as negative values, as the levels of transcription for their genes were greater than the levels of HPRT. Spleen samples from G2 at 48h showed low levels of cDNA, probably due to technical problems during sample homogenization and were therefore not included.

Standard curves were generated using known concentrations of each immunological component to analyze the data using the SDS system software and statistically analyzed by One Way ANOVA using Statistical Package for the Social Sciences (SPSS) software, version 16 (SPSS Inc., SPSS for Windows, Chicago, USA).

DNA extraction

DNA was extracted from approximately 1g of homogenized brain tissue as described previously (Bartley *et al.*, 2013b). Briefly, thawed tissue was processed using the Wizard® genomic DNA purification protocol (Promega Corporation, Madison, USA) and the final DNA pellet was resuspended in 200 μ L of RNase/DNase free water. For all of the other tissues, samples were finely chopped using sterile scalpel blades and 0.5g transferred into 2.0mL microtubes containing 0.8mL lysis buffer (50% KCl 1M, 20% Tris-HCL 500mM, 10% Gelatin A.R., 0.5% NP40 100% and 0.5% Tween 20, pH 8,3) and incubated overnight at 55°C with 20mg/mL proteinase K (Thermo Fisher Scientific, Waltham, USA). After this incubation, the proteinase K was inactivated (98°C for 10 minutes) and the samples were centrifuged, the resultant supernatant was then removed and processed through to DNA (as above). The final DNA suspensions in 200 μ L RNase/DNase free water were stored at -20°C prior to PCR analysis. Samples of water were processed along with each batch of samples; these were used not only as additional negative controls but also acted as extraction controls

to ensure no contamination occurred during the extraction process.

Diagnostic ITS-1 nested-PCR and host actin inhibition control PCR

The nested ITS1 PCR targets the multicopy 18S-5.8S rRNA internal transcribed spacer (ITS1) region of the *Toxoplasma* parasite. Primers and methodology were previously described by Burrells *et al.*, (2013). To improve the sensitivity of the assay, each DNA sample was analyzed in triplicate. A sample was considered positive if at least 1/3 replicates returned a positive result.

First round reactions were conducted as described: standard 20 μ L PCR reactions contained 2 μ L 10x PCR master mix (45mM Tris-HCl, 11mM (NH₄)₂SO₄, 4.5mM MgCl₂, 0.113mg/mL BSA, 4.4 μ M EDTA and 1.0mM dATP, dATC, dGTP, dTTP), 0.75 units BioTaq (Bioline, London, UK), using 3.75 μ M of primers NN1-ext-F and NN1-ext-R (Buxton *et al.*, 2001), listed in Table 2 and 2 μ L DNA. Positive control DNA was included with all batches of samples and consisted of *T. gondii* DNA derived from tachyzoites grown in tissue culture, negative controls were also included these consisted of sterile DNase/RNase free water and DNA extraction controls. All reactions were made to a final volume of 20 μ L with sterile DNase/RNase free water. Reaction conditions were 5 min at 95°C, followed by 35 cycles of 1 min at 95°C, 1 min at 55°C, 1 min at 72°C and a final extension period of 5 min at 72°C. The reaction conditions for the second-round amplification were identical to the first, with the following exceptions, the first round amplicon was diluted with 100 μ L of DNase/RNase free water and 2 μ L of this diluted amplicon was used as the template and 3.75 μ M of primers Toxo_NP-1_F and Toxo_NP-2_R (Hurtado *et al.*, 2001), were used. All second round PCR products were visualized under UV light following electrophoresis in 2% agarose gels incorporating Biotum Gel Red™ (1:10000 dilution) (Cambridge Bioscience Ltd, Cambridge, UK).

To ensure the integrity of the DNA in each sample and to ensure that any negative result was not due to PCR inhibition, a PCR reaction which amplified host actin was carried out using the diluted ITS1 first round products. The actin PCR used the same standard master mix as previously described above for the ITS1 PCR, but with the following differences: 2 μ L of diluted first round ITS1 PCR product was used as template and 4 μ M of the primers Uni_Actin_F3 and Uni_Actin_R3 were used per reaction (Table 2). Cycling conditions were as previously described for the nested ITS1 PCR. All PCR products were visualized following electrophoresis in 2% agarose gels incorporating Gel Red™.

To determine any statistical differences in the incidence of DNA detection in the different groups a chi-square test was performed (for each day and organ separately) (Massad, 2004; Minitab, 2019). The significance level of $\alpha = 0.05$ was adopted. In the case of the pairwise comparisons between proportions (posthoc test assuming an equal proportion of positive results in each group), the Bonferroni correction significance level $\alpha_{\text{bonf}} = 0.016$ (Hochberg, 1988) was applied. All statistical analyses were performed in R-Studio software, Version 1.2.1335.

Histopathology and immunohistochemistry (IHC)

Formalin fixed paraffin embedded samples as described in the Animals and Experimental Design section were processed as reported in Hamilton *et al.*, (2019). Briefly, 5 μ m sections were cut then processed immediately with haematoxylin and eosin (HE) for histological examination. For immunohistochemistry (IHC), heat-induced epitopal retrieval (HIER) was used by adding slides to citrate buffer (0.01M citric acid, pH6) and autoclaving them for ten minutes at 121°C. *Toxoplasma gondii* rabbit polyclonal antibody (1:600 dilution, catalogue n° PA5-16638, Thermo Fisher Scientific, Waltham, USA) and normal rabbit serum (HKV1; 1:500 dilution) for the negative control was applied to slides for 18-24 hours at 4°C. Next,

goat anti-rabbit horseradish peroxidase (HRP) polymer from Dako Envision Kit K4001 (Dako North America Incorporation, Carpinteria, USA) was applied for 30 minutes at room temperature then AEC (3-amino-9-ethylcarbazole) red chromogen solution (Vector SK-4200) was applied for 30 minutes at room temperature (Benavides *et al.*, 2011). All tissues were then counterstained with hematoxylin and mounted with coverslips (Marienfeld Microscope Cover Glasses, Lauda-Königshofen, Germany) using Shandon Consul-Mount® Histology Formulation (Thermo Fisher Scientific, Waltham, USA). Histology was carried out on all samples collected and the severity of pathology was based on the number and size of lesions observed in the tissues examined. The presence of *T. gondii* tachyzoites and cysts was assessed by IHC.

Results

Clinical observations

Clinical signs of acute toxoplasmosis were observed only in mice of G3 (stary stiff coat and poor demeanor) and G4 (ruffled coat and hunched back). The scoring of the mice is graphically summarized in Figure 1. In G3, eight mice were euthanized between 8 and 11 dpi due to their clinical score; this was earlier than the scheduled time points of 14 and 21 dpi. These samples were labeled as 8-11dpi for identification purposes and differentiation from mice euthanized at their allocated time points as part of the serial analysis. Two mice in G3 recovered from acute disease, these mice were euthanized at 14 dpi as scheduled. Nine mice in G4 displayed mild clinical signs of infection, five were symptomatic during the experiment but were euthanized at their scheduled time point and four recovered to being asymptomatic before being euthanized at their scheduled time point.

Post-mortem findings

Enlargement of mesenteric lymph nodes and spleen was the main finding in mice from all experimentally infected groups immediately after infection (24h). Organs were considered enlarged when they were at least 1.5 times larger than in the control group. Mice from G2 showed splenomegaly and lymph adenomegaly until 7 dpi, after then only MLN enlargement was observed at 14 dpi and nothing abnormal was noted at 21 dpi. Enlargement of the spleen and MLN were consistently observed until 14 and 21 dpi in G3 and G4 mice, respectively. The eight mice from G3 that were euthanized on welfare grounds at 8-10 dpi showed darker lungs than the control mice; at 8-11 dpi, the livers, kidneys and spleens were either paler or showed white spots in the surface. At 10 and 11 dpi the intestines were congested and empty and all of the mice showed symptoms of dehydration (lethargic and skin tightened). G4 mice presented with darker colored lungs at 14 and 21 dpi. The most severe splenomegaly was present in G4 mice at 14 dpi, with spleens 3 times larger than those in G1 control mice.

Cell and marker phenotypes after Toxoplasma gondii infection

Mean levels of expression (cDNA) for immune markers from experimentally infected groups (G2, G3 and G4) and uninfected G1 mice were plotted against time, which was established as the horizontal axis for graphic representation (Figure 2). Results from mice euthanized at 8 to 11 dpi were shown separately in Figure 3. All expression comparisons were made to those of G1.

The marker for which most significant different expression profiles were seen in G2 mice was MyD88 in the MLN at 14 dpi and the spleen at 21 dpi (Table 3). For G3, altered expression of the studied markers was demonstrated earlier at 48h after infection in the spleen and continued until 8 to 11 dpi in both MLN and spleen, in which increased significant results were observed (Table 3) most frequently for CD8, CD25 and IFN γ . The increase in expression of markers in G4 mice started at 96 hours after infection onwards and remained

upregulated until the end of the experiment, the MLN was the tissue for which most significant results were observed at 14 dpi (Table 3). Detailed results by specific markers and organs are described below.

CD4

Alterations in the expression of this T cell marker were observed in the spleen of mice from all experimental groups (Figure 2B). For G2 (Type II) there was a tendency for upregulation of CD4 expression at 72h, 96h (Supplementary material) but significantly decreased ($P = 0.006$) at 7 dpi compared to the control group. It was observed that the CD4 marker expression was also significantly decreased ($P=0.004$) in G3 (Genotype BrI) mice that were euthanized due severe toxoplasmosis at 8-11 dpi. The G4 (Genotype BrIII) mice demonstrated significant decreases in CD4 expression in spleen samples at 14 and 21 dpi ($P=0.008$ and $P=0.049$, respectively) compared to the control mice (Figure 3).

CD8

Significant increases in mean levels of transcription of CD8, a marker of cytotoxic T lymphocytes, were seen in mice from G3 in the spleen at 48h ($P=0.032$). However CD8 was significantly downregulated in the spleen at 7 dpi ($P=0.018$) (Table 3, Figure 2F) and both in the spleen and MLN at 8-11 dpi ($P=0.045$ and $P\leq 0.001$, respectively) of G3 mice compared to the G1 controls (Figure 3). The mice in G2 demonstrated increased expression of CD8 in the spleen during early timepoints 72h and 96h pi (Supplementary material) however, as observed for G4, no statistical differences were demonstrated when comparing these results with the data from G1.

IFN γ

The mean expression levels of this cytokine were significantly increased in the MLN of mice from G4, at 96h, 7 and 14 dpi ($P=0.009$, $P=0.009$ and $P=0.003$, respectively), compared with control group (Table 3, Figure 2C). In mice from G3 with symptoms of acute toxoplasmosis, euthanized between 8-11 dpi, IFN γ showed significantly higher expression levels in both MLN and spleen ($P=0.004$ and $P=0.046$) (Figure 3). Except at 72h pi (Supplementary material), in mice from G2 the IFN γ expression level observed was comparable with control group and no significance was observed for this group.

IL-12

Significantly increased expression of IL-12 was only observed in MLN samples from the groups of mice infected with the non-archetypal strains of *T. gondii*. For G3 mice at 8-11 dpi ($P=0.004$) and for G4 mice, at 7 and 14 dpi ($P=0.018$ and $P=0.009$, respectively) (Figure 2I). In the spleen, the mean levels of expression of IL-12 were comparable with G1 (control), except at 96h for G2, but this difference was not significant.

MyD88

MLN and spleen samples from mice from G2 exhibited higher levels of MyD88 expression, an adapter molecule for receptors of antigen presenting cells, compared with the control group at 72h (Supplementary material). However, at 14 and 21 dpi levels of MyD88 expression from the G2 mice were significant lower ($P=0.047$ and $P=0.042$, respectively) than G1. For G3 in the spleen at 96h pi significantly less MyD88 expression was observed ($P=0.05$) compared to G1. Only G4 showed significant upregulation at 7 dpi, and only for the spleen ($P=0.046$). From 24 to 72h, MyD88 expression levels were comparable to control in the non-archetypal groups (Supplementary material). In G3 mice that survived acute toxoplasmosis and were analyzed at 14 dpi, decreased expression levels of MyD88 was

observed (Figure 2L) but without significance and it is noteworthy that, compared with G1, this marker was the least altered in mice with severe disease, euthanized between 8-11 dpi (Figure 3).

CXCR3

Mean levels of the neutrophil surface activator marker CXCR3 were significantly increased only once in the studied time points, this was seen in the MLN of mice from G4 (BrIII) at 14 dpi ($P=0.047$) (Figure 2G). Apart from this, expression was comparable to the control group profile in the tissues of the other groups.

CD25

For CD25, a marker present on Tregs and early phase lymphocytes, significant higher levels of gene expression were observed in G3 mice (BrI) already showing clinical symptoms of toxoplasmosis (Figure 1) at 7dpi ($P=0.044$) (Figure 2N) and in animals euthanized at 8-11 dpi, in both MLN and spleen ($P\leq 0.0001$ and $P=0.022$, respectively) (Table 3, Figure 3). Expression levels in G2 mice (archetypal Type II variant) were comparable with G1 (control) at all time points studied. In G4, significantly reduced levels of CD25 expression were seen in the spleen at 14 dpi ($P=0.023$) (Figure 2N) compared to the G1 controls.

Detection of parasite DNA in mouse tissues

Results obtained from brain, heart, SI and OG samples collected from all experimental groups of mice at all time points between 24-96h were negative for the detection of parasite DNA. Positive results are shown in Table 4. A more widespread dissemination of parasite DNA was observed in G3 compared to the other experimental groups. The G2 mice infected with the archetypal strain M4 (Type II variant, RFLP#3) demonstrated only three PCR

positive results (brain), two at 7 dpi and one at 14 dpi. Parasite DNA was detected initially (7-14 dpi) in the brains of the G4 mice infected with the intermediate virulent genotype (BrIII) only being found in heart (1/5) and OG (1/5) on 21 dpi. For the G3 mice infected with the virulent isolate (BrI) OG samples from 4/5 mice tested PCR positive on 7 dpi and a further 8 out of 15 mice that tested positive between 7-14 dpi for at least one OG sample.

Although the chi-square test for proportions (Table 5) pointed towards statistical association between the samples considering the OG at 7 dpi ($P=0.004$) and the brain at 14 dpi ($P=0.015$), none posthoc test indicated association.

Histopathology and Immunohistochemistry

No lesions or parasites were identified in any section examined from any of the G1 or G2 mice throughout the course of the experiment.

The G3 mice euthanized at 7 dpi and between 8 to 11 dpi showed moderate to severe lesions in most tissues examined. The most severe lesions were seen in the liver (Figure 4A), intestine, and in lungs of mice euthanized between 9 and 11 dpi. In the brain, meningoencephalitis was observed at 9 and 10 dpi and it was characterized by few small perivascular cuffs, glial foci and in one brain with central necrosis. In the other organs examined variable degrees of mononuclear inflammatory infiltrate was present at 7 dpi and from 8 to 11 dpi. At 7 and 11 dpi, parasites were found in high numbers in the majority of tissues, often in, predominantly in the form of tachyzoites (Figure 4F). Mild lesions and few parasites were occasionally found in the G3 mice euthanized at 14 dpi.

In G4 mice, moderate to severe lesions were usually seen at 14 and 21 dpi in most tissues examined. The brain and lungs were the most severely affected organs. In the brain, the main finding was meningoencephalitis (Figure 4D), characterized by numerous small perivascular cuffs and few glial foci. In the lungs, all mice euthanized at 14 dpi and three of

the five mice euthanized at 21 dpi had moderate to severe mononuclear inflammation and necrosis (Figure 4G). In the liver, mild to severe lesions were present from 7 dpi until 21 dpi. Low to moderate numbers of *T. gondii* parasites were first identified in the lung, liver and intestine of G4 mice at 7 dpi. At 14 and 21 dpi, parasites were most abundant in the brain and lung. Presence of parasites in other tissues was sporadic and low. Tissue cysts were the predominant form of the parasite found in this group and they were often not associated with lesions (Figure 4H).

Discussion

In the acute phase of infection caused by non-virulent strains of *T. gondii* the sporozoites penetrate the intestinal lamina propria, stage differentiates into tachyzoites and disseminates systemically. Once the parasite is controlled by the immune system, a persistent infection is established with tissue cysts forming in the central nervous system (Dubey, 2010). However, infection with virulent isolates in mice may lead to death (Hill *et al.*, 2012) due to uncontrolled proliferation of the parasite or leading to immune imbalance of the Th1 response, as reported for European laboratory strains of *T. gondii* (Ajioka and Soldati, 2007). Previous information concerning host-pathogen immune response interactions examined by intraperitoneal inoculations of tachyzoites in mice have been obtained using archetypal strains Type III (Tuladar *et al.*, 2019), Type II (Fox *et al.*, 2016) and Type I (Torres *et al.*, 2013), but less data are available regarding oral infection (Detavernier *et al.*, 2019). Currently, only a few studies have shown results of the responses between the host immune system with non-archetypal parasites (Lu *et al.*, 2018; Meireles *et al.*, 2015; Jin *et al.*, 2019). To help understand differences in virulence between non-archetypal *T. gondii* strains, we report here novel information about tissue tropism, morbidity, mortality and the concomitant development of early immune responses of mice following an oral challenge with oocysts of

genetically distinct *T. gondii* genotypes, including two field strains. The morbidity/mortality results of mouse infections with non-archetypal genotypes BrI (G3) and BrIII (G4) are comparable with clinical observations from a previous study in which 9 of 10 mice inoculated with 50 oocysts from isolate TgCatBr71 (BrI) died of acute toxoplasmosis and all mice that were infected with TgCatBr60 (BrIII) survived (Chiebao *et al.*, 2016). This high and intermediate virulence for BrI and BrIII *T. gondii*, respectively, was also observed in our results. The present study also included more observations of lesions and the reactive spleens and MLN in experimental infected groups, which were more evident in G3 and G4; a high number of pro-inflammatory immune response markers significantly altered in G3 and seconded by G4; and more varied tissue distribution for the Brazilian strains.

During this current study the lack of statistical significance of the qRT-PCR for the immunological marker expression levels for mice from G2 in comparison to uninfected (G1) control mice may be due to variations in responses observed among the outbred individuals. Despite increased levels of expression for CD8 and MyD88 were observed in G2 at 48h and for CD4 and IL-12 at 96h pi (though these were not statistically significant), the only significant result for T cells markers was the splenic CD4 downregulation at 7 dpi. An important common finding for the infected mice (G2, G3 and G4) was the observation of lymph adenomegaly and splenomegaly at necropsy which is an indication of infection by the parasite. This is in agreement with a separate study in which spleen enlargement was also observed in BALB/c mice after 7 dpi with tachyzoites with different *T. gondii* laboratory strains (Zhang *et al.*, 2018). The absence of any pathological lesions or demonstrable parasites from G2 (M4) shows that this isolate demonstrated lower virulence than the non-archetypal strains and it seems that oocyst infection with this Type II parasite tends to be milder than tachyzoite infection (Sánchez-Sánchez *et al.*, 2019). Signs of parasite dissemination (DNA) were evidenced by the PCR results of the brain samples at 7 and 14

dpi. Infection of outbred mice with *T. gondii* Type II isolates does not usually lead to the development of severe disease and this was confirmed in the current study, in G2 mice. This could be further evidenced, since G2 mice did not show any pathological lesions or parasites when examined histologically. Similar results were observed by Bezerra *et al.*, (2019), showing that mice infected with the ME49 strain (Type II) had lower number of parasites in the central nervous system samples compared to the VEG strain (Type III).

The lack of significant expression of activated T cells markers from G2 and G4, compared to G3 may be related to the low levels of pathogen-associated molecular pattern (PAMP) presentation after phagocytosis of sporozoites, which has been previously described in gut cells of mice (Guiton *et al.*, 2017). Discrepancies with T cell expressions in this study, compared to previous results (Saeij *et al.*, 2005) could be related to the infective stage, since oocysts were used in this study while others performed infection with cysts or tachyzoites, which could lead to differences in the timing and magnitude of the immune system stimulation.

There were significantly higher levels of pro-inflammatory cytokines for the spleen samples from the non-archetypal genotype G3 (BrI) mice euthanized at 8 to 11 dpi compared to the control mice. In contrast, in the MLN at 7 dpi for G4 (BrIII) there was already upregulation of the pro-inflammatory cytokine marker IFN γ ($P=0.009$), which remained significantly increased at 14 dpi ($P=0.003$). The increase in IFN γ expression coincided with the significant activation of the IL-12 gene ($P=0.009$) and increased expression levels of the neutrophil surface activator marker CXCR3 ($P=0.047$). These observations suggest that a longer and controlled immune response at the initial site of infection balanced with an adequate expression of pro-inflammatory components at other lymphoid organs was helping to diminish clinical symptoms and in the establishment of chronic toxoplasmosis. Increased expression of IFN γ and IL-12 markers was also observed a

little later in G3, at 8-11 dpi in the MLN ($P=0.004$ and $P=0.001$, respectively), while IFN γ expression was also shown to be significantly higher ($P=0.046$) in the spleen. Previous studies using tachyzoites from archetypal strains of *T. gondii* (Types I and II) observed differences in the expression levels of IL-12. These differences were observed at around 3 to 5 days post infection, with higher levels of expression observed for the Type II strain instead (Zhang *et al.*, 2018). The Type I genotypes induced a lethal infection in mice, which was combined with the production of high serum levels of IFN γ and IL-12 (Mordue *et al.*, 2001). These results are in agreement with the findings of the present study for G3 (BrI). It would be interesting to examine the interplay between IL-12 and IFN γ further in determining clinical outcomes as it may offer a basis to evaluate if parasites from the BrIII non-archetypal genotype may have developed a mechanism to control excessive IFN γ production and thereby, avoiding the deleterious consequences of a strong Th1 response.

At 48h to 96h pi, lower expression levels of CXCR3 in G3 mice were observed in the MLN, compared to G1 (control) and this combination of results may suggest a predominance of a Th2 type immune response. As previously described, the lack of induction of cell surface receptors like CXCR3 of Th1 cells can lead to increased susceptibility to disease and is observed when neutrophils are depleted early after infection (Miller *et al.*, 2009).

The TLR-MyD88 signaling cascade was identified as essential to parasite detection by the innate immune response of mice infected with archetypal strains such as RH and ME49 (Gazzinelli *et al.*, 2014). In the current study, this dependence was corroborated in mice from G4 (BrIII), with high levels of expression observed at 7 dpi ($P=0.046$). A MyD88-dependent pathway required for mice survival was demonstrated previously, which occurred earlier than the present study (4 dpi) and when tachyzoites of the archetypal Type II strain were used (Sukhumavasi *et al.*, 2008).

Mice from G2 (Type II) and G3 (BrIII) with acute toxoplasmosis showed a

completely different result from G4. In mice from G3 a MyD88-independent pathway: with significantly lower expression of MyD88 was observed in spleen samples at 96h pi ($P=0.050$).

In G2 however, MyD88 expression was initially upregulated at 72h pi and then decreased levels of expression were seen in the MLN at 14 dpi ($P=0.047$) and in the spleen at 21 dpi ($P=0.042$). This early MyD88 dependent pathway, followed by the decrease in expression, could explain the better control of the infection of the M4 strain. As suggested before, gene expression of proinflammatory response is different according with the virulence of the strain of *Toxoplasma* (Hill *et al.*, 2012). Previously, it was also demonstrated that IFN γ production is delayed in the absence of MyD88 (Sukhumavasi *et al.*, 2008), therefore the correlation between downregulation of MyD88 and lack of IFN γ expression observed in G2 could also be a mechanism related with the low virulence of this parasite genotype.

Another important difference between groups was noted. Compared to G1, a significant increase in expression of the T cell marker CD25 was observed in mice from G3 infected with the virulent strain BrI on days 7 ($P=0.044$) and 8 to 11 in the spleen ($P = 0.022$) and at 8-11 dpi in the MLN ($P < 0.001$). This upregulation appeared to occur in severely ill mice just before they were euthanized in the acute phase of disease, but not in the G3 mice that recovered from acute toxoplasmosis. This may mean that the immune system of the mice showing severe clinical symptoms is trying to suppress the intense activation and proliferation of Th1 cells and the subsequent cascade of proinflammatory products. Alternatively, it could also reflect differences in parasite dissemination. In the groups with the more virulent parasites, more samples were positive for parasite DNA by PCR, indicating that the virulent parasites are disseminating more effectively. The increased immune responses represented by T cell markers CD8 ($P < 0.001$ at the spleen) and CD25 higher expression may be reflecting an increased parasite exposure. Previous *in vitro* studies (Saeij

et al., 2005; Dardé, 2008) with an archetypal virulent type I strain showed that higher growth rates in cell culture may either be due to a higher reinvasion rate or to a shorter doubling time, both of which increase the number of parasites. Both facts could explain the increased incidence of parasite DNA positive tissues seen in mice from G3 in the current study. The invasion ability of *T. gondii* types I, II and III were compared *in vitro* before and cellular parasite penetration was enhanced in type I strains, compared to type II (Barragan and Sibley, 2002).

Histopathological data from the non-archetypal genotypes supports the significantly higher expression levels of IL-12 and IFN γ , since the great majority of lesions and parasites in the tissues and the significant expressions of the proinflammatory cytokines were observed between 7 and 14 dpi. The G3 mice had no pathology or *Toxoplasma* DNA in tissues up to a week (24-96h) after infection. In this group from 7 dpi to 11 dpi, parasites were found in high numbers in all organs but especially in the liver, lungs and intestine. Pathology was most consistently severe in the liver and intestine between 7 and 11 dpi and in the lungs from 9 to 11 dpi. Lesions and parasites were frequently found in the kidney, an organ not extensively studied in toxoplasmosis research. Most kidney samples with at least moderate lesions were also pale in appearance at postmortem. At 14 dpi, only mild lesions and infrequent parasites were found in the lung and liver, respectively, by IHC. However, PCR analysis gave different results, identifying DNA parasite in the brains of most mice from the BrI (14/15) and BrIII (13/15) at 7 and 14 dpi. This difference may have occurred due to low numbers of parasites and their heterogeneous distribution resulting in the parasites being missed when sections were cut for IHC. The changes described in the most severely affected organs may explain some of the clinical signs observed in euthanized mice in this group, however, it is possible that the parasitaemia and immune response (also indicated by splenomegaly and lymphadenopathy detected at post mortem) were also significant contributing factors to the

mouse morbidity and mortality. In a previous study on *Toxoplasma* burden in tissue samples of mice infected with tachyzoites of the virulent RH strain using qPCR, it was reported that significantly higher parasite loads were observed earlier than in our study, at 24 and 48h pi. The parasites were also mainly located in the liver and kidney, although the lungs were not analyzed in their study (Dadimoghaddam *et al.*, 2014). Tachyzoites appear to be the most frequent form of the parasite identified in BrI infected G3 mice, compared with G4 mice infected with BrIII in which bradyzoite (tissue cysts) were found more often. From our current results, it could be speculated that the virulent strain remains in the acute phase for longer. Therefore, the timing at which tachyzoites and bradyzoites begin to be found could be an indicator for strain virulence.

In this current mouse study, an important observation is that OG (eyes) appear to be a site of predilection for the virulent BrI strain (G3). This tropism is in accordance with a previous study in which *T. gondii* was quantified in high loads in eyes from mice after three days of infection with an archetypal Type I strain (Dadimoghaddam *et al.*, 2014). This early finding may be related to the intraperitoneal injection method and the use of tachyzoites (Dadimoghaddam *et al.*, 2014) rather than using oocysts as described in this study. Collection of the OG may represent a viable sampling tissue for detection studies (saving the brain for isolation purposes) and indicate that ocular infection could be a virulence related trait, as observed in human toxoplasmosis in Brazil (Lopes *et al.*, 2009; Herrmann *et al.*, 2014; Mendes *et al.*, 2014). Although no statistical significance was observed, the biological significance of the many PCR positive results in G3, at earlier timepoints, in specific organs, is clear. This positivity suggests that the virulent isolate (BrI) is driving a proinflammatory response that could lead to parasite evasion by dissemination to immune privileged organs, such as OG and brain.

Mice from G4 (BrIII) did not show severe pathology or high parasite dissemination in

the majority of organs during the acute stage of infection, before 14 dpi. No parasites were detected with IHC in the brain before 14 dpi but parasite DNA was detected by PCR in all animals at 7 dpi. Again, it is possible that there were low numbers of parasites and they were not detected, or they were not present in the histological section. At 14 and 21 dpi, brains and lungs were the most affected organs. At 21 dpi, lesions were less severe and parasite invasion was reduced in organs compared to 14 dpi which may suggest a resolving infection as a result of an adequate immune response and may be further supported by the reduced incidence of splenomegaly and lymphadenopathy. This reduction in pathology was in lambs experimentally infected with oocysts of *T. gondii* (M4 Type II variant), with a reduction in lesions in the central nervous system from 14 dpi (Katzer *et al.*, 2014). Large genetic variability of *T. gondii* in Brazil has been shown both in animal and human reservoirs, which could be implicated in the clinical disease outcome. Recent studies in Brazil predominantly reported diverse new non-archetypal genotypes; the most common single genotype found was BrIII and it was identified in chickens, horses and wild mammals (Fournier *et al.*, 2014; Pena *et al.*, 2018a; Silva *et al.*, 2018) in addition a type I genotype, although rare, was also described (Pena *et al.*, 2018b). Finding such diverse strains supports the need for further studies comparing specific and cross protection immune responses raised against them by the hosts.

Mice infected with BrI (G3) failed to generate a sufficiently robust protective immune response to overcome the disease caused by the virulent BrI genotype. Two hypotheses are given as to why this may have happened. Firstly, the virulent parasites induce an internal mechanism to suppress immunomodulation, as reported in the CTLA-4 blockage by *Trypanosoma cruzi* (Martins *et al.*, 2004) and the excessive levels of resultant cytokines were lethal. Secondly, since the severely ill mice had higher expression levels of IFN γ than surviving mice and we demonstrated that its balanced production is important to overcome

disease, then the virulent parasite could be stimulating its pathway. The mucosal immunity balanced with a controlled Th1 response in other tissues from the intermediate virulent strain (G4, BrIII) could be the optimal pathway stimulated to disease chronification and parasite propagation. The whole mechanism of action involved in the infection by different genotypes of *T. gondii* must be elucidated and future studies should also consider the role of the differences in growth rates of the parasite.

Overall, the results showed an overview of key molecules involved in the initial immune response against non-archetypal and archetypal strains of the parasite in mice and that virulence differs between strains, not only due to immune response stimuli variation but it is also due to different kinetics of gene expression. The present study has provided a basis for more evaluations of other possible pathways, for example host related regulatory compounds, like Foxp3 and ocular cytokinomes, or alternatively parasite virulence genes such as polymorphic rhopty protein kinases ROP18 and ROP5.

Supplementary material

Available on the Cambridge University Press platform alongside the article.

Acknowledgments

Thanks are due to CNPq (Brazilian National Council for Scientific and Technological Development) for supporting R.M.S. in this study (process number 310532/2017-5).

Author contribution

DPC, RMS and EAI conceived the experiment. DPC, PMB, EAI and FK designed the experiment. DPC and AB conducted the experiment. PB performed the statistical analysis. LEB and FC completed the histopathological analysis. DPC, PB, HFJP, LEB, FC and FK

contributed to the interpretation of data. DPC, PMB, AB, LEB, FC, EAI and FK wrote the article.

Financial support

This study was funded by the Moredun Foundation, Scottish Government's Rural and Environment Science and Analytical Services Division (RESAS); FAPESP (Research Support Foundation of the State of São Paulo) (R.M.S., grant number 2011/19297-8) and CAPES (Higher Education Improvement Coordination) (D.P.C., grant number 0382/14-0).

Conflict of interest

The authors declare there are no conflicts of interest.

Ethical standards

The animals were purchased for experimental purposes and all procedures were approved by the Moredun Research Institute Animal Welfare and Ethical Review Body (AWERB) (Experiment No E22-14) and Biomathematics and Statistics Scotland (BIOSS). All experimental procedures complied fully with the regulations laid down by the Home Office of Great Britain and Northern Ireland for compliance with the Animals (Scientific Procedures) Act 1986.

We confirm that the manuscript has been read and approved by all named authors and that there are no other persons who satisfied the criteria for authorship but are not listed. We further confirm that all of us have approved the order of authors listed in the manuscript.

References

- Ajioka, J. W. and Soldati, D.** (2007). *Toxoplasma: molecular and cellular biology*. ed. Ajioka, J. W. and Soldati, D. Horizon Bioscience, Wymondham.
- Ajzenberg, D., Cogné, N., Paris, L., Bessières, M.-H., Thulliez, P., Filisetti, D., Pelloux, H., Marty, P. and Dardé, M.-L.** (2002). Genotype of 86 *Toxoplasma gondii* isolates associated with human congenital toxoplasmosis, and correlation with clinical findings. *The Journal of infectious diseases* **186**, 684–689. doi: 10.1086/342663.
- Barragan, A. and Sibley, L. D.** (2002). Transepithelial migration of *Toxoplasma gondii* is linked to parasite motility and virulence. *Journal of Experimental Medicine* **195**, 1625–1633.
- Bartley, P.M., Burrells, A., Benavides, J., Canton, G., Garcia, J.L., Thomson, J., Chianini, F., Innes, E.A. and Katzer, F.** (2019). Cell mediated and innate immune responses in pigs following vaccination and challenge with *Toxoplasma* parasites. *Veterinary Parasitology* **275**, 108963. doi:10.1016/j.vetpar.2019.108963.
- Bartley, P. M., Katzer, F., Rocchi, M. S., Maley, S. W., Benavides, J., Nath, M., Pang, Y., Cantón, G., Thomson, J., Chianini, F. and Innes, E. A.** (2013a). Development of maternal and foetal immune responses in cattle following experimental challenge with *Neospora caninum* at day 210 of gestation. *Veterinary Research* **44**, 91. doi: 10.1186/1297-9716-44-91.
- Bartley, P. M., Wright, S. E., Zimmer, I. A., Roy, S., Kitchener, A. C., Meredith, A., Innes, E. A. and Katzer, F.** (2013b). Detection of *Neospora caninum* in wild carnivorans in Great Britain. *Vet. Parasitol. Veterinary Parasitology* **192**, 279–283.
- Benavides, J., Maley, S., Pang, Y., Palarea, J., Eaton, S., Katzer, F., Innes, E. A., Buxton, D. and Chianini, F.** (2011). Development of lesions and tissue distribution of parasite in lambs orally infected with sporulated oocysts of *Toxoplasma gondii*.

Veterinary Parasitology **179**, 209–215.

- Bezerra, E. C. M., dos Santos, S. V., dos Santos, T. C. C., de Andrade, H. F. and Meireles, L. R.** (2019). Behavioral evaluation of BALB/c (*Mus musculus*) mice infected with genetically distinct strains of *Toxoplasma gondii*. *Microbial Pathogenesis* **126**, 279–286. doi: 10.1016/j.micpath.2018.11.021.
- Burrells, A., Bartley, P. M., Zimmer, I. A., Roy, S., Kitchener, A. C., Meredith, A., Wright, S. E., Innes, E. A. and Katzer, F.** (2013). Evidence of the three main clonal *Toxoplasma gondii* lineages from wild mammalian carnivores in the UK. *Parasitology* **140**, 1768–1776.
- Buxton, D., Wright, S., Maley, S. W., Rae, A. G., Lundén, A. and Innes, E. A.** (2001). Immunity to experimental neosporosis in pregnant sheep. *Parasite Immunology* **23**, 85–91. doi: 10.1046/j.1365-3024.2001.00362.x.
- Chiebao, D. P., Pena, H. F. D. J., Cabral, A. D., Rocca, M. P., Lopes, E. G., Valadas, S. Y. O. B., Keid, L. B., Grisi Filho, J. H. H. and Soares, R. M.** (2016). Infection of mice with oocysts of *Toxoplasma gondii* by oral route showed differences of virulence from Brazilian RFLP genotypes BrI and BrIII. *Research in Veterinary Science* **107**, 257–260. doi: 10.1016/j.rvsc.2016.06.010.
- Chiebao, D. P., Pena, H. F., Passarelli, D., Santín, T., Pulz, L. H., Strefezzi, R. F., Sevá, A. P., Martins, C. M., Lopes, E. G., Grisi-Filho, J. H. H., Gennari, S. M. and Soares, R. M.** (2019). Congenital transmission of *Toxoplasma gondii* after experimental reinfection with brazilian typical strains in chronically infected sheep. *Frontiers in Veterinary Science* **6**, 1–11. doi: 10.3389/fvets.2019.00093.
- Chiu, B.C., Martin, B.E., Stolberg, V.R. and Chensue, S.W.** (2013). Cutting edge: Central memory CD8 T cells in aged mice are virtual memory cells. *The Journal of Immunology*. **191**, 5793-5796.

- Dadimoghaddam, Y., Daryani, A., Sharif, M., Ahmadpour, E. and Hossienikhah, Z.** (2014). Tissue tropism and parasite burden of *Toxoplasma gondii* RH strain in experimentally infected mice. *Asian Pacific Journal of Tropical Medicine*. **7**, 521-524.
- Dardé, M. L.** (2008). *Toxoplasma gondii*, “new” genotypes and virulence. *Parasite* **15**, 366–371. doi: 10.1051/parasite/2008153366.
- Detavernier, A., Azouz, A., Shehade, H., Splittgerber, M., Van Maele, L., Nguyen, M., Thomas, S., Achouri, Y., Svec, D., Calonne, E., Fuks, F., Oldenhove, G. and Goriely, S.** (2019). Monocytes undergo multi-step differentiation in mice during oral infection by *Toxoplasma gondii*. *Communications Biology* **2**, 1–14. doi: 10.1038/s42003-019-0718-6.
- Dubey, J. P.** (2010). *Toxoplasmosis of animals and humans*, 2nd Edn. CRC Press, Boca Raton.
- Dubey, J. P. and Beattie, C. P.** (1988). *Toxoplasmosis of animals and man*. CRC Press, Boca Raton.
- Dubey, J. P., Lago, E. G., Gennari, S. M., Su, C. and Jones, J. L.** (2012). *Toxoplasmosis in humans and animals in Brazil: high prevalence, high burden of disease, and epidemiology*. doi: 10.1017/S0031182012000765.
- Elbez-Rubinstein, A., Ajzenberg, D., Dardé, M.-L., Cohen, R., Dumètre, A., Yera, H., Gondon, E., Janaud, J. C. and Thulliez, P.** (2009). Congenital toxoplasmosis and reinfection during pregnancy: case report, strain characterization, experimental model of reinfection and review. *Journal of Infectious Diseases* **199**, 280–285.
- Fournier, G. F. D. S. R., Lopes, M. G., Marcili, A., Ramirez, D. G., Acosta, I. C. L., Giuli da Silva Ferreira, J. I., Cabral, A. D., Ribeiro de Lima, J. T., Fatima de Jesus Pena, H., Dias, R. A. and Gennari, S. M.** (2014). *Toxoplasma gondii* in domestic and wild animals from forest fragments of the municipality of Natal, northeastern Brazil.

Revista brasileira de parasitologia veterinaria **23**, 501–508. doi: 10.1590/S1984-29612014092.

Fox, B. A., Rommerein, L. M., Guevara, R. B., Falla, A., Triana, M. A. H., Sun, Y. and Bzik, D. J. (2016). The *Toxoplasma gondii* rhostry kinome is essential for chronic infection. *mBio* **7**, e00193-16. doi: 10.1128/mBio.00193-16.Editor.

Ganesan, A.P., Johansson, M., Ruffell, B., Yagui-Beltran, A., Lau, J., Jablons, D.M. and Coussens, L.M. (2013). Tumor-infiltrating regulatory T cells inhibit endogenous cytotoxic T cell responses to lung adenocarcinoma. *The Journal of Immunology* **191**, 2009-2017.

Gazzinelli, R. T., Mendonça-Neto, R., Lilue, J., Howard, J. and Sher, A. (2014). Innate resistance against *Toxoplasma gondii*: An evolutionary tale of mice, cats, and men. *Cell Host and Microbe* **15**, 132–138. doi:10.1016/j.chom.2014.01.004.

Guiton, P. S., Sagawa, J. M., Fritz, H. M. and Boothroyd, J. C. (2017). An in vitro model of intestinal infection reveals a developmentally regulated transcriptome of *Toxoplasma* sporozoites and a NF- κ B-like signature in infected host cells. *PLoS ONE* **12**, 1–29. doi: 10.1371/journal.pone.0173018.

Hamilton, C., Robins, R., Thomas, R., Oura, C., Oliveira, S., Villena, I., Innes, E. A., Katzer, F. and Kelly, P. J. (2019). Prevalence and genetic diversity of *Toxoplasma gondii* in free-ranging chickens from the Caribbean. *Acta Parasitologica* **64**, 738–744. doi: 10.2478/s11686-019-00071-7.

Herrmann, D. C., Maksimov, P., Hotop, A., Groß, U., Däubener, W., Liesenfeld, O., Pleyer, U., Conraths, F. J. and Schares, G. (2014). Genotyping of samples from German patients with ocular, cerebral and systemic toxoplasmosis reveals a predominance of *Toxoplasma gondii* type II. *International Journal of Medical Microbiology* **304**, 911–916. doi: 10.1016/j.ijmm.2014.06.008.

- Hide, G., Morley, E. K., Hughes, J. M., Gerwash, O., Elmahaishi, M. S., Elmahaishi, K. H., Thomasson, D., Wright, E. a, Williams, R. H., Murphy, R. G. and Smith, J. E.** (2009). Evidence for high levels of vertical transmission in *Toxoplasma gondii*. *Parasitology* **136**, 1877–85. doi: 10.1017/S0031182009990941.
- Hill, R. D., Gouffon, J. S., Saxton, A. M. and Su, C.** (2012). Differential gene expression in mice infected with distinct toxoplasma strains. *Infection and Immunity* **80**, 968–974. doi: 10.1128/IAI.05421-11.
- Hochberg Y.** (1988). A Sharper Bonferroni Procedure for Multiple Tests of Significance. *Biometrika* **75**, 800–802. doi:10.1093/biomet/75.4.800
- Hoeman, C.M., Dhakal, M., Zaghouni, A.A., Cascio, J.A., Wan, X., Khairallah, M.T., Chen, W. and Zaghouni, H.** (2013). Developmental expression of IL-12Rbeta2 on murine naive neonatal T cells counters the upregulation of IL-13Ralpha1 on primary Th1 cells and balances immunity in the newborn. *The Journal of Immunology* **190**, 6155-6163.
- Howe, D. K. and Sibley, L. D.** (1995). *Toxoplasma gondii* comprises three clonal lineages: correlation of parasite genotype with human disease. *Journal of Infectious Diseases* **172**, 1561–1566.
- Hurtado, A., Aduriz, G., Moreno, B., Barandika, J. and Garcia-Perez, A. L.** (2001). Single tube nested PCR for the detection of *Toxoplasma gondii* in fetal tissues from naturally aborted ewes. *Veterinary Parasitology* **102**, 17–27. doi: 10.1016/S0304-4017(01)00526-X.
- Innes, E. A. and Vermeulen, A. N.** (2006). Vaccination as a control strategy against the coccidial parasites *Eimeria*, *Toxoplasma* and *Neospora*. *Parasitology* **133**, 145–168.
- Jin, Y., Yao, Y., El-Ashram, S., Tian, J., Shen, J. and Ji, Y.** (2019). The Neurotropic Parasite *Toxoplasma gondii* Induces Astrocyte Polarization Through NFκB Pathway.

Frontiers in Medicine 6, 1–7. doi: 10.3389/fmed.2019.00267.

- Johnson-Tardieu, J.M., Walworth, E.W., Cornelius, J.G., Ye, X., Schuster, S.M. and Peck, A.B.** (1996). Autoimmune diabetes-prone NOD mice express the Lyt2 alpha (Lyt2.1) and Lyt3 alpha (Lyt3.1) alleles of CD8. *Immunogenetics* 43, 6-12.
- Katzer, F., Canton, G., Burrells, A., Palarea-Albaladejo, J., Horton, B., Bartley, P. M., Pang, Y., Chianini, F., Innes, E. a. and Benavides, J.** (2014). Immunization of lambs with the S48 strain of *Toxoplasma gondii* reduces tissue cyst burden following oral challenge with a complete strain of the parasite. *Veterinary Parasitology* 205, 46–56. doi: 10.1016/j.vetpar.2014.07.003.
- Kawai, T. and Akira, S.** (2005). Toll-like receptor downstream signaling. *Arthritis Research and Therapy* 7, 12–19.
- Konecki, D.S., Brennand, J., Fuscoe, J.C., Caskey, C.T. and Chinault, A.C.** (1982). Hypoxanthine-guanine phosphoribosyl transferase genes of mouse and Chinese hamster: construction and sequence analysis of cDNA recombinants. *Nucleic Acids Research* 10, 6763-6775.
- Lopes, F. M. R., Gonçalves, D. D., dos Reis, C. R., Breganó, R. M., Freire, R. L., de Freitas, J. C. and Navarro, I. T.** (2009). Presence of domesticated cats and visual impairment associated to *Toxoplasma gondii* serum positive children at an elementary school in Jataizinho, state of Paraná, Brazil. *Revista Brasileira de Parasitologia Veterinaria* 17, 12–15. doi: S1984-29612008000100003 [pii].
- Lu, Y. Y., Dong, H., Feng, Y. J., Wang, K., Jiang, Y. B., Zhang, L. X. and Yang, Y. R.** (2018). Avirulence and lysozyme secretion in Paneth cells after infection of BALB/c mice with oocysts of *Toxoplasma gondii* strains TgCatCHn2 (ToxoDB#17) and TgCatCHn4 (ToxoDB#9). *Veterinary Parasitology* 252, 1–8. doi: 10.1016/j.vetpar.2018.01.016.

- Martins, G. A., Tadokoro, C. E., Silva, R. B., Silva, J. S. and Rizzo, L. V. (2004).** CTLA-4 Blockage Increases Resistance to Infection with the Intracellular Protozoan *Trypanosoma cruzi*. *The Journal of Immunology* **172**, 4893–4901. doi: 10.4049/jimmunol.172.8.4893.
- Massad, E., Menezes, R.X., Silveira, P.S.P. and Ortega N.R.S. (2004).** Métodos Quantitativos em Medicina. Manole, Barueri.
- Meireles, L. R., Ekman, C. C. J., Andrade Júnior, H. F. De and Luna, E. J. D. A. (2015).** Human toxoplasmosis outbreaks and the agent infection form. Findings from a systematic review. *Journal of the Institute of Tropical Medicine of Sao Paulo* **57**, 369–376. doi: 10.1590/S0036-46652015000500001.
- Mendes, N. H. D., Oliveira, C. B. S., Garcia, C. A., Holanda, C. M. X. C. and Andrade-Neto, V. F. (2014).** Epidemiological and serological profiles of ocular toxoplasmosis in the municipality of Natal, northeastern Brazil. *Transactions of the Royal Society of Tropical Medicine and Hygiene* **108**, 656–661. doi: 10.1093/trstmh/tru113.
- Miller, C. M., Boulter, N. R., Ikin, R. J. and Smith, N. C. (2009).** The immunobiology of the innate response to *Toxoplasma gondii*. *International Journal for Parasitology* **39**, 23–39. doi: 10.1016/j.ijpara.2008.08.002.
- Minitab. (2019).** Suporte ao Minitab **18**. Available at: <https://support.minitab.com/pt-br/minitab/18/>.
- Mordue, D. G., Monroy, F., La Regina, M., Dinarello, C. a and Sibley, L. D. (2001).** Acute toxoplasmosis leads to lethal overproduction of Th1 cytokines. *Journal of immunology (Baltimore, Md. : 1950)* **167**, 4574–4584. doi: 10.4049/jimmunol.167.8.4574.
- Pena, H. F. J., Soares, R. M., Amaku, M., Dubey, J. P. and Gennari, S. M. (2006).** *Toxoplasma gondii* infection in cats from São Paulo state, Brazil: Seroprevalence,

oocyst shedding, isolation in mice, and biologic and molecular characterization. *Research in Veterinary Science* **81**, 58–67. doi: 10.1016/j.rvsc.2005.09.007.

Pena, H. F. J., Gennari, S. M., Dubey, J. P. and Su, C. (2008). Population structure and mouse-virulence of *Toxoplasma gondii* in Brazil. *International Journal for Parasitology* **38**, 561–569. doi: 10.1016/j.ijpara.2007.09.004.

Pena, H. F. J., Pinheiro, T. M., Soares, H. S., Oliveira, S., Alves, B. F., Ferreira, M. N. and Gennari, S. M. (2018a). Typical Brazilian genotype of *Toxoplasma gondii* isolated from a horse destined for human consumption in Europe from a slaughterhouse. *Parasitology Research* **117**, 3305–3308. doi: 10.1007/s00436-018-5999-z.

Pena, H. F. J., Alves, B. F., Soares, H. S., Oliveira, S., Ferreira, M. N., Bricarello, P. A., Machado, T. M. P., Castro, B. B. P. and Gennari, S. M. (2018b). Free-range chickens from Santa Catarina state, southern Brazil, as asymptomatic intermediate hosts for *Toxoplasma gondii* clonal type I and typical Brazilian genotypes. *Veterinary Parasitology: Regional Studies and Reports* **13**, 55–59. doi: 10.1016/j.vprsr.2018.04.001.

Saeij, J. P. J., Boyle, J. P. and Boothroyd, J. C. (2005). Differences among the three major strains of *Toxoplasma gondii* and their specific interactions with the infected host. *Trends in Parasitology* **21**, 476–481. doi: 10.1016/j.pt.2005.08.001.

Sánchez-Sánchez, R., Ferre, I., Regidor-Cerrillo, J., Gutiérrez-Expósito, D., Ferrer, L. M., Arteché-Villasol, N., Moreno-Gonzalo, J., Müller, J., Aguado-Martínez, A., Pérez, V., Hemphill, A., Ortega-Mora, L. M. and Benavides, J. (2019). Virulence in Mice of a *Toxoplasma gondii* Type II Isolate Does Not Correlate With the Outcome of Experimental Infection in Pregnant Sheep. *Frontiers in Cellular and Infection Microbiology* **9**, 1–18. doi:10.3389/fcimb.2018.00436.

Shaw, M. H., Freeman, G. J., Scott, M. F., Fox, B. A., Bzik, D. J., Belkaid, Y. and Yap,

- G. S.** (2006). Tyk2 negatively regulates adaptive Th1 immunity by mediating IL-10 signaling and promoting IFN-gamma dependent IL-10 reactivation. *Journal of immunology (Baltimore, Md.: 1950)* **176**, 7263–7271.
- Shibata, K., Yamada, H., Nakamura, M., Hatano, S., Katsuragi, Y., Kominami, R. and Yoshikai, Y.** (2014). IFN-gamma-producing and IL-17-producing gammadelta T cells differentiate at distinct developmental stages in murine fetal thymus. *The Journal of Immunology* **192**, 2210-2218.
- Sukhumavasi, W., Egan, C. E., Amy, L., Taylor, G. a, Fox, B. a, David, J., Denkers, E. Y., Warren, A. L. and Bzik, D. J.** (2008). TLR adaptor MyD88 is essential for pathogen control during oral *Toxoplasma gondii* infection but not adaptive immunity induced by a Vaccine Strain of the Parasite. *The Journal of Immunology* **181**, 3464–3473. doi:www.jimmunol.org/content/181/5/3464
- Shwab, E. K., Zhu, X. Q., Majumdar, D., Pena, H. F. J., Gennari, S. M., Dubey, J. P. and Su, C.** (2014). Geographical patterns of *Toxoplasma gondii* genetic diversity revealed by multilocus PCR-RFLP genotyping. *Parasitology* **141**, 453–461. doi: 10.1017/S0031182013001844.
- Sibley, D. L., Mordue, D. and Howe, D. K.** (1999). Experimental approaches to understanding virulence in toxoplasmosis. *Immunobiology* **201**, 210–224. doi: 10.1016/S0171-2985(99)80061-8.
- Silva, M. A., Pena, H. F. J., Soares, H. S., Aizawa, J., Oliveira, S., Alves, B. F., Souza, D. S., Melo, R. P. B., Gennari, S. M., Mota, R. A. and Silva, J. C. R.** (2018). Isolation and genetic characterization of *Toxoplasma gondii* from free-ranging and captive birds and mammals in Pernambuco State, Brazil. *Revista Brasileira de Parasitologia Veterinaria* **27**, 481–487. doi: 10.1590/s1984-296120180059.
- Strausberg, R.L., Feingold, E.A., Grouse, L.H., Derge, J.G., Klausner, R.D., Collins,**

F.S., Wagner, L., Shenmen, C.M., Schuler, G.D., Altschul, S.F., Zeeberg, B., Buetow, K.H., Schaefer, C.F., Bhat, N.K., Hopkins, R.F., Jordan, H., Moore, T., Max, S.I., Wang, J., Hsieh, F., Diatchenko, L., Marusina, K., Farmer, A.A., Rubin, G.M., Hong, L., Stapleton, M., Soares, M.B., Bonaldo, M.F., Casavant, T.L., Scheetz, T.E., Brownstein, M.J., Usdin, T.B., Toshiyuki, S., Carninci, P., Prange, C., Raha, S.S., Loquellano, N.A., Peters, G.J., Abramson, R.D., Mullahy, S.J., Bosak, S.A., McEwan, P.J., McKernan, K.J., Malek, J.A., Gunaratne, P.H., Richards, S., Worley, K.C., Hale, S., Garcia, A.M., Gay, L.J., Hulyk, S.W., Villalon, D.K., Muzny, D.M., Sodergren, E.J., Lu, X., Gibbs, R.A., Fahey, J., Helton, E., Kettelman, M., Madan, A., Rodrigues, S., Sanchez, A., Whiting, M., Madan, A., Young, A.C., Shevchenko, Y., Bouffard, G.G., Blakesley, R.W., Touchman, J.W., Green, E.D., Dickson, M.C., Rodriguez, A.C., Grimwood, J., Schmutz, J., Myers, R.M., Butterfield, Y.S., Krzywinski, M.I., Skalska, U., Smailus, D.E., Schnerch, A., Schein, J.E., Jones, S.J. and Marra, M.A. (2002). Generation and initial analysis of more than 15,000 full-length human and mouse cDNA sequences. *Proceedings of the National Academy of Sciences of the United States of America* **99**, 16899-16903.

Sukhumavasi, W., Egan, C. E., Amy, L., Taylor, G. a, Fox, B. a, David, J., Denkers, E. Y., Warren, A. L. and Bzik, D. J. (2008). TLR adaptor MyD88 is essential for pathogen control during oral *Toxoplasma gondii* infection but not adaptive immunity induced by a Vaccine Strain of the Parasite. *The Journal of Immunology* **181**, 3464–3473. doi: www.jimmunol.org/content/181/5/3464.

Torres, M., Guiton, R., Lacroix-Lamandé, S., Ryffel, B., Leman, S. and Dimier-Poisson, I. (2013). MyD88 is crucial for the development of a protective CNS immune response to *Toxoplasma gondii* infection. *Journal of neuroinflammation* **10**, 19. doi: [10.1186/1742-2094-10-19](https://doi.org/10.1186/1742-2094-10-19).

- Tuladar, S., Kochanowsky, J. A., Bhaskara, A., Ghotmi, Y., Chandrasekaran, S. and Koshy, A. A.** (2019). The ROP16 III -dependent early immune response determines the subacute CNS immune response and type III *Toxoplasma gondii* survival. *PLoS Pathogens* **15**, e1007856. doi: 10.1371/journal.ppat.1007856.
- Tzanidakis, N., Maksimov, P., Conraths, F. J., Kiossis, E., Brozos, C., Sotiraki, S. and Schares, G.** (2012). *Toxoplasma gondii* in sheep and goats: Seroprevalence and potential risk factors under dairy husbandry practices. *Veterinary Parasitology* **190**, 340–348. doi: 10.1016/j.vetpar.2012.07.020.
- Wang, Z., Filgueiras, L.R., Wang, S., Serezani, A.P., Peters-Golden, M., Jancar, S. and Serezani, C.H.** (2014). Leukotriene B4 enhances the generation of proinflammatory microRNAs to promote MyD88-dependent macrophage activation. *The Journal of Immunology* **192**, 2349-2356.
- Watson, W. A. and Beverley, J. K. A.** (1971). Epizootics of toxoplasmosis causing ovine abortion. *Veterinary Records* **88**, 120–124.
- Zhang, Y., Jiang, N., Zhang, T., Wang, D., Feng, Y., Sang, X., Yang, N. and Chen, Q.** (2018). *Toxoplasma gondii* Genotype Determines Tim-3 Expression Levels in Splenic and Circulatory T Cells in Mice. *Frontiers in Microbiology* **9**, 1–9. doi: 10.3389/fmicb.2018.02967.

Table 1. Mice scoring system listing the criteria to euthanize an animal after experimental infection (total score = A+B)

Category	Description	Score
A=Coat Condition	Sleek/glossy coat	0
	Ruffled coat	1
	Stary stiff coat	2
B=Demeanor	Bright and active	0
	Hunched	1
	A reluctance to move	1
	Tottering gait	1

Accepted Manuscript

Table 2. Marker name, primer sequence, identification and references of the primers used for qRT-PCR in mice tissues

Marker	Sequence	GenBank accession	Reference
HPRT	5'- TGCTGACCTGCTGGATTACA-3' 5'- TATGTCCCCCGTTGACTGAT-3'	J00423	(Konecki et al., 1982)
CD4	5'- AGGAAGTGAACCTGGTGGTG-3' 5'-CTCCTGCTTCAGGGTCAGTC-3'	NM013488	(Ganesan et al., 2013)
CD8	5'- CCGTGAGGGACACGAATAAT-3' 5'- GACTGGCACGACAGAACTGA-3'	MMU34881	(Johnson-Tardieu et al., 1996)
CD25	5'- AGAACACCACCGATTTCTGG-3' 5'- CTGTGGGTTGTGGGAAGTCT-3'	BC114437	(Strausberg et al., 2002)
IFN- γ	5'- GCGTCATTGAATCACACCTG-3' 5'- TGAGCTCATTGAATGCTTGG-3'	NM008337	(Shibata et al., 2014)
IL-12	5'- AAGCCACCAGTCCCAGTATG-3' 5'- GAACAGGCCACAGTTCCATT-3'	NM008354	(Hoeman et al., 2013)
CXCR3	5'- GCAAGTCCCAACCACAAGT-3' 5'- CAAAGTCCGAGGCATCTAGC-3'	NM009910	(Chiu et al., 2013)
MyD88	5'- ACTGGCCTGAGCAACTAGGA-3' 5'- TGTCCCAAAGGAAACACACA-3'	NM010851	(Wang et al., 2014)

Accepted Manuscript

Table 3. One Way ANOVA significant results obtained after qRT-PCR analysis of markers from immunological components expressed by tissues of mice experimentally infected with different strains of *Toxoplasma gondii* against the Δ Ct value of HPRT from non-infected mice. Up and down arrows represent up and downregulation, respectively

		Groups compared with G1 (control)		
		G2 (Type II)	G3 (BrI)	G4 (BrIII)
MLN				<u>4 dpi</u> ↓IFN γ ($P = 0.009$)
	<u>14 dpi</u> ↓MyD88 ($P = 0.047$)		<u>8-11 dpi</u> ↓CD8 ($P = 0.045$) ↑IL-12 ($P = 0.001$) ↑CD25 ($P < 0.0001$) ↑IFN γ ($P = 0.004$)	<u>7 dpi</u> ↑IFN γ ($P = 0.009$) <u>14 dpi</u> ↑CXCR3 ($P = 0.047$) ↑IL-12 ($P = 0.009$) ↑IFN γ ($P = 0.003$)
SPLEEN			<u>2 dpi</u> ↓CD8 ($P = 0.032$)	<u>7 dpi</u> ↑MyD88 ($P = 0.046$)
	<u>7 dpi</u> ↓CD4 ($P = 0.006$)		<u>4 dpi</u> ↓MyD88 ($P = 0.050$)	
			<u>7 dpi</u> ↓CD8 ($P = 0.018$) ↑CD25 ($P = 0.044$)	<u>14 dpi</u> ↓CD4 ($P = 0.008$) ↓CD25 ($P = 0.023$)
	<u>21 dpi</u> ↓MyD88 ($P = 0.042$)		<u>8-11 dpi</u> ↓CD4 ($P = 0.004$) ↑CD8 ($P < 0.0001$) ↑CD25 ($P = 0.022$) ↑IFN γ ($P = 0.046$)	<u>21 dpi</u> ↑CD4 ($P = 0.049$)

Accepted

Table 4. *Toxoplasma gondii* DNA detection by ITS1 nested-PCR in tissues from mice orally infected with oocysts from different genotypes

<i>T. gondii</i> genotype	DPI	Tissue			
		SI	Heart	Brain	OG
G2 - M4 (type II)	7	0 (5)	0 (5)	2 (5)	0 (5)
	14	0 (5)	0 (5)	1 (5)	0 (5)
	21	0 (5)	0 (5)	0 (5)	0 (5)
G3 - BrI	7	0 (5)	2 (5)	4 (5)	4 (5)
	8-11	0 (8)	1 (8)	8(8)	3(8)
	14	0 (2)	0 (2)	2 (2)	1 (2)
G4 - BrIII	7	0 (5)	0 (5)	5 (5)	0 (5)
	14	0 (5)	0 (5)	5 (5)	0 (5)
	21	0 (5)	1 (5)	3 (5)	1 (5)

DPI = days post infection

SI = small intestine

OG = ocular globe

() = number of mice tested

Accepted Manuscript

Table 5: *P*-value obtained from proportion chi-square test for each evaluated organ, considering the three genotypes of *Toxoplasma gondii*. Each statistical test was specifically performed for 7, 14 and 21 days. The significance level was assumed as $\alpha = 0.05$ and $\alpha_{\text{bonf}} = 0.016$ for posthoc test.

		SI	Heart	Brain	OG
07 Days	Proportion chi-square test ($\alpha = 0.05$)				
		NA	0.100	0.092	0.004
	Pairwise comparisons between proportions ($\alpha_{\text{bonf}} = 0.016$)				
	G3 (BrI) – G2 (TypeII)	NA	0.86	1.00	0.11
	G4 (BrIII) – G2 (TypeII)	NA	NA	0.50	NA
	G4 (BrIII) – G3 (BrI)	NA	0.86	1.00	0.11
14 Days	Proportion chi-square test ($\alpha = 0.05$)				
		NA	NA	0.015	0.065
	Pairwise comparisons between proportions ($\alpha_{\text{bonf}} = 0.016$)				
	G3 (BrI) – G2 (TypeII)	NA	NA	0.28	1.00
	G4 (BrIII) – G2 (TypeII)	NA	NA	0.11	NA
	G4 (BrIII) – G3 (BrI)	NA	NA	NA	1.00
21 Days	Proportion chi-square test ($\alpha = 0.05$)				
		NA	1.000	0.168	1.000
	Pairwise comparisons between proportions ($\alpha_{\text{bonf}} = 0.016$)				
	G3 (BrI) – G2 (TypeII)	NA	NA	NA	NA
	G4 (BrIII) – G2 (TypeII)	NA	1.00	0.17	1.00
	G4 (BrIII) – G3 (BrI)	NA	NA	NA	NA

NA: Not available

ACCEPTED MANUSCRIPT

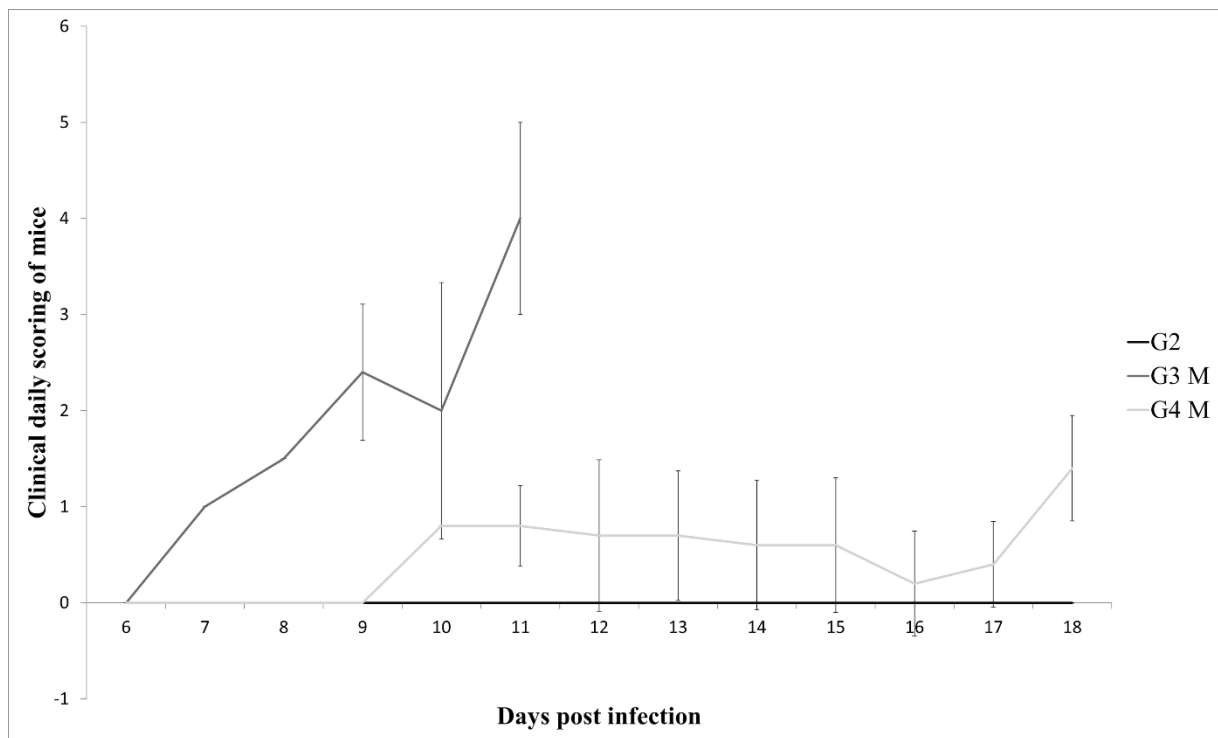
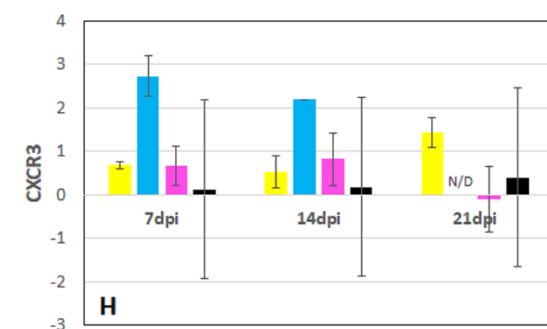
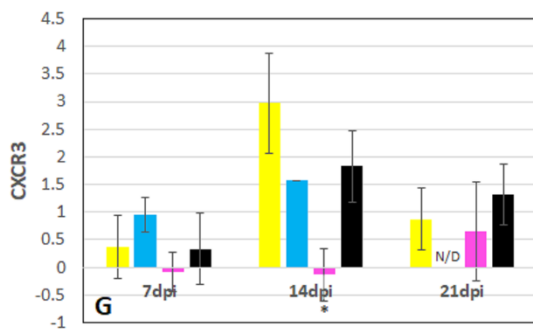
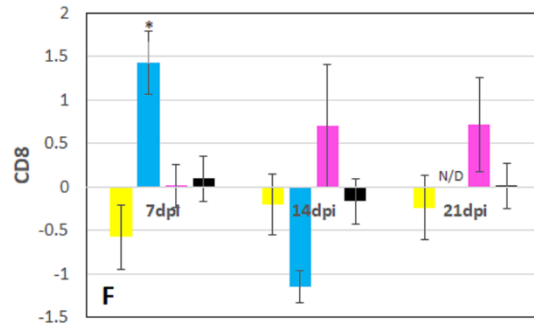
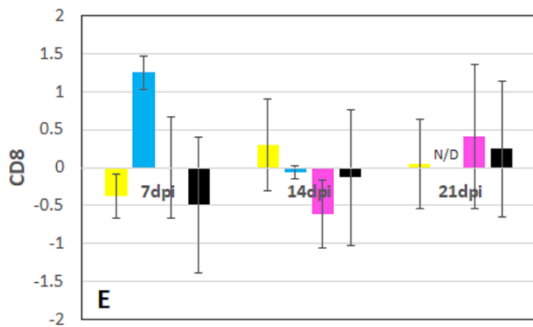
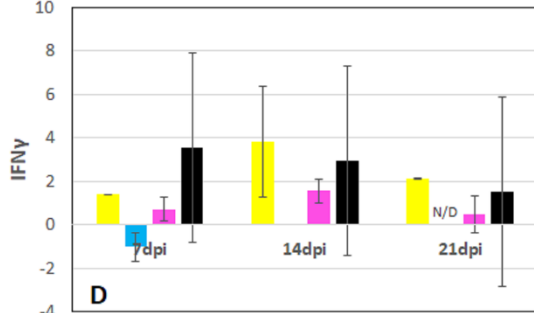
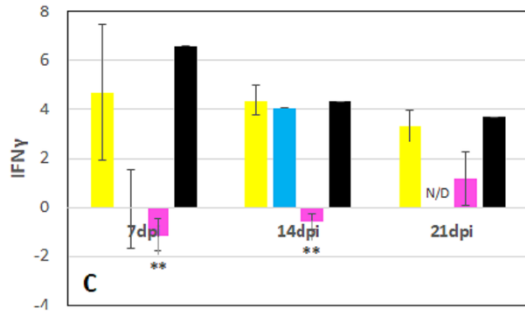
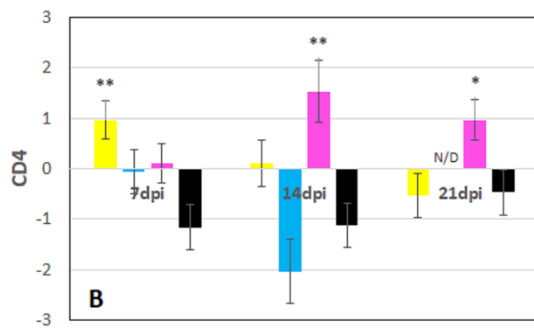
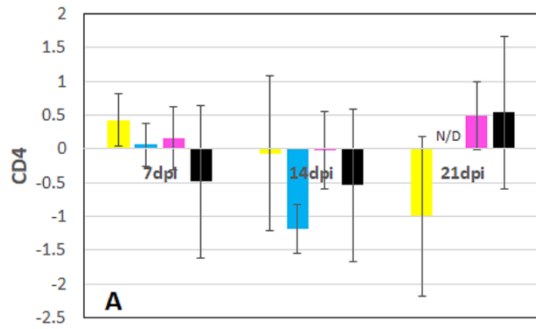


Figure 1. Variation of mean value of scoring (M) and standard deviation according to the clinical findings in mice experimentally infected with Type II, genotypes BrI and BrIII (G2, G3 and G4, respectively) of *Toxoplasma gondii*. Vertical axys stands for the sum of daily scoring in each mouse according to the following criteria: 1= ruffled coat or hunched back; 2 = ruffled coat and hunched back or reluctance to move; 3 = stary stiff coat and hunched back; 4 = stary stiff coat, hunched back, reluctance to move and dehydration

Accepted Manuscript

MESENTERIC LYMPH NODES

SPLEEN



- G2 Infected with Type II *T. gondii*
- G3 Infected with Genotype BrI *T. gondii*
- G4 Infected with Genotype BrIII *T. gondii*
- G1 Not infected control group

cont.

cont.

MESENTERIC LYMPH NODES

SPLEEN

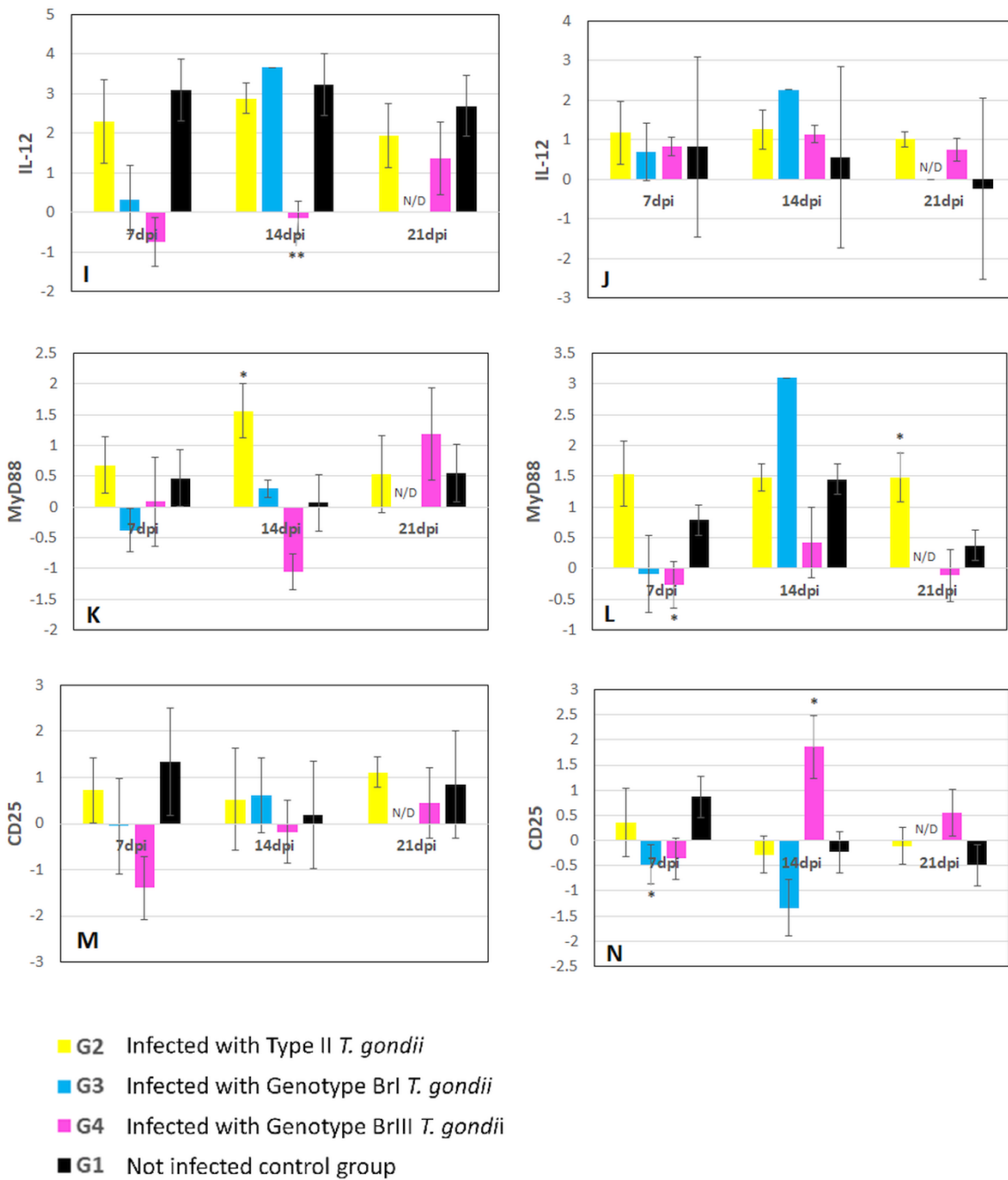


Figure 2. Mean levels and standard deviation of $\Delta\Delta C_t$ values for mRNA expression of immune response genes normalized against HPRT from samples of spleen and mesenteric lymph nodes (MLN) of mice at different timepoints (hours = h, and days post infection = dpi, not determined = N/D) after challenge with M4, BrI and BrIII oocysts (G2, G3 and G4, respectively) of *Toxoplasma gondii*. Results are compared with negative control (G1). *P*

value was determined using the one-way analysis of variance ($*P<0.05$, $**P<0.01$, $***P<0.001$). (A, B) CD4; (C, D) IFN γ ; (E, F) CD8; (G, H) CXCR3; (I, J) IL-12; (K, L) MyD88; (M, N) CD25

Accepted Manuscript

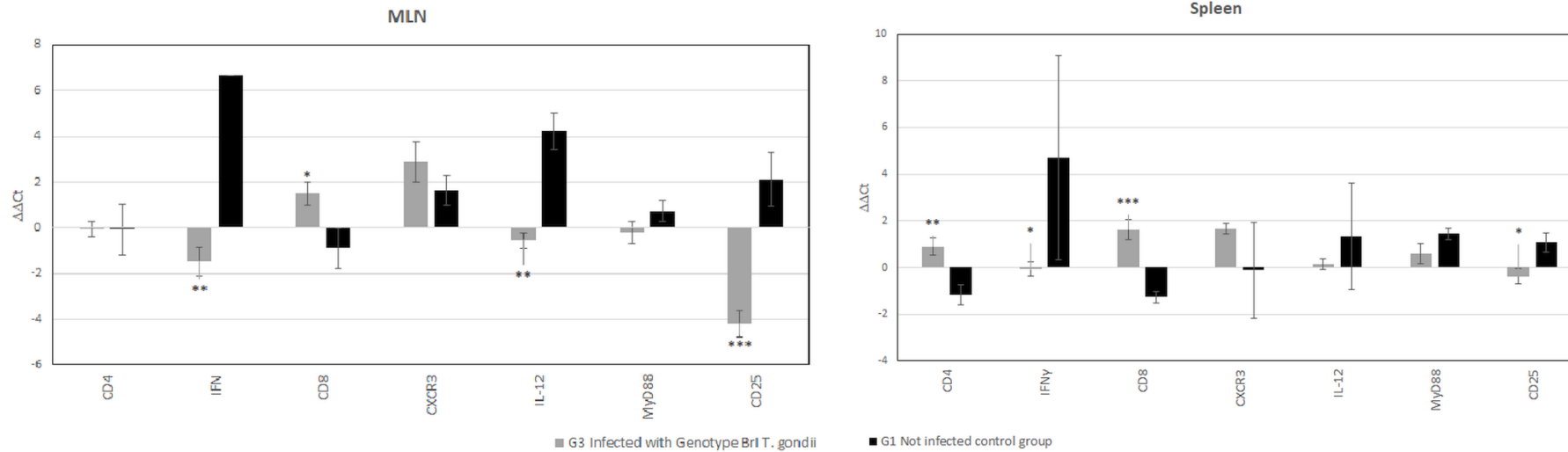


Figure 3. Mean levels and standard deviation of mRNA expression of CD4, IFN γ , CD8, CXCR3, IL-12, MyD88 and CD25 markers in the spleen and mesenteric lymph nodes (MLN) of mice euthanized due to severity of symptoms at 8-11 days post infection after challenge with BrI oocysts (G3) of *Toxoplasma gondii*. Results are compared with negative control (G1). *P* value was determined using the one-way analysis of variance (**P*<0.05, ***P*<0.01, ****P*<0.001)

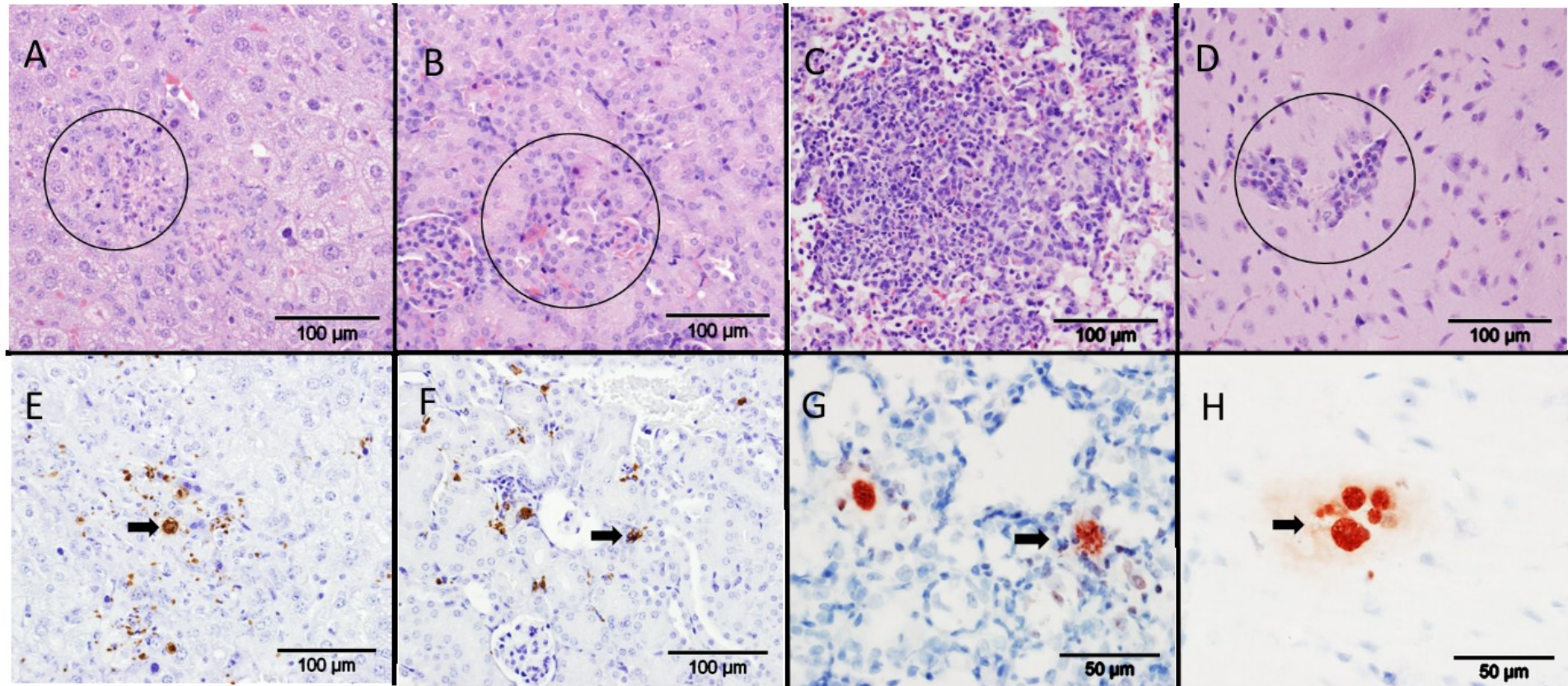


Figure 4. Lesions and parasite detection in haematoxylin and eosin (HE) staining and specific labeling by immunohistochemistry (IHC) from tissues of mice infected with different strains of *Toxoplasma gondii*. (A) and (E): Liver from a G3 (genotype BrI) mouse euthanized at 9dpi. Focus of necrotizing mononuclear hepatitis (A, circle, HE, bar 100 μ m), large number of immunolabeled tachyzoites and a moderately large cyst (arrow) within lesions (E, IHC, bar 100 μ m); (B) and (F): Kidney from a G3 mouse euthanized at 9 dpi, small mononuclear focus of nephritis (B, circle, HE, bar 100 μ m), and large number of immunolabeled *T. gondii* tachyzoites and cysts associated or not (arrow) with lesions (F, IHC, bar 100 μ m); (C) and (G): Lungs from mice from G4 (genotype BrIII) euthanized at 14dpi. Large focus of necrotising interstitial pneumonia with mild central necrosis (C, HE, bar 100 μ m),

immunolabelled *T. gondii* cysts (arrow) not associated with lesions (G, IHC, bar 50µm); (D) and (H) Brains from G4 mice euthanized at 14 dpi. Small mononuclear perivascular cuffs (D, circle, HE, bar 100 µm), immunolabelled *T. gondii* cysts and single tachyzoite not associated with lesions (H, IHC, bar 50 µm)

Accepted Manuscript