

University of Wollongong

Research Online

Faculty of Health and Behavioural Sciences -
Papers (Archive)

Faculty of Science, Medicine and Health

2009

Hermeneutics in Primary Care: Corneal Ulceration Treated with Bandage Contact Lenses / Alternate title: Case Report - Corneal Ulceration Treated with Bandage Contact Lenses

Tommy Cleary

University of Wollongong, tomcleary@live.com.au

Katherine Chan

Follow this and additional works at: <https://ro.uow.edu.au/hbspapers>

 Part of the [Arts and Humanities Commons](#), [Life Sciences Commons](#), [Medicine and Health Sciences Commons](#), and the [Social and Behavioral Sciences Commons](#)

Recommended Citation

Cleary, Tommy and Chan, Katherine: Hermeneutics in Primary Care: Corneal Ulceration Treated with Bandage Contact Lenses / Alternate title: Case Report - Corneal Ulceration Treated with Bandage Contact Lenses 2009.

<https://ro.uow.edu.au/hbspapers/122>

Research Online is the open access institutional repository for the University of Wollongong. For further information contact the UOW Library: research-pubs@uow.edu.au

Hermeneutics in Primary Care: Corneal Ulceration Treated with Bandage Contact Lenses / Alternate title: Case Report - Corneal Ulceration Treated with Bandage Contact Lenses

Abstract

Bandage contact lens use in primary care optometry can be important for allowing people to live without painful effects of corneal disease. This particular case study describes the initial healing of ulceration with a bandage contact lens inserted and also the long term issues of recurrence of ulceration with cessation of lens wear and management of microbial keratoconjunctivitis with bandage lens wear. In an attempt to address holistic themes this paper utilises a hermeneutical approach to clinical judgement in a primary care setting.

Disciplines

Arts and Humanities | Life Sciences | Medicine and Health Sciences | Social and Behavioral Sciences

Publication Details

This article was originally published as Cleary, T and Chan, K, Case Report - Corneal Ulceration Treated with Bandage Contact Lenses / Alternate title : Hermeneutics in Primary Care: Corneal Ulceration Treated with Bandage Contact Lenses, *Illuminate*, 9 December 2009, 23-28.

Title:

Hermeneutics in Primary Care: Corneal Ulceration Treated with Bandage Contact Lenses

Authors:

Tom Cleary
Katherine Chan

Abstract:

Bandage contact lens use in primary care optometry can be important for allowing people to live without painful effects of corneal disease. This particular case study describes the initial healing of ulceration with a bandage contact lens inserted and also the long term issues of recurrence of ulceration with cessation of lens wear and management of microbial keratoconjunctivitis with bandage lens wear. In an attempt to address holistic themes this paper utilises a hermeneutical approach to clinical judgement in a primary care setting.

Keywords:

Bandage Contact Lens, Primary Care Optometry, Corneal Ulceration, Fuchs Endothelial Dystrophy, Bullous Keratopathy, Hermeneutics, Clinical interpretation.

Purpose/Aim:

The purpose of this paper is to use a case study to illustrate the healing of corneal ulceration with the necessary aid of a bandage contact lens and discuss related clinical issues.

Introduction:

This paper will present a case of bandage contact lens fitting in a broad scope primary care optometry practice. There is an argument that the wider use of this type of bandage contact lens may eventuate in the future. Cataract surgery is the most common operation performed in Australia (AIHW, 2005). With an aging population even more cataracts surgery will be performed and more corneal de-compensation may occur due to deteriorating Fuchs endothelial dystrophy and the like. Although there are improving outcomes from specialised surgical techniques used to address chronic corneal disorders there are always certain people who do not want any more eye surgery, such as in this case. Bandage contact lenses are one way of addressing these people's hopes and expectations of reduced discomfort from recurring episodes of acute corneal disease without surgical intervention.

Fuchs endothelial dystrophy as described by Kanski (2007: p 300) is “a bilateral disease characterised by accelerated corneal endothelial cell loss. It is more common in women and is associated with a slightly increased prevalence of primary open-angle glaucoma.” Later stages of the dystrophy include “persistent epithelial edema resulting in the formation of microcysts and bullae which causes pain and discomfort on rupture due to the exposure of naked nerve endings (Kanski, 2007: p 300).”(See also figure 9.55 d and e at Kanski online) According to Andrew and Woodward (2007): “One of the most common indications for the fitting of therapeutic contact lenses is bullous keratopathy,” with their study showing that symptoms of bullous keratopathy were reduced in most cases of bandage contact lens use.

What this case study will seek to demonstrate is that given the appropriate long term primary care support the rehabilitation of the corneal surface with a bandage contact lens is possible even in a severe case of recurrent ulceration. Although this particular case falls well outside the usual practice of contact lens fitting it follows that broad scope primary care optometry often requires an appreciation of interpretive subjectivity and the wishes of the patient.

Case Report Bandage Lens Use in Primary Care Optometry

Part One: Initial Healing of Traumatized Cornea

History

An 80 year old lady, Lucia Santo, was referred by a local ophthalmologist to OPSM Wollongong for fitting of a bandage contact lens to help with recurrent corneal erosions on a background of bullous keratopathy in her right eye. Lucia reported that her right eye was not painful but only irritating. At this stage it was difficult to gain an adequate history from Lucia for though she reported only irritation her stoic character meant that the disabling nature of the condition was under reported.

Clinical Findings

Uncorrected VA: RE: <6/120 LE: 6/30

RE ptosis was noted and general facial asymmetry.

There were persistent and periodic episodes of blepharospasm of the RE, with Facial Hemispasm suspected (see Figure 21.60 of Kanski online).

Unable to measure IOP

Slit lamp exam: difficult to examine eye due to photophobia

Large full thickness corneal epithelial ulcerative erosion noted RE with thinning of underlying stroma (see Figure 1.0 and 1.3 below).

Anterior eye: IOL OU, anterior chamber quiet OU.

Auto refractor: RE no reading, distorted mires, LE +1.50/-1.50x74

Auto Keratometer: RE [8.10@10](#) , [8.49@100](#) , corneal astigmatism -2.00x100
LE 8.05@168, 8.34@78, corneal astigmatism -1.50x78

Posterior eye: not clearly visible in both eyes due to bilateral Fuchs corneal dystrophy resulting in bilateral corneal edema (and ulceration and blepharospasm of the right eye) obscuring fundus.

Initial Management

Extended wear lens was inserted and appointment arranged for review the following morning. Lucia also began to use the Tobrex, Maxidex and Homatropine drops three times daily as prescribed that day by the referring ophthalmologist.

B&L Purevision BC 8.6, DM 14.0 PWR -2.25 fit well with a slight bubble overlying the area of ulceration noted initially which confirmed the depth of the ulceration (See figure 1.0). The bubble under the contact lens resolved spontaneously after about 10 minutes.

Over the next 5 months of careful follow-up with monthly replacement of the bandage contact lens the corneal lesion was observed healing slowly. Corneal photography was performed regularly with the practice's Non Mydriatic Retinal camera in anterior eye mode. Use of the retinal camera in this way was instrumental in the ability to maintain effective primary care attention in a practice with several optometrists.

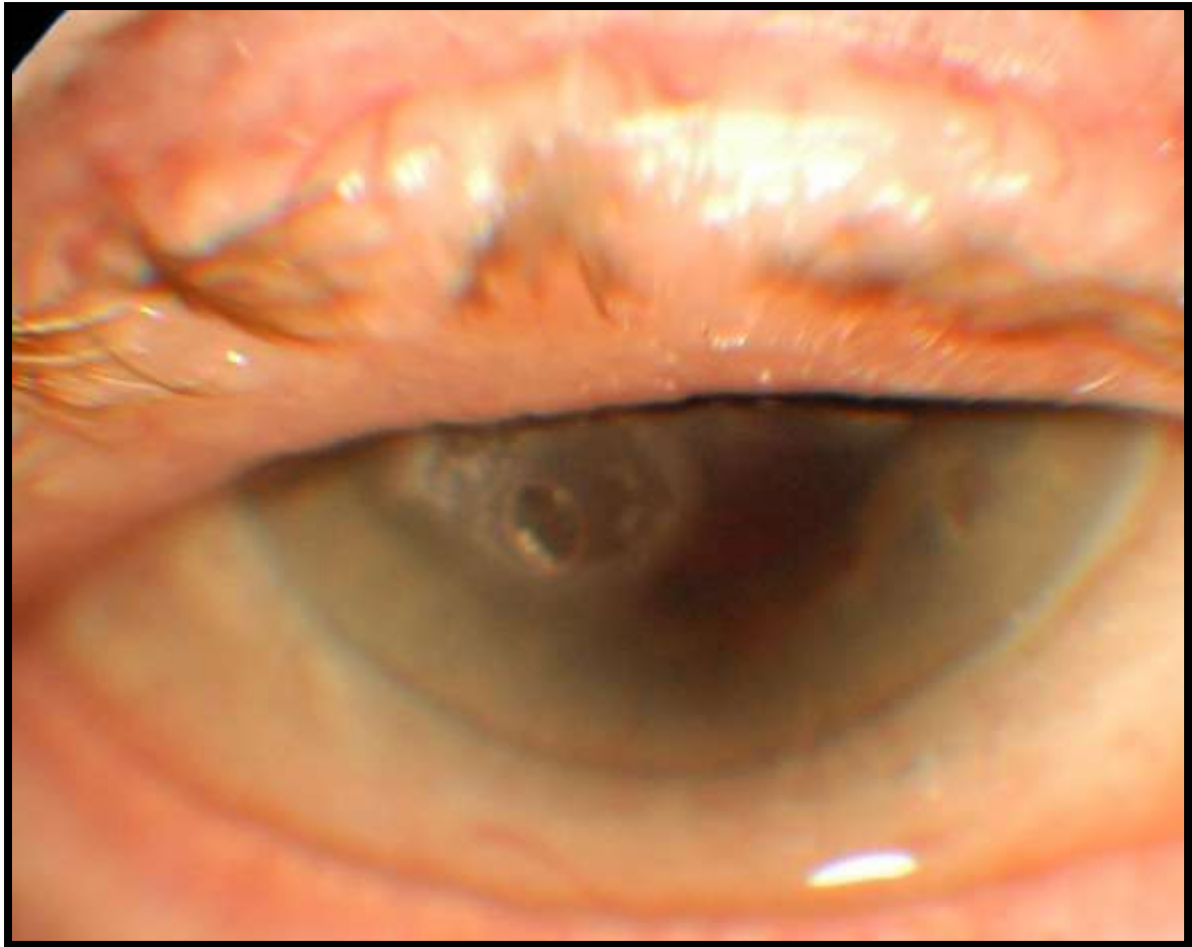
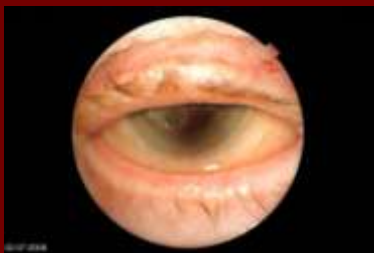
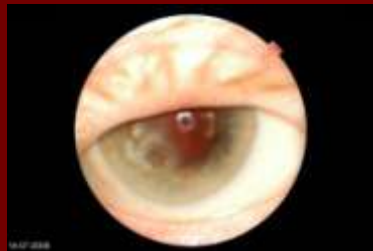Figure 1.0: Immediately after contact lens insertion there was a bubble under the contact lens overlying the area of ulceration.

Bandage Contact: on third follow up visit 2 weeks later lid position and symptoms have improved.

Before



After



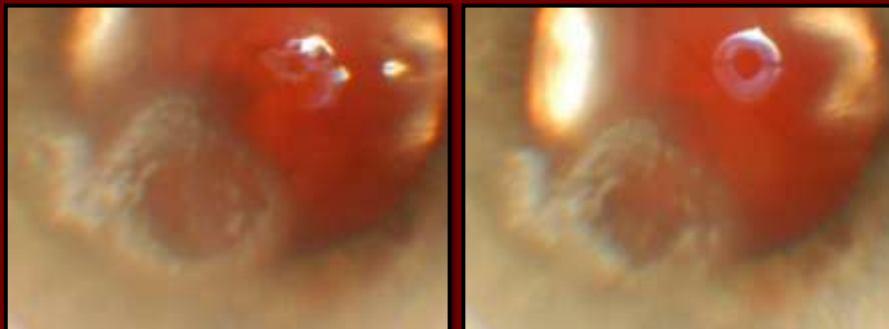
note ptosis reduction and decreased injection

Above Figure 1.1

Is it better? Maybe a little.
Well its not getting worse!

Before

After



Courtesy OPSM Wollongong

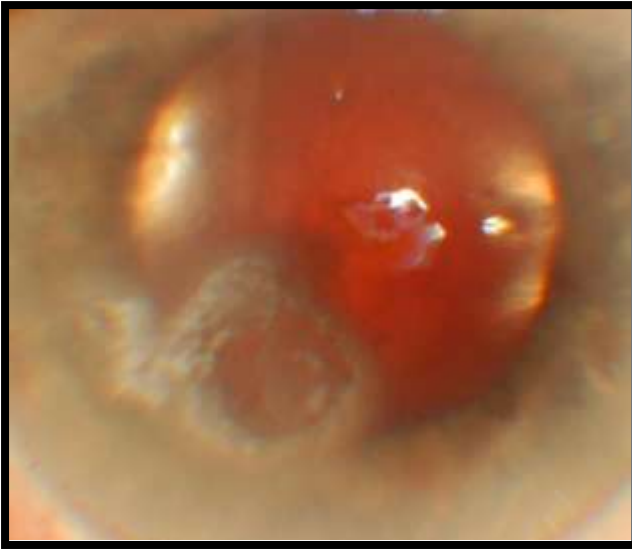
11

Figure 1.2:

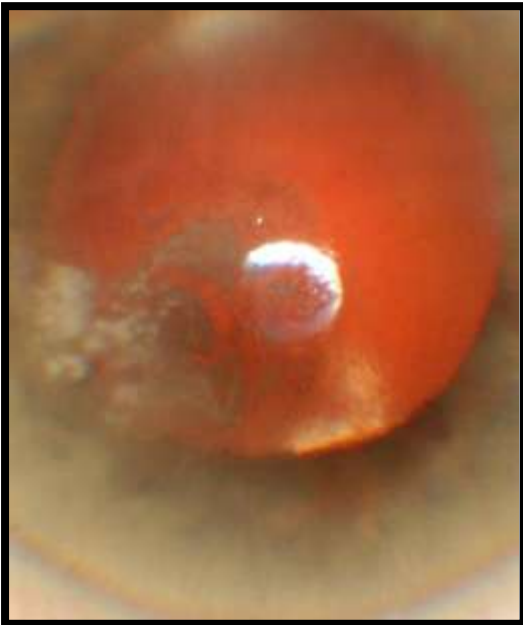
Above Left, Before: initial area of ulceration quite large

Above Right, After: two weeks later, maybe a little better

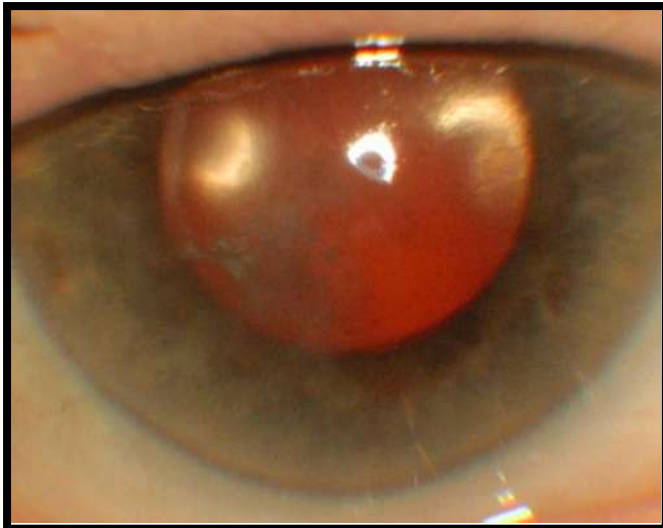
Ulcer healing over initial 5 weeks of bandage lens use (Figure 1.3-1.5):



Above Figure 1.3: initial ulceration without contact lens



Above Figure 1.4: after 20days of lens wear, contact in situ.



Above Figure 1.5: after 37 days of lens wear, contact in situ.

Part Two: Establishing Long Term use of Bandage Contact Lens

Ehrlich (2001) explains that for extended wear therapeutic contact lens fitting: “The original two silicone hydrogel lenses: Purevision from Bausch & Lomb, and Night and Day from CIBA Vision, offer theoretical advantages over traditional hydrogel lenses with an oxygen transmissibility which is less likely to impede wound healing and epithelial cell reproduction, and is theoretically more suitable for overnight wear (Lim et al., 2001). They also have a low water content so this theoretically reduces the dependence of the lens on tear quality and quantity. The disadvantages include the increased rigidity (modulus of elasticity) poor surface wettability, and limited parameters. Epidemiological studies have not shown a significant difference in reduction in microbial keratitis with these lenses in a normal population.”

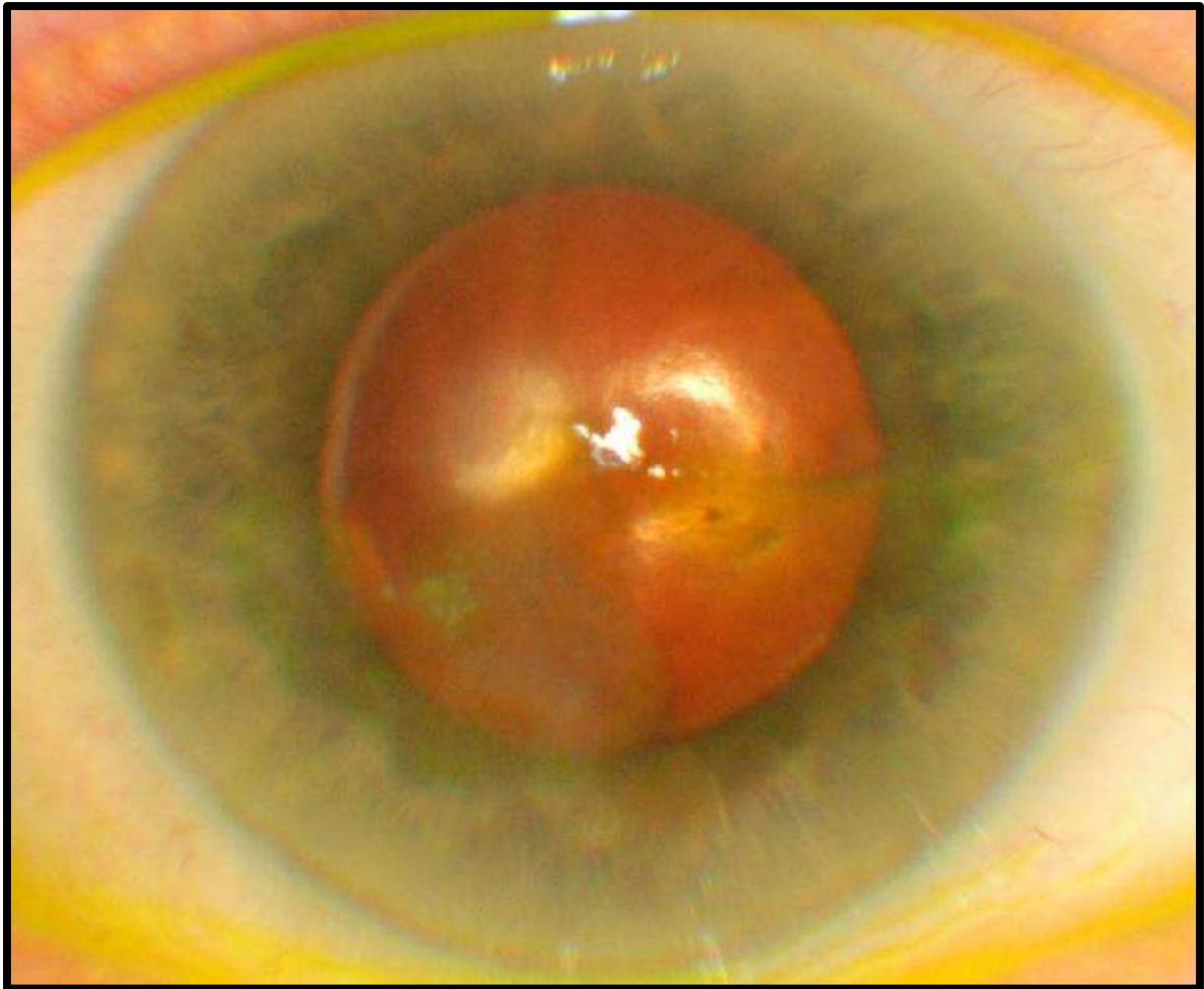
In the same paper Ehrlich describes a number of mechanisms of therapeutic benefit of bandage contact lenses:

“Protection of the corneal surface from shearing forces of the eyelid during normal blinking,
The retention of a stable ocular tear film,

The creation of a barrier between the tears and the cornea, reducing neutrophil infiltrate from the tears,

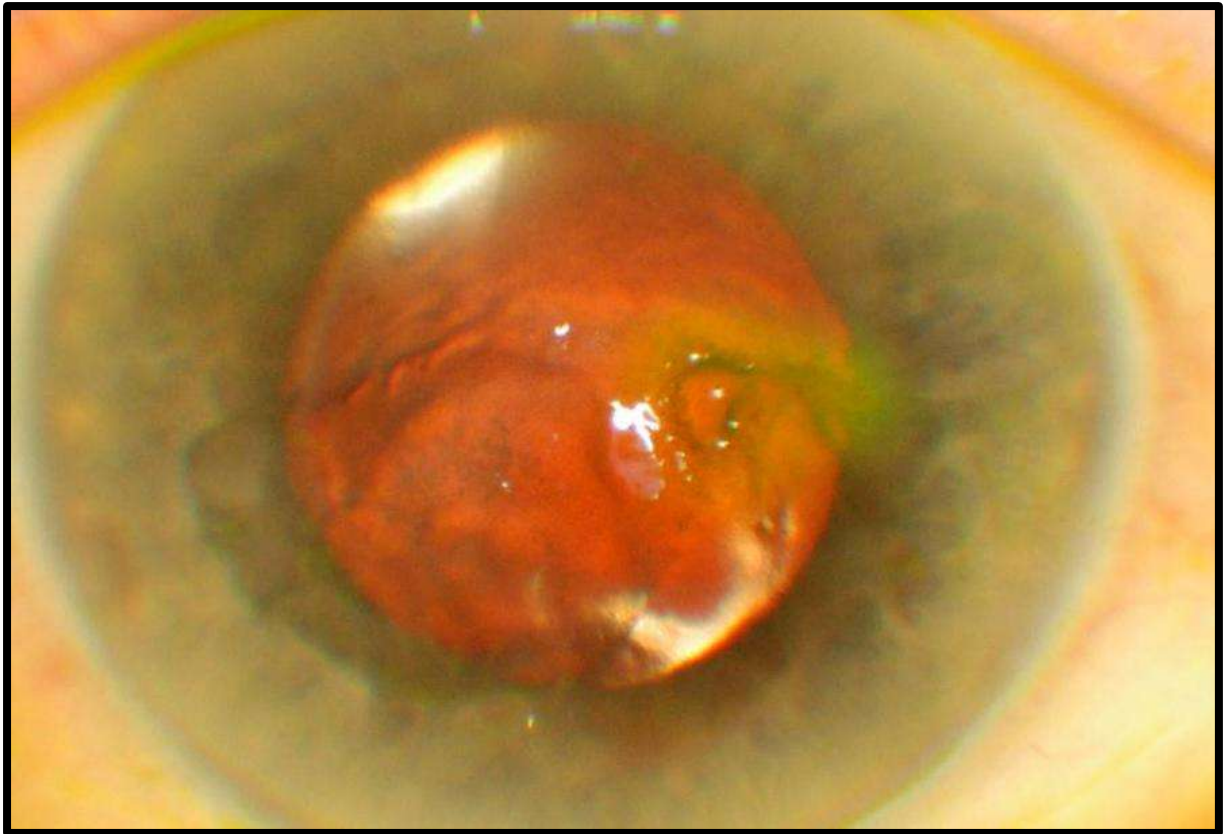
The retention of a fibrin matrix on an injured corneal surface. It is believed that this can form a scaffold to assist epithelial cell growth over a corneal ulcer.(Leibowitz and Rosenthal, 1971)”

After five months of monthly replacement extended wear bandage lens use the initial ulceration had healed quite well and the symptoms of pain and photophobia had reduced. There was still significant edema of the cornea but only mild staining of the epithelial surface (see Figure 2.0 below). It was decided to see how Lucia would fair without the contact lens (at this stage she was still using Maxidex, Tobrex and Isopto Homatropine 3 times daily).



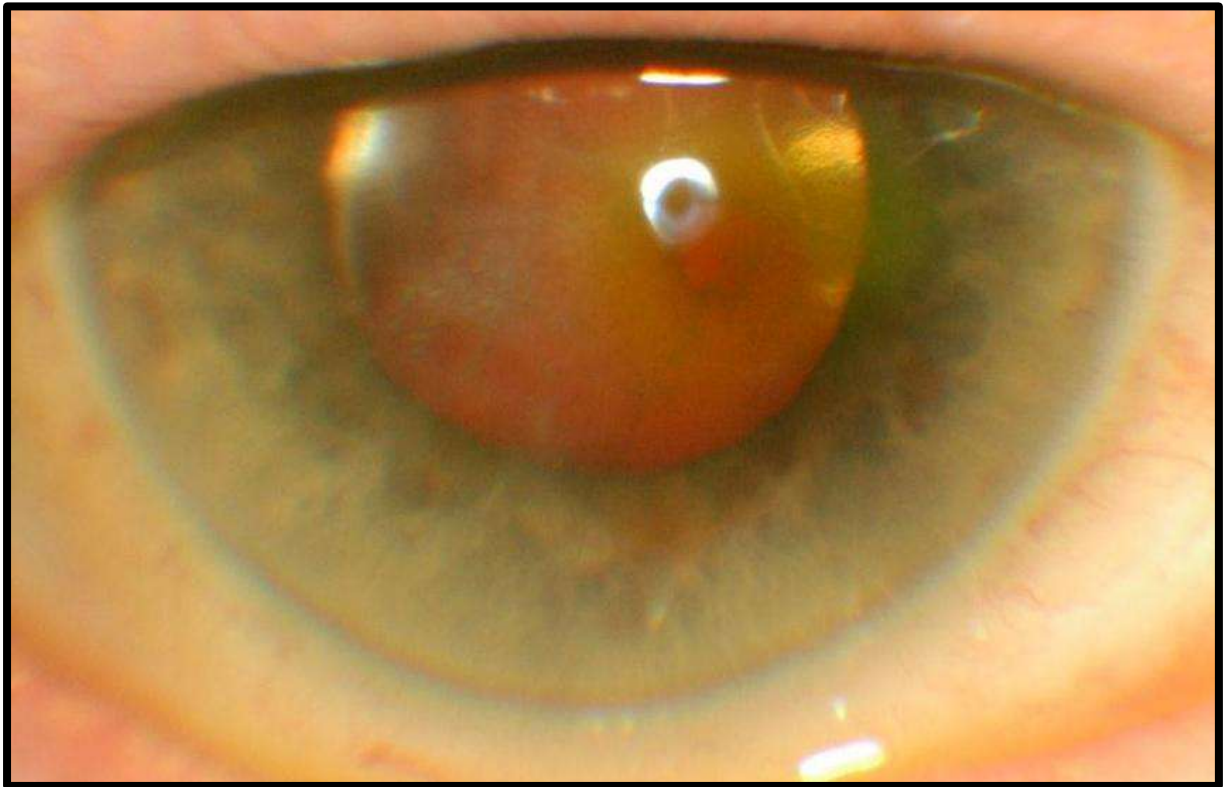
Above Figure 2.0: Cornea with Fluorescein staining showing relatively stable corneal epithelium immediately after removal of contact lens on 17th November

Unfortunately the shearing forces produced by Lucia's chronic spontaneous blepharospasm and the instability of the corneal epithelium from underlying edema meant that Lucia re-presented two days later on the 19th November with a painful, photophobic eye and foreign body sensation (see Figure 2.1 below).



Above Figure 2.1: After two days without bandage lens the corneal epithelium had sloughed off and begun a new area of erosion.

This instability of the corneal epithelium immediately improved and a reduction in symptoms (no foreign body sensation reported) upon insertion of a new bandage contact lens (see Figure 2.2 below).



Above Figure 2.2: corneal epithelial structure improved on contact lens insertion.

This episode of recurrent corneal epithelial erosion when bandage contact lens wear was discontinued temporarily confirmed that Lucia was indeed benefiting from the support provided by the bandage contact lens. She reported that she was happy with the level of vision and comfort of the eye with the bandage lens inserted. Essentially her Bullous Keratopathy was disrupting vision but with the bandage contact lens inserted Lucia was otherwise asymptomatic enough that she remained confident that she did not need a penetrating keratoplasty.

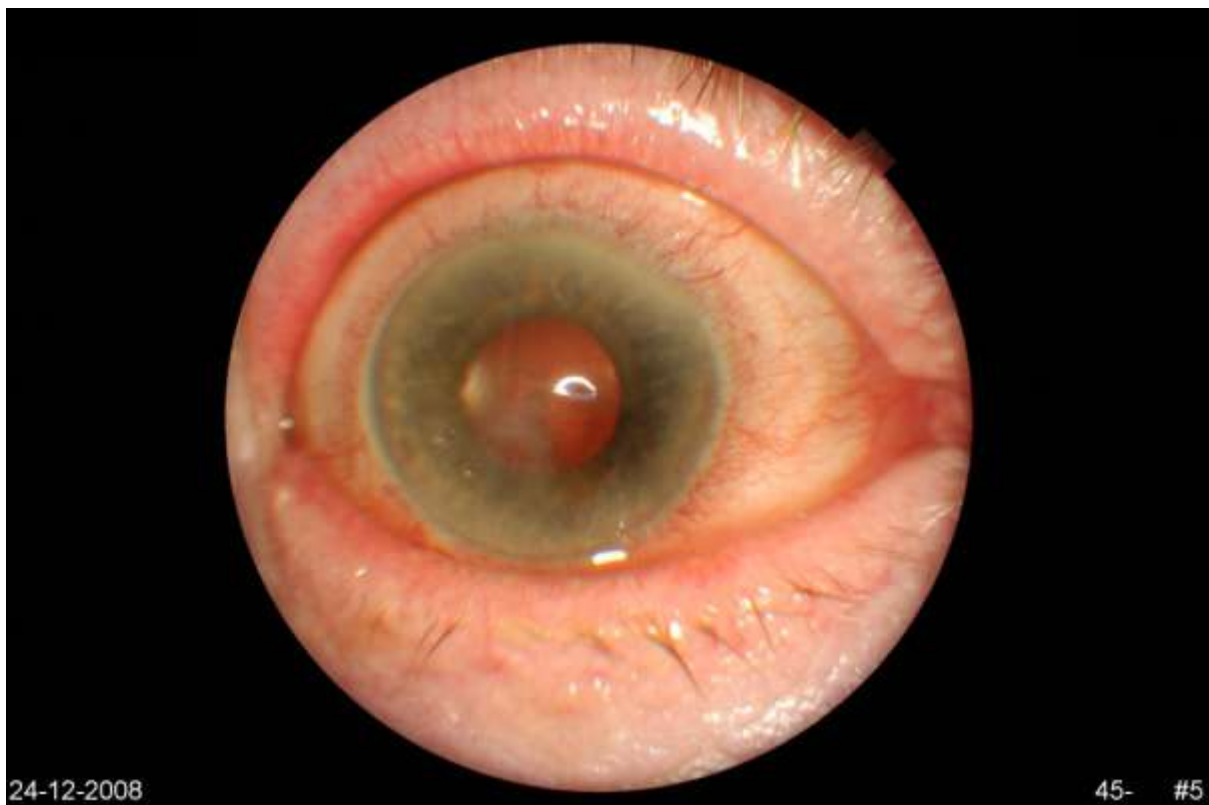
Part Three: Long term Bandage lens care and expecting the unexpected

Bandage contact lens use had now been established in Lucia's case as a long term option for healing of the initial lesion as well as preventing the formation of additional ulcerations. Despite the relative corneal stability with the bandage lens aiding rehabilitation of Lucia's eye there is the ever present danger of bacterial keratoconjunctivitis. As Ehrlich (2001) notes "This contact lens wearing group has a high reported risk of microbial keratitis of 52/10,000 per year (Liesegang, 1997)". Despite this Gunnar Hovding had earlier concluded in a study of conjunctival and contact lens bacterial flora found during continuous bandage lens wear that bandage contact lens fitting may not "in itself necessitate the use of topical antibiotics"(1982).

Lucia still had poor vision though she did claim it had improved and now visual acuity was testable to OD 6/60 (which improved from <6/120 initially), OS 6/24.

In consultation with the referring ophthalmologist, it was decided to cease the prophylactic use of Tobrex and continue with bandage contact lens and the other drops (with Maxidex and Homatropine used when needed for comfort). There was continuing stable use of the bandage contact lens over the next couple of months and Lucia was advised to pay special attention to any episodes of red eye or ocular discomfort. She had regained some corneal sensation since bandage lens use had begun and although still quite stoic it was hoped she would report any episodes of corneal discomfort.

On Christmas Eve 2008 she presented with a red, watery and slightly uncomfortable right eye (see Figure 3.0 below). The contact lens was replaced and Tobrex use re-instated three times daily. If the eye did not improve Lucia was advised to go to Sydney Eye Hospital as local ophthalmology services were not be available over the Christmas break.

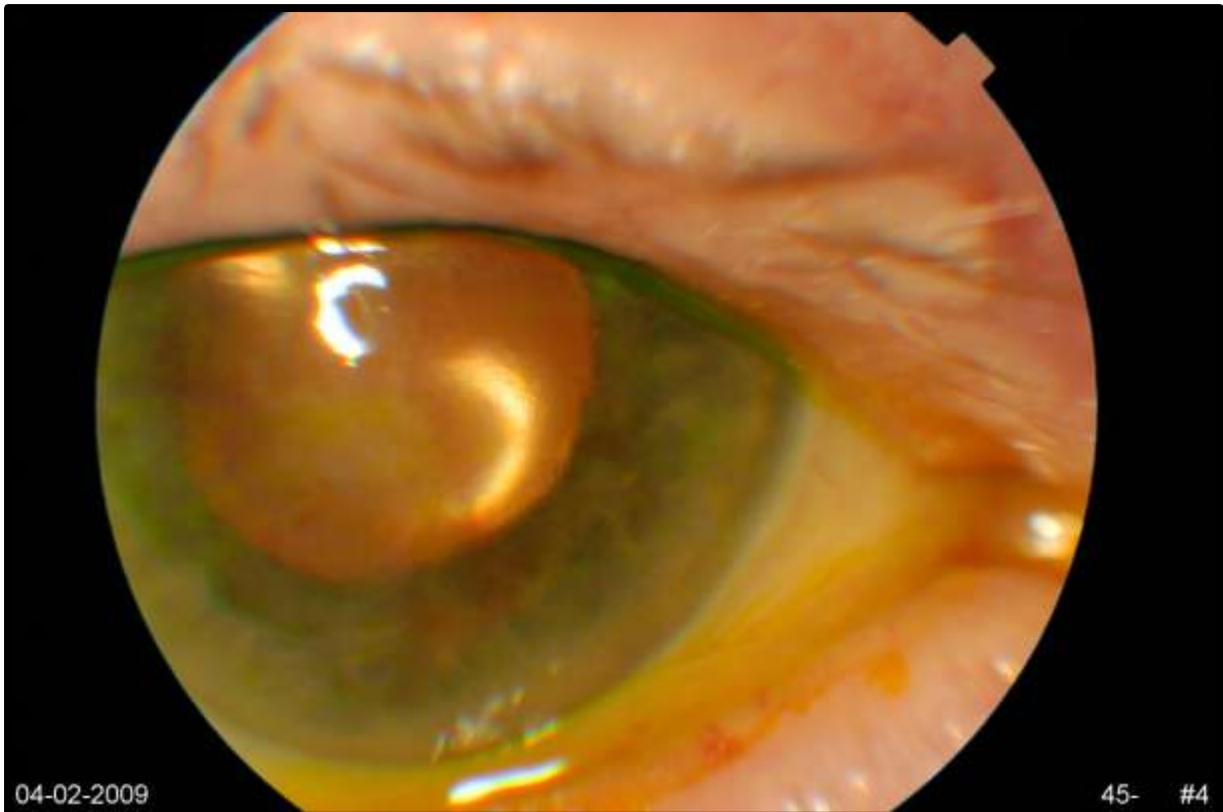


Above Figure 3.0: the eye became infected without the prophylactic use of tobrex antibiotic eye drops (photo taken with new contact lens recently inserted, note air bubbles under the lens).

Fortunately the episode of presumed bacterial keratoconjunctivitis resolved without further incident with the use of Tobrex antibiotic eye drops 3 times daily and at review on the 27th December there were no signs of bacterial infection or ocular inflammation. Lucia insisted that although the eye was red and a little watery during this episode it was not painful or photophobic and cleared up quickly with the aid of the antibiotics.

Conclusion

The ongoing primary care optometry management of Lucia's bandage contact lens wear has been challenging (see figure 4.0 below). She has a background of recurring ulceration since her cataract surgery due to corneal de-compensation and is still quite resistant to further surgery, such as a corneal transplant. Despite the difficulties of long term bandage contact use she is more motivated than ever to continue in this supported extended wear lens modality.



Above Figure 4.0 February 2009 photo without contact lens, eye stained with fluorescein.

Long-term bandage contact lens wear is complicated by essential blepharospasm and by the chronic edema of the cornea which makes the epithelial surface very fragile. For this and many other unresolved reasons (such as difficulty in contact lens handling because of Lucia's low vision and poor dexterity) the monthly contact lens insertion and removal has been performed by an optometrist over the last year.

There are many different and equally valid approaches to primary care theory and practice. Drew Leder's (1990) exploration of clinical interpretation describes how the wide variety of textual forms encountered in health care needs to be recognised when attempting to discern their meaning. He focuses on four areas; the illness as lived out by the patient, the narrative constituted in the history-taking, the patient's body as objectively examined and the finally the instrumental text constructed by diagnostic technologies (the instrumental text as

exemplified by the photographic series in this paper). This hermeneutical approach actively avoids the assumption that clinical practice is based on a purified science. According to Leder this is because if interpretive subjectivity is not recognised and utilised then the primary subject, “the living breathing patient”, can be too easily excluded from clinical practice and judgement.

In this case study we have seen how both the experience of disease and the framing of meaning in Lucia’s story about her past experience are very particular and create much of the distinct significance of her clinical presentation. In a way understanding Lucia is crucial to understanding why, for example, encountering and overcoming an episode of presumed microbial keratoconjunctivitis can be interpreted as a positive step towards long term primary care management of her eye disease with bandage contact lenses. In most other situations this type of episode could result in the cessation of contact lens wear.

The process that led to this assessment was not simply the result of forming a hypothesis and testing with experimentation but also reflecting and meditating on both the pragmatic and transient meaning in the texts Leder describes. This hermeneutical way of addressing ideas that are not immediately situated in the world is, according to Hans-Georg Gadamer’s *Truth and Method*, dependent on the “meditating spirit that we, like the Greeks, name after Hermes: the messenger of the gods.”(Gadamer, 1989: p 157) So hermeneutics in many ways it is a lot simpler than it sounds, we often use this way of thinking during our everyday experiences without realising.

Surprisingly not many authors are willing or able to write with a partisan approach in favour of the non expert, let alone the person experiencing a disease. Lucia’s stoic nature and patient wisdom reminds me of Jaroslav Hasek’s character Svejek from the first modern anti war novel who among other medical adventures comments on doctors that declare him fit for war despite being unable to walk because of his rheumatism:

“‘I think that we should be fair about everything,’ said Svejek. ‘After all, anybody can and must make a mistake, the more he thinks about a thing. Medical experts are human beings and human beings have their faults.’(Hasek, 1974: p 27)”

As Gadamer (1996) explains health is a very contestable and elusive state of being precisely because when you are healthy you become preoccupied with other things. It is disease that lends itself to objectivity, health on the other hand is too close to our subjective being to be easily characterised as other. In being involved with Lucia’s primary care experience over the last year I have learnt once again that ocular health can be very relative. I am happy that even with what little we can do at this stage she still regularly reports that her eye has been “no trouble at all, and I think I can see better now than before.”

Bibliography

- AIHW (2005) Vision problems among older Australians. *Bulletin no. 27. AIHW cat. No.AUS 60.Canberra: AIHW*
- ANDREW, N. C. & WOODWARD, E. G. (2007) The bandage lens in bullous keratopathy. *Ophthalmic and Physiological Optics*, 9, 66-68.
- EHRlich, D. P. (2001) Therapeutic contact lenses. *Optician*, July, 23.
- GADAMER, H.-G. (1989) *Truth and Method*, New York, Crossroad.
- GADAMER, H.-G. (1996) *The Enigma of Health: The Art of Healing in a Scientific Age*, Stanford, California, Stanford University Press.
- HASEK, J. (1974) *The Good Soldier Svejk and His Fortunes in the World War*, Harmondsworth, William Heinerman in association with Penguin Books.
- HOVDING, G. (1982) Conjunctival and contact lens Bacterial Flora During Continuous "Bandage" Lens Wear. *Acta Ophthalmologica*, 60, 439-448.
- KANSKI, J. J. (2007) *Clinical Ophthalmology*, London, Elsevier Butterworth-Heinemann.
- LEDER, D. (1990) Clinical Interpretation: The Hermeneutics of Medicine. *Theoretical Medicine*, 11, 9-24.
- LEIBOWITZ, H. M. & ROSENTHAL, P. R. (1971) Hydrophilic contact lenses in corneal disease. Superficial sterile indolent ulcers. *Arch Ophthalmology*, 85, 163-5.
- LIESEGANG, T. (1997) Contact lens-related microbial keratitis: Part I: Epidemiology. *Cornea*, 16, 125-31.
- LIM, L., TAN, D. T. & W.K.CHAN (2001) Therapeutic use of Bausch & Lomb PureVision contact lenses. *CLAO J*, 27, 179-85.