

A DISSECTION'S GUIDE TO HUMAN ABDOMINAL CAVITY

Marco Scaglione ^{1*}, Carla Zannelli ^{1*}, Riccardo Antonini ¹, Vincenzo Canalella ¹, Arianna Melita ¹, William Rà ¹, Simona Rusignuolo ¹, Arianna Sferruzza ¹, Carola Gagliardo ², Adele Guarrera ¹, Chiara Lo Piccolo ³, Margherita Mazzola ⁴, Dario Saguto ⁴, Francesco Carini ^{4^}, Giovanni Tomasello ^{4^}

1. School of Medicine, University of Palermo, Palermo, Italy

2. Department of Surgical, Oncological and Stomatological Sciences, University of Palermo, Italy

3. European Oncologic Institute, Division of Head and Neck Surgery, Milano, Italy

4. Institute of Human Anatomy and Histology, Department of Biomedicine, Neurosciences and Advanced Diagnostics, University of Palermo, Palermo, Italy

* ^ These authors contributed equally to the present work

ARTICLE INFO

Article history:

Received 28 February 2020

Revised 23 March 2020

Accepted 06 April 2020

Keywords:

Human anatomy, dissection guide, abdominal cavity, dissection course.

ABSTRACT

The purpose of this article is to show the abdominal cavity's dissection method. In the summer of 2018 a group of students from the University of Palermo, who had already taken the anatomy exam and had a good knowledge of English, went for a period of two weeks to do a dissection course at the University of Malta. The students dissected skin, subcutaneously, muscle layers, parietal peritoneum and abdominal organs. This work proves to be a small dissection guide for young medical students who want to learn the main bases of dissection and important information for topographical anatomy.

© EuroMediterranean Biomedical Journal 2020

1. Introduction

Thanks to an agreement between the University of Malta and the University of Palermo a group of students of medicine of University of Palermo was able to go to Malta to carry out a dissection course. The selected students have been selected in relation to the good quality of their university career and their good knowledge of the English language. The course was held in the sector room of the University of Malta, where dissections were carried out with careful separation of anatomical structures and of tutors from both the universities (1, 2).

The aim of this work is to describe the abdominal cavity and its topographical anatomy.

The abdominal cavity has a hexagonal shape and in the clinical scope it is divided into nine parts (Figure 1 and 2) through two vertical lines called "hemiclavicular line" that start from the midpoint of the clavicle and end up to the pubic symphysis, a horizontal subcostal line and a horizontal transtubercular line.

Each of this part contains specific organs (3-7):

- Liver, Gallbladder and Hepatic Flexure.
- Stomach, Transverse Colon, Pancreas. Duodenum and the final part of the left Liver's lobe.
- Spleen and Splenic Flexure.
- Right Colon and Right Kidney.
- Small Intestine
- Left Colon and Left Kidney
- Appendix, Cecum, Ureters and Right Ovary.
- Bladder, Rectum Colon, Uterus.
- Sigmoid Colon and Left Ovary.

* Corresponding author: Francesco Carini, francesco.carini@unipa.it

DOI: 10.3269/1970-5492.2020.15.8

All rights reserved. ISSN: 2279-7165 - Available on-line at www.embj.org

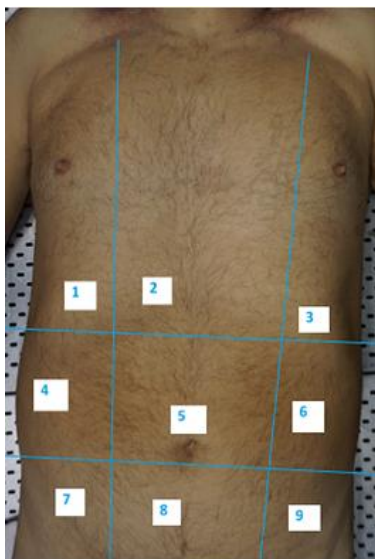

Figure 1. Abdominal quadrants on the abdominal wall. 1) Right hypochondrium; 2) Epigastrium; 3) Left hypochondrium; 4) Right side; 5) Mesogastrium; 6) Left side; 7) Right iliac fossa; 8) Hypogastrium; 9) Left iliac fossa

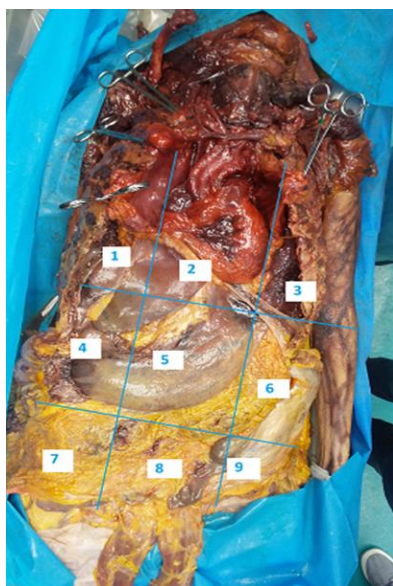


Figure 2. Abdominal quadrants after abdominal wall remotion. For numbers, see Figure 1.

2. Material and methods

Two corpses were used for the dissection, both of which died of natural causes. Specifically, the bodies belonged to an 80-year-old man and a 75-year-old woman. Surgical instruments such as scalpel (handle size 4), blade (size 22), Mayo scissors, anatomical and surgical forceps, and shears for ribs have also been used.

During the dissection, the operators wore surgical uniforms (scrubs), latex gloves, surgical mask and protective glasses.

The cadavers were placed, on the dissecting anatomic table and dissection of the abdominal cavity started by a xifo-umbilical-pubic incision.

3. Results

The After practicing a xifo-umbilical-pubic incision, from the most superficial layer to the innermost, you will find:

- Skin
- Subcutaneous tissue made of two parts: Camper's fat band and, under it, Scarpa's fibrous band.
- Muscles. Specifically, there are four couples of muscles that cover abdominal organs:
 - Rectus abdominis muscles
 - External oblique muscles
 - Internal oblique muscles
 - Trasversal muscles

All together these muscles create a barrier to protect the organs (Figure 3).

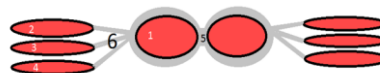


Figure 3. Schematisation of the linkage between abdominal muscles above the arched. 1) Rectus abdominis muscles; 2) External oblique muscles; 3) Internal oblique muscles; 4) Trasversal muscles; 5) White Line (also called Linea Alba); 6) Aponeurosis of each muscle.

It is important to underline that this layout is valid for the regions above the arched line, because under it the aponeurosis of muscles 2, 3 and 4 join all together and pass in front of muscle 1 (Figure 4). When you dissect the Parietal Peritoneum, you will find abdominal organs (Figure 5).

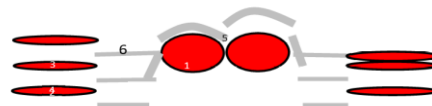


Figure 4. Schematisation of the linkage between abdominal muscles under the arched line. For numbers, see Figure 3.

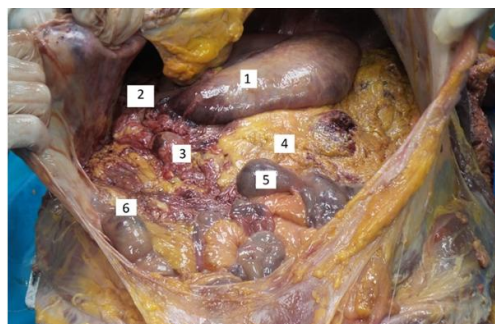


Figure 5. View of abdominal organs and greater omentum. 1) Stomach; 2) Liver; 3) Duodenum; 4) Greater Omentum (also called Gastrocolic Omentum); 5) Small Intestine's loops

The first thing that you notice is that some organs, like Liver and Stomach, are immediately visible as soon as you open the Parietal Peritoneum, whereas the others are mostly covered by the Greater Omentum. This structure is a large apron-like fold of visceral peritoneum that hangs down from the stomach. It starts from the greater curvature, covers small intestine and doubles back to ascend to the transverse colon. The linkage between the greater omentum and the transverse colon can be seen when you lift and overturn the greater omentum to see the transverse colon and mesocolon (Figure 6).

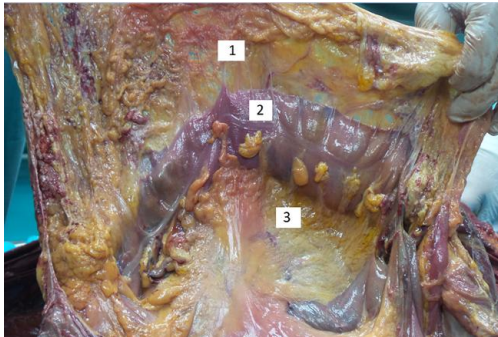


Figure 6. Linkage between greater omentum, transverse colon and transverse mesocolon. 1) Greater Omentum; 2) Transverse Colon; 3) Transverse Mesocolon (a broad, meso-fold of visceral peritoneum which links the Transverse Colon to the posterior abdominal wall).

Good This structure divides the peritoneal cavity into two parts:

- Upper mesocolic region, that contains Liver, Stomach and Spleen
- Lower mesocolic region, that contains small intestine's loops

In the transverse mesocolon there is an important vascular arcade called Arc of Riolan (also called Haller's anastomosis), which has the aim to connect the proximal middle colic artery with a branch of the left colic artery (Figure 7).

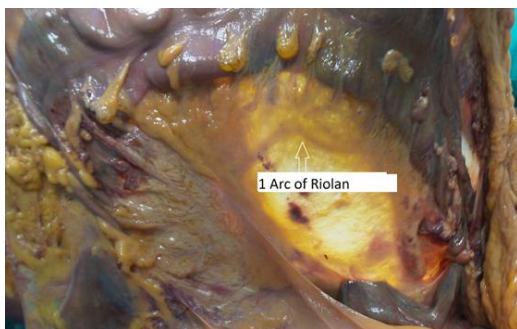

Figure 7. Focus on transverse mesocolon, Haller's anastomosis and Arc of Riolan

If we look at the upper mesocolic region (Figure 8), we immediately see the liver and its important ligaments.

We also see the gallbladder (Figure 9), a small important organ which lies beneath the liver and is responsible for concentrating and store the bile produced by the liver.

With the opening of the Oddi's sphincter, the bile will be released in the duodenum.

1. Gallbladder
2. Quadrate Lobe

3. Caudate Lobe
4. Right Lobe
5. Left lobe

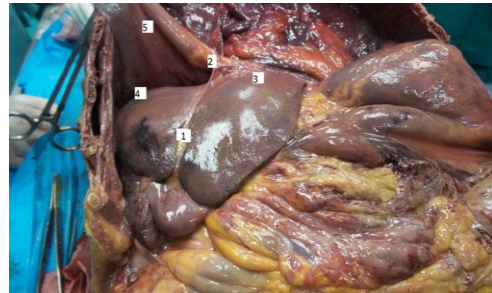


Figure 8. View of upper mesocolic region. 1) Round ligament which starts from the free edge of falciform ligament and represents the remnant of the fetal umbilical vein. This structure divides the left part of the liver into medial and lateral sections; 2) Falciform ligament is a reflection of the parietal peritoneum which seems to dive from the diaphragm into the liver; 3) Liver's left lobe; 4) Liver's right lobe; 5) Diaphragm.

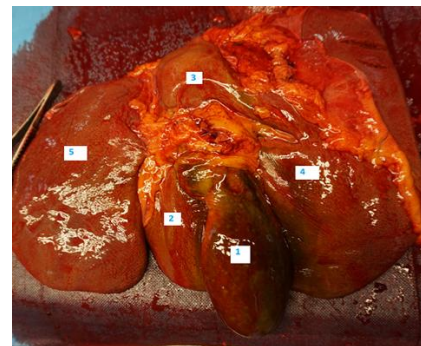


Figure 9. View of hepatic bed and hepatic lobes. For numbers, see Figure 8.

While, looking at the lower mesocolic region (Figure 10), we see small intestine's loops which are covered by Mesentery. The mesentery is a structure, formed by the double fold of peritoneum, which connects small intestine to the posterior abdomen wall. It plays a very important role in fact it allows lymphatic and blood vessel to supply all the loops.

1. Small intestine's loops
2. Right colon and cecum

Until now we described all the structures in front of the posterior wall of parietal peritoneum.

Going over this wall there are other organs and structures included in the so called "Retroperitoneal region" (Figure 11). It contains:

- Kidneys
- Adrenals
- Ureters
- Abdominal aorta
- Inferior vena cava
- Distal Duodenum
- Left and Right Colon
- Pancreas

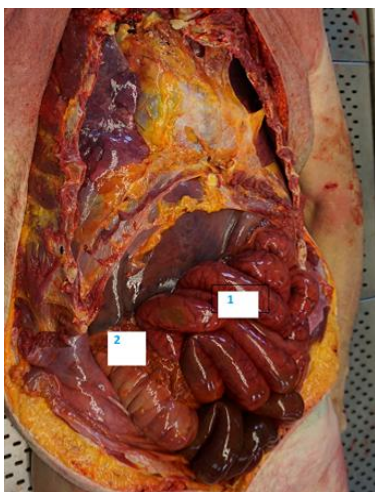


Figure 10. View of lower mesocolic region. 1) Ilium; 2) Ascending colon.

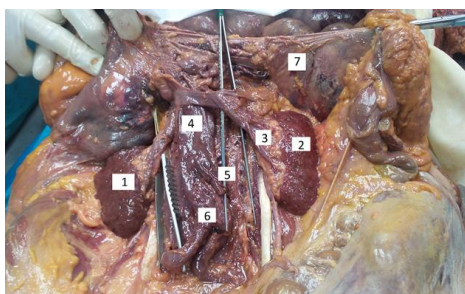


Figure 11. View of retroperitoneal area. 1) Right Kidney; 2) Left Kidney; 3) Renal Hilum; 4) Abdominal Aorta; 5) Inferior Mesenteric Artery; 6) Iliac Bifurcation; 7) Posterior layer of the Parietal Peritoneum, dissected

4. Discussion and conclusions

The study of anatomy through books and atlases allows us to know in depth the structures of the human body.

Through this article, and this study of cadavers, we have put into practice the knowledge acquired theoretically through book studies.

The dissection of the abdominal cavity has allowed us to acquire a greater awareness of the anatomical structures, the relationships between the various organs and to acquire morphological-functional knowledge, useful for understanding the pathologies related to these structures.

This opportunity should be a practice accessible to all students in order to strengthen the practical component of medical students' knowledge.

5. Acknowledgements

Our special thanks go to professors Francesco Cappello, Cristoforo Pomara and Christian Zammit whose personal availability and professional were essential and professional were essential to carrying out our project

References

1. Pollara P, Inzerauto P, Ravi N, Tomasino C, Scorsone A, Liguoro B, Busardò FP, Slama F, Capitummino R, Seidita E, Tomasello G, Carini F, Pomara C. Experiences that “Reach the heart”. Taking part in a whole-body dissection course at the University of Malta. *EuroMediterranean Biomedical Journal* 2017; 12 (22): 108-112.
2. Costantino C, Moscadini S, Puccio G, Cappello F, Mazzucco W. *EuroMediterranean biomedical journal: the renewed manuscript layout and web rendering foreshadow further journal improvement.* *EuroMediterraneanBiomedical Journal* 2017; 12 (1):1-5.
3. Barni T, Billi AM, BusinaroR, Cannas M, Cappello F, Castellucci M, Cocco L, D’Agata Velia, De Caro R, De Luca R, Dolci S, Geremia R, Guerra G, Gulisano M, Loreto C, Macchi V, Manzoli L, Mezzogiorno A, Montella A, Morini S, Nori S, Palumbo C, Papa M, Porzionato A, Rezzani R, Rodella L, Rossi P, Sbarbati A, Serrao G, Vercelli A, Vertemati M, Vitale M, Zancanaro C, Zecchi S, Zummo G. *Anatomia del Gray*. Edra.
4. Netter F.H. *Atlante di Anatomia Umana*. Edra.
5. Gilroy AM, MacPheerson BR, Ross LM. *Prometheus. Atlante di Anatomia*. Edises.
6. Pomara C, Karch SB, Finesch V. *Forensic autopsy – a Handbook and atlas*. CRC.
7. Rohen JW, Yokochi C, Lutjen-Drecoll E. *Color Atlas of Anatomy –a photographic study of human body*. Piccin.