

Kansas Agricultural Experiment Station Research Reports

Volume 6
Issue 10 *Swine Day*

Article 35

2020

Using a CO₂ Surgical Laser for Piglet Castration to Reduce Pain and Inflammation, and to Improve Wound Healing

A. V. Viscardi

Kansas State University, aviscardi@k-state.edu

C. A. Cull


Midwest Veterinary Service, Inc., Oakland, NE

M. D. Kleinhenz

Kansas State University, mkleinhe@k-state.edu

See next page for additional authors

Follow this and additional works at: <https://newprairiepress.org/kaesrr>

 Part of the [Large or Food Animal and Equine Medicine Commons](#), and the [Other Animal Sciences Commons](#)

Recommended Citation

Viscardi, A. V.; Cull, C. A.; Kleinhenz, M. D.; Montgomery, S.; Curtis, A.; Lechtenberg, K.; and Coetzee, J. F. (2020) "Using a CO₂ Surgical Laser for Piglet Castration to Reduce Pain and Inflammation, and to Improve Wound Healing," *Kansas Agricultural Experiment Station Research Reports*: Vol. 6: Iss. 10. <https://doi.org/10.4148/2378-5977.8016>

This report is brought to you for free and open access by New Prairie Press. It has been accepted for inclusion in Kansas Agricultural Experiment Station Research Reports by an authorized administrator of New Prairie Press. Copyright 2020 Kansas State University Agricultural Experiment Station and Cooperative Extension Service. Contents of this publication may be freely reproduced for educational purposes. All other rights reserved. Brand names appearing in this publication are for product identification purposes only. No endorsement is intended, nor is criticism implied of similar products not mentioned. K-State Research and Extension is an equal opportunity provider and employer.



Using a CO₂ Surgical Laser for Piglet Castration to Reduce Pain and Inflammation, and to Improve Wound Healing

Abstract

The objectives of this preliminary study were to determine the ability of a CO₂ surgical laser to 1) reduce pain, 2) reduce inflammation, and 3) improve wound healing of piglets undergoing surgical castration. Two-day old male Yorkshire × Landrace piglets were used and randomly assigned to one of three treatments ($n = 10$ piglets/treatment group): surgical castration with the CO₂ laser, surgical castration with a scalpel, or sham (uncastrated control). Piglets were video recorded in their pens for 1 h pre-procedure and from 0-2, 6-8, and at 24 h post-procedure for behavior scoring. Surgical site images were collected at baseline, 0, 8, 24, 48, 72, 96, 120, 144, and 168 h post-castration for wound healing assessment. Infrared thermography (IRT) images of the surgical site were also taken at baseline, 0, 0.5, 8, and 24 h post-procedure to assess inflammation. Finally, blood was collected from each piglet at baseline and 0.5 h post-castration to assess cortisol levels, prostaglandin E metabolite (PGEM), and pig-major acute phase protein (pig-MAP) concentration. Laser-castrated piglets displayed more pain behaviors across the observation period than scalpel-castrated piglets ($P = 0.049$). Laser-castrated piglets also displayed significantly more agonistic behavior than both scalpel-castrated and sham piglets ($P = 0.005$ and $P = 0.036$, respectively); yet, laser-castrated piglets had significantly lower temperatures at the site of incision compared to scalpel-castrated piglets ($P = 0.0211$). There was no significant difference in wound healing or any of the blood parameters assessed between laser-castrated and scalpel-castrated piglets. There was evidence of thermal tissue damage on the scrotum of piglets that were castrated using the CO₂ laser. This may have resulted in the unremarkable healing time and the increased pain behavior observed in this study. The surgical laser technique should be refined before conclusions can be made regarding the utility of a CO₂ laser for piglet castration.

Keywords

animal welfare, castration, CO₂ surgical laser, piglet, pain, refinement

Creative Commons License



This work is licensed under a [Creative Commons Attribution 4.0 License](https://creativecommons.org/licenses/by/4.0/).

Cover Page Footnote

The authors would like to thank personnel at Midwest Veterinary Services for data collection and technical assistance. This project was supported by Agriculture and Food Research Initiative Competitive Grant no. #2020-67015-31540 from the USDA National Institute of Food and Agriculture. Drs. Coetzee and Kleinhenz are supported by the Agriculture and Food Research Initiative Competitive Grants no. #2017-67015-27124, 2020-67030-31479, 2020-67015-31540 and 2020-67015-31546 from the USDA National Institute of Food and Agriculture.

Authors

A. V. Viscardi, C. A. Cull, M. D. Kleinhenz, S. Montgomery, A. Curtis, K. Lechtenberg, and J. F. Coetzee

Using a CO₂ Surgical Laser for Piglet Castration to Reduce Pain and Inflammation, and to Improve Wound Healing¹

Abbie V. Viscardi,² Charley A. Cull,³ Michael D. Kleinhenz,⁴ Shawnee Montgomery,² Andrew Curtis,² Kelly Lechtenberg,³ and Johann F. Coetzee²

Summary

The objectives of this preliminary study were to determine the ability of a CO₂ surgical laser to 1) reduce pain, 2) reduce inflammation, and 3) improve wound healing of piglets undergoing surgical castration. Two-day old male Yorkshire × Landrace piglets were used and randomly assigned to one of three treatments ($n = 10$ piglets/treatment group): surgical castration with the CO₂ laser, surgical castration with a scalpel, or sham (uncastrated control). Piglets were video recorded in their pens for 1 h pre-procedure and from 0-2, 6-8, and at 24 h post-procedure for behavior scoring. Surgical site images were collected at baseline, 0, 8, 24, 48, 72, 96, 120, 144, and 168 h post-castration for wound healing assessment. Infrared thermography (IRT) images of the surgical site were also taken at baseline, 0, 0.5, 8, and 24 h post-procedure to assess inflammation. Finally, blood was collected from each piglet at baseline and 0.5 h post-castration to assess cortisol levels, prostaglandin E metabolite (PGEM), and pig-major acute phase protein (pig-MAP) concentration. Laser-castrated piglets displayed more pain behaviors across the observation period than scalpel-castrated piglets ($P = 0.049$). Laser-castrated piglets also displayed significantly more agonistic behavior than both scalpel-castrated and sham piglets ($P = 0.005$ and $P = 0.036$, respectively); yet, laser-castrated piglets had significantly lower temperatures at the site of incision compared to scalpel-castrated piglets ($P = 0.0211$). There was no significant difference in wound healing or any of the blood parameters assessed between laser-castrated and scalpel-castrated piglets. There was evidence of thermal tissue damage on the scrotum of piglets that were castrated using the CO₂ laser. This may have resulted in the unremarkable healing time

¹ The authors would like to thank personnel at Midwest Veterinary Services for data collection and technical assistance. This project was supported by Agriculture and Food Research Initiative Competitive Grant no. #2020-67015-31540 from the USDA National Institute of Food and Agriculture. Drs. Coetzee and Kleinhenz are supported by the Agriculture and Food Research Initiative Competitive Grants no. #2017-67015-27124, 2020-67030-31479, 2020-67015-31540 and 2020-67015-31546 from the USDA National Institute of Food and Agriculture.

² Department of Anatomy and Physiology, College of Veterinary Medicine, Kansas State University.

³ Midwest Veterinary Service, Inc., Oakland, NE.

⁴ Department of Clinical Sciences, College of Veterinary Medicine, Kansas State University.

and the increased pain behavior observed in this study. The surgical laser technique should be refined before conclusions can be made regarding the utility of a CO₂ laser for piglet castration.

Introduction

Male piglets in North America are routinely castrated on-farm to prevent boar taint and minimize aggression. This painful procedure is done on conscious piglets, using a scalpel to make an incision on the scrotum and removing the testicles by cutting or tearing the spermatic cord. Complications, such as hemorrhage, infection, excessive swelling, and intestinal herniation (resulting in pre-weaning mortality), may be partially attributable to the described surgical castration technique. Refining the castration procedure by replacing the scalpel with a technique that decreases tissue damage and bleeding may reduce these post-surgical complications and lead to improved piglet welfare in commercial production systems.

CO₂ surgical lasers are increasingly being used for procedures in veterinary and human medicine. They function by emitting a colorless, infrared light at a specific wavelength (10,600 nm) that is absorbed by intracellular water and causes tissue cells to ablate or vaporize. This allows for precise incisions to be made on the skin and takes no more time than if a standard scalpel was used. Pain and swelling have been shown to be significantly reduced in human patients who have undergone the same surgical procedure using a CO₂ laser compared to a scalpel. The CO₂ laser has also refined the canine castration procedure by nearly eliminating blood flow during the surgery and reducing the risk of scrotal hematoma, bruising, and infection compared to canine castration with a scalpel.

The objectives of this pilot study were to determine the ability of a CO₂ surgical laser to 1) reduce pain, 2) reduce inflammation, and 3) improve wound healing of piglets undergoing surgical castration. We hypothesized that surgical castration of piglets using the CO₂ laser would result in decreased inflammation at the surgical site, reduced wound healing time, and less post-surgical pain compared to piglets castrated with a scalpel.

Procedures

All animal use and procedures were approved by the Institutional Animal Care and Use Committee at Midwest Veterinary Services (MVS) prior to study commencement (Protocol # MCL-19065).

A total of 30 piglets (mean body weight = 3.9 ± 1.6 lb; 2 days old) were used in this study. Piglets were randomly assigned to one of three treatments: surgical castration using a CO₂ laser (VetScalpel; Aesculight, LLC, Bothell, WA), surgical castration using a scalpel, or sham (uncastrated control). To conduct the castration procedure, piglets were removed from their pen, placed on a table in the supine position and restrained by two individuals. The surgical site was then disinfected using gauze soaked in isopropyl alcohol 70% (Vet One; MWI, Boise, ID). Piglets were castrated by making one horizontal incision on the scrotum with the CO₂ laser (set to 15 W, continuous) or scalpel, based on their treatment group. Testicles were removed by ablating (CO₂ laser) or

cutting (scalpel) the spermatic cord. The CO₂ laser was calibrated after each litter of pigs to ensure proper functionality (all calibrations yielded $79.7 \pm 1.4\%$). Piglets in the sham treatment group were restrained in the same manner, the handle of the scalpel was used to simulate the incision and the scrotum was manipulated to resemble a surgical castration. Piglets were then returned to their pen. All processing procedures occurred between 09:30 and 10:30 and were conducted by the same individual.

Piglets were video recorded for 1 h pre-procedure using a high definition video camera (Sony Handycam HDR-CX405, Sony USA Inc., New York, NY) mounted on a tripod and placed outside of each farrowing pen. Immediately post-castration, piglets were video recorded continuously from 0-2 h and from 6-8 h. Finally, 24 h post-procedure, piglets were recorded for 1 h. The behavior of each piglet was scored continuously by one experienced observer for the first 15 min of every hour of data collected using BORIS software (Behavioral Observation Research Interactive Software v. 7.7.3, Torino, Italy) and a detailed ethogram (Table 1). The observer was masked to treatment and time point; however, they could observe which piglets had been castrated and which had not. A total of 3,600 min (60 h) of behavior recordings were scored and analyzed for this study.

Still images of each piglet's scrotum were collected using a point-and-shoot camera (Olympus Stylus Tough TG-4; Olympus Corporation, Tokyo, Japan) at baseline (pre-procedure) and at 0, 8, 24, 48, 72, 96, 120, 144, and 168 h post-castration. Images were scored using a 6-point scale⁵ by one individual blinded to piglet treatment and time point. Wounds with a score of one were fully healed (no scab) and wounds with a score of six had signs of fresh blood.

Infrared thermography images of the surgical castration site were collected from each piglet pre-procedure and at 0, 0.5, 8, and 24 h post-procedure using an infrared camera (FLUKE TiX580; FLUKE Corporation, Everett, WA). In castrated piglets, the incision and surrounding tissues of the scrotum were captured in a single image; in sham piglets, an image of the scrotum was collected. The temperature of the incision (in castrated piglets) and the average temperature of the surrounding tissues of the scrotum were recorded and analyzed. These data were used to assess the degree of inflammation associated with the surgical castration procedure.

A blood sample (4.0 mL) from each piglet was collected from the jugular vein using a 20-gauge needle (TycoHealth Care, Mansfield, MA) at baseline and 30 min post-castration. Blood was immediately transferred into serum separator tubes (BD Vacutainer, Franklin Lakes, NJ) and placed on ice. Once all of the samples at each time point were collected, blood was centrifuged at 3,000 g for 10 min. The serum was pipetted from the tube, placed into cryovials and stored at -80°C until analysis. Serum samples were submitted to the Iowa State University-Pharmacology Analytical Support Team (ISU-PhAST) at the Iowa State University Veterinary Diagnostic Laboratory for cortisol determination. Samples were also analyzed by a laboratory technician at Kansas State University to determine prostaglandin E metabolite and pig-major acute phase protein

⁵ Sutherland, M., B. Davis, T. Brooks, and J. McGlone. 2010. Physiology and behavior of pigs before and after castration: Effects of two topical anesthetics. *Anim.* 4:2071-2079. doi:10.1017/S1751731110001291.

concentration. All laboratory personnel were blinded to piglet treatment and time point.

Statistical Analysis

Behavior data were analyzed using a generalized linear mixed (GLIMMIX) model with a beta distribution, including treatment, time, litter, and time \times treatment interaction in SAS (Statistical Analysis System 9.4, SAS Institute Inc., NC). Litter was included as a random effect and time was a repeated measure with piglet as the experimental unit. *Post hoc* tests were conducted using the Tukey-Kramer adjustment. Statistical significance was set at $P < 0.05$.

Cortisol was log-transformed for normality prior to analysis. Wound scores, temperature of the surgical site (from IRT images), cortisol, PGEM, and pig-MAP were analyzed using a mixed model in SAS, including litter, time, treatment, and time \times treatment interaction. Litter was included as a random effect and time was a repeated measure with piglet as the experimental unit. A *post hoc* Tukey's test was conducted for significant outcomes.

Results

Four individual behaviors (agonistic: $P = 0.004$, desynchronized: $P = 0.045$, tail wagging: $P = 0.026$, and trembling: $P = 0.049$) and one grouped behavior (pain: $P = 0.026$) were affected by treatment across the observation period (Table 2). Laser-castrated piglets trembled significantly more than scalpel-castrated piglets ($P = 0.041$) and engaged in more desynchronized behaviors ($P = 0.039$). Laser-castrated piglets also wagged their tails significantly more than sham piglets ($P = 0.027$). Agonistic behavior was displayed significantly more by laser-castrated piglets than both scalpel-castrated ($P = 0.005$) and sham ($P = 0.037$) piglets. Laser-castrated piglets demonstrated significantly more pain behaviors than piglets that were scalpel-castrated ($P = 0.049$).

There were significant time and treatment effects on wound scores ($P < 0.0001$ for both). Both castrated-treatment groups had significantly higher wound scores than sham piglets ($P < 0.0001$); however, there was no significant difference found in wound score between laser-castrated and scalpel-castrated piglets (Figure 1, $P = 0.988$). Wound scores decreased over time and did not reach baseline levels until 168 h (7 days) post-castration. A researcher involved in this study, who did not score castration wounds, noted evidence of scrotal tissue burns and bruising of the surrounding tissues in a number of the still images. Once unblinded to treatment, the images were assessed and both tissue burns and bruising were only observed in piglets that had been castrated using the CO₂ laser (Figure 2).

There was a significant time ($P < 0.0001$) and treatment effect ($P = 0.010$) on temperature at the incision site. At 0 h post-castration, laser-castrated and scalpel-castrated piglets had significantly higher incision site temperatures compared to sham piglets ($P < 0.0001$). At 0.5 h and 7 h post-castration, laser-castrated piglets had significantly lower temperatures at the site of incision compared to sham piglets ($P = 0.0005$ and $P = 0.010$, respectively). Across the assessment period, laser-castrated piglets had significantly lower incision site temperatures compared to scalpel-castrated piglets ($P = 0.008$).

There were no differences found in cortisol, PGEM, or pig-MAP concentration between any treatment group ($P = 0.19$, $P = 0.62$, and $P = 0.73$, respectively).

Discussion

Piglets that were castrated using the CO₂ laser exhibited significantly more pain behaviors (trembling, spasms, rubbing the rump, tail wagging, and stiffness) than scalpel-castrated piglets, which is contrary to the study hypothesis. Three factors likely contributed to this result: the disinfectant used, piglet restraint, and laser-castration technique. Isopropyl alcohol 70% is a common disinfectant used in human and veterinary medicine. Alcohols are highly flammable in nature and there is evidence that heat produced by the CO₂ laser caused a chemical reaction with the alcohol on the piglet's scrotal surface, resulting in thermal tissue damage. Difficulty in completely immobilizing conscious piglets resulted in suboptimal laser-castration technique, which also likely contributed to the increase in pain behavior observed.

There was no difference in wound score (i.e., healing time) between scalpel-castrated and laser-castrated piglets throughout the study. This is likely related to the burning of the scrotal tissue in laser-castrated piglets. The lack of difference in healing time may also be a result of poor laser technique or a power setting that was too low, requiring multiple passes with the laser to make an incision. These sequential passes with the laser at the incisional site increase the amount of thermal injury. The power setting selected for this study (15 W, continuous) was determined from the manufacturer's recommendations and by practicing surgical castration on piglet cadavers prior to study start. The power may need to be increased in future work, as multiple passes with the laser were required to make the scrotal incision.

Infrared thermography is a validated tool to measure cutaneous temperature and assess inflammation. Laser-castrated piglets had a lower temperature at the incision site across the assessment period (up to 24 h post-castration) compared to scalpel-castrated piglets, suggesting that there was less inflammation at the surgical site when the CO₂ laser was used. While this result is consistent with our study hypothesis, it contradicts the literature regarding thermal tissue injury and inflammation.⁶ As well, a decrease in inflammation after piglet surgical castration is generally associated with a reduction in acute pain and pain behaviors,⁷ yet this was not observed. The temperature of the surrounding scrotal tissues (excluding the incision site) did not differ between laser-castrated and scalpel-castrated piglets, suggesting inflammation at this location may be more predictive of castration-associated pain.

Using a CO₂ surgical laser instead of a scalpel has the potential to reduce pain, inflammation, and improve animal welfare. In this study, thermal tissue damage caused by the CO₂ laser confounded the pain and wound healing results, making it difficult to draw conclusions regarding the utility of this tool for surgical castration of piglets. A non-alcohol-based disinfectant should be used and the laser-castration technique optimized in

⁶ Strudwick, X. L., and A. J. Cowin. 2017. The role of the inflammatory response in burn injury. In: S. P. Kartal and D. Bayramgürler, editors, Hot topics in burn injuries. IntechOpen. doi:10.5772/intechopen.71330.

⁷ Herskin, M. S., and P. Di Giminiani. 2018. Pain in pigs: characterization, mechanisms and indicators. In: M. Špinková, editor, Advances in Pig Welfare. Elsevier Ltd, Cambridge, MA. p. 325-355.

future work, to assess pain, inflammation, and wound healing more accurately in piglets after processing.

Table 1. Ethogram used to score piglet behavior, grouped into feeding, locomotion, non-specific behaviors, castration-related pain behaviors, posture and social cohesion

Behavior	Description
Suckling	Teat in mouth and suckling movements
Nosing udder	Nose in contact with udder, up and down head movements
Playing	Springing, bouncy movements with or without littermates
Agonistic	Biting or fighting other littermates
Walking	Moving forward at a normal pace
Running	Trot or gallop
Awake inactive	No special activity, but awake
Sleeping	Lying down, eyes closed
Nosing	Snout in contact with a substrate
Chewing	Nibbling at littermates or substrates
Trembling	Shivering, as with cold
Spasms	Quick and involuntary contractions of the muscles
Scratching	Rubbing the rump against the floor, pen walls, or littermates
Tail wagging	Tail's movement from side to side (or up and down)
Stiffness	Lying with extended and tensed legs
Lying	Body weight supported by side or belly
Sitting	Body weight supported by hindquarters and front legs
Standing	Body weight supported by four legs
Kneeling	Body weight supported by front carpal joints and hind legs
Isolated	Alone, or with one littermate, distance of 40 cm separates the animal(s) from the closest group of littermates
Desynchronized	Activity different from that of most littermates (at least 75%)

Table 2. Proportion of time piglets were engaged in specific behaviors ($n = 10$ piglets per treatment group) post-castration. Values represent the proportional means (\pm SE).

Behavior ¹	Post-Castration			
	Treatment	CO ₂ Laser	Scalpel	Sham
Tail wagging	0.0257	0.02 \pm 0.00 ^a	0.00 \pm 0.00 ^{ab}	0.00 \pm 0.00 ^b
Trembling	0.0493	0.07 \pm 0.07 ^a	0.02 \pm 0.02 ^b	0.04 \pm 0.05 ^{ab}
Desynchronized	0.0446	0.18 \pm 0.07 ^a	0.05 \pm 0.03 ^b	0.16 \pm 0.06 ^{ab}
Agonistic	0.0038	0.01 \pm 0.00 ^a	0.00 \pm 0.00 ^b	0.00 \pm 0.00 ^b
Pain ²	0.0257	0.06 \pm 0.01 ^a	0.02 \pm 0.00 ^b	0.03 \pm 0.01 ^{ab}

¹Only significant behavior variables are presented.

²Pain behaviors include scratching, stiffness, trembling, and tail wagging.

^{ab}Values within a row with different superscripts are significantly different ($P < 0.05$).

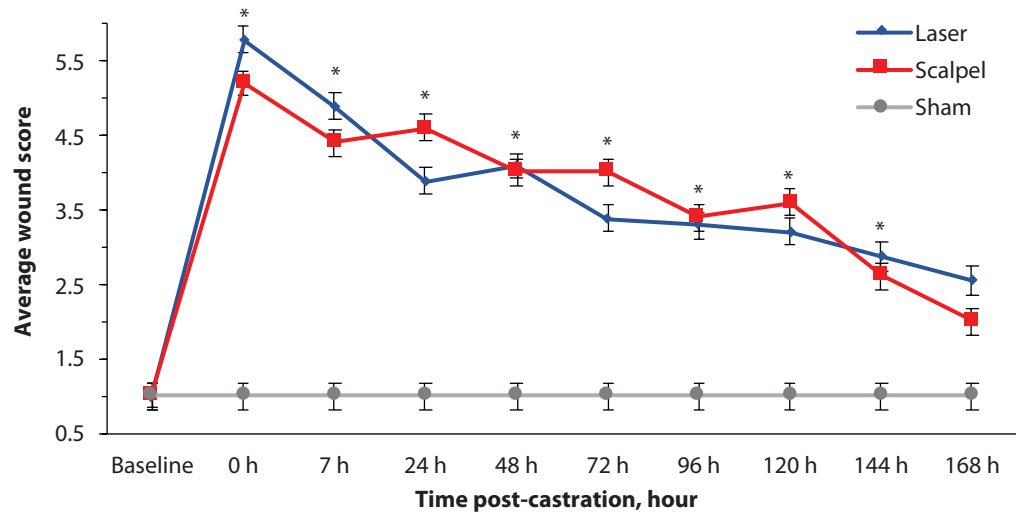


Figure 1. Average wound score (\pm SE) of piglets in each treatment group over time. Asterisks represent a significant difference ($P < 0.05$) between the castrated piglets (laser and scalpel; $n = 20$) and sham piglets ($n = 10$).

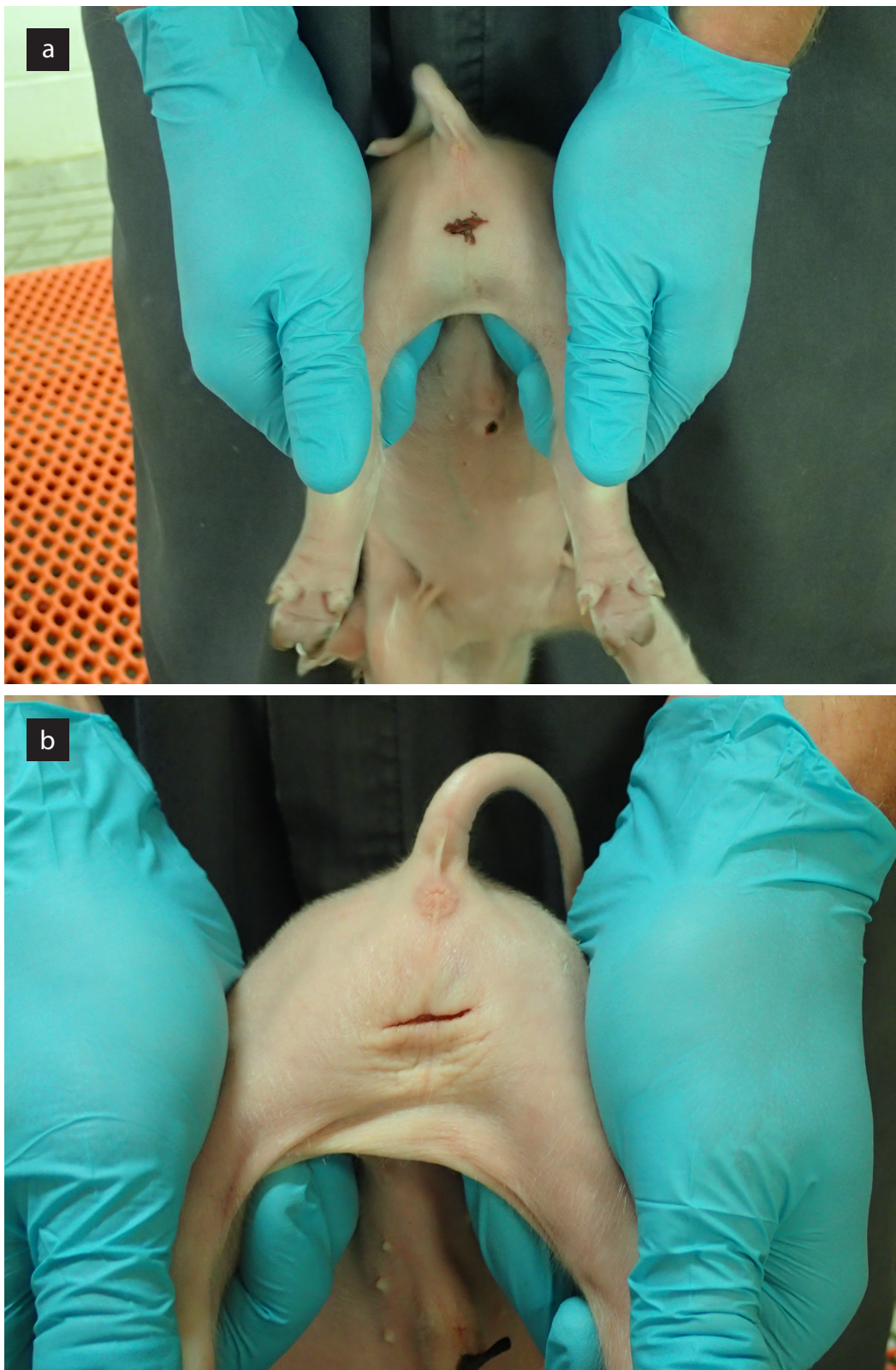


Figure 2. A comparison of the surgical wound at 24 h post-castration for a piglet undergoing the procedure using a) the CO₂ laser or b) a scalpel. Evidence of tissue burning at the incision site and bruising of the surrounding tissues is clear in the laser-castrated piglet.