

RVC OPEN ACCESS REPOSITORY – COPYRIGHT NOTICE

This is the peer reviewed version of the following article:

Beltran, E., Grundon, R., Stewart, J., Biggi, M., Holloway, A. and Freeman, C. (2016), IMAGING DIAGNOSIS — UNILATERAL TRIGEMINAL NEURITIS MIMICKING PERIPHERAL NERVE SHEATH TUMOR IN A HORSE. *Veterinary Radiology & Ultrasound*, 57: E1–E4. doi:[10.1111/vru.12272](https://doi.org/10.1111/vru.12272)

This article may be used for non-commercial purposes in accordance with [Wiley Terms and Conditions for Self-Archiving](#).

The full details of the published version of the article are as follows:

TITLE: IMAGING DIAGNOSIS — UNILATERAL TRIGEMINAL NEURITIS MIMICKING PERIPHERAL NERVE SHEATH TUMOR IN A HORSE

AUTHORS: Beltran, E., Grundon, R., Stewart, J., Biggi, M., Holloway, A. and Freeman, C.

JOURNAL TITLE: *Veterinary Radiology & Ultrasound*

PUBLISHER: Wiley

PUBLICATION DATE: January 2016

DOI: 10.1111/vru.12272

1

2

3 IMAGING DIAGNOSIS - UNILATERAL TRIGEMINAL NEURITIS MIMICKING
4 PERIPHERAL NERVE SHEATH TUMOR IN A HORSE

5

6 ELSA BELTRAN, RACHAEL GRUNDON, JENNIFER STEWART, MARIANNA
7 BIGGI, ANDREW HOLLOWAY, COURTENAY FREEMAN

8

9 **Corresponding author**

10 Elsa Beltran, Department of Clinical Science & Services, The Royal Veterinary College,
11 Hawkshead Lane, North Mymms, Hatfield, Herts, AL9 7TA, United Kingdom. e-mail:

12 ebeltran@rvc.ac.uk

13

14 **Key Words:** trigeminal nerve, MRI, horse, neuritis

15 **Running head:** Unilateral trigeminal neuritis in a horse

16 **Funding sources:** This study was not financially supported by any organisation or grant

17 **Previous presentations or abstracts:** This case report was presented as clinical research
18 abstract at the 27th annual symposium of the European College of Veterinary Neurology,
19 18th-20th September, 2014, Madrid, Spain.

20

21 **Abstract**

22 A 16-year-old Warmblood gelding presented with a non-healing corneal ulcer and absent
23 corneal sensation in the left eye. A lesion affecting the maxillary and ophthalmic branches
24 of the left trigeminal nerve was suspected. Magnetic resonance (MR) imaging identified
25 marked thickening of the ophthalmic and maxillary branches of the left trigeminal nerve.
26 The nerve was iso- to hypointense on T1-weighted and T2-weighted images with
27 heterogeneous enhancement. A peripheral nerve sheath tumor was suspected, however
28 granulomatous neuritis was histopathologically confirmed. These inflammatory changes
29 can result in severe nerve enlargement and should be considered with MR findings
30 suggestive of peripheral nerve sheath tumor.

31

32 **Signalment, History and Clinical Findings**

33 A 16-year-old Warmblood gelding was presented with a two-week history of a non-healing
34 corneal ulcer in the left eye. On presentation there was a mid depth stromal ulcer of the left
35 eye with a 4-5 mm fringe of perilimbal vascularisation. The ocular defect covered 70% of
36 the cornea with severe corneal edema precluding deeper ocular examination. A focal area
37 of cellular infiltrate was present at 10 o'clock at the margin of the ulcer and also ventrally
38 along the edge of the ulcer. There was minimal ocular discharge and the eye was open and
39 comfortable. The right eye was normal to ocular examination. Touch testing of the left
40 corneal surface revealed no corneal sensation. A neurological examination was requested.

41

42 Neurological examination revealed normal mental status, posture and gait. Postural
43 reactions were normal in all four limbs. Cranial nerve examination revealed decreased
44 sensation at the medial and lateral canthus of the left eye, the cornea of the left eye, over
45 the maxilla on the left, and in the left nostril. Palpebral reflex was decreased in the left eye,
46 but the menace response was present. Direct pupillary light reflex (PLR) could not be
47 assessed in the left eye due to the severity of the corneal ulcer and edema; however, a
48 normal consensual PLR was present on the right eye. The rest of the neurological
49 examination was normal. Pre-referral haematology and serum biochemistry did not reveal
50 any abnormalities.

51

52 Based on the history, ophthalmic and neurologic examination, a lesion affecting the
53 maxillary and ophthalmic branches of the left trigeminal nerve (CN V) was suspected. The
54 main differential diagnoses were neoplasia and inflammatory/infectious diseases. A MR

55 imaging study of the head was recommended in order to investigate the underlying cause.
56 A temporary tarsorrhaphy was placed in the left eye and the horse was started on topical
57 ocular serum and chloramphenicol eye drops every 4 hours.

58

59 **Imaging, Diagnosis and Outcome**

60 Magnetic resonance imaging of the head was performed under general anesthesia using a
61 1.5-T superconducting magnet (GE Signa Echospeed System, General Electric Medical
62 System, Milwaukee, WI). The horse was position on right lateral recumbency and images
63 were obtained in three planes (dorsal, sagittal and transverse). Sequences included T2-
64 weighted (T2W) fast spin echo (FSE), T1-weighted (T1W) FSE before and after
65 administration of intravenous contrast medium (20 ml, gadobenate dimeglumine,
66 MultiHance®, Bracco Imaging SpA, Milan, Italy). 3D- Spoiled Gradient Echo (SPGR)
67 pulse sequence was also acquired in transverse plane after contrast medium administration.
68 The MR images showed severe enlargement of the ophthalmic and maxillary branches of
69 the left trigeminal nerve from the level of middle cranial fossa, extending rostrally through
70 the orbital fissure and round foramen respectively, measuring about 2 cm in diameter
71 compared to 0.4 cm on the right side. The left infraorbital nerve was markedly thickened
72 along the length of the infraorbital canal. The trigeminal nerve enlargement was visible on
73 all sequences, however the T1W images acquired in transverse and sagittal planes showed
74 better definition of the lesion. The left orbital fissure, round foramen, and infraorbital canal
75 were enlarged by the markedly thickened left trigeminal nerve. The bony margin of these
76 structures surrounding the emerging left trigeminal nerve was thinned, presumably
77 secondary to pressure atrophy. The nerve was iso- to hypointense to grey matter on T1W,

78 T2W FSE, and 3D-SPGR and exhibited heterogeneous, mainly peripheral enhancement on
79 T1W sequence after contrast administration (Fig. 1). The imaging findings were consistent
80 with an extensive, diffuse left trigeminal neuropathy. The main differential diagnosis was
81 a peripheral nerve sheath tumor. Cerebrospinal fluid was collected from the
82 cerebellomedullary cistern and the analysis (nucleated cell count, total protein, and
83 cytology) was within normal limits.

84

85 Ultrasonographic examination (Philips HDI 5000, Bothell, USA) of the infraorbital nerve
86 at its exit from the infraorbital canal was performed using a 8.5 MHz microconvex array
87 transducer and 12 MHz linear array transducer in order to obtain a fine needle aspirate or
88 tru-cut biopsy; however, the nerve did not appear abnormal at this level precluding non-
89 invasive sampling.

90

91 The ulcer initially improved with evidence of healing and epithelialisation but then rapidly
92 progressed to a large descematocele requiring either surgical repair or enucleation. Given
93 the poor prognosis the owner declined any further treatment and elected to have the horse
94 euthanized. Post mortem examination confirmed gross enlargement of the left orbital
95 fissure, round foramen, and infraorbital canal in addition to the ophthalmic and maxillary
96 branches of left CN V (Fig. 2). Histopathology revealed that the trigeminal nerve was
97 markedly expanded by a densely cellular population of fibroblasts arranged in parallel
98 bundles depositing moderate amounts of fibrillar eosinophilic matrix. Admixed were large
99 numbers of infiltrating macrophages, lymphocytes, plasma cells, neutrophils,
100 multinucleated giant cells and eosinophils. Inflammatory cells are focused upon nerve

101 fascicles, with rupture of the perineurium and extension of inflammatory cells into the
102 interfascicular interstitium (Fig. 3). There was marked myelin degeneration with associated
103 axonal swelling (spheroids). The left infraorbital nerve at its exit from the infraorbital
104 canal, which was accessible to ultrasound examination, appeared mildly enlarged.
105 Histopathology at the same level revealed an extensive expansion of the fibrous connective
106 tissue surrounding the nerve fascicles, with small aggregates of lymphocytes. All these
107 findings were consistent with a severe granulomatous neuritis affecting the ophthalmic and
108 maxillary branches of the left trigeminal nerve.

109

110 **Discussion**

111 The etiology of the progressive granulomatous inflammation of the left trigeminal nerve in
112 this case remains undetermined. Granulomatous inflammation affecting the cranial nerves
113 has been associated with *polyneuritis equi* (PNE);¹ however, clinical experience has
114 suggested that horses with PNE presenting primarily with cranial nerve deficits eventually
115 also show cauda equina deficits.² Moreover, the most common clinical signs reported when
116 the cranial nerves are involved include atrophy of the muscles of mastication, dysphagia,
117 head tilt, facial nerve paresis and head shaking.³⁻⁶ In the present case, the neurological
118 examination did not reveal involvement of any other cranial nerve or any signs of cauda
119 equina dysfunction (poor tail tone, faecal and urinary incontinence, pelvic limb weakness
120 or pelvic limb muscle atrophy) at the time of presentation. However, a subclinical PNE
121 affecting this area could not be ruled out because the cauda equina was not assessed on
122 post-mortem examination. The underlying cause of PNE remains unknown, but an

123 underlying immune-mediated process has been suggested.^{5,7} Corticosteroids and
124 azathioprine have been proposed as potential treatments to slow progression of the disease.⁴

125

126 The MR imaging features of peripheral nerve sheath tumor (PNST) affecting the cranial
127 nerves have not been described in horses. There is a case report of lingual PNST in a horse,
128 where MR imaging revealed a large, round, well defined and encapsulated mass with mixed
129 signal intensity on T2W and T1W images.⁸ Some consistent, although nonspecific, MR
130 imaging features of PNST in dogs include diffuse thickening of the nerve that is typically
131 iso to hyperintense on T2W FSE sequences and iso-to hypointense on T1W FSE sequences
132 to normal muscle with heterogeneous contrast enhancement.^{9,10} Similar findings in our
133 case, together with the chronicity of the changes and degree of enlargement, suggested an
134 ante-mortem diagnosis of PNST; however, histopathology confirmed a severe
135 granulomatous neuritis.

136

137 There is a report of a trigeminal nerve sarcoid granuloma mimicking a trigeminal PNST in
138 a person.¹¹ This case had a similar expansile mass of the trigeminal nerve and was thought
139 to be a PNST; however, histopathology confirmed a sarcoid granuloma. Equine sarcoids
140 are attributed to non-productive infection with bovine papillomavirus.^{12,13} Histopathology
141 typically reveals fibroblast proliferation with spindle cells often arranged in bundles, oval
142 nuclei and small nucleoli. Peripheral nerve sheath tumor can histologically be difficult to
143 distinguish from sarcoids. Differentiation can be made with immunohistochemistry
144 staining for S-100 protein.¹⁴ However, histopathology in the present case was not consistent
145 with sarcoid granuloma.

146

147 The MR imaging findings in this horse confirmed the clinical diagnosis of trigeminal
148 neuropathy and led clinicians to consider the possibility of further investigating the area of
149 the affected nerve to reach a final diagnosis. On ultrasonographic examination the
150 infraorbital nerve appeared normal at its exit from the infraorbital canal. Given the normal
151 appearance of the nerve, fine needle aspiration was not attempted. Nevertheless, post-
152 mortem examination of the nerve at this level revealed some abnormalities and fine needle
153 aspiration or a surgical biopsy could have provided more diagnostic information than
154 anticipated.

155

156 In conclusion, granulomatous neuritis should be considered as a differential diagnosis in
157 horses with MR imaging findings suggestive of a trigeminal nerve sheath tumor. These
158 inflammatory changes can result in severe enlargement of the nerve mimicking a nerve
159 sheath tumor. Therefore, a surgical biopsy may be indicated to further characterize these
160 lesions in order to plan the best treatment approach.

161 **References**

162

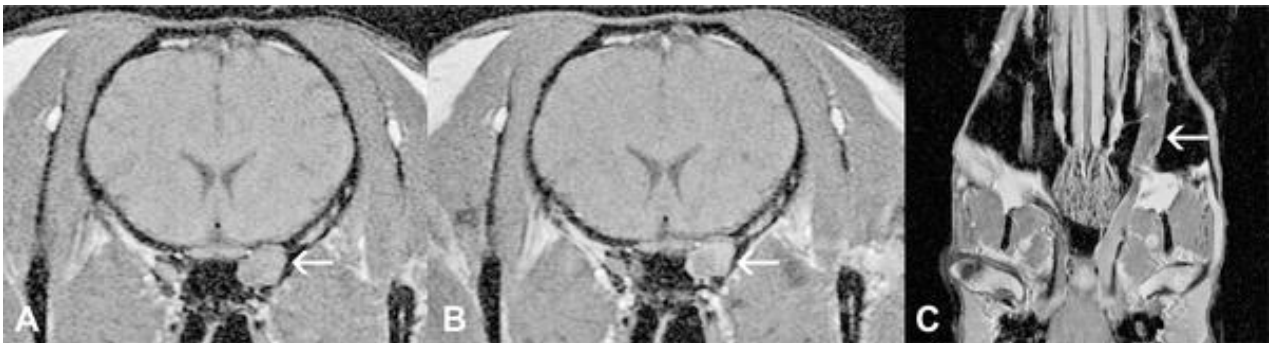- 163 1. Cummings JF, de Lahunta A, Timoney JF. Neuritis of the cauda equina, a chronic
164 idiopathic polyradiculoneuritis in the horse. *Acta Neuropathol.* 1979;46:17–24.
- 165 2. Bazargani T, Rafia S, Helan JAH, Moaddab SH. Occurrence of Unilateral Posterior
166 Polyneuritis in an 8-year-old Crossbred Mare. *J Equine Vet Sci* 2010; 30:711–714.
- 167 3. Hahn CN. Miscellaneous Disorders of the Equine Nervous System: Horner’s
168 Syndrome and Polyneuritis Equi. *Clin Tech Equine Pract* 2006;5:43–48.
- 169 4. Aleman M. Miscellaneous neurologic or neuromuscular disorders in horses. *Vet*
170 *Clin North Am Equine Pract* 2011;27:481-506.
- 171 5. Van Galen G1, Cassart D, Sandersen C, Delguste C, Nollet H, Amory H, Ducatelle
172 R. The composition of the inflammatory infiltrate in three cases of polyneuritis equi.
173 *Equine Vet J* 2008;40:185-188.
- 174 6. Roberts VL1, Perkins JD, Skärllina E, Gorvy DA, Tremaine WH, Williams A,
175 McKane SA, White I, Knottenbelt DC. Caudal anaesthesia of the infraorbital nerve
176 for diagnosis of idiopathic headshaking and caudal compression of the infraorbital
177 nerve for its treatment, in 58 horses. *Equine Vet J.* 2013;45:107-110.
- 178 7. Aleman M, Katzman SA, Vaughan B, Hodges J, Crabbs TA, Christopher MM,
179 Shelton GD, Higgins RJ. Antemortem diagnosis of polyneuritis equi. *J Vet Intern*
180 *Med* 2009;23:665-668.
- 181 8. A. Schneider, C. Tessier, D. Gorgas, P. Kircher, J. Mamani, J. Miclard. Magnetic
182 resonance imaging features of a benign peripheral nerve sheath tumour with
183 ‘ancient’ changes in the tongue of a horse. *Equine Equine Veterinary Educ*
184 2010;22:346–351.
- 185 9. Kraft S, Ehrhart EJ, Gall D, et al. Magnetic resonance imaging characteristics of
186 peripheral nerve sheath tumors of the canine brachial plexus in 18 dogs. *Vet Radiol*
187 *Ultrasound* 2007;48:1–7.
- 188 10. Davis EG, Coates JR, Johnson GC, Cook CR, Pardo ID. What is your neurologic
189 diagnosis? Peripheral nerve sheath tumor. *J Am Vet Med Assoc* 2011;239:189–191.
- 190 11. Quinones-Hinojosa A, Chang EF, Khan SA, McDermott MW. Isolated trigeminal
191 nerve sarcoid granuloma mimicking trigeminal schwannoma: case report.
192 *Neurosurgery* 2003;52:700-705.
- 193 12. Otten N, von Tschanner C, Lazary S, Antczak DF, Gerber H. 1993. DNA of bovine
194 papillomavirus type 1 and 2 in equine sarcoids: PCR detection and direct
195 sequencing. *Arch. Virol.* 132:121–131.

- 196 13 Lunardi M1, de Alcântara BK, Otonel RA, Rodrigues WB, Alfieri AF, Alfieri AA.
197 Bovine papillomavirus type 13 DNA in equine sarcoids. J Clin Microbiol.
198 2013;51:2167-2171.
- 199 14. Bogaert L1, Heerden MV, Cock HE, Martens A, Chiers K. Molecular and
200 immunohistochemical distinction of equine sarcoid from schwannoma. Vet Pathol.
201 2011;48:737-741.
- 202
- 203

204 **Figure captions**

205

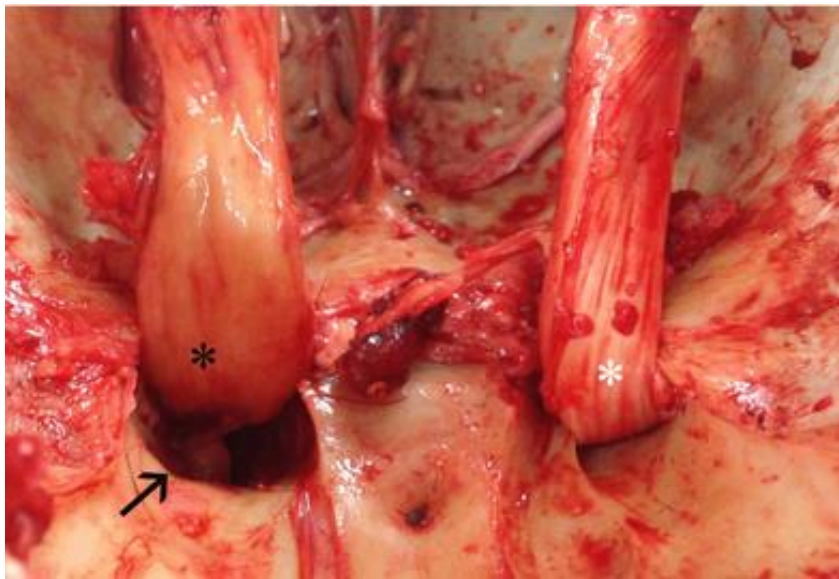
206 Figure 1 (A) Transverse T1-weighted (T1W) image at the level of the orbital fissure.
207 (B) Transverse T1W image after contrast administration at the same level
208 of Fig 1A. (C) Dorsal T1W image after contrast administration (TR=520ms,
209 TE=15.5ms, slice thickness 5mm). There is enlargement of the ophthalmic
210 and maxillary branches of the left trigeminal nerve from the level of middle
211 cranial fossa, through the orbital fissure and round foramen respectively.
212 The infraorbital branch of the maxillary branch of the trigeminal nerve is
213 markedly enlarged along the length of the infraorbital canal (arrow) (C).
214 The nerve was iso- to hypointense to grey matter on T1W (A) with
215 heterogeneous, mainly peripheral enhancement on T1W sequence (B) after
216 contrast administration. There was bony remodelling and secondary
217 enlargement of the left orbital fissure (arrow) (A,B).



218

219

220 Figure 2 View of the inner cranial vault after removal of the brain. Gross enlargement
221 of left orbital fissure and round foramen is visible (arrow). The ophthalmic
222 and maxillary branches of left trigeminal nerve (black asterisk) are enlarged
223 compared to the right trigeminal nerve (white asterisk).



224

225

226 Figure 3 Histopathology from a section of the left trigeminal nerve from the affected
227 horse (original magnification x 40 (A) and x 200 (B)). Haematoxylin and
228 eosin showed revealed that the trigeminal nerve was markedly expanded by
229 a densely cellular population of fibroblasts arranged in parallel bundles
230 depositing moderate amounts of fibrillar eosinophilic matrix. Admixed
231 were large numbers of infiltrating macrophages, lymphocytes, plasma cells,
232 neutrophils, multinucleated giant cells and eosinophils. Proliferation of
233 fibroblasts, and associated deposition of collagen, has resulted in marked
234 thickening of the perineurium. A densely cellular infiltrate is observed,
235 extending into the nerve fascicles through the endoneurium. This infiltrate
236 is composed of lymphocytes, plasma cells, macrophages, multinucleated
237 giant cells, and small numbers of eosinophils. Leukocytic infiltration is
238 associated here with neuronal destruction.

