

## RVC OPEN ACCESS REPOSITORY – COPYRIGHT NOTICE

This is the peer reviewed version of the following article:

Snyder, C. J., Soukup, J. W., Drees, R. and Tabone, T. J. (2015), Caudal Mandibular Bone Height and Buccal Cortical Bone Thickness Measured by Computed Tomography in Healthy Dogs. *Veterinary Surgery*. doi: 10.1111/vsu.12401

which has been published in final form at <http://dx.doi.org/10.1111/vsu.12401>.

This article may be used for non-commercial purposes in accordance with [Wiley Terms and Conditions for Self-Archiving](#)."

The full details of the published version of the article are as follows:

TITLE: Caudal Mandibular Bone Height and Buccal Cortical Bone Thickness Measured by Computed Tomography in Healthy Dogs

AUTHORS: Snyder, C. J., Soukup, J. W., Drees, R. and Tabone, T. J.

JOURNAL TITLE: *Veterinary Surgery*

VOLUME/EDITION:

PUBLISHER: Wiley

PUBLICATION DATE: 18 September 2015 (online)

DOI: 10.1111/vsu.12401

**RUNNING HEAD: Mandibular Bone Height and Buccal Bone Thickness in Dogs**

Caudal mandibular bone height and buccal cortical bone thickness measured by computed tomography in healthy dogs

Christopher J. Snyder, DVM, Diplomate AVDC, Jason W. Soukup, DVM, Diplomate AVDC, Randi Drees, Dr. Med. Vet, Diplomate ACVR & ECVDI, Tom J. Tabone, MS

Corresponding author:

Christopher J. Snyder

Department of Surgical Sciences

School of Veterinary Medicine

University of Wisconsin-Madison

2015 Linden Drive

Madison, WI 53706

[csnyderdvm@gmail.com](mailto:csnyderdvm@gmail.com)

## **ABSTRACT**

**Objective:** To characterize the bone height and buccal cortical bone thickness of the caudal mandible of healthy dogs.

**Study Design:** Prospective original study.

**Sample Population:** Client-owned dogs (n=36).

**Methods:** Dogs were distributed by weight into 3 groups (<10, 10-20, >20 kg). Thirteen transverse plane computed tomography images were selected for each dog based on anatomic landmarks from the 4th premolar (PM4) through the 2nd molar. On each image, bone thicknesses were measured along the buccal surface of both mandibles from the alveolar margin to the ventral border in 3 mm increments. The number of 3 mm increments were recorded as an estimation of mandibular height.

**Results:** A total of 14,901 measurements were retained for statistical analysis. Buccal bone was generally thicker ventrally in the area studied with decreasing bone thickness over both roots of PM4 and the mesial root of the 1st molar (M1). Cortical bone thickness of <2.0 mm was measured across all groups at most locations 3 mm ventral from the alveolar margin. Mandibular bone height demonstrated significantly fewer ( $P<.05$ ) 3 mm increments over the distal root of M1 in dogs  $\geq 10$  kg compared with the number of observations at the immediately mesial and distal locations.

**Conclusions:** Thin cortical bone overlying the mesial and distal roots of PM4 and mesial root of M1 limits these areas for the potential use of monocortical anchorage devices.

Decreased mandibular bone height at mandibular M1 may create a stress riser at this location, which along with thin cortical bone may explain why this is a common area for mandibular fracture.

Maxillofacial injuries reportedly account for 1.6-2.7% of all fractures in dogs.<sup>1-3</sup> Dogs sustaining head trauma frequently suffer fractures involving the mandible.<sup>3-5</sup> Management of maxillofacial fractures requires attention to structures unique to the oral cavity including tooth roots and neurovascular structures coursing through the mandible and maxilla. Fixation techniques that permit quick return to function (e.g., food prehension, chewing, and swallowing) are preferable. Mandibular fractures frequently involve the area of the mandibular 1st molar (M1),<sup>4-5</sup> which potentially creates a stress riser in this area because of this tooth's large size.<sup>5</sup> Mandibular fracture repaired in this area can be particularly challenging in dogs because muscular attachments and neurovascular structures in the caudal mandible complicate surgical exposure compared to mandibular mid-body fractures. In addition, tooth roots and the inferior alveolar neurovascular bundle markedly limit locations where pilot holes can be safely placed for various forms of invasive fracture repair.<sup>6</sup>

Non-invasive fracture repair techniques, such as intraoral composite splint fabrication or maxillomandibular canine tooth bonding do not require surgical exposure of the fracture site or risk damaging tooth roots or disrupting neurovascular structures. These techniques have gained popularity due to positive experiences with clinical application of dental composites in veterinary medicine.<sup>7-13</sup> However, specific situations such as gap defects, large edentulous areas of the mandible or pathologic fractures located in compromised bone may preclude use of non-invasive repair techniques and require the use of open reduction and internal fixation.

The placement of fixation devices along the dorsal surface of the mandible (tension surface) capitalizes on the naturally occurring compressive forces generated along the ventral surface of the mandible.<sup>14,15</sup> It becomes biomechanically advantageous to leverage the use of a tension band when considering fixation techniques for the mandible, including open reduction and internal fixation. Limitations of soft tissue coverage exist with interfragmentary wire or plate placement at the alveolar margin (tension surface). Implants should be placed beneath the alveolar mucosa to prevent dehiscence and plate exposure and therefore placement below the mucogingival junction is necessary.<sup>16</sup>

The development of mini implants with the application of monocortical screws has revolutionized human maxillofacial trauma and reconstruction.<sup>14-17</sup> Areas of safe and sufficient cortical bone thickness have been mapped in humans for drilling and placement of monocortical screws, orthodontic implants and intermaxillary fixation screws.<sup>18</sup> These locations have served as a guide for implant placement into areas of sufficient cortical bone while sparing dental structures.<sup>19-22</sup> Limited information exists regarding appropriate safe placement of implants in the maxilla and mandible of dogs.<sup>23</sup> Use of mini plates for osteosynthesis in people has been proven to withstand the forces exerted during mastication<sup>14</sup> and similar clinical examples of successful bone healing have been reported in dogs.<sup>24-27</sup> In people, proper placement of mini plates and monocortical screws results in equivalent healing to compression plates while avoiding important structures<sup>28-30</sup> with an experimental study in dogs reporting similar findings.<sup>31</sup>

Despite being less rigid than traditional orthopedic plates, the application of monocortical screws and mini plates may provide sufficient stability partially due to restricted bite forces reported in human mandibular fracture patients.<sup>32</sup> Gupta et al. reported preoperative molar tooth bite forces of people with mandibular fractures to be approximately 10% of the bite force measured 6 months postoperatively.<sup>32</sup> Two weeks following fixation, molar tooth bite force was ~35-40% of the force measured 6 months postoperatively.<sup>32</sup> Comparable information does not exist for veterinary patients suffering mandibular fractures, but comparative findings may be reasonably expected. Collection of data documenting buccal cortical bone thickness in the caudal mandible in dogs will guide further investigations into the biomechanics and bone healing following the application of monocortical screw and plate fixation.

Computed tomography (CT) is used for objective measurements and analysis in people and produces high accuracy measurements in the transverse plane analogous to implant placement.<sup>19,20,22</sup> The same information is not available in the veterinary literature, especially in a variety of animal sizes. Computed tomography has shown to be a good estimate for the measurement of mandibular bone thickness in anatomic sections in dogs.<sup>23</sup> In people, cortical bone thickness greater than 1.0 mm is an important factor in determining mini implant stability,<sup>33</sup> and cortical bone thickness of 2.0 mm has been suggested as the minimum amount of bone necessary to generate compression using plate fixation in maxillofacial injuries.<sup>34</sup>

A number of variables, including tension band placement and cortical bone thickness, are important to consider in selecting a method of internal fixation. The use of temporary orthodontic anchorage devices has become increasingly popular in people and may have veterinary application for fracture stabilization; however, knowledge of the characteristics of bone in the caudal mandible is necessary. The goal of our study was to measure bone height and buccal cortical bone thickness of the caudal mandible in healthy dogs of various sizes.

## **MATERIALS AND METHODS**

Dogs presenting for diagnostic CT of conditions unrelated to our study at the Veterinary Medical Teaching Hospital at the University of Wisconsin-Madison School of Veterinary Medicine (March 2010-October 2011) were considered for study inclusion. The institutional Animal Care and Use Committee approved all procedures and written consent was obtained from pet owners. Dogs were considered eligible for enrollment in the study if they were greater than 1 year of age, had a mesaticephalic head shape, complete or near-complete mandibular dentition, and had only minimal periodontal disease based on oral examination (stage 1<sup>35</sup> or less). Dogs missing the mandibular 4th premolar (PM4), 1st molar (M1) or any 2 other teeth caudal to the canine tooth, with obvious gross pathology involving the mandible, and dogs considered to be an anesthetic risk (greater than an American Society of Anesthesiologists (ASA) Patient Status Scale classification of 2 [mild systemic disease]<sup>36</sup>) were excluded. Dogs were divided into 3 groups by weight: <10 kg

(11 dogs, mean 6.5 kg, range 4.8-8.6 kg); 10-20 kg (10 dogs, mean 14.2, range 10.6-18.8), and >20 kg (15 dogs, mean 32.4, range 22-49).

Patients were anesthetized using a variety of anesthetic protocols and an oral evaluation and periodontal probing of mandibular teeth was performed on all dogs by 1 investigator (CJS or JWS). The imaging study for which the dogs were presented was completed prior to positioning dogs in sternal recumbency for image acquisition for this study (GE HiSpeed LX/i CT, GE Medical Systems, Milwaukee, WI). The head was extended with the lower jaw elevated and oriented with the ventral border of the mandibles parallel to the tabletop (Fig 1). Images were acquired in the transverse plane using 1 mm slice thickness and an interval from the mandibular 1st incisors through the temporomandibular joint using a high frequency spatial reconstruction algorithm (GE proprietary term: bone) and studies were evaluated with open source DICOM viewing software (OsiriX Imaging Software version 6.5.2, <http://www.osirix-viewer.com>). A single investigator (CJS) selected 13 profile image slices for the right and left mandibles of each dog (Table 1; Fig 2). Profile images were selected demonstrating greatest cortical bone thickness at locations not overlying tooth root structure (interproximal, furcational, and caudal to the 2nd molar (M2) locations as well as thinnest cortical bone and centered over root structures (mesial and distal roots). The *interproximal space* was defined as a location between the mesial and distal aspects of two separate teeth. The *furcation* was defined as a space where the roots of a multi-rooted tooth meet. *Mesial* and *distal* are directional terms referring to a surface or structure of a tooth closer (mesial) to, or farther away from (distal), the midline of the mouth along the



dental arch. *Caudal to M2* refers to the profile caudal to M2. The mandibular 3rd molar was not present in all patients.

Region of interest (ROI) guides for measuring buccal cortical bone thickness were placed over the mandibular body by a single investigator (CJS) and saved using the DICOM viewer. The long axis of the ROI markers were oriented parallel to the long axis of the buccal cortical bone plate (Fig 3a). Vertical markers were created every 3 mm beginning 3 mm ventral to the alveolar margin and staggered continually. Due to software resolution and tolerance, markers were spaced as close to 3.0 mm as possible (range, 2.9-3.1 mm). ROI markers for each dog were saved as a template for investigators to use for generating individual measurements.

Images were magnified to 300% to standardize and optimize CT viewing conditions and the window level and width were set to 4,100 and 13,500 Hounsfield units, respectively. Investigators (n=3) were only allowed to decrease ambient room light and increase monitor brightness settings to optimize visualization of cortical bone. No further modifications to window width and level settings within the imaging software were permitted. Investigators then imported the dog-specific vertical template ROI marks to guide measurement of bone thickness at the intersection of each 3 mm template mark using a digital calibrated ruler. Measurements were made from the buccal edge of the cortical bone plate and continued perpendicular to the bone surface (as if simulating screw placement) until reaching either the periodontal ligament space, mandibular canal or exiting through the lingual cortical surface (Fig 3). ROI measurements for each investigator were saved and transferred to a

spreadsheet. The mean and standard error (SE) of measurements for the 3 investigators at each location for each dog were used to remove measurements with SE >0.50 mm from the data set (Fig 4). Of 15,255 total measurements taken by the 3 investigators 354 were eliminated from the data set (118 individual locations; 2.3%). The mean, SE, and number of observations at each profile height were reported for all 3 weight groups (Table 2). The 95% confidence interval (CI) was calculated for each thickness measurement (mean  $\pm$  1.96x SE) and a cortical bone thickness of 2.00 mm was selected as the cutoff for appropriate cortical thickness. This value was chosen as the minimal potential cortical thickness providing anchorage for implants placed monocortically<sup>16</sup> and one that is greater than the minimum cortical thicknesses (>1.00 mm) for orthodontic implant success.<sup>33</sup> Locations where the 95% CI was <2.00 mm would be considered less appropriate for monocortical anchorage of mini implants, whereas locations where the 95% CI  $\geq$  2.00 mm would be considered appropriate (Fig 5). Data for bone thickness were analyzed using Proc Means (SAS/STAT Software, version 9.3, SAS Institute Inc., Cary, NC). McNemar's chi-squared statistic (Proc Freq, SAS/STAT Software, version 9.3, SAS Institute Inc., Cary, NC) was used to determine if there was a significant change in the number of observations at each of the 3mm increments. Statistical significance was set at a  $P < .05$ .

## RESULTS

There were no significant differences in cortical bone thickness for any particular location between right and left mandibles in each dog ( $P=.75$ ) or within body weight groups (<10 kg,  $P=.28$ ; 10-20 kg,  $P=.30$ ; >20 kg  $P=.86$ ). There were no significant differences in cortical thickness between investigators across all dogs ( $P=.15$ ) or for dogs 10-20 kg ( $P=.46$ ). However, measurements in dogs <10 kg ( $P=.02$ ) and those >20 kg ( $P<.001$ ) were significantly different between investigators.

### *Buccal Cortical Bone Thickness*

Buccal cortical bone was progressively thicker ventrally in all 3 groups (Table 2). In all dogs, regardless of weight, cortical thickness was <2.00 mm (95% CI) at 3 mm ventral from the alveolar margin, except for dogs <10 kg at the region of interproximal PM4 / M1 and regions extending from the furcation of M1 to caudal M2 and for the 10-20 kg group at caudal M2. The >20 kg group demonstrated a cortical thickness <2.00 mm at all locations 3 mm ventral from the alveolar crest. Cortical thickness was <2.00 mm at 6 mm ventral from the alveolar crest at the mesial root of PM4 of the 10-20 kg and >20 kg groups, and at the mesial root of M1 in all 3 groups.

Cortical thickness was both greater than and less than 2.00 mm (95% CI) at 6 mm ventral from the alveolar margin overlying the mesial root of PM4, distal root of PM4, and at 9 mm ventral from the alveolar crest over the mesial root of M1 in < 10 kg dogs. At 6 mm in dogs 10-20 kg bone thickness was greater than or less than 2.00 mm overlying distal root PM4, interproximal M1/M2 and at 3 mm ventral from the alveolar margin at the

furcation M2 and distal root M2 locations. In >20 kg, group thickness was greater than or less than 2.00 mm overlying the furcation of M2 and distal root M2. At distances of  $\geq 9$  mm from the alveolar margin, bone was measured >2.00 mm at all locations except at the 9 mm location overlying the mesial root of M1 in dogs <10 kg.

### *Mandibular Bone Height*

Each group exhibited a reduction in the number of measurements in the dr M1 location, suggesting a loss of bone height in this area (12-21 mm from the alveolar margin depending on the size of the dog) (Fig 6). In dogs < 10 kg, the number of bone thickness measurements made decreased at 12 mm from the alveolar margin, suggesting a reduction in bone height in some patients within the group. There was no significant difference in number of measurements between the f M1 and dr M1 profiles ( $P=.25$ ) at 12 mm; however, there was a significant difference between the dr M1 and I M1/M2 profiles ( $P<.001$ ). In dogs 10-20 kg, the change in number of bone thickness measurements occurred at 15 mm from the alveolar margin. This change was significant between the number of observations between the f M1 and dr M1 ( $P=.008$ ) and dr M1 and I M1/M2 ( $P=.035$ ) profiles. In dogs > 20 kg, the change in number of bone thickness measurements occurred at 21 mm from the alveolar margin with significant differences between the f M1 and dr M1 ( $P<.001$ ) and dr M1 and I M1/M2 ( $P<.001$ ) profiles.

## **DISCUSSION**

The results of our study document  $> 2.0$  mm of cortical bone at distances more than 3 mm below the alveolar margin in dogs of all sizes. Thicker cortical bone provides increase supportive for monocortical anchorage devices. Thin cortical bone, combined with decreased mandibular bone height at the dr M1 location may both predispose this location to fracture. Placement of anchorage directly over the mesial roots of PM4 and M1 should be avoided due to decreased cortical bone thickness and close proximity to tooth root structure. Considering the tension band principle, anchorage should be considered 6-9 mm below the alveolar margin where cortical bone is thicker.

Several decisions associated with mini implant placement determine success, including cortical bone thickness and screw number. Cortical bone thickness  $> 1.0$  mm significantly improves the success of mini implants in people.<sup>33</sup> Several reports in humans recommend mini screw lengths of 5-7 mm to attain adequate bone purchase for fixation stabilization.<sup>15,37,38</sup> Biomechanically, monocortical screws have decreased failure load and a lower bending stress<sup>39</sup>; however, application in the correct anatomic locations in the oral cavity and the reduced masticatory forces placed on oral fixation devices provide adequate stabilization for healing. In people, it has been shown that the number of screws is more important in determining how load forces are distributed in a 2.0 mm adaption plate rather than the effect of monocortical versus bicortical anchorage.<sup>40</sup> Three screws in each fracture segment produced significantly increased resistance to failure compared to 2 screws per segment, while 4 screws per fracture segment did not further increase resistance to failure compared to 3 screws,<sup>40</sup> suggesting that 3 screws per fracture

segment placed in a tension band location should adequately resist vertical forces placed on the fracture site by mastication in people.<sup>40</sup> To consider whether these principles may be applicable to a canine population, information needs to be first generated to characterize the cortical bone thickness at locations where plates may be placed and secondly, advanced biomechanical testing of plates with monocortical screws needs to be properly evaluated.

Contact between screws and tooth structure can negatively impact screw stability.<sup>41</sup> Inflammation associated with root damage may also result in bone resorption and decrease mechanical retention and stability of the screw.<sup>41</sup> Efforts to select screw placement locations that avoid tooth structure and where sufficient cortical bone thickness and peri-implant cortical bone exist may be equally important. Inadvertent tooth root damage affecting cementum and/or dentin has been shown to result in those dental structures possessing a limited capacity for root healing following screw removal.<sup>42</sup> The combination of increasing cortical bone thickness and natural taper of the tooth roots suggest that placing monocortical implants as close to the alveolar margin as possible while remaining ventral enough to the alveolar margin to avoid contacting the tooth root may provide optimal placement of monocortical anchorage for orthodontic anchorage devices or as a tension band for fracture fixation. Canine dentition appears relatively larger and occupies more space than the human dentition, reinforcing the need to generate canine-specific data for bone thickness. In locations without dental or neurovascular structures, bicortical screw placement not be problematic. Placement of an internal fixation device applied as a tension band while also anchoring in thicker cortical bone is ideal.

Interestingly, the lightest weight range (< 10 kg) in our study demonstrated increasing cortical bone thickness (>2.0 mm) at depths closer to the alveolar margin compared to larger dogs (10-20 and >20 kg). It has been shown that tooth eruption and masticatory forces play a key role in the determination of alveolar bone height and bone quality.<sup>43</sup> Forces distributed through the mandibular body by tooth structure may contribute to our finding that cortical bone was >2.0 mm at depths closer to the alveolar margin relative to the heavier dogs. Cortical thickness patterns demonstrate bone was relatively thinner over the mesial tooth roots of mandibular PM4 and M1. This finding suggests that the mandibular cortical plate accommodates the root anatomy at these locations.

Fixation devices are functionally strongest in tension and should be placed in this biomechanically advantageous location.<sup>44,45</sup> The alveolar margin (dorsal surface) is the tension surface of the mandibular body. Fixation methods requiring bicortical holes for the placement of external fixator pins, bicortically placed screws, and guide holes for interfragmentary wires all need to be carefully planned to avoid damaging important structures and benefit from placement in dense cortical bone. The limited flexibility for placement of screws afforded by osteosynthesis plates creates challenges when attempting to avoid these structures. Bicortically placed locking plates have proven stronger than monocortical locking plates under an experimental bending load tested using the clavicle.<sup>39</sup> Use of monocortically anchored plates may be controversial to some in dynamic locations such as the mandible. An abundance of noninvasive and semi-rigid fixation techniques are reported in dogs with success (e.g., acrylic/composite,<sup>46</sup> interdental wire and acrylic,<sup>47</sup> maxillomandibular fixation using acrylic or composite of canine or other teeth with or

without wire reinforcement,<sup>48</sup> tape muzzle,<sup>49</sup> and bi-gnathic encircling devices<sup>50</sup>). Experimental and clinical applications of semi-rigid, noninvasive techniques have demonstrated successful healing suggesting that rigid fixation, although ideal, may not be necessary when successfully treating mandibular fractures. Kern et al. showed successful bone healing *in vivo* using 3 mandibular fracture fixation devices.<sup>12</sup> The reduced callus formation seen in early healing in the plate fixation group is supportive of more predictable healing occurring using techniques of rigid fixation for mandibular fracture repair.<sup>12</sup> Improved predictability with healing by using more stable forms of fixation (mini plates and screws) combined with increased understanding where bone stock may support monocortical screw placement creates justification for further investigation and testing. The goal should be the safe application of internal fixation in dogs to facilitate a quick return to function and permit predictable primary bone healing.<sup>16</sup> In addition to patient size and the nature of the fracture, a variety of biomechanical properties associated with implant constructs exist and are beyond the scope of this study. Aside from available cortical bone and complicated anatomy of the mandible, variables associated with repair include plate and screw size, appropriateness of monocortical versus bicortical screw placement, and availability of locking and non-locking constructs.

Fractures of the body of the mandible frequently involve the area of mandibular M1 and small dogs are commonly overrepresented.<sup>3,4,5</sup> Increased cortical bone thickness in smaller patients in our study may be related to the impact of masticatory forces distributed by these teeth<sup>43</sup> that may be relatively magnified when comparing the size of teeth to the



size of supporting mandibular bone. Masticatory forces distributed through bone in smaller patients may explain the variation in distribution of alveolar marginal bone thicknesses relative to thicknesses found in medium and larger sized dogs.

Mandibular M1:bone height ratio has a significant association with weight.<sup>51</sup> Smaller dogs have proportionally larger teeth relative to supporting bone when compared to larger dogs.<sup>51</sup> The size of teeth in small toy breed dogs was described as “excessively” large when compared to the size of their upper and lower jaws.<sup>51</sup> In smaller dogs, the large size of the roots of M1 relative to the height of supporting mandibular bone, as well as the root surface surrounded by periodontal ligament, may both contribute to structural weakening and predilection for fracture at this location. Small dogs have also been shown to have an increased prevalence of periodontal disease.<sup>52</sup> Periodontal disease coupled with decreased supporting bone height involving M1 may contribute to biomechanical weakening at this location. Based on the number of measurements in this location in our study, Kitshoff’s description of this area as a “stress riser”<sup>5</sup> may be amplified by the possibility that mandibular bone height may be reduced in the area of the distal root of M1. Fractures commonly reported involving M1 could also be related to cortical bone thinning over the mesial root of M1.

The unexpected trend of measurements at distal root of M1 location suggests a reduction in mandibular bone height exists in this location. Based on the number of measurements (raw or qualified), mandibular bone height (alveolar margin to ventral border) demonstrated a similar trend in all 3 groups. Our results suggest that the height of

mandibular bone is less (mandibular height from alveolar margin to ventral border) in the area of the distal root of M1. Dogs 10–20 kg and >20 kg demonstrated a marked reduction in the number of measurements (qualified or raw) at the distal root of M1 when compared to measurements recorded at the furcation of M1 or the interproximal space of M1/M2. Further exploration into anatomic patterns of bone thickness in this fracture-prone location may enable development of fixation techniques and devices that specifically compensate for this biomechanically weak location.

The significant differences between investigator measurements noted in dogs < 10 kg and  $\geq 20$  kg are likely related to a combination of factors, including investigator interpretation of location of the extramural and intramural cortical bone surfaces, individual variability for orientation of measurement calipers perpendicular to the cortical surface, and resolution of the imaging software. While not ideal, these differences are of limited clinical importance since drilling perfectly perpendicular holes for interfragmentary wire, pins or screws can be difficult. Additional investigators creating measurements would have resulted in a larger number of measurements and may have reduced the SE at some locations. Similar human studies have reported measurements by a single investigator.<sup>21</sup> The accuracy of 3D CT to perform linear measurements of dentofacial structures in humans has proven reliable<sup>53,54</sup> making serial sectioning of mandibles from sacrificed dogs unnecessary for this study.

In conclusion, we do not suggest that the data gathered in our study are universally applicable; however, they will selectively guide further biomechanical testing and

investigation as to the impact of cortical bone thickness when considering biomechanical factors of internal fixation. Attention to the anatomic details of individual dogs, presence of periodontal disease with associated bone loss, mechanical loads to be placed on the fixation device in each case, and availability and appropriateness of fixation hardware are all case-specific. However, in our study, cortical thickness of  $>2.0$  mm existed in most areas of the buccal caudal mandible at points  $>3$  mm ventral to the alveolar margin. When considering the placement of any monocortical implant (for osteosynthesis or orthodontic anchorage) particular attention should be paid to the available cortical bone overlying the mesial and distal roots of the PM4 and the mesial root of the M1 in the mandible.

#### **ACKNOWLEDGEMENTS**

The authors thank Kelsie Ernst who assisted with data entry, Nick Keuler for support with study design, and Kristi Takasaki for illustrations. Supported by a grant from the Foundation for Veterinary Dentistry.

#### **DISCLOSURE**

The authors declare no financial or other conflicts of interest related to this report.

## REFERENCES

1. Wong WT: A survey of fractures in the dog and cat in Malaysia. *Vet Rec* 1984;115:273-274
2. Phillips IR: A survey of bone fractures in the dog and cat. *J Sm Anim Pract* 1979;20:661-674
3. Umphlet RC, Johnson AL: Mandibular fractures in the dog. A retrospective study of 157 cases. *Vet Surg* 1990;19:272-275
4. Lopes FM, Gioso MA, Ferro DG, et al: Oral fractures in dogs of Brazil - a retrospective study. *J Vet Dent* 2005;22:86-90
5. Kitshoff AM, de Rooster H, Ferreira SM, et al: A retrospective study of 109 dogs with mandibular fractures. *Vet Comp Orthop Traumatol* 2013;26:1-5
6. Verstraete FJ, Lightelm AJ: Dental trauma caused by screws in internal fixation of mandibular osteotomies in the dog. *Vet Comp Orthop Traumatol* 1992;5:104-108
7. Rice CA, Riehl J, Broman K, et al: Comparing the degree of exothermic polymerization in commonly used acrylic and provisional composite resins for intraoral appliances. *J Vet Dent* 2012;29:78-83
8. Wiggs RB, Lobprise HB: Oral fracture repair, in Wiggs RB, Lobprise HB (eds): *Veterinary Dentistry Principles and Practice*. Philadelphia, PA, Lippencott-Raven, 1997, pp 259-279
9. Niemiec BA: Intraoral acrylic splint application. *J Vet Dent* 2003;20:123-126
10. Beckman B, Smith MM: Interarcade bonding for non-invasive mandibular fracture repair. *J Vet Dent* 2009;26:62-66

11. Muir P, Gengler WR: Interdental acrylic stabilisation of canine tooth root and mandibular fractures in a dog. *Vet Rec* 1999;145:43-45
12. Kern DA, Smith MM, Stevenson S, et al: Evaluation of three fixation techniques for repair of mandibular fractures in dogs. *J Am Vet Med Assoc* 1995;206:1883-1890
13. Legendre L: Use of maxillary and mandibular splints for restoration of normal occlusion following jaw trauma in a cat: case report. *J Vet Dent* 1998;15:179-181
14. Champy M, Lodde JP, Schmitt R, et al: Mandibular osteosynthesis by miniature screwed plates via a buccal approach. *J Oral Maxillofac Surg* 1978;6:14-21
15. Worthington P, Champy M: Monocortical miniplate osteosynthesis. *Otolaryngol Clin North Am* 1987;20:607-620
16. Boudrieau RJ: Maxillofacial fracture repair using mini plates and screws, in: Verstrete FJM, Lommer M (eds): *Oral and Maxillofacial Surgery in Dogs and Cats*. Edinburgh, UK, Elsevier Ltd., 2012, pp 239-308
17. Kerawala CJ, Allen W, Williams ED: Can monocortical mini plates provide bony compression? An experimental model. *Br J Oral Maxillofac Surg* 2003; 41:232-235
18. Cornelius CP, Ehrenfeld M: The use of MMF screws: surgical technique, indications, contraindications, and common problems in review of the literature. *Craniomaxillofac Trauma Reconstr* 2010;3:55-80
19. Poggio PM, Incorvati C, Velo S, et al: "Safe zones"; a guide for miniscrew positioning in the maxillary and mandibular arch. *Angle Orthod* 2006;76:191-197

20. Schilli W, Ewers R, Niederdellmann H: Bone fixation with screws and plates in the maxillofacial region. *Int J Oral Surg* 1981;10(Suppl. 1):329-332
21. Ono A, Motoyoshi M, Shimizu N: Cortical bone thickness in the buccal posterior region for orthodontic mini implants. *Int J Oral Maxillofac Surg* 2008;37:334-340
22. Monnerat C, Restle L, Mucha JN: Tomographic mapping of mandibular interradicular spaces for placement of orthodontic mini implants. *Am J Orthod Dentofacial Orthop* 2009;135:428.e1-428.e9.
23. Zhao L, Xu Z, Yang Z et al: Quantitative research using computed tomographic scanning of beagle jaws for determination of safe zones for micro-screw implantation. *Ann Anat* 2009;191:379-388
24. Lewis JR, Boudrieau RJ, Reiter AM: Mandibular reconstruction after gunshot trauma in a dog by use of recombinant human bone morphogenic protein-2. *J Am Vet Med Assoc* 2008;233:1598-1604
25. Boudrieau RJ: Miniplate reconstruction of severely comminuted maxillary fractures in two dogs. *Vet Surg* 2004;33:154-163
26. Boudrieau RJ, Mitchell SL, Seeherman H: Mandibular reconstruction of a partial hemimandibulectomy in a dog with severe malocclusion. *Vet Surg* 2004;33:119-130
27. Sverzut CE, Lucas MA, Sverzut AT et al: Bone repair in mandibular body osteotomy after using 2.0 miniplate system- histological and histometric analysis in dogs. *Int J Exp Path* 2008;89:91-97
28. Ellis E, Walker L: Treatment of mandibular angle fractures using two noncompression mini plates. *J Oral Maxillofac Surg* 1994; 52:1032-1037

29. Baker SB, Dayan JH: Principles of fixation for maxillofacial trauma, in: Fonseca RJ (ed): *Oral and Maxillofacial Trauma* (ed 3). St. Louis, MO, Elsevier, 2005, pp 1131-1170
30. Chiodo TA, Miles M: Use of monocortical mini plates for the intraoral treatment of mandibular fractures. *Atlas Oral Maxillofacial Surg Clin North Am* 2009;17:19-25
31. Freitag V, Landau H: Healing of dentate or edentulous mandibular fractures treated with rigid or semirigid plate fixation- an experimental study in dogs. *J Craniomaxillofac Surg* 1996;24:83-87
32. Gupta A, Singh V, Mohammad S: Bite force evaluation of mandibular fractures treated with microplates and mini plates. *J Oral Maxillofac Surg* 2012;70:1903-1908
33. Motoyoshi M, Inaba M, Ono A, et al: The effect of cortical bone thickness on the stability of orthodontic mini implants on the stress distribution surrounding bone. *Int J Oral Maxillofac Surg* 2009;38:13-18
34. Kellman RM, Schilli W: Plate fixation of fractures of the mid and upper face. *Otolaryngol Clin North Am* 1987;20:559-572
35. Wiggs RB, Lobprise HB: Periodontology, in: Wiggs RB, Lobprise HB, (eds): *Veterinary Dentistry Principles and Practice*. Philadelphia, PA, Lippencott-Raven, 1997, pp 186-231
36. Muir WW: Considerations for general anesthesia, in: Tranquilli WJ, Thurmon JC, Grimm KG, (eds): *Lumb and Jones' Veterinary Anesthesia and Analgesia*, 4<sup>th</sup> ed. Ames, IA, Blackwell, 2007, pp 17-30

37. Davies BW, Cederna JP, Guyuron B: Non-compression unicortical miniplate osteosynthesis of mandibular fractures. *Ann Plast Surg* 1992;28:414-419
38. Saka B: Mechanical and biomechanical measurements of five currently available osteosynthesis systems of self-tapping screws. *Br J Oral Maxillofac Surg* 2000;38:70-75
39. Little KJ, Riches PE, Fazzi UG: Biomechanical analysis of locked and non-locked plate fixation of the clavicle. *Injury* 2012;43:921-925
40. Haug HR: The effects of screw number and length on two methods of tension band plating. *J Oral Maxillofac Surg* 1993;51:159-162
41. Chen SS, Chang HH, Chen YH, et al: Tissue reaction surrounding miniscrews for orthodontic anchorage: an animal experiment. *J Dent Sci* 2012;7:57-64
42. Asschericks K, Vannet BV, Wehrbein H, et al: Root repair after injury from mini-screw. *Clin Oral Implants Res* 2005;16:575-578
43. Hennet PR, Harvey CE: Craniofacial development and growth in the dog. *J Vet Dent* 1992;9:11-18
44. Boudrieau RJ, Verstraete FJM: Principles of maxillofacial fracture repair, in: Verstraete FJM, Lommer M (eds): *Oral and Maxillofacial Surgery in Dogs and Cats*. Edinburgh, UK, Elsevier Ltd., 2012, pp 233-242
45. Pauwels F: The significance of a tension band for the stressing of the tubular bone with application to compression osteosynthesis, in: Pauwels F (ed): *Biomechanics of the Locomotor Apparatus, Contributions on the Functional Anatomy of the Locomotor Apparatus*. Germany, Springer-Verlag Berlin Heidelberg, 1980, pp 430-449



46. Legendre L: Intraoral acrylic splints for maxillofacial fracture repair. *J Vet Dent* 2003;20:70-78
47. Kern DA, Smith MM, Stevenson S, et al: Evaluation of three fixation techniques for repair of mandibular fractures in dogs. *J Am Vet Med Assoc* 1995;206:1883-1890
48. Bennett JW, Kapatkin AS, Manfra Marretta S: Dental composite for the fixation of mandibular fractures and luxations in 11 cats and 6 dogs. *Vet Surg* 1994;23:190-194
49. Withrow SJ: Taping of the mandible in treatment of mandibular fractures. *J Am Anim Hosp Assoc* 1981;17:27-31
50. Nicholson I, Wyatt J, Radke H et al: Treatment of caudal mandibular fracture and temporomandibular joint fracture-luxation using a bi-gnathic encircling and retaining device. *Vet Comp Orthop Traumatol* 2010;23:102-108
51. Gioso MA, Shofer F, Barros PS, et al: Mandible and mandibular 1st molar tooth measurements in dogs: relationship of radiographic height to body weight. *J Vet Dent* 2001;18:65-68
52. Harvey CE, Shofer FS, Laster L: Association of age and body weight with periodontal disease in North American Dogs. *J Vet Dent* 1994;11:94-105
53. Cavalcanti MG, Yang J, Ruprecht A, et al: Accurate linear measurements in the anterior maxilla using orthoradially reformatted spiral computed tomography. *Dentomaxillofac Radiol* 1999;28:137-140

54. Hedeşiu M, Balog C, Preda DM, et al: The accuracy of alveolar crest dimensions measurement for dental implants. In vitro study. *Rev Med Chir Soc Med Nat Iasi* 2008;112:224-228

## TABLES

Table 1 Locations for the 13 CT slice profiles from Figure 1 used for measurement of mandibular buccal bone thickness.

Slice Location	Description
I PM3/PM4	Interproximal 3rd premolar/4th premolar
mr PM4	Mesial root 4th premolar
f PM4	Furcation 4th premolar
dr PM4	Distal root 4th premolar
I PM4/M1	Interproximal 4th premolar/1st molar
mr M1	Mesial root 1st molar
f M1	Furcation 1st molar
dr M1	Distal root 1st molar
I M1/M2	Interproximal 1st molar/2nd molar
mr M2	Mesial root 2nd molar
f M2	Furcation 2nd molar
dr M2	Distal root 2nd molar
caud M2	Caudal to 2nd molar

Table 2 Mean ( $\pm$  SE) cortical bone thickness.

Group 1 (0-10kg)															
Level Profile	3 mm			6 mm			9 mm			12 mm			15 mm		
	mean	std error	observ	mean	std error	observ	mean	std error	observ	mean	std error	observ	mean	std error	observ
I PM3/PM4	1.90	0.04	<b>66</b>	2.16	0.04	<b>66</b>	2.15	0.03	<b>57</b>	2.28	0.07	<b>18</b>			
nr PM4	1.31	0.04	<b>66</b>	1.97	0.04	<b>66</b>	2.15	0.03	<b>60</b>	2.15	0.05	<b>27</b>	2.74	0.10	<b>3</b>
F PM4	1.88	0.05	<b>66</b>	2.24	0.04	<b>66</b>	2.16	0.03	<b>60</b>	2.17	0.05	<b>30(33)</b>	2.31	0.12	<b>3</b>
dr PM4	1.29	0.03	<b>66</b>	2.02	0.05	<b>66</b>	2.18	0.04	<b>60</b>	2.22	0.06	<b>24</b>			
I PM4/M1	2.03	0.05	<b>66</b>	2.24	0.04	<b>66</b>	2.18	0.04	<b>57</b>	2.27	0.05	<b>24</b>	2.62	0.06	<b>3</b>
nr M1	1.27	0.05	<b>66</b>	1.88	0.04	<b>66</b>	2.00	0.05	<b>57</b>	2.45	0.06	<b>21</b>	2.67	0.06	<b>6</b>
F M1	2.16	0.05	<b>66</b>	2.23	0.04	<b>66</b>	2.17	0.04	<b>63</b>	2.36	0.05	<b>24</b>			
dr M1	2.17	0.05	<b>66</b>	2.35	0.06	<b>66</b>	2.31	0.04	<b>51(57)</b>	2.57	0.10	<b>12(21)</b>	2.67	0.06	<b>6</b>
I M1/M2	2.37	0.05	<b>66</b>	2.39	0.06	<b>66</b>	2.31	0.05	<b>54(60)</b>	2.58	0.07	<b>27(33)</b>	3.45	0.04	<b>3(6)</b>
nr M2	2.41	0.05	<b>66</b>	2.46	0.06	<b>66</b>	2.32	0.05	<b>57(60)</b>	2.57	0.05	<b>36(39)</b>	3.46	0.15	<b>12(18)</b>
F M2	2.69	0.06	<b>66</b>	2.59	0.06	<b>66</b>	2.40	0.05	<b>57(63)</b>	2.50	0.05	<b>36(45)</b>	3.23	0.14	<b>18(24)</b>
dr M2	2.79	0.10	<b>66</b>	2.78	0.07	<b>66</b>	2.40	0.06	<b>60(66)</b>	2.38	0.07	<b>42(57)</b>	3.23	0.23	<b>27</b>
caud M2	3.13	0.10	<b>66</b>	2.99	0.07	<b>66</b>	2.40	0.06	<b>60(66)</b>	2.67	0.16	<b>45(57)</b>	5.61	0.65	<b>9</b>

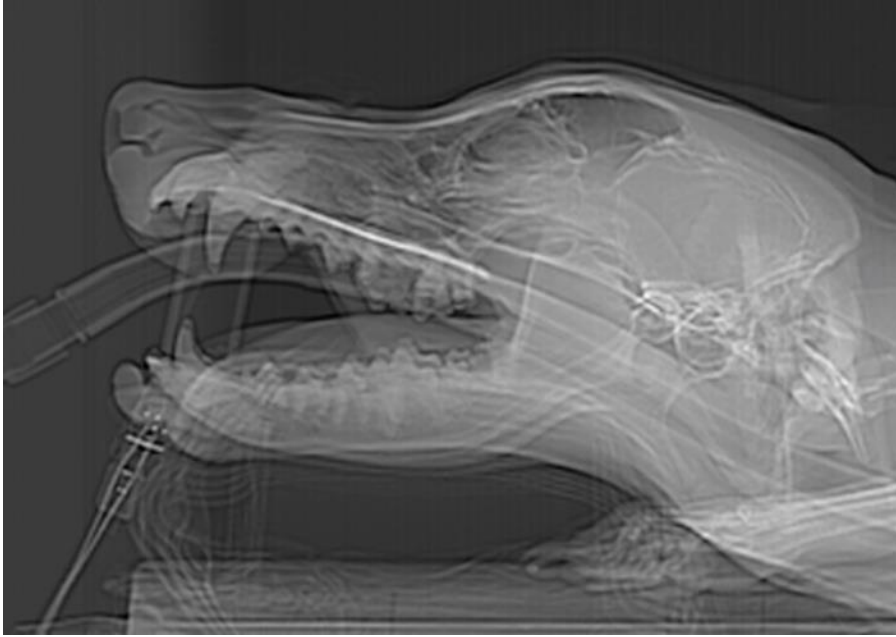Group 2 (10-20kg)																					
Level Profile	3 mm			6 mm			9 mm			12 mm			15 mm			18 mm			21 mm		
	mean	std error	observ	mean	std error	observ	mean	std error	observ	mean	std error	observ	mean	std error	observ	mean	std error	observ	mean	std error	observ
I PM3/PM4	1.78	0.04	<b>60</b>	2.15	0.04	<b>60</b>	2.28	0.04	<b>60</b>	2.20	0.04	<b>57(60)</b>	2.29	0.04	<b>33</b>	2.31	0.06	<b>6</b>	2.45	0.21	<b>3</b>
nr PM4	1.17	0.05	<b>60</b>	1.71	0.08	<b>60</b>	2.14	0.06	<b>60</b>	2.47	0.13	<b>60</b>	2.23	0.04	<b>42</b>	2.27	0.04	<b>9</b>	2.25	0.13	<b>6</b>
F PM4	1.54	0.06	<b>60</b>	2.19	0.05	<b>60</b>	2.31	0.04	<b>60</b>	2.22	0.04	<b>60</b>	2.20	0.04	<b>48</b>	2.47	0.07	<b>6</b>	2.39	0.10	<b>6</b>
dr PM4	1.28	0.04	<b>60</b>	1.93	0.05	<b>60</b>	2.30	0.05	<b>60</b>	2.24	0.04	<b>60</b>	2.17	0.04	<b>39</b>	2.23	0.07	<b>9</b>	2.23	0.01	<b>6</b>
I PM4/M1	1.65	0.05	<b>60</b>	2.24	0.04	<b>60</b>	2.38	0.05	<b>60</b>	2.21	0.03	<b>60</b>	2.27	0.04	<b>45</b>	2.35	0.06	<b>15</b>	2.25	0.08	<b>6</b>
nr M1	1.01	0.05	<b>60</b>	1.70	0.07	<b>60</b>	2.29	0.07	<b>60</b>	2.33	0.06	<b>60</b>	2.15	0.05	<b>45</b>	2.33	0.06	<b>21</b>	2.31	0.06	<b>6</b>
F M1	1.62	0.05	<b>60</b>	2.34	0.04	<b>60</b>	2.34	0.04	<b>60</b>	2.26	0.04	<b>60</b>	2.27	0.06	<b>51</b>	2.34	0.06	<b>24</b>	2.07	0.07	<b>6</b>
dr M1	1.87	0.06	<b>60</b>	2.57	0.05	<b>60</b>	2.36	0.05	<b>60</b>	2.39	0.06	<b>60</b>	2.60	0.06	<b>33</b>	2.43	0.09	<b>6(9)</b>	2.56	0.18	<b>6</b>
I M1/M2	1.91	0.07	<b>60</b>	2.39	0.05	<b>60</b>	2.39	0.05	<b>60</b>	2.34	0.05	<b>60</b>	2.68	0.07	<b>42</b>	2.75	0.17	<b>12(15)</b>	2.51	0.15	<b>6</b>
nr M2	1.83	0.08	<b>60</b>	2.44	0.06	<b>60</b>	2.40	0.05	<b>60</b>	2.40	0.05	<b>60</b>	2.72	0.07	<b>48(57)</b>	2.90	0.12	<b>24</b>	2.40	0.11	<b>6</b>
F M2	1.91	0.06	<b>60</b>	2.35	0.06	<b>60</b>	2.43	0.05	<b>60</b>	2.40	0.05	<b>60</b>	2.81	0.12	<b>51(60)</b>	2.73	0.12	<b>24</b>	2.21	0.09	<b>6</b>
dr M2	1.88	0.09	<b>60</b>	2.45	0.07	<b>60</b>	2.50	0.06	<b>60</b>	2.44	0.05	<b>60</b>	2.79	0.14	<b>60</b>	2.98	0.17	<b>33(36)</b>	3.07	0.39	<b>21(24)</b>
caud M2	2.33	0.12	<b>57(60)</b>	2.60	0.07	<b>60</b>	2.62	0.06	<b>60</b>	2.44	0.06	<b>60</b>	2.62	0.10	<b>57(60)</b>	2.98	0.15	<b>42(45)</b>	3.30	0.08	<b>18(24)</b>

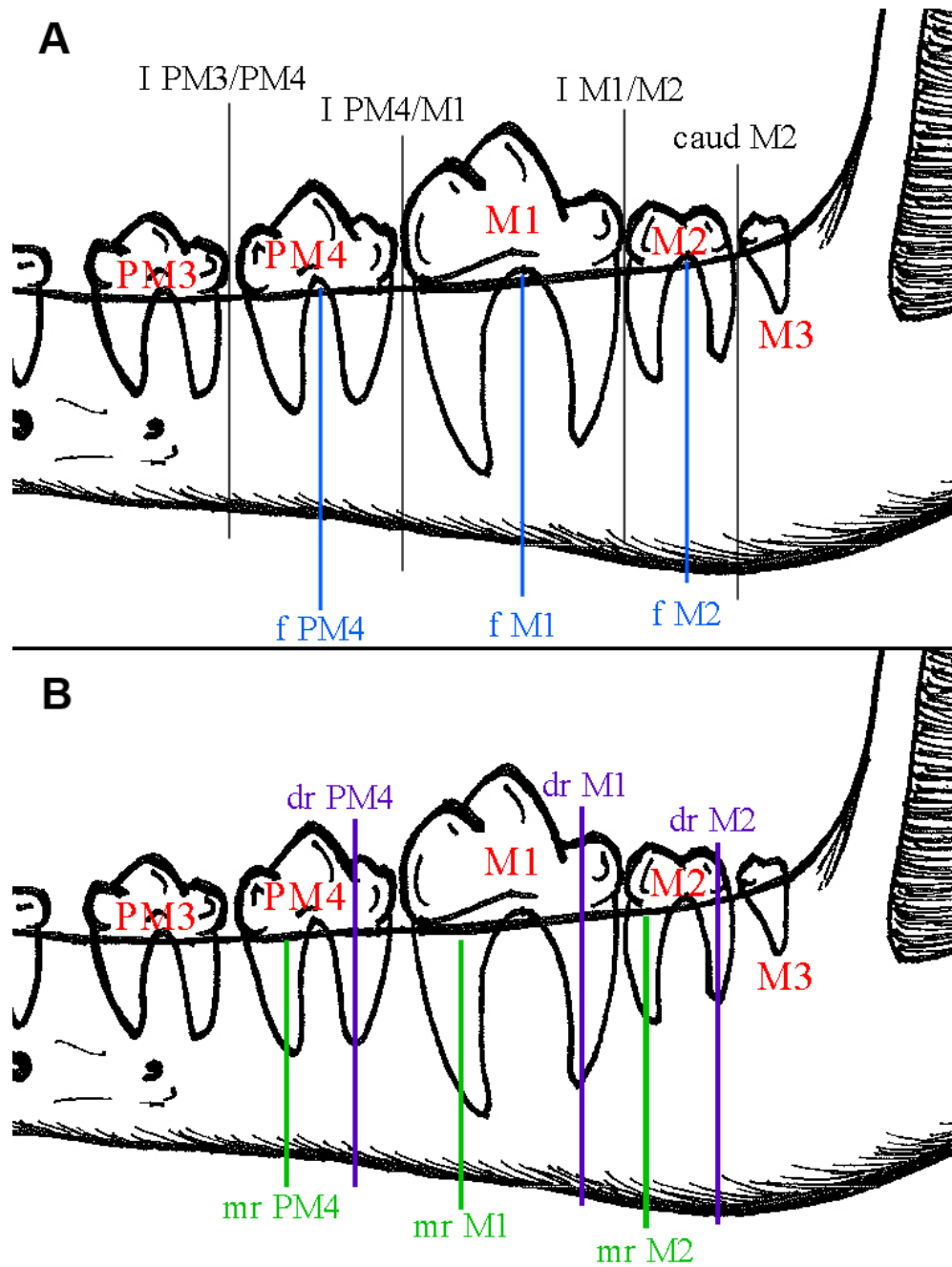
Group 3 (>20kg)																											
Level Profile	3 mm			6 mm			9 mm			12 mm			15 mm			18 mm			21 mm			24 mm			27 mm		
	mean	std error	observ	mean	std error	observ	mean	std error	observ	mean	std error	observ	mean	std error	observ	mean	std error	observ	mean	std error	observ	mean	std error	observ	mean	std error	observ
I PM3/PM4	1.91	0.04	<b>87(90)</b>	2.50	0.04	<b>90</b>	2.82	0.04	<b>90</b>	2.80	0.04	<b>90</b>	2.65	0.04	<b>90</b>	2.86	0.04	<b>63</b>	3.25	0.13	<b>15(18)</b>	3.74	0.10	<b>6</b>			
nr PM4	1.30	0.04	<b>90</b>	1.87	0.04	<b>90</b>	2.31	0.05	<b>90</b>	2.65	0.04	<b>90</b>	2.75	0.04	<b>90</b>	2.77	0.04	<b>84</b>	2.94	0.06	<b>42</b>	3.51	0.17	<b>6</b>			
F PM4	1.66	0.05	<b>90</b>	2.16	0.05	<b>87(90)</b>	2.61	0.04	<b>90</b>	2.74	0.04	<b>90</b>	2.72	0.04	<b>90</b>	2.72	0.04	<b>81</b>	2.83	0.05	<b>54</b>	3.30	0.20	<b>6</b>			
dr PM4	1.60	0.04	<b>90</b>	2.09	0.04	<b>90</b>	2.47	0.05	<b>90</b>	2.72	0.04	<b>90</b>	2.74	0.03	<b>90</b>	2.74	0.04	<b>81</b>	2.88	0.07	<b>39</b>	3.34	0.10	<b>6</b>	3.25	0.23	<b>3</b>
I PM4/M1	1.66	0.05	<b>78(90)</b>	2.18	0.05	<b>81(90)</b>	2.61	0.05	<b>90</b>	2.77	0.05	<b>87(90)</b>	2.75	0.04	<b>90</b>	2.73	0.04	<b>87</b>	2.87	0.07	<b>48(51)</b>	2.91	0.12	<b>15</b>	3.28	0.27	<b>6</b>
nr M1	1.28	0.04	<b>90</b>	1.82	0.05	<b>90</b>	2.44	0.04	<b>90</b>	2.81	0.06	<b>84(90)</b>	2.77	0.04	<b>90</b>	2.59	0.04	<b>90</b>	2.76	0.08	<b>48(57)</b>	3.18	0.10	<b>15</b>	3.42	0.21	<b>6</b>
F M1	1.76	0.05	<b>90</b>	2.55	0.06	<b>90</b>	2.84	0.05	<b>90</b>	2.85	0.04	<b>90</b>	2.75	0.04	<b>90</b>	2.66	0.04	<b>90</b>	2.76	0.06	<b>63(69)</b>	2.57	0.12	<b>15</b>	3.27	0.27	<b>6</b>
dr M1	1.94	0.04	<b>90</b>	2.48	0.06	<b>84(90)</b>	2.76	0.05	<b>87(90)</b>	2.79	0.04	<b>90</b>	2.68	0.04	<b>90</b>	2.85	0.05	<b>81(90)</b>	3.15	0.11	<b>36(42)</b>	3.11	0.28	<b>12</b>	3.87	0.49	<b>3(6)</b>
I M1/M2	1.84	0.05	<b>90</b>	2.20	0.05	<b>87(90)</b>	2.44	0.05	<b>90</b>	2.75	0.04	<b>90</b>	2.76	0.04	<b>90</b>	2.88	0.05	<b>87(90)</b>	3.09	0.08	<b>54(63)</b>	2.86	0.19	<b>18</b>			<b>(6)</b>
nr M2	1.76	0.05	<b>90</b>	2.22	0.07	<b>87(90)</b>	2.33	0.05	<b>90</b>	2.66	0.04	<b>87(90)</b>	2.82	0.04	<b>90</b>	3.01	0.05	<b>90</b>	3.12	0.08	<b>63(72)</b>	2.58	0.10	<b>18(21)</b>	3.17	0.25	<b>6</b>
F M2	1.86	0.06	<b>90</b>	2.11	0.06	<b>87(90)</b>	2.37	0.05	<b>90</b>	2.67	0.04	<b>90</b>	2.89	0.04	<b>90</b>	3.03	0.05	<b>90</b>	3.16	0.08	<b>63(72)</b>	3.02	0.14	<b>33(36)</b>	3.25	0.12	<b>3(6)</b>
dr M2	1.59	0.08	<b>87(90)</b>	2.10	0.06	<b>87(90)</b>	2.28	0.06	<b>90</b>	2.59	0.05	<b>90</b>	2.81	0.04	<b>90</b>	3.06	0.06	<b>90</b>	3.24	0.07	<b>78(84)</b>	3.40	0.17	<b>57(63)</b>	3.32	0.16	<b>9(12)</b>
caud M2	1.67	0.06	<b>90</b>	2.25	0.09	<b>84(90)</b>	2.44	0.08	<b>90</b>	2.64	0.05	<b>90</b>	2.84	0.04	<b>90</b>	3.07	0.05	<b>90</b>	3.20	0.06	<b>87</b>	3.15	0.06	<b>69(75)</b>	3.34	0.11	<b>30</b>

# = # of measurements at each location (# of total measurements prior to removal due to excessive investigator variability).

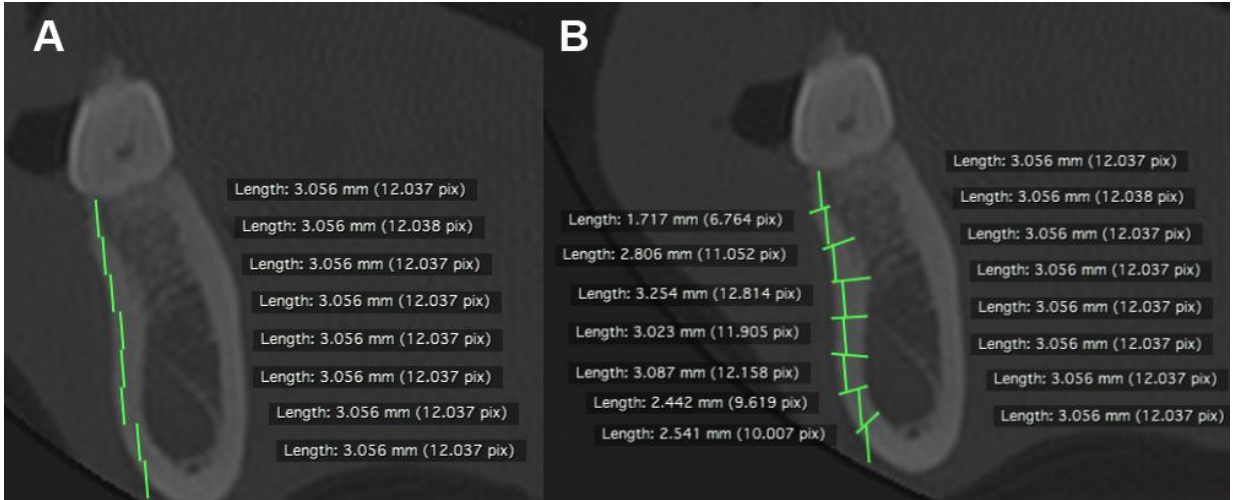
## FIGURE LEGENDS



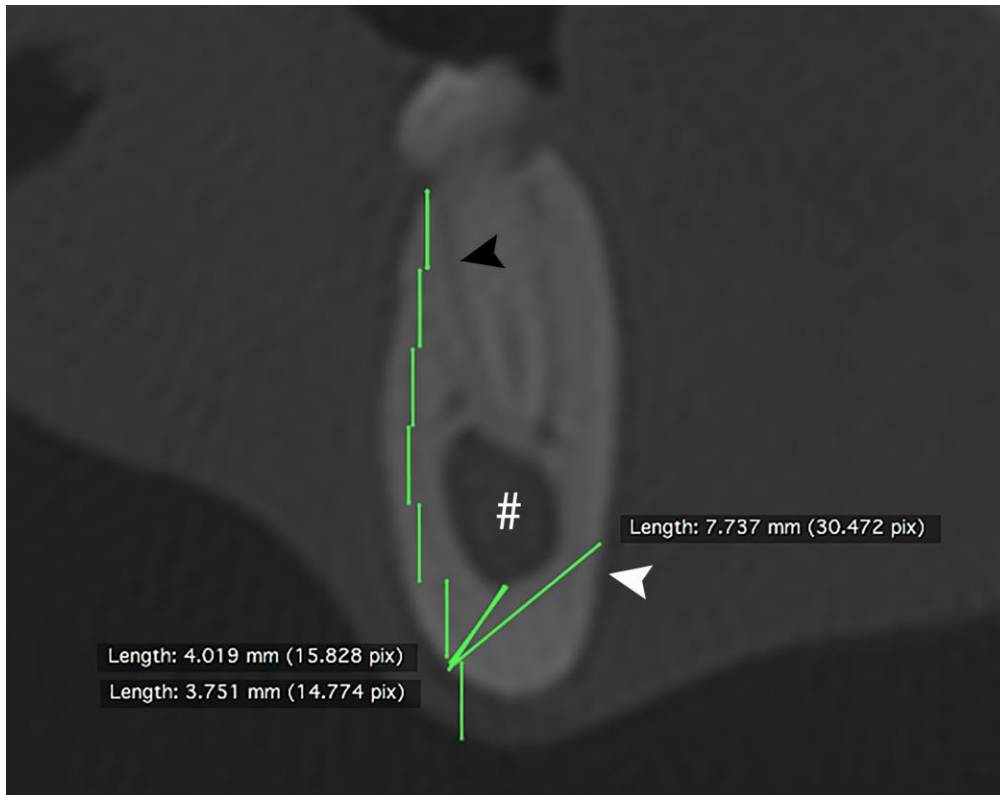
**Figure 1** CT localizer (topogram) image of an anesthetized dog demonstrating study positioning with the neck extended to allow orientation of the ventral border of the mandibles parallel to the CT tabletop and permit image acquisition through the vertical axis of the teeth.



**Figure 2** Schematic indicating locations for profile images chosen to represent anatomical locations A) between teeth (black lines) and at the furcation between roots (blue lines), and B) overlying the mesial (green lines) and distal (purple lines) roots.

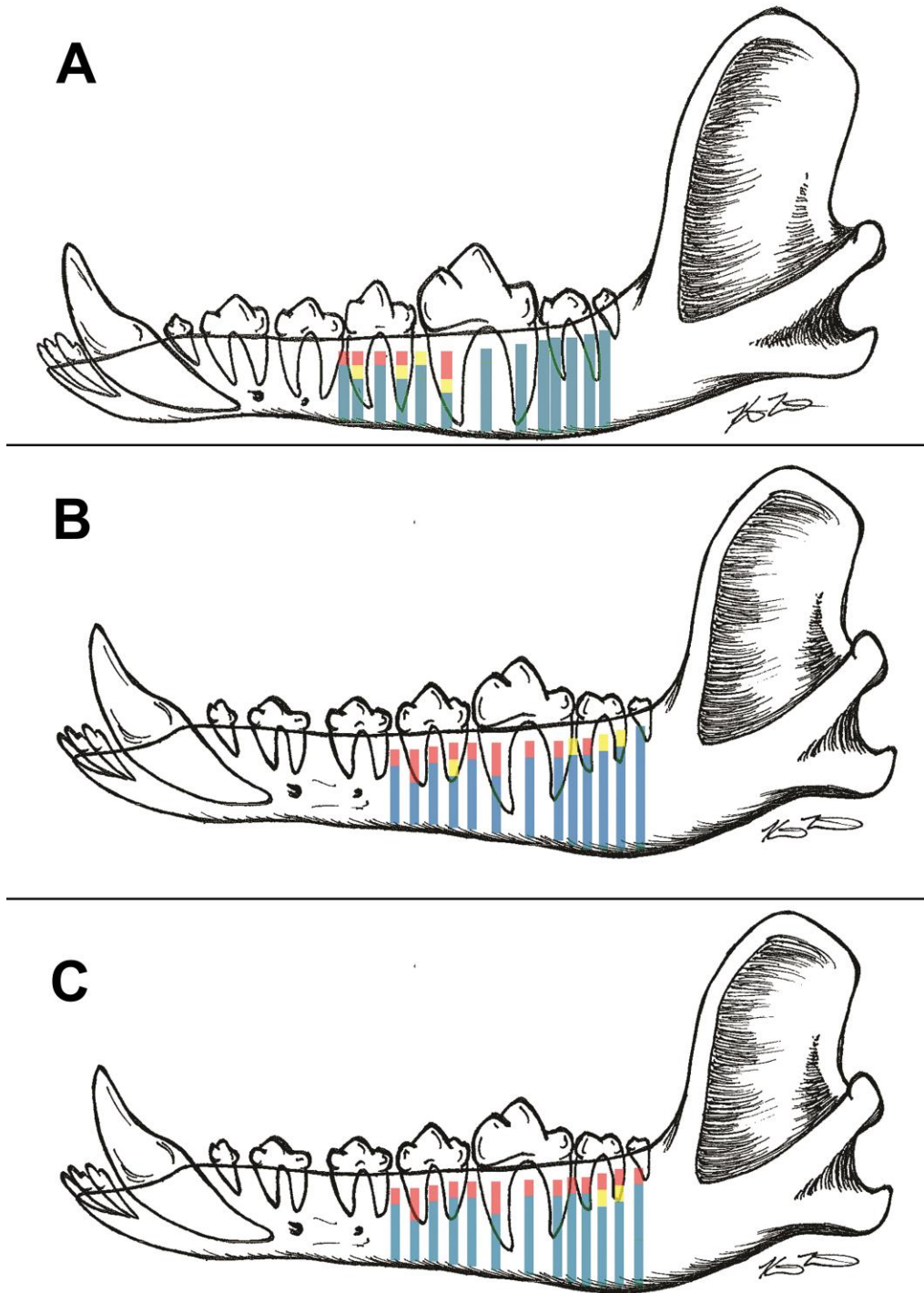


**Figure 3** Representative profile images through the furcation of the left mandibular 1st molar showing A) Region of interest (ROI) markers placed in a staggered fashion along the long axis of buccal cortical bone, and B) Investigator ROI measurements identifying the thickness of the buccal cortical bone plate at each predetermined spacing.



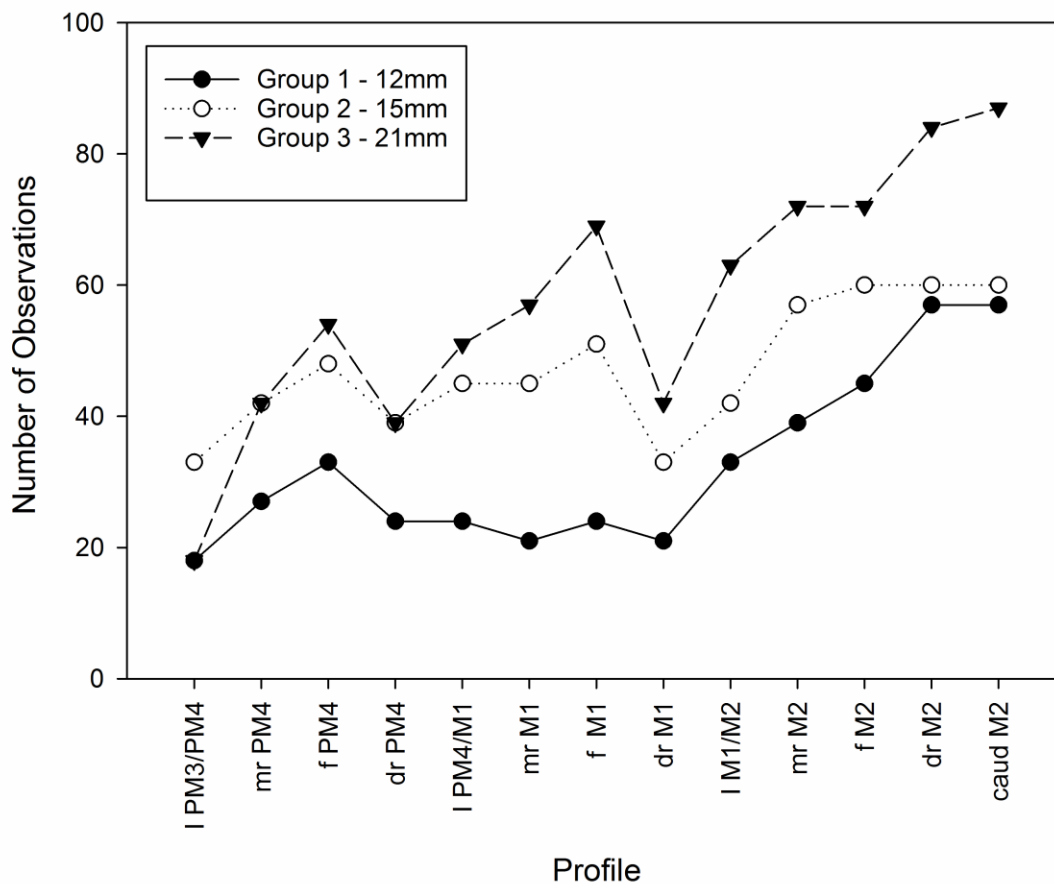
**Figure 4** Representative profile image extending through the distal root of M2 in a dog < 10 kg with all 3 investigator measurements applied to the same image for the most ventral measurement and variable investigator interpretation for measurement of cortical thickness. These measurements were discarded due to a SE of 1.29. Black arrowhead depicts periodontal ligament space, white arrowhead depicts lingual cortical bone margin and # demonstrates mandibular canal.





**Figure 5** Schematic of locations of cortical bone thickness for dogs < 10 kg (A), 10-20 kg (B), and > 20 kg (C). Red = bone thickness is <2.00 mm (95% CI). Yellow = bone thickness > or < 2.00mm. Blue = bone thickness >2.00mm.

## Changes in Bone Height



**Figure 6** Number of total recorded measurements as an estimate of mandibular bone height from each of 3 groups of dogs by weight demonstrating the location at which there was a large reduction in number of measurements recorded. The depth from the alveolar margin at which the decrease in observations varied between groups and is indicated in the legend.