

RVC OPEN ACCESS REPOSITORY – COPYRIGHT NOTICE

This is the peer reviewed version of the following article:

SCUDDER, C., KENNY, P. & NIESSEN, S. 2015. Treatment of canine and feline hyperadrenocorticism: trilostane and the alternatives. *Companion Animal*, 20, 230-238.

which has been published in final form at <http://dx.doi.org/10.12968/coan.2015.20.4.230>.

This article may be used for non-commercial purposes in accordance with [Wiley Terms and Conditions for Self-Archiving](#)."

The full details of the published version of the article are as follows:

TITLE: Treatment of canine and feline hyperadrenocorticism: trilostane and the alternatives

AUTHORS: **Mr Christopher Scudder** BVSc MVetMed MRCVS. Veterinary Researcher, RVC and **Mr Patrick Kenny** BVSc Dip ACVIM (Neurology) DipECVN FHEA MRCVS, Head of Neurology and Neurosurgery, RVC at Department of Clinical Science and Services, Royal Veterinary College, North Mymms, UK. **Dr Stijn Niessen** DVM PhD DipECVIM-CA MRCVS, Co-Head of Small Animal Internal Medicine, RVC. Diabetes Research Group, Medical School, University of Newcastle, Newcastle, Tyne and Wear, UK

JOURNAL TITLE: *Companion Animal*

VOLUME/EDITION: 20/4

PUBLISHER: Wiley

PUBLICATION DATE: 9 April 2015 (online)

DOI: 10.12968/coan.2015.20.4.230

Treatment of canine and feline hyperadrenocorticism: trilostane and the alternatives

Mr Christopher Scudder BVSc MVetMed MRCVS. Veterinary Researcher, RVC and

Mr Patrick Kenny BVSc Dip ACVIM (Neurology) DipECVN FHEA MRCVS, Head of Neurology and Neurosurgery, RVC at Department of Clinical Science and Services, Royal Veterinary College, North Mymms, UK.

Dr Stijn Niessen DVM PhD DipECVIM-CA MRCVS, Co-Head of Small Animal Internal Medicine, RVC. Diabetes Research Group, Medical School, University of Newcastle, Newcastle, Tyne and Wear, UK

Abstract: The common causes of hyperadrenocorticism (HAC) are pituitary ACTH-secreting corticotroph tumours, known as pituitary-dependent hyperadrenocorticism, and cortisol-secreting adrenal tumours. The only licensed medical treatment in the UK is trilostane. This treatment improves the clinical signs of HAC in the majority of cats and dogs. There are a number of alternative treatment options that are available for use in non-responders or as first-line treatment instead of trilostane. After a diagnosis of HAC is made, each option should be discussed with clients. This article discusses medical, surgical and radiotherapy options that should be considered to create an individualised treatment plan for each patient and owner.

The common causes of hyperadrenocorticism (HAC) are pituitary ACTH-secreting corticotroph tumours, known as pituitary-dependent hyperadrenocorticism (PDH), and cortisol-secreting adrenal tumours (ATs) which can either be adenomas or carcinomas. There are rare reports of dogs having ectopic ACTH syndrome caused by non-pituitary ACTH-secreting tumours, and food-dependent HAC. The common clinical signs of hyperadrenocorticism (HAC) are polydipsia, polyuria, polyphagia and panting (Behrend et al, 2013). The American College of Veterinary Internal Medicine has published a consensus statement on the diagnosis of HAC in dogs, and there are many excellent reviews on this topic (Kooistra and Galac, 2010; Melian et al, 2010; Behrend et al, 2013; Behrend, 2015).

Pituitary tumours are the cause of HAC in 75 to 85% of canine and feline HAC cases, and it is most commonly caused by an adenoma (Hoenig, 2002; Kooistra and Galac, 2010; Valentin et al, 2013). Pituitary tumours can be categorised in several ways, for instance micro- or macro-, functional or non-functional and adenoma or carcinoma. Macroadenomas often protrude out of the bony indentation that houses the pituitary at the base of the brain, the sella turcica, and are >10 mm, although classification based on a cut-off size of 10 mm has questionable utility in veterinary medicine (Meij et al, 2002; Wood et al, 2007). In addition to the common clinical signs of HAC, pituitary macroadenomas may cause central blindness or neurological disease, secondary to a space-occupying lesion effect (Goossens et al, 1998; Wood et al, 2007). There are a number of different treatment options for PDH and ATs, and clinicians should individualise treatment according to the specific presentation of the animal and preference of the owner. The age of the animal at diagnosis and long-term costs are some of the factors that should be considered.

Medical Management

Trilostane (Vetoryl, Dechra, Shrewsbury, UK) has been shown to be extremely useful in the management of PDH. One of the mechanisms of actions is the inhibition of 3- β hydroxysteroid dehydrogenase, an essential enzyme during steroidogenesis in the adrenal gland. Trilostane has been shown to impressively improve the clinical signs of HAC in 86% and between 67 to 100% of cats and dogs, respectively (Ramsey, 2010; Mellett Keith et al, 2013). Trilostane is sold as 10 mg, 30 mg, 60 mg and 120 mg hard capsules, is recommended by many as a preferred treatment modality, and is the only licensed drug to treat canine HAC in the UK. Trilostane is rapidly absorbed from the gastrointestinal tract after oral administration, and bioavailability is improved when given with food. Peak serum concentrations of trilostane and the primary active metabolite, ketotrilostane, occur 30 to 90 minutes after oral administration, and peak serum cortisol reduction occurs between four to six hours after administration (Vetoryl datasheet, Dechra, Shrewsbury, UK). A starting dose of 2–5 mg/kg/day is recommended, and the addition of a 10 mg capsule to the product range has made prescription of these doses more practical (Ramsey, 2010).

Patient monitoring is performed as recommended by the data-sheet, and dose alterations prescribed gradually to achieve control of clinical signs and biochemical control. The monitoring of trilostane-treated hyperadrenocorticoid dogs is challenging if the supply of synthetic ACTH is restricted. Recent studies have investigated the use of serum cortisol and serum cortisol to endogenous plasma ACTH ratio to monitor patients during trilostane therapy (Cook and Bond, 2010; Burkhardt et al, 2013). Serum cortisol, measured two to three hours post-trilostane administration, above 28 mmol/l excluded excessive suppression in 97% of dogs, and four to six hour post-trilostane administration serum cortisol concentrations above 36 mmol/l excluded excessive cortisol suppression in 98% of dogs (Cook and Bond, 2010; Burkhardt et al, 2013). Three-hour post-trilostane administration serum cortisol concentration

>120 mmol/l was an indicator of inadequate control, and four to six hours post-trilostane administration below 80 mmol/l excluded inadequate control in 95% of dogs (Cook and Bond, 2010; Burkhardt et al, 2013). However, the authors of the study concluded that endogenous ACTH or serum cortisol to endogenous ACTH concentrations did not adequately distinguish between excessively, adequately, and inadequately controlled dogs and should not be used instead of an ACTH stimulation test to monitor trilostane therapy (Burkhardt et al, 2013). One attractive alternative to measuring serum cortisol would be the measurement of urine cortisol or corticoid to creatinine ratios (UCCR). However, the majority of hyperadrenocorticoid dogs treated with trilostane for two months did not achieve normalisation of their UCCR, possibly because of the measurement of cortisol precursors that continue to be synthesised during trilostane therapy (Galac et al, 2009). Therefore, the UCCR test cannot be used as a monitoring tool for trilostane treatment. The authors recommend basal serum cortisol and electrolyte concentrations are measured if a patient becomes unwell during therapy, and medication is temporarily discontinued while awaiting results. The patient can be prescribed 0.2 mg/kg prednisolone and receive supportive care if sick enough to require hospitalisation. A lymphocyte count could be performed while awaiting the endocrine test results as patients are highly unlikely to have hypoadrenocorticism if their lymphocyte count is $<0.75 \times 10^9/l$ (Seth et al, 2011). The patient should restart trilostane at half the previous dose when clinically well and basal cortisol is >28 mmol/l. A trilostane dose increase should be considered if a patient continues to exhibit clinical signs consistent with hyperadrenocorticism and basal cortisol is >28 mmol/l, but a slow and gradual dose increase should be prescribed.

A proportion of dogs do not respond completely during once-daily trilostane therapy. Twice- or three times daily therapy could be prescribed on a trial basis based on the rationale that trilostane may not induce cortisol reduction for 24 hours. Twice-daily therapy is generally well tolerated and often improves the clinical signs of dogs affected by PDH and AT (Alenza et al, 2006; Feldman, 2008; Arenas et al, 2013). There are several disadvantages of trilostane for the management of HAC. Although HAC is typically a disease of the older dog, long-term use can prove expensive, especially in large dogs and those diagnosed at a young age. Dose adjustments and frequent blood test monitoring can add to the

long-term financial cost for owners. Adverse drug effects are common, occurring in 10 to 40% of patients treated either one or twice daily. (Alenza et al, 2006; Arenas et al, 2013). Side effects are typically mild, and include gastrointestinal upset and lethargy, which may improve following dose reduction. However, rare cases of iatrogenic adrenal necrosis and subsequent hypoadrenocorticism have been reported. These are thought to be related to the increased endogenous ACTH levels causing increased adrenal blood flow, causing in turn a higher chance of adrenal haemorrhage, given the fragile nature of adrenal vessels. Trilostane treatment also leaves the inciting cause untouched. The possibility that a pituitary tumour could continue to grow, and cause secondary space-occupying disease, should be a consideration at the time of diagnosis.

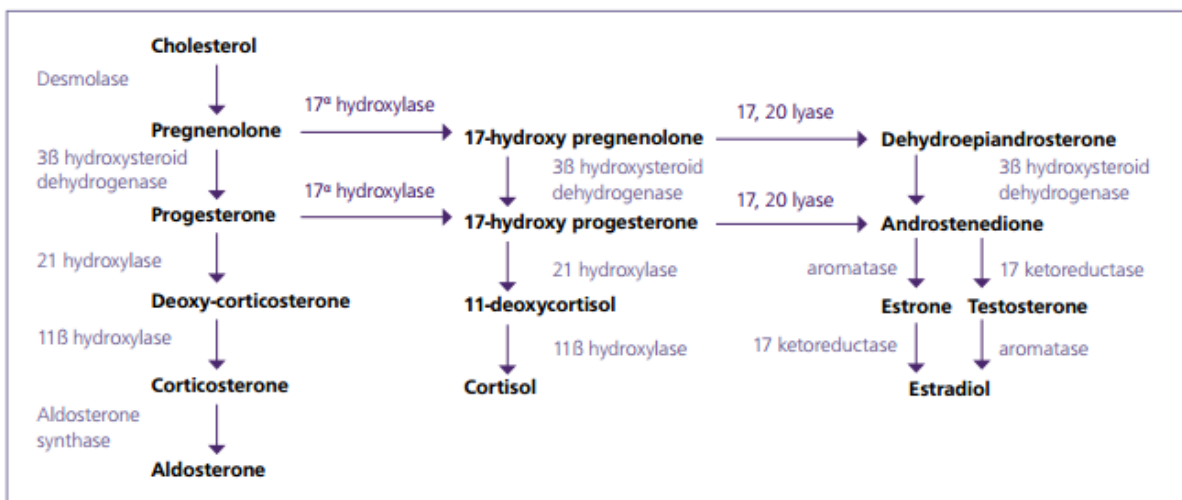


Figure 1: Adrenal gland steroid hormone biochemical pathways

There is a general paucity of information regarding using trilostane to treat feline HAC. The first report was in 2003, which described a good clinical response to 30 mg twice-daily trilostane therapy, and this dose appeared to be well tolerated (Skelly et al, 2003). Three subsequent case series report the response to trilostane therapy in five, nine and 15 cats (Neiger et al, 2004; Mellett Keith et al, 2013; Valentin et al, 2014). Therapy was typically well tolerated and associated with good long-term survival in many cases. However, up to 90% of feline HAC patients have concurrent diabetes mellitus, which is likely secondary to cortisol-induced insulin resistance (Graves, 2010). Trilostane therapy reduced insulin requirements in 6/9 diabetic HAC cats in one study, and this was only a 36% reduction, while another study reported insulin doses were not reduced in any of the five diabetic HAC cats treated (Neiger et al, 2004; Mellett Keith et al, 2013). As insulin dose decrease has been considered an indicator of response to HAC treatment, unchanged insulin requirement suggests inadequate control of hypercortisolaemia, or permanent exocrine pancreatic disease (Valentin et al, 2014).

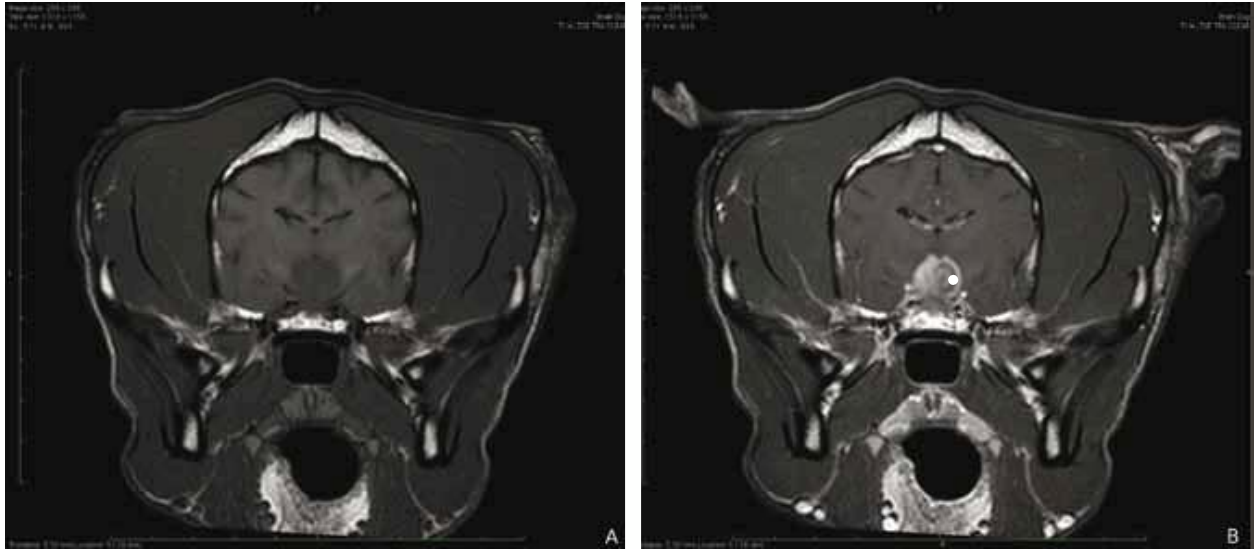

Figure 2. Use of contrast-enhanced T1-weighted MRI to aid diagnosis of a pituitary enlargement in a dog with hyperadrenocorticism; (a) pre-contrast enhanced T1-weighted intra-cranial MRI; (b) post-gadolinium contrast enhanced T1-weighted intra-cranial MRI.

The Veterinary Medicines Regulations allows UK veterinarians to prescribe medications for use other than the authorised use if there are no licenced products or if the licenced product is unsuitable. Prescription of a non-licenced product should be considered if a patient experiences significant adverse drug effects or the licenced product is ineffective at controlling the disease. Veterinary surgeons should consider the reliability of the original diagnosis of HAC before prescription of an alternative medication, because nearly 90% of hyperadrenocorticoid dogs experience rapid clinical improvement during trilostane treatment.

Mitotane (Lysodren, HRA Pharma UK and Ireland Limited, London, UK) is a prescription-only medicine licensed for the symptomatic treatment of advanced adrenal cortical carcinoma in humans. The complete mechanism of action of mitotane is unknown, however it is primarily adrenolytic, by induction of free radicals, and inhibits 11β hydroxylase and desmolase in the adrenal gland, thereby reduce steroid synthesis (Figure 1) (Veytsman et al, 2009). This drug successfully improves clinical signs of HAC in up to 87% of dogs and 50% of cats, but mitotane-associated side-effects occur in up to 42% dogs, and clinical relapse following dose adjustments is common (Lorenz, 1982; Nelson et al, 1988; Kintzer and Peterson, 1991; Schwedes, 1997). The common side-effects are gastrointestinal signs (vomiting, anorexia and diarrhoea) or weakness. Mitotane can be used for two different treatment strategies: it can be given life-long with gradual dose adjustment to effect, or for a short period of time for the induction of permanent hypoadrenocorticism. Mitotane can be considered for patients who do not respond to, or experience adverse drug effects during, trilostane therapy, and for those with metastatic AT.

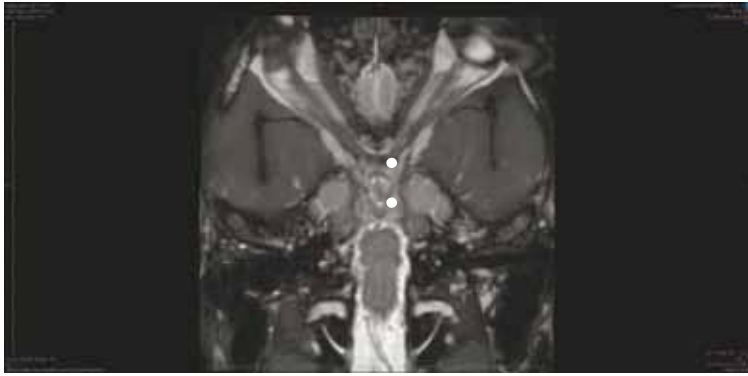

Figure 3: Dorsal view of a T2-weighted intra-cranial MRI to show the location of the optic chiasm and pituitary gland. Optic chiasm compression could be caused by a pituitary macroadenoma.

Life-long therapy is prescribed as an initial ‘loading-phase’ typically over eight days, followed by a ‘maintenance phase’. The average maintenance weekly dose of mitotane in one study of 184 dogs was 71 mg/kg, but relapse of clinical signs was common using this protocol, with around 50% of dogs experiencing clinical relapse within the first year of therapy, and the loading phase may need to be repeated in this scenario (Kintzer and Peterson, 1991).

Adrenolytic protocols require giving higher doses of mitotane daily (typically doses of 50 to 100 mg/kg/day given in three or four doses per day) for 25 consecutive days (Rijnberk and Belshaw, 1988; Feldman and Nelson, 2004; Clemente et al, 2007). Concurrent glucocorticoid and mineralocorticoid supplementation is started on day three of therapy. These ‘higher-dose’ protocols have been successful at achieving control of HAC-associated clinical signs, and have a median survival time of 720 days and three year survival fraction of 60% (den Hertog et al, 1999; Clemente et al, 2007). The potential side effects of these protocols, expense of treatment of hypoadrenocorticism (particularly in the USA), and risk of fatal consequences of poorly-treated hypoadrenocorticism, has caused some clinicians to discourage its use (Behrend, 2015).

The adrenolytic protocols have a reported mortality rate of 5 to 10% within the first 25 days of therapy, although these figures may over-estimate the risk, as some of the patients had significant concurrent disease at the time of diagnosis; 10 to 40% of incidence of gastrointestinal upset; and 30 to 40% incidence of disease relapse (den Hertog et al, 1999; Clemente et al, 2007).

The use of mitotane in cats has been discouraged due to the feline sensitivity to chlorinated hydrocarbons and reports of serious side-effects and poor response to treatment (Duesberg and Peterson, 1997; Nelson et al, 1988). There are reports of mitotane therapy achieving clinical control of feline HAC, however trilostane appears to be a more advantageous medical management option in cats (Schweddes, 1997).

Trilostane versus mitotane studies have been reported. Possibly the most applicable study to the UK veterinary surgeon is the study by Barker et al (2005), which reported median survival times of 662 days and 708 days for trilostane treated and life-long mitotane therapy treated PDH respectively. Twice-daily trilostane appeared to have a more favourable outcome for the treatment of PDH compared to a

mitotane adrenolytic protocol, having median survival times of 900 days and 720 days, respectively (Clemente et al, 2007). Both trilostane and mitotane have been used to treat AT and no study to date has reported significantly different survival times for either drug (Helm et al, 2011; Arenas et al, 2014).

Several prognostic factors have been proposed when using trilostane or mitotane therapy. Older age and heavier weight are negative prognostic factors reported in several studies; higher one hour post-ACTH serum cortisol, weakness at presentation, hyperphosphataemia and severity of clinical signs have also been reported as negative prognostic indicators (Kintzer and Peterson, 1991; Barker et al, 2005; Clemente et al, 2007; Arenas et al, 2014; Fracassi et al, 2014).

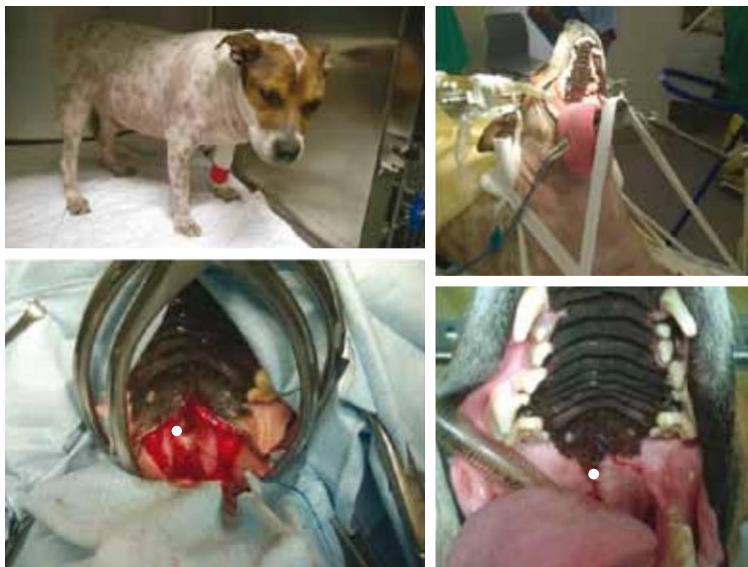

Figure 4. (a) Photograph of a dog with pituitary-dependent hyperadrenocorticism; (b) The same dog under general anaesthesia placed in sternal recumbency and head placed in a surgical head brace to maintain an elevated head position; (c) The soft palate has been incised and retracted. The pituitary fossa has been exposed after burring the basisphenoid and presphenoid bones; (d) The soft palate has been closed using absorbable suture material.

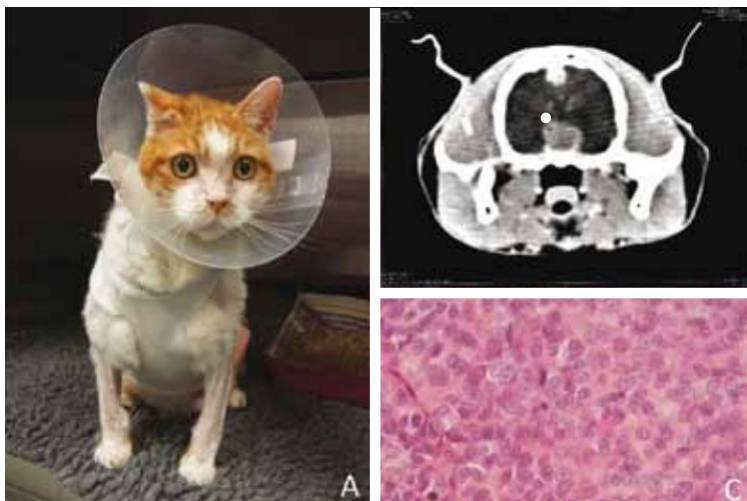

Figure 5. (a) Photograph of a cat with a diagnosis of pituitary-dependent hyperadrenocorticism; (b) Contrast enhanced computed tomography of the same cat showing pituitary enlargement; (c) Photomicrograph showing haematoxylin and eosin staining of the pituitary tissue collected during the hypophysectomy surgery of the same cat. The cells are polygonal and exhibit the eosinophilic cytoplasm that is typical of corticotropes.

There are a small number of studies reporting use of alternative drugs to manage HAC. Ketoconazole is likely to have several cortisol synthesis-inhibiting mechanisms of action, including general inhibition of P450 enzymes and 11 β hydroxylase (Loose et al, 1983; Loli et al, 1986). However, its efficacy is underwhelming, especially in light of better medical options being available, despite some reports suggesting it to be relatively effective, with improvement of HAC-associated clinical signs in 43 of 48 dogs and survival times comparable to mitotane and trilostane (median survival 810 vs 622 to 852 days, respectively) (Barker et al, 2005; Lien and Huang, 2008; Fracassi et al, 2014). Idiosyncratic ketoconazole-induced hepato- and other toxicity appear to be rare, but therapy is commonly associated with gastrointestinal upset (Lien and Huang, 2008; Mayer et al, 2008).

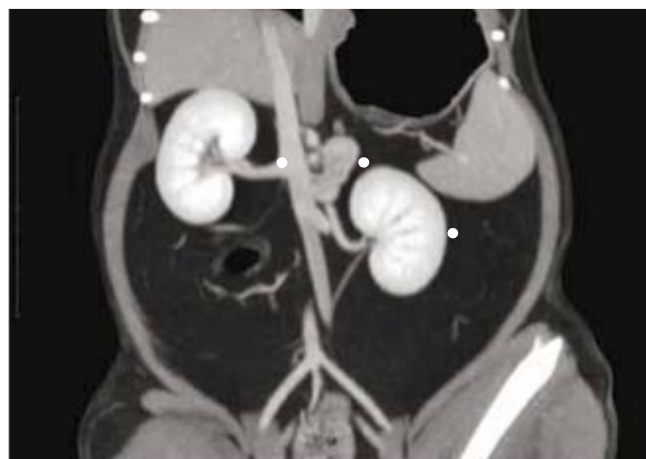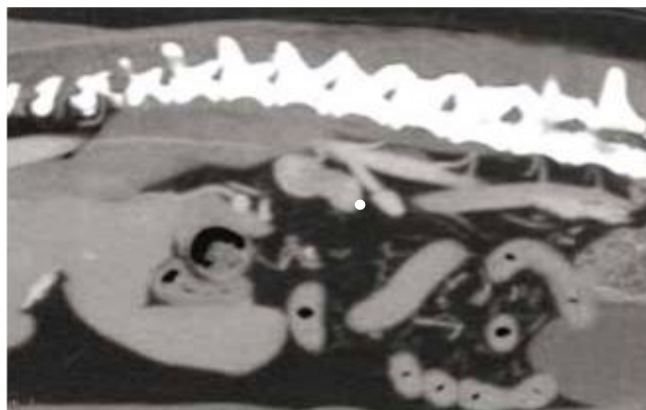

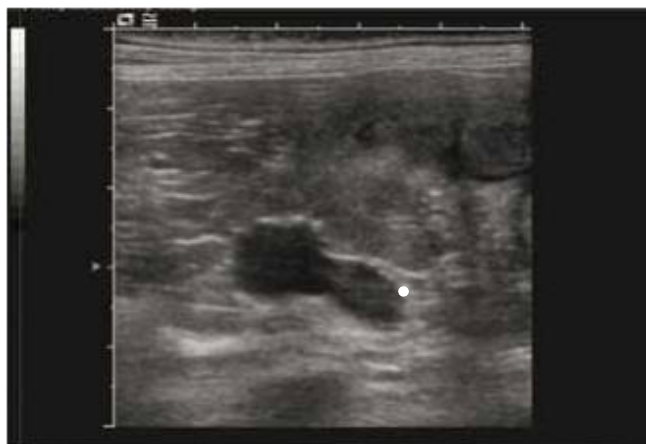
Figure 6. (a) Ultrasound image of an enlarged adrenal gland. The gland has the characteristic 'peanut' shape but is enlarged at the cranial aspect; (b) A sagittal image of contrast-enhanced abdominal computed tomography identifying an enlarged adrenal gland; (c) A dorsal image of contrast-enhanced abdominal computed tomography. This is the same adrenal gland as in 4b, showing the relationship of the adrenal gland to the kidneys and caudal vena cava.

Metyrapone inhibits the conversion of 11-deoxycortisol to cortisol, and successfully improved HAC clinical signs prior to bilateral adrenalectomy in two cats, but reports in dogs are lacking (Daley et al, 1993; Moore et al, 2000). In summary, trilostane is the medical management option of choice for the UK veterinarian, and mitotane is an appropriate second line therapy. Other medical management options are often either less effective or more frequently associated with detrimental side-effects.

Surgical Management

Hypophysectomy

Hypophysectomy (surgical extirpation of the hypophysis/pituitary gland) is the only curative procedure for PDH. Around 75% of patients achieve long-term cure, but the remainder of patients experience disease recurrence or residual disease post-surgery (Hanson et al, 2005). Surgical debulking of larger pituitary tumours can improve or resolve neurological deficits caused by compression of the adjacent brain (Figures 2 and 3 reveal the location of the pituitary gland and relationship to the adjacent brain and optic nerves). This treatment option is available in the UK; it should be performed by an experienced surgeon in a facility capable of providing the intensive intra- and post-operative care required by these patients. Although a financial investment is required up front, subsequent medical management (hormonal replacement) over the long term is comparatively less expensive. Both factors are of relevance when considering younger animals diagnosed with hyperadrenocorticism. Additionally, there is a reasonable chance (approximately 20%) that without surgery the pituitary tumour will grow large enough to cause clinical signs and shortened life span (Kipperman et al, 1992; Bertoy et al, 1996; Ihle, 1997; Kent et al, 2007).

Hypophysectomy is by no means a new procedure: the first canine hypophysectomy was performed in 1886, and later refined by Aschner in 1912. Since these early reports, there have been several techniques described, including the transbuccal approach (Essex and Astrabadi, 1953), transoral approach following mandibular symphysiotomy (Henry and Hulse, 1982), and ventral paramedian approach between the larynx and mandibular ramus (Axlund et al, 2005). These techniques have been largely superseded by the transoral approach described by Meij et al (1997; 2001). The patient is positioned in sternal recumbency and the head elevated with mouth open. The skull-base is accessed by a soft palate incision and the bone ventral to the hypophyseal fossa is removed using a rotating burr (Meij et al, 1998). The approach is guided by referencing bony landmarks and reconstructions of pre-operative computed tomography images. When the pituitary gland is exposed, the dura mater is incised and the pituitary gland extirpated using fine surgical tools. The skull defect is closed using either bone wax or collagen sponge, and the soft palate is closed using absorbable suture material in two layers (Figure 4). Medical care of the patient during the intra- and post-operative period centres on glycaemic and free-water control, initially cortisol and later also thyroxine supplementation. A two-week course of broad-spectrum bacteriocidal antibiotics is prescribed, because the surgery is performed transorally.

Cortisol and thyroxine supplementation are life-long and titrated to effect. The hypothalamus synthesises vasopressin, which is normally transported to the posterior pituitary via the hypothalamic-neurohypophyseal tract. Desmopressin (DDAVP) is prescribed to manage free-water control but, depending on the exact location of the pituitary stalk excision, remaining neurones in the hypothalamic-neurohypophyseal tract may be able to release vasopressin. Around 80% of patients can be weaned off desmopressin over the weeks to months following surgery, however 20% develop permanent central diabetes insipidus and require life-long desmopressin therapy (Hanson et al, 2005). Insulin therapy is titrated to effect and can often be reduced or discontinued as hypercortisolaemia-induced insulin-resistance resolves, if patients are diabetic at the time of presentation.

The acute surgical mortality rate of humans who had Cushing's disease and were treated by transphenoidal adenectomy was 0 to 1.9%; remission rates were between 69 to 98% and were associated with tumour size and invasiveness (Kelly, 2007). Post-operative basal cortisol was a predictor of disease remission in this review. A report of 150 canine hypophysectomy surgeries for the treatment of PDH described an 8% post-operative mortality rate, with the majority of these patients being in the early cohort following the development of their hypophysectomy clinic (Hanson et al, 2005). Their one-, two-, three- and four-year estimated survival rates were 84%, 76%, 72% and 68%, respectively. Survival and disease-free fraction was lower in patients with pituitary height to brain area ratio >0.31 , and a later study from the same group described older age, larger pituitary size and increased basal plasma ACTH concentration as risk factors for post-operative survival (Hanson et al, 2007). Pre-operative urine cortisol to creatinine ratio was a predictor for disease recurrence, and post-operative urine cortisol to creatinine ratio measured six to 10 weeks after surgery was a predictor for disease remission and survival.

Feline hypophysectomy has been described in two case series, and the techniques used are similar to canine hypophysectomy (Figure 5). In the first, hypophysectomy was performed on seven hyperadrenocorticoid cats: two died within two weeks of surgery, and the remaining five achieved disease remission (Meij et al, 2001). A more recent abstract reported the treatment of twelve cats with hypersomatotropism and diabetes mellitus by hypophysectomy: two cats died perioperatively; of the surviving ten cats, seven went into complete diabetic remission, and three into partial remission (Kenny et al, 2015).

Keratoconjunctivitis sicca (KCS) and persistent diabetes insipidus can occur after canine and feline hypophysectomy surgery. KCS affects a third of dogs post-operatively and although the majority completely recover, 20% of these dogs have persistently low tear production (Hanson et al, 2005). Hormone supplementation and monitoring of thyroxine is needed, since pituitary adenectomy without total hypophysectomy is rarely possible.

In summary, hypophysectomy provides a surgical alternative to medical palliation of PDH. Around 75% of treated patients achieve disease cure without recurrence. Life-long post-operative hormone supplementation is required and should be discussed with owners considering this option.

Adrenalectomy

Bilateral adrenalectomy (BA) is the treatment of choice for bi-lateral AT. BA is more widely available than is hypophysectomy, and should be considered as a possible option for the treatment of PDH. There are cases of ectopic ACTH production causing HAC in humans and a single case report exists of this disease in dogs; BA or medical management are appropriate in these cases if the primary tumour cannot be found or excised (Galac et al, Naan et al, 2013; Andrade et al, 2014). Patients will need life-long glucocorticoid and mineralocorticoid supplementation, and to be monitored in a similar manner to a patient with naturally occurring hypoadrenocorticism. As hypoadrenocorticism is more easily managed than hyperadrenocorticism, this remains an attractive alternative.

A recent systemic review of BA for human AT revealed low surgical mortality (3%) and a good rate of resolution of clinical signs, but 43% of patients died due to thromboembolic disease (such as stroke or myocardial infarction), progressive disease or other cause within 12 months following surgery (Ritzel et al,

2013). A case series of eight cats that underwent BA for PDH has been described (Duesberg et al, 1995). Three of the eight cats died within three weeks of surgery from complications that could have been attributed to HAC induced disease and surgical complications. The clinical signs of the remaining five cats resolved by four months post-surgery, but some cats continued to require insulin therapy. There are case reports of bilateral adrenalectomy in dogs, but to the authors' knowledge a large case-series has not been reported (Anderson et al, 2001; Hanson et al, 2007; Lang et al, 2011).

Unilateral adrenalectomy is the treatment of choice in patients with AT, and may be followed by chemotherapy in patients with metastatic disease (Figure 6 reveals the adrenal enlargement). Table 1 summarises the findings of studies reporting case series of adrenalectomy in patients having AT. There are a number of different prognostic factors and survival times reported, and it should be noted that different surgical techniques, surgical expertise and post-operative care protocols will have influenced outcomes. There are no large case series of unilateral adrenalectomy for the treatment of feline AT, though a recent case series of 10 cats that underwent adrenalectomy for adrenal-dependent hyperaldosteronism revealed good post-operative recovery. Two of these 10 cats were euthanized due to consequences of surgery, and the remaining eight cats had good long-term survival (Lo et al, 2014). Although these cats will have a different metabolic derangement profile to cats having AT, this study suggests that it is possible to perform unilateral adrenalectomy safely in this species.

In summary, adrenalectomy is the treatment of choice for AT. Patients undergoing bilateral adrenalectomy will require life-long management of hypoadrenocorticism.

Table 1. Summaries of studies of adrenalectomy in dogs with cortisol-secreting adrenal tumours

Reference	Number	Procedure/ disease	Survival	Complications (number of patients)							Prognostic factors
				Died	Intra-op	Pancreatitis	CVR	Renal	GIT	Other	
Scavelli et al, 1986	25 dogs	All unilateral; 24 ventral midline, 1 paracostal, 11 adenomas, 14	Adenoma: 3 survive \geq 24 months; carcinoma: 2 survive \geq 24 months	12		1	7	1		1	Negative: possible AT carcinoma
van Sluijs et al, 1995	36 dogs	33 unilateral and 3 bilateral	40% probability of survival at 1 200 days	10		3		1		6	
Anderson et al, 2001	21 dogs	18 unilateral and 3 bilateral; 4 adenomas and 20 carcinomas	Adenoma MST not reached; if carcinoma patient survived first 14 days, survival time 992 days	5		1	1	1	1	1	None
Kyles et al, 2003	40 dogs	37 unilateral and 3 bilateral 28 AT, 11 pheo, 1 no diagnosis	MST not reached for adrenalectomy alone; MST c. 6–8 months	9	4	1	8	1	3	5	
Schwartz et al, 2008	41 dogs	Unilateral adrenalectomy; 19 carcinoma 14	MST carcinoma was 230 days; MST adenoma	4	2	3		5		10	Negative: pre-operative hypokalaemia, azotaemia, kidney disease
Lang et al, 2011	60 dogs	59 unilateral and 1 bilateral; 15 adenoma, 26 carcinoma, 6	If survive peri-operative period: 492 days	7			21		7		Negative: acute adrenal haemorrhage; each 1 mm increase in tumour size increased perioperative mortality by
Massari et al, 2011	52 dogs	25 adenomas, 18 carcinomas, 7 pheo, 1 other	All-dog survival was 953 days		1	1	4			2	Negative: tumour size \geq 5, metastatic disease, vein thrombosis
Barrera et al, 2013	86 dogs	14 adenoma and 45 carcinoma, 27 pheo	All adenoma patients survived; MST carcinoma 48 months; MST pheo not reached	22	53	8	31	6	31	12	Negative: presence of extensive vena cava thrombus, but not tumour type
Mayhew et al, 2014	48 dogs	19 adenoma and 27 carcinoma	Short-term follow-up only	2		1	6			1	

AT = Adrenal tumour; CVR = Cardiovascular/respiratory; GIT = gastro-intestinal; MST = median survival time; op = operation;

Radiotherapy

Radiotherapy is considered an effective second line therapy for human PDH. Radiotherapy is prescribed for human patients unsuitable for hypophysectomy, or for those who experience disease persistence following hypophysectomy. Radiotherapy improves survival in patients with pituitary masses, and the

response to radiotherapy and survival following treatment is negatively correlated with the ratio of tumour size to brain height (Theon et al, 1998; Kent et al, 2007).

Fractionated external beam radiotherapy has been used to treat canine pituitary macroadenomas since 1985. The first report of radiotherapy improving the neurological disease caused by a PDH macrotumour was in 1990 (Dow et al, 1990). Dogs received 10 fractions of 4 Gy (40 Gy total dose) over 22 days. Neurological status improved within three months and pituitary tumour volume reduced by 50% every six months for at least one year. Side effects were regional hair depigmentation, reduced hearing or deafness, keratoconjunctivitis sicca, and temporary vestibular syndrome; one dog started to seizure 17 months later and another developed unilateral trigeminal neuropathy nearly 30 months later. However, biochemical control of PDH following radiotherapy has been poor, and continued medical management has been necessary (Goossens et al, 1998; Theon et al, 1998). Fractionated radiotherapy can improve the diabetic control of cats with PDH, but, as in dogs, does not lead to normalisation of cortisol secretion (Mayer et al, 2006).

Stereotactic radiosurgery, performed by delivering a single dose of radiotherapy to a defined target area, has been performed in dogs with pituitary neoplasia, but the ability of this treatment to control canine PDH is not yet known (Mariani et al, 2013). Stereotactic radiosurgery for PDH has been reported in two cats. One cat was receiving concurrent trilostane and experienced clinical improvement within nine months after radiosurgery; the other cat was euthanised two months after treatment due to suspected abdominal neoplasia. Larger studies are needed to understand the role that radiosurgery could have in the management of PDH.

In summary, radiotherapy can play a limited role in the management of hyperadrenocorticism. It appears most useful to shrink the pituitary tumour, but seems less useful to achieve hormonal normalisation.

Malignant neoplasms

Pituitary carcinomas are rare; adenomas are most commonly encountered. They are defined by metastatic behaviour rather than by invasive or histopathology characteristics in human endocrinology (Kaltsas et al, 2005). The treatment of humans affected by pituitary carcinomas is mainly palliative. The incidence of this type of tumour in veterinary species is not known, nor is the most appropriate treatment protocol. Treatment would likely involve a combination of surgery, radiotherapy and medical treatments including cytotoxic chemotherapy, in an attempt to improve quality of life. However, euthanasia should be considered if the patient's quality of life does not improve in response to therapy.

Adrenal tumour invasion and/or metastatic disease are used to differentiate adrenal cortical adenomas from carcinoma in human pathology, and an adrenal mass ≥ 2 cm is likely to be malignant in canine medicine (Cook et al, 2014). In the absence of these features, the Weiss system, which assesses nine different histopathological features, is commonly used in human pathology to assess adrenal tumour malignancy (Weiss, 1984). Adrenal carcinomas should be excised if possible, because this is positively correlated with survival in humans (Fulmer, 2007). Metastatic disease is a negative prognostic factor, and adjuvant treatment with mitotane or mitotane plus cytotoxic chemotherapy may improve survival further (Helm et al, 2011).

The opinion of the authors is that veterinary patients are probably best monitored for the development of metastatic disease and receive treatment if/when this disease occurs. Cytotoxic chemotherapy typically has disappointing success as the primary and sole therapy for adrenal cortical neoplasia, and the benefits of adjuvant chemotherapy without metastatic disease do not outweigh possible side-effects.

In summary, surgical excision of malignant AT is an appropriate treatment option and can prove very satisfactory if performed at a time prior to metastatic disease. Malignant PDH is fortunately rare.

Conclusion

Trilostane is a good treatment option for many patients suffering from hyperadrenocorticism, but there is more to consider than trilostane treatment after a diagnosis of HAC has been made. Clinicians should encourage owners to invest in differentiating PDH from AT. Additionally, the full range of treatment options should be discussed, so that therapy is tailored to the individual patient and owner rather than the recommendation of a single therapy for all patients.

References:

- Alenza DP, Arenas C, Lopez ML, Melian C (2006) Long-term efficacy of trilostane administered twice daily in dogs with pituitary-dependent hyperadrenocorticism. *J Am Anim Hosp Assoc* 42: 269–76
- Anderson CR, Birchard SJ, Powers BE, Belandria GA, Kuntz CA, Withrow SJ (2001) Surgical treatment of adrenocortical tumors: 21 cases (1990-1996). *J Am Anim Hosp Assoc* 37: 93–7
- Andrade N, Rivas LR, Milovancev M, Radlinsky MA, Cornell K, Schmiedt C. (2014) Intercostal approach for right adrenalectomy in dogs. *Vet Surg* 43: 99–104
- Arenas C, Melián C, Pérez-Alenza MD (2013) Evaluation of 2 trilostane protocols for the treatment of canine pituitary-dependent hyperadrenocorticism: Twice daily versus once daily. *J Vet Intern Med* 27: 1478–85
- Arenas C, Melián C, Pérez-Alenza MD (2014) Long-term survival of dogs with adrenal-dependent hyperadrenocorticism: a comparison between mitotane and twice daily trilostane treatment. *J Vet Intern Med* 28: 473–80
- Axlund TW, Behrend EN, Sorjonen DC, Simpson ST, Kemppainen RJ (2005) Canine hypophysectomy using a ventral paramedian approach. *Vet Surg* 34: 179–89
- Barker EN, Campbell S, Tebb AJ (2005) A comparison of the survival times of dogs treated with mitotane or trilostane for pituitary-dependent hyperadrenocorticism. *J Vet Intern Med* 19: 810–5
- Barrera JS, Bernard F, Ehrhart EJ, Withrow SJ, Monnet E (2013) Evaluation of risk factors for outcome associated with adrenal gland tumors with or without invasion of the caudal vena cava and treated via adrenalectomy in dogs: 86 cases. *J Am Vet Med Assoc* 242: 1715–21
- Behrend EN (2015) Canine hyperadrenocorticism. In: Feldman EC, Nelson RW, Reusch CE, Scott-Moncrieff JCR, eds. *Canine and Feline Endocrinology*. 4th edn. Elsevier Saunders, St Louis, MO: 377–452
- Behrend EN, Kooistra HS, Nelson R, Reusch CE, Scott-Moncrieff JC (2013) Diagnosis of spontaneous canine hyperadrenocorticism: 2012 ACVIM consensus statement (small animal). *J Vet Intern Med* 27: 1292–304
- Bertoy EH, Feldman EC, Nelson RW, Dublin AB, Reid MH, Feldman MS (1996) One-year follow-up evaluation of magnetic resonance imaging of the brain in dogs with pituitary-dependent hyperadrenocorticism. *J Am Vet Med Assoc* 208: 1268–73
- Biller BMK, Grossman AB, Stewart PM et al (2008) Treatment of adrenocorticotropic hormone-dependent Cushing's syndrome: a consensus statement. *J Clin Endocrinol Metab* 93: 2454–62

- Burkhardt WA, Boretti FS, Reusch CE, Sieber-Ruckstuhl NS (2013) Evaluation of baseline cortisol, endogenous ACTH, and cortisol/ACTH ratio to monitor trilostane treatment in dogs with pituitary-dependent hypercortisolism. *J Vet Intern Med* 27: 919–23
- Clemente M, De Andrés PJ, Arenas C, Melián C, Morales M, Pérez-Alenza MD (2007) Comparison of non-selective adrenocorticolysis with mitotane or trilostane for the treatment of dogs with pituitary-dependent hyperadrenocorticism. *Vet Rec* 161: 805–9
- Cook AK, Bond KG (2010) Evaluation of the use of baseline cortisol concentration as a monitoring tool for dogs receiving trilostane as a treatment for hyperadrenocorticism. *J Am Vet Med Assoc* 237: 801–805
- Cook AK, Spaulding KA, Edwards JF (2014) Clinical findings in dogs with incidental adrenal gland lesions determined by ultrasonography: 151 cases (2007-2010). *J Am Vet Med Assoc* 244: 1181–5
- Daley CA, Zerbe CA, Schick RO, Powers RD (1993) Use of metyrapone to treat pituitary-dependent hyperadrenocorticism in a cat with large cutaneous wounds. *J Am Vet Med Assoc* 202: 956–60
- Dow SW, LeCouteur RA, Rosychuk RAW, Powers BE, Kemppainen RJ, Gillette EL (1990) Response of dogs with functional pituitary macroadenomas and macrocarcinomas to radiation. *J Small Anim Pract* 31: 287–94
- Duesberg C, Peterson ME (1997) Adrenal disorders in cats. *Vet Clin North Am Small Anim Pract* 27: 321–347
- Duesberg CA, Nelson RW, Feldman EC, Vaden SL, Scott-Moncrieff CR (1995) Adrenalectomy for treatment of hyperadrenocorticism in cats: 10 cases (1988-1992). *J Am Vet Med Assoc* 207: 1066–70
- Essex HE, Astrarabadi TM (1953) Transbuccal hypophysectomy in the dog. *Ann Surg* 138: 143–4
- Feldman E (2008) Evaluation of twice-daily, lower-dose trilostane treatment administered orally in dogs with naturally occurring hyperadrenocorticism. *J Am Vet Med Assoc* 238: 1441–51
- Feldman EC, Nelson RW (2004) Canine hyperadrenocorticism (Cushing's Syndrome). In: Feldman EC, Nelson RW, eds. *Canine and Feline Endocrinology and Reproduction*. 3rd edn. Saunders, St Louis, MO: 252–439
- Fracassi F, Corradini S, Floriano D et al (2014) Prognostic factors for survival in dogs with pituitary-dependent hypercortisolism treated with trilostane. *Vet Rec* 176: 49. doi: 10.1136/vr.102546
- Fulmer BR (2007) Diagnosis and management of adrenal cortical carcinoma. *Curr Urol Rep* 8: 77–82
- Galac S, Kooistra HS, Voorhout G et al (2005) Hyperadrenocorticism in a dog due to ectopic secretion of adrenocorticotrophic hormone. *Domest Anim Endocrin* 28: 338–48

- Galac S, Buijtels JJ, Kooistra HS (2009) Urinary corticoid: creatinine ratios in dogs with pituitary-dependent hypercortisolism during trilostane treatment. *J Vet Intern Med* 23: 1214–9
- Goossens MM, Feldman EC, Theon AP, Koblik PD (1998) Efficacy of cobalt 60 radiotherapy in dogs with pituitary-dependent hyperadrenocorticism. *J Am Vet Med Assoc* 212: 374–6
- Graves TK (2010) Hypercortisolism in cats (feline Cushing's syndrome). In Ettinger SJ, Feldman EC, eds. *Textbook of Veterinary Internal Medicine*. 7th edn. Elsevier Saunders, St Louis, MO: 1840–7
- Hanson JM, van 't Hoofd MM, Voorhout G, Teske E, Kooistra HS, Meij BP. (2005) Efficacy of transsphenoidal hypophysectomy in treatment of dogs with pituitary-dependent hyperadrenocorticism. *J Vet Intern Med* 19: 687–94
- Hanson JM, Teske E, Voorhout G, Galac S, Kooistra HS, Meij BP (2007) Prognostic factors for outcome after transsphenoidal hypophysectomy in dogs with pituitary-dependent hyperadrenocorticism. *J Neurosurg* 107: 830–40
- Helm JR, McLauchlan G, Boden LA et al (2011) A comparison of factors that influence survival in dogs with adrenal-dependent hyperadrenocorticism treated with mitotane or trilostane. *J Vet Intern Med* 25: 251–60
- Henry RW, Hulse DA (1982) Transoral hypophysectomy with mandibular symphysiotomy in the dog. *Am J Vet Res* 43: 1825–9
- den Hertog E, Braakman JC, Teske E, Kooistra HS, Rijnberk A (1999) Results of non-selective adrenocorticolysis by o,p'-DDD in 129 dogs with pituitary-dependent hyperadrenocorticism. *Vet Rec* 144: 12–17
- Hoening M (2002) Feline hyperadrenocorticism—where are we now? *J Feline Med Surg* 4: 171–4
- Ihle S (1997) Pituitary corticotroph macrotumors. Diagnosis and treatment. *Vet Clin North Am Small Anim Pract* 27: 287–96
- Kaltsas GA, Nomikos P, Kontogeorgos G, Buchfelder M, Grossman AB (2005) Clinical review: Diagnosis and management of pituitary carcinomas. *J Clin Endocrinol Metab* 90: 3089–99
- Kelly DF (2007) Transsphenoidal surgery for Cushing's disease: a review of success rates, remission predictors, management of failed surgery, and Nelson's Syndrome. *Neurosurg Focus* 23(3): E5
- Kenny, PJ, Scudder C, Keyte SV, et al (2015) Experiences of a newly established hypophysectomy Clinic for treatment of feline hypersomatotropism. *J Vet Intern Med* 29: 449–50

Kent MS, Bommarito D, Feldman E, Theon AP (2007) Survival, neurologic response, and prognostic factors in dogs with pituitary masses treated with radiation therapy and untreated dogs. *J Vet Intern Med* 21: 1027–33

Kintzer PP, Peterson ME (1991) Mitotane (o,p'-DDD) treatment of 200 dogs with pituitary-dependent hyperadrenocorticism. *J Vet Intern Med* 5: 182–90

Kipperman BS, Feldman EC, Dybdal NO, Nelson RW (1992) Pituitary tumor size, neurologic signs, and relation to endocrine test results in dogs with pituitary-dependent hyperadrenocorticism: 43 cases (1980–1990). *J Am Vet Med Assoc* 201: 762–7

Kooistra HS, Galac S (2010) Recent advances in the diagnosis of Cushing's syndrome in dogs. *Vet Clin North Am Small Anim Pract* 40: 259–67

Kyles AE, Feldman EC, de Cock HE et al (2003) Surgical management of adrenal gland tumours with and without associated tumor thrombi in dogs: 40 cases. *J Am Vet Med Assoc* 223: 654–62

Lang JM, Schertel E, Kennedy S, Wilson D, Barnhart M, Danielson B (2011) Elective and emergency surgical management of adrenal gland tumors: 60 cases (1999–2006). *J Am Anim Hosp Assoc* 47: 428–35

Lien YH, Huang HP (2008) Use of ketoconazole to treat dogs with pituitary-dependent hyperadrenocorticism: 48 cases (1994–2007). *J Am Vet Med Assoc* 233: 1896–901

Lo AJ, Holt DE, Brown DC, Schlicksup MD, Orsher RJ, Agnello KA (2014) Treatment of aldosterone-secreting adrenocortical tumors in cats by unilateral adrenalectomy: 10 cases (2002–2012). *J Vet Intern Med* 28: 137–43

Loli P, Berselli ME, Tagliaferri M (1986) Use of ketoconazole in the treatment of Cushing's syndrome. *J Clin Endocrinol Metab* 63: 1365–71

Loose DS, Kan PB, Hirst MA, Marcus RA, Feldman D (1983) Ketoconazole blocks adrenal steroidogenesis by inhibiting cytochrome P450-dependent enzymes. *J Clin Invest* 71: 1495–9

Lorenz MD (1982) Diagnosis and medical management of canine Cushing's syndrome: a study of 57 consecutive cases. *J Am Anim Hosp Assoc* 18: 707–16

Mariani CL, Schubert TA, House RA et al (2013) Frameless stereotactic radiosurgery for the treatment of primary intracranial tumours in dogs. *Vet Comp Oncol*: [early view]. DOI: 10.1111/vco.12056

Massari F, Nicoli S, Romanelli G, Buracco P, Zini E (2011) Adrenalectomy in dogs with adrenal gland tumors: 52 cases (2002–2008). *J Am Vet Med Assoc* 239:

Mayer MN, Greco DS, LaRue SM (2006) Outcomes of pituitary tumor irradiation in cats. *J Vet Intern Med* 20: 1151–4

Mayer UK, Glos K, Schmid M, Power HT, Bettenay SV, Mueller RS (2008) Adverse effects of ketoconazole in dogs – a retrospective study. *Vet Dermatol* 19: 199–208

Mayhew PD, Culp WT, Hunt GB et al (2014) Comparison of perioperative morbidity and mortality rates in dogs with noninvasive adrenocortical masses undergoing laparoscopic versus open adrenalectomy. *J Am Vet Med Assoc* 245: 1028–35

Meij BP, Voorhout G, Van den Ingh TS, Hazewinkel HA, Van't Verlaat JW (1997) Transsphenoidal hypophysectomy in beagle dogs: evaluation of a microsurgical technique. *Vet Surg* 26: 295–309

Meij BP, Voorhout G, van den Ingh TS, Hazewinkel HA, Teske E, Rijnberk A (1998) Results of transsphenoidal hypophysectomy in 52 dogs with pituitary-dependent hyperadrenocorticism. *Vet Surg* 27: 246–61

Meij BP, Voorhout G, Van Den Ingh TS, Rijnberk A (2001) Transsphenoidal hypophysectomy for treatment of pituitary-dependent hyperadrenocorticism in 7 cats. *Vet Surg* 30: 72–86

Meij B, Voorhout G, Rijnberk A (2002) Progress in transsphenoidal hypophysectomy for treatment of pituitary-dependent hyperadrenocorticism in dogs and cats. *Mol Cell Endocrinol* 197: 89–96

Melian C, Perez-Alenza MD, Peterson ME (2010) Hyperadrenocorticism in dogs.

In: Ettinger S, Feldman E, eds. *Textbook of Veterinary Internal Medicine*. 7th edn. Saunders, St Louis, MO: 1816–40

Mellett Keith AM, Bruyette D, Stanley S (2013) Trilostane therapy for treatment of spontaneous hyperadrenocorticism in cats: 15 cases (2004-2012). *J Vet Intern Med* 27: 1471–1477

Moore LE, Biller DS, Olsen DE (2000) Hyperadrenocorticism treated with metyrapone followed by bilateral adrenalectomy in a cat. *J Am Vet Med Assoc* 217: 691–4

Naan EC, Kirpensteijn J, Dupré GP, Galac S, Radlinsky MG (2013) Innovative approach to laparoscopic adrenalectomy for treatment of unilateral adrenal gland tumors in dogs. *Vet Surg* 42: 710–5

Neiger R, Witt AL, Noble A, German AJ (2004) Trilostane therapy for treatment of pituitary-dependent hyperadrenocorticism in 5 cats. *J Vet Intern Med* 18: 160–4

Nelson RW, Feldman EC, Smith MC (1988) Hyperadrenocorticism in cats: seven cases (1978-1987). *J Am Vet Med Assoc* 193: 245–50

Ramsey IK (2010) Trilostane in dogs. *Vet Clin North Am Small Anim Pract* 40: 269–83

- Rijnberk A, Belshaw B (1988) An alternative protocol for the medical management of canine pituitary-dependent hyperadrenocorticism. *Vet Rec* 122: 486–8
- Ritzel K, Beuschlein F, Mickisch A (2013) Clinical review: Outcome of bilateral adrenalectomy in Cushing's syndrome: a systematic review. *J Clin Endocrinol Metab* 98: 3939–48
- Scavelli TD, Peterson ME, Matthiesen DT (1986) Results of surgical treatment for hyperadrenocorticism caused by adrenocortical neoplasia in the dog: 25 cases (1980-1984). *J Am Vet Med Assoc* 189: 1360–4
- Schwartz P, Kovak JR, Koprowski A, Ludwig LL, Monette S, Bergman PJ (2008) Evaluation of prognostic factors in the surgical treatment of adrenal gland tumors in dogs: 41 cases (1999-2005). *J Am Vet Med Assoc* 232: 77–84
- Schwedes CS (1997) Mitotane (o, p'-DDD) treatment in a cat with hyperadrenocorticism. *J Small Anim Pract* 38: 520–4
- Seth M, Drobotz KJ, Church DB, Hess RS (2011) White blood cell count and the sodium to potassium ratio to screen for hypoadrenocorticism in dogs. *J Vet Intern Med* 25: 1351–6
- Skelly BJ, Petrus D, Nicholls PK (2003) Use of trilostane for the treatment of pituitary-dependent hyperadrenocorticism in a cat. *J Small Anim Pract* 44: 269–72
- Théon AP, Feldman EC (1998) Megavoltage irradiation of pituitary macrotumors in dogs with neurologic signs. *J Am Vet Med Assoc* 213: 225–31
- Valentin SY, Cortright CC, Nelson RW et al (2013) Comparison of diagnostic tests and treatment options for feline hyperadrenocorticism: A retrospective review of 32 cases. *J Vet Intern Med* 27: 688
- Valentin SY, Cortright CC, Nelson RW et al (2014) Clinical findings, diagnostic test results, and treatment outcome in cats with spontaneous hyperadrenocorticism: 30 cases. *J Vet Intern Med* 28: 481–7
- van Sluijs FJ, Sjollem BE, Voorhout G, van den Ingh TS, Rijnberk A (1995) Results of adrenalectomy in 36 dogs with hyperadrenocorticism caused by adrenocortical tumour. *Vet Q* 17: 113–6
- Veytsman I, Nieman L, Fojo T (2009) Management of endocrine manifestations and the use of mitotane as a chemotherapeutic agent for adrenocortical carcinoma. *J Clin Oncol* 27: 4619–29
- Weiss LM (1984) Comparative histologic study of 43 metastasizing and nonmetastasizing adrenocortical tumors. *Am J Surg Pathol* 8: 163–9
- Wood FD, Pollard RE, Uerling MR, Feldman EC (2007) Diagnostic imaging findings and endocrine test results in dogs with pituitary-dependent hyperadrenocorticism that did or did not have neurologic abnormalities: 157 cases (1989-2005). *J Am Vet Med Assoc* 231: 1081–5