

Contents lists available at ScienceDirect

Meat Science

journal homepage: www.elsevier.com/locate/meatsci

Pathophysiology of penetrating captive bolt stunning in Alpacas (*Vicugna pacos*)



Troy J. Gibson^{a,*}, Claire Whitehead^b, Rebecca Taylor^a, Olivia Sykes^a, Natalie M. Chancellor^a, Georgina Limon^a

^a Production Population Health, Royal Veterinary College, Hawkshead Lane, Hatfield, AL9 7TA, United Kingdom

^b Camelid Veterinary Services, Lower Hitch Cottage, Whitchurch Hill, Reading, RG8 7NU, United Kingdom

ARTICLE INFO

Article history:

Received 30 May 2014

Received in revised form 29 August 2014

Accepted 21 October 2014

Available online 28 October 2014

Keywords:

Alpaca

Behaviour

Captive bolt

Stunning

Slaughter

ABSTRACT

The aim of this study was to examine the behavioural and cranial/spinal responses of alpacas culled by captive bolt shooting and the resulting pathophysiology of captive bolt injury. Ninety-six alpacas were shot (103 shots) in a range of locations with a penetrating captive bolt gun (CBG). Ten (9.8%) alpacas were incompletely concussed following the first shot. No animals required more than two shots. Incorrectly placed shots accounted for all of the animals that displayed signs of sensibility. Damage to the thalamus, hypothalamus, midbrain, medulla, cerebellum, parietal and occipital lobes were significantly associated with decreasing odds of incomplete concussion. In conclusion, the study confirmed that CBG stunning can induce insensibility in alpacas and suggests that the top of the head (crown) position maximises damage to structures of the thalamus and brainstem.

© 2014 The Authors. Published by Elsevier Ltd. This is an open access article under the CC BY-NC-ND license (<http://creativecommons.org/licenses/by-nc-nd/4.0/>).

1. Introduction

Alpacas and llamas are increasing in popularity as farmed and exotic pet species in many countries including the United Kingdom (UK), New Zealand (NZ), Canada, United States of America (USA) and Australia. There are currently just over 30,000 registered in the UK (Whitehead, 2013), with estimates of close to 195,000 in North America and >90,000 in Australia (Anon, 2014; Jabbar, Campbell, Charles, & Gasser, 2013). They are kept predominantly for fibre production and as pets on smallholdings and hobby farms, with small numbers being slaughtered for human consumption. Camelids are an important livestock species in South America where llamas and alpacas are bred for fibre, meat, skin and used as pack animals. In South America, apart from a few large commercial herds, domestic camelids are principally confined to higher altitudes of the Central Andean region, where their production is almost exclusively based on low input, small-scale subsistence farming (Cardellino & Mueller, 2009).

Slaughter and dispatch of domestic camelids in the UK is normally performed with penetrating captive bolt gun (CBG) stunning, immediately followed by exsanguination by severing the carotid arteries and jugular veins (ventral neck incision) at the level of the jaw line or by severing the aorta in the thoracic cavity (chest stick or thoracic stab).

There is a large amount of practical experience and research on captive bolt stunning in a range of livestock species used for human consumption. Previous work has examined the time to undoubted

insensibility and the effectiveness of penetrating and non-penetrating captive bolt in sheep and cattle using brainstem and cranial/spinal reflexes (Atkinson, Velarde, & Algers, 2013; Blackmore, 1979; Fricker & Riek, 1981; Gibson et al., 2012; Gouveia, Ferreira, Roque de Costa, Vaz-Pires, & Martins da Costa, 2009; Gregory, Lee, & Widdicombe, 2007; Svendsen, Jensen, Karlsen, Svalastoga, & Jensen, 2008) and changes in the spontaneous EEG and evoked potentials (Daly, Gregory, & Wotton, 1987; Daly, Gregory, Wotton, & Whittington, 1986; Daly & Whittington, 1986; Fricker & Riek, 1981; Gibson et al., 2009a,b; Lambooy & Spanjaard, 1981). Generally, these studies conclude that captive bolt stunning is an effective method of rendering animals insensible prior to the act of slaughter, provided that the animals are shot in the correct position, with the appropriate CBG/cartridge combination for the species and animal type and finally that the CBGs are regularly cleaned and serviced to minimise deterioration in performance (Grandin, 1980, 1994, 2002).

In most parts of South America, the slaughter of camelids is by puntilla (also known as neck stabbing and *evernazione*). This traditional method involves inserting a knife into the back of the neck in an attempt to sever the spinal cord. The aim is to induce immediate collapse and immobilisation allowing the animal to be bled without risk of injury to the slaughtermen. Traditionally, this method was considered to be humane (Gregory, 1990); however, research in llamas and cattle has found that often the stab is ineffective, with a significant proportion of animals (cattle 91%; llamas 95%) showing signs of brain and spinal cord function, suggesting that they were still sensible and able to experience pain and distress (Dembo, 1894; Limon, Guitian, & Gregory, 2009, 2010).

* Corresponding author. Tel.: +44 707 66 7078.

E-mail address: tgibson@rvc.ac.uk (T.J. Gibson).

Currently, there are limited standards or guidelines for the humane dispatch of llamas and alpacas in the UK or overseas. The recommendations that do exist are principally based on anecdotal observations supported by unpublished information or extrapolated from previous research in other livestock species.

The aim of this study was to examine the behavioural and cranial/spinal responses of alpacas shot with CBG and the resulting pathophysiology of captive bolt injury. These results could be used to ascertain whether or not the use of the CBG is an effective stunning method for alpacas, and also to make welfare-based recommendations for shooting position in alpacas.

2. Materials and methods

The study received local ethical approval from the Royal Veterinary College Ethics and Welfare Committee. Alpacas were from a commercial breeding farm in Southern England. Ninety-six alpacas that were selected for routine culling were shot with a Cash Special CBG with 0.22 purple 2.5 gr (nominal propellant charge 190 mg) cartridges (Accles & Shelvoke, Sutton Coldfield, UK). The alpacas were either of the Huacaya (73) or Suri (17) breed, with 91 female and 5 males, aged between 2 and 16 years (mean 8 years). Data on breed and age were missing for 6 animals. Animals were individually restrained between two adjacent metal gates forming a simple crush, with the head unrestrained. The initial intention was to shoot an equal number of alpacas in the frontal and crown positions. However, attempting to shoot in the frontal position was found to be difficult. In total, the frontal and crown shots were attempted in 9 and 94 animals, respectively. The frontal position was defined as the intersection of two lines crossing from the medial canthus of each eye to the opposite ear, with the shot aiming towards the brainstem. Crown shots were defined as a shot placed on the highest point on the head, while aiming down to the base of the jaw. All animals were shot by a licensed slaughterman under veterinary supervision.

Immediately after shooting, all animals were assessed for clinical signs of sensibility, including the presence or absence of immediate collapse, righting reflex, rhythmic breathing, corneal reflex, palpebral reflex, eyeball rotation, nystagmus, jaw muscle tension, convulsions, leg kicking and cardiac arrest (palpation of the chest). When the eyeball was rotated with the sclera visible the corneal reflex was not assessed. If any animals were incompletely concussed, they were immediately reshot in the crown position. Animals were classified as sensible immediately after CBG shooting if either rhythmic breathing or failure to collapse was present and/or if two of more of the following parameters were present: positive corneal reflex, positive palpebral reflex, eyeball rotation and nystagmus. Shallow depth of concussion was defined as the presence of eyeball rotation, nystagmus or an intermittently positive corneal or palpebral reflex.

Approximately 30 s poststunning, the animals were hoisted and suspended by a hind leg and a ventral neck incision was made to the soft tissue of the neck close to the base of the jaw, severing the trachea, oesophagus, jugular veins and carotid arteries. The testing of clinical signs of sensibility/insensibility were continuously performed after shooting, or until cardiac arrest. In addition shot position, presence of brain tissue extruding from the bolt hole or on the ground, vessels severed and the weight of the blood following exsanguination were recorded.

Following death, the heads were removed and the location of the bolt penetration site (for both frontal and crown positions) was determined relative to the intersection of lines between the eyes and the opposite ear. Heads were frozen and stored before examining the gross pathology of the brain caused by the captive bolt injury. Frozen heads were band-sawed longitudinally through or near to the bolt penetration site.

Postmortem examinations were conducted on both the frozen and defrosted heads of each animal. The trajectory and penetration depth of the bolt was measured from the outer surface of the head using a

plastic probe inserted through the bolt entrance cavity. Brains were removed from the cranial vault of defrosted heads and sliced into 5 mm sections for examination for gross lesions, displacement of tissue (extrusion of tissue out of the bolt cavity and cerebellar coning), haemorrhage (in the third ventricle, lateral ventricles, cerebral aqueduct, fourth ventricle, on the ventral surface of the brainstem) and position of bone fragments. The head was examined for bone and skin tissue thicknesses with vernier calipers and signs of cavitation of the inner table of the cranial vault at the bolt entrance site. Severity of tissue damage of specific brain regions was assessed subjectively as none (0%), mild (1–20%), moderate (21–49%) or severe (>50%). Haemorrhage over the entire brain was assessed subjectively as a percentage of total brain surface area. Data from the left and right cerebral hemispheres were pooled to aid analysis. Any skin, wool or bone fragments recovered from the brains or cranial vault were collected and weighed.

Categorical variables representing degree of brain damage were re-categorised into binary variables. Therefore, these variables became *region with damage* (mild, moderate or severe) and *region without damage*. Animals with signs of sensibility and shallow depth of concussion were pooled and classed as incomplete concussion. The strength to which damage in each of the brain regions was associated with incomplete concussion was determined using Chi squared test (or Fisher Exact test when necessary). For each of those associations that were significant ($P < 0.05$), a logistic regression model was built and odds ratios were obtained as measure of effect. All analysis was carried out using the statistical software R 3.0, package epicalc.

3. Results

Ninety-six alpacas were shot in a variety of positions with penetrating CBG, 7 animals were reshot due to failure of the initial shot. When alpacas were reshot, both shots were included in the analysis. In total, data were collected and analysed for 103 shots; of these, 7 animals had signs of sensibility. Meanwhile, 3 additional alpacas had signs of a shallow depth of concussion based on one sign only; consisting of nystagmus ($n = 2$) and intermittent positive palpebral reflex ($n = 1$). There were no other signs of return of sensibility in those 3 animals. For subsequent analysis the data from animals with signs of sensibility and shallow depth of concussion were pooled ($n = 10$; 9.7%) and classed as incomplete concussion.

Immediately after CBG shooting, 2 animals remained standing on all four limbs and 3 had normal rhythmic breathing (Table 1), all these animals were reshot. The most common indicator of shallow depth of concussion was jaw tension; however, this was not always related to other indices (Table 1). Positive corneal and palpebral reflexes were recorded in 7 and 8 animals, respectively. Eyeball rotation was not observed in any animals after CBG shooting. Nystagmus and convulsions were seen after CBG stunning in 3 and 5 animals respectively.

Fig. 1 displays the CBG shot entrance positions. Data on shot position were missing for 3 animals (1 insensible, 2 showing a shallow depth of concussion). Five of the shots did not enter the cranial vault, all of these animals were incompletely concussed. Four of these shots entered left of the cranial vault in the occipital or caudal aspects of the temporal

Table 1
Number and percentage of behavioural and cranial/spinal responses ($n = 103$).

Parameter	Number (%)
Failed to collapse immediately	2 (1.9%)
Normal rhythmic breathing after shot	3 (2.9%)
Righting reflex	1 (1.0%)
Positive corneal reflex	7 (6.8%)
Positive palpebral reflex	8 (7.8%)
Eyeball rotation	0 (–)
Showing nystagmus	3 (2.9%)
Jaw muscle tension	13 (12.6%)
Convulsions after the shot	5 (4.9%)

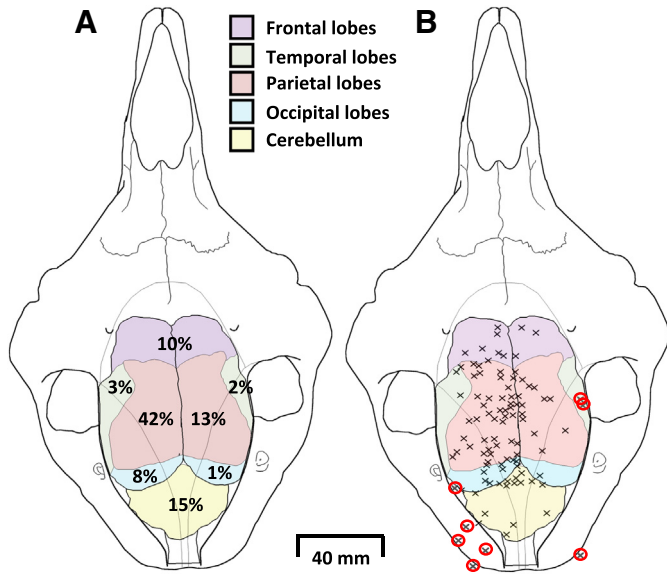


Fig. 1. Captive bolt shot entrance positions for 100 shots. Data were missing for 3 shots. The following regions of the brain are shaded: frontal lobes, temporal lobes, parietal lobes, occipital lobes and cerebellum. (A) The percentage of shots entering into the specific brain regions. (B) The position of each shot with shots that failed to produce complete concussion circled in red.

bone, while 1 shot penetrated into the right lateral aspect of the occipital bone. Three of the shots that entered (or superficially damaged) the region of the right temporal and left occipital lobe were in animals that were incompletely concussed. The majority of shots were left of mid-line (left 75% and right 25%). In relation to the corresponding underlying brain regions 10% of shots entered the frontal lobes, 5% the temporal lobes (left 3% and right 2%), 55% the parietal lobes (left 42% and right 13%), 15% the occipital (left 8% and right 1%) and 15% entered the cerebellum.

The majority of animals were slaughtered with a ventral neck incision close to the jaw ($n = 94$). Two alpacas were slaughtered with a chest stick and another with an incision on the ventral aspect of the neck in relation to the C3 vertebra. This was performed to assess the practicality of cuts in these positions. The mean time to onset of cardiac arrest after CBG stunning and exsanguination was $96 \pm$ standard deviation (SD) 29 (range 40–247) s.

Captive bolt penetration depth in the head ranged between 21 and 84 mm (mean 64 ± 8) (Table 2). There was no significant correlation between bolt penetration depth and skull thickness ($P = 0.183$). Skin and skull thickness at the penetration site was 3 ± 4 and 4 ± 2 mm, respectively. The extrusion of brain tissue from the shot hole occurred with 73% of the shots. Eighty-nine (86%) of the shots produced cavitation of the inner table of the bolt entrance cavity.

The majority of animals had some form of damage to the brain, 79 and 78% had damage to the thalamus and hypothalamus respectively. Overall, 76%, 67%, 62%, 72% and 44% had some form of damage to the

Table 2

Mean \pm SD and range of penetrative depth, skin and bone thickness at the penetration site, weight of fragments removed from the brain and brain weight.

	Mean \pm SD	Range
Bolt penetration depth (mm)	64 ± 8	21–84
Skin tissue thickness at penetration site (mm)	3 ± 4	1–21
Skull thickness at penetration site (mm)	4 ± 2	1–11
Weight of bone fragments, skin and hair removed from the brain (g)	1.3 ± 0.7	0.1–3.6
Brain weight (g)*	159.3 ± 12.9	131–185

* Only recorded for 53 animals.

midbrain, pons, medulla, cerebellum and spinal cord, respectively. Damage to the lobes of the cerebrum was seen in frontal (55%), parietal (72%), temporal (59%) and occipital (63%) lobes.

Table 3 presents the results from the 10 alpacas that had signs of incomplete concussion. Of these, none had any macroscopic damage to the pons region and severe damage to the thalamus, hypothalamus, midbrain and medulla was absent in these alpacas. The one alpaca with moderate damage to the thalamus and hypothalamus had a transient intermittent positive palpebral reflex, with no other signs of incomplete concussion. Three animals had moderate and severe damage to the spinal cord, of these alpacas two also had damage to the cerebellum and one had mild damage to the medulla. Two animals that were incompletely concussed had severe damage to the frontal lobe, and three had moderate damage to the temporal lobe.

For the logistic regression analysis of incomplete concussion and the damage to the specific brain structures, the severity of damage was grouped to aid analysis. Damage to the thalamus (OR = 0.04, $P < 0.001$), hypothalamus (OR = 0.05, $P < 0.001$), midbrain (OR = 0.02, $P < 0.001$), medulla (OR = 0.06, $P = 0.007$), cerebellum (OR = 0.13, $P = 0.006$), parietal (OR = 0.13, $P = 0.006$) and occipital (OR = 0.05, $P = 0.006$) lobes all reduced the odds of incomplete concussion (Table 4). There was no significant association between damage to spinal cord and incomplete concussion ($P = 0.39$), frontal ($P = 0.1$) and temporal lobes ($P = 0.06$). Similarly, age was not significantly associated with incomplete concussion ($P = 0.13$).

The percentage of haemorrhage over the entire brain surface was subjectively scored for animals that only received one shot; mean haemorrhage was $40 \pm 18\%$. This was principally subarachnoid haemorrhage. Haemorrhage was found in the 3rd ventricle (51%), lateral ventricles (51%), cerebral aqueduct (52%), 4th ventricle (74%) and on the ventral surface of the brainstem (82%).

4. Discussion

Ninety-six alpacas were shot with penetrating CBG, 7 animals were re-shot resulting in a total of 103 shots fired. After the CBG shot, 90% of alpacas were rendered immediately insensible. Damage to the thalamus, hypothalamus, midbrain, medulla, cerebellum, parietal and occipital lobes were strongly associated with decreasing odds of incomplete concussion. Shots that missed the brain or only superficially damaged the thalamus and brainstem, usually failed to induce complete insensibility. This suggests that the kinetic energy imparted to the skull with the failed shots was insufficient to induce complete insensibility via concussive force alone. This finding applies specifically to the CBG/cartridge combination used in this study (Cash Special with 2.5 gr cartridge). Previous studies have suggested that it is the kinetic energy imparted to the cranium by the bolt that produces insensibility (Daly & Whittington, 1989), while the actual physical damage by the bolt to specific brain structures is responsible for producing irrecoverable

Table 3

Damage observed in brain structures during PM examination in the 10 alpacas that had signs of incomplete concussion.

Damage to	Severity of damage			
	None (%)	Mild (%)	Moderate (%)	Severe (%)
Thalamus	8 (80%)	1 (10%)	1 (10%)	0 (-)
Hypothalamus	8 (80%)	1 (10%)	1 (10%)	0 (-)
Midbrain	9 (90%)	1 (10%)	0 (-)	0 (-)
Pons	10 (100%)	0 (-)	0 (-)	0 (-)
Medulla	9 (90%)	1 (10%)	0 (-)	0 (-)
Cerebellum	7 (70%)	1 (10%)	1 (10%)	1 (10%)
Spinal cord	7 (70%)	0 (-)	2 (20%)	1 (10%)
Frontal lobes	7 (70%)	1 (10%)	0 (-)	2 (20%)
Temporal lobes	7 (70%)	0 (-)	3 (30%)	0 (-)
Parietal lobes	7 (70%)	1 (10%)	1 (10%)	1 (10%)
Occipital lobes	9 (90%)	0 (-)	1 (10%)	0 (-)

Table 4

Results of logistic regression models assessing the extent to which damage in each region of the brain is associated with incomplete concussion. Only models that show significant associations are presented.

Region	OR	95% CI	P value
Thalamus	0.04	0.01–0.23	<0.001
Hypothalamus	0.05	0.01–0.25	<0.001
Midbrain	0.02	0.02–0.18	<0.001
Medulla	0.06	0.01–0.46	0.007
Cerebellum	0.13	0.03–0.56	0.006
Parietal lobes	0.13	0.03–0.56	0.006
Occipital lobes	0.05	0.01–0.42	0.006

insensibility (Gibson et al., 2012). However, in the current study, the results suggest that for alpacas, CBG injury induces insensibility principally by direct physical trauma (focal and diffuse injury) from the bolt to the structures of the diencephalon and brainstem (Finnie, Manavis, Blumbergs, & Summersides, 2002). Pressure effects, in the form of flattening of the cerebrum contralateral to the CBG shot, were observed. However, it was not possible to determine if this was due to trauma from contrecoup forces or associated with subdural haemorrhage after the shot.

The behavioural/cranial/spinal responses and the gross pathology results of this study suggest that the preferred shooting position for alpacas is on midline on top of the head (crown position). Shooting in this position maximises the probability of the bolt penetrating into or damaging the parietal/occipital lobes, thalamus, midbrain, pons or medulla. Damage to these structures was found to be associated with decreased odds of incomplete concussion. Anecdotally the slaughterman reported that shooting in the frontal position was difficult and often resulted in head movement immediately prior to the CBG shot, for this reason fewer frontal shots were attempted.

For the shot to be correctly placed, it should not have excessive lateral/rostral/caudal angulation and should be aimed towards the back of the jaw. Shots that failed to produce immediate insensibility either missed the brain or entered off midline superficially damaging the cerebellum, lobes of the cerebrum and missing the structures of the thalamus and brainstem. The top of the head (crown) position of the shot is similar to that found to produce irrecoverable insensibility in sheep shot with penetrating captive bolt without a secondary procedure (bleeding or pithing) (Gibson et al., 2012).

Eyeball rotation following CBG stunning has been previously reported as the first sign of a shallow depth of concussion. In sheep and cattle shot with CBG, the incidence of eyeball rotation has been reported as 4% and 3.8%, respectively (Gibson et al., 2012; Gregory et al., 2007), and is often associated with other indices of a shallow depth of concussion or return of sensibility. However, there were no cases of eyeball rotation after CBG in the current study, suggesting that for alpacas eyeball rotation should not be used as an indicator for the assessment of success or otherwise of CBG stunning for inducing insensibility. After CBG stunning only 5 alpacas had convulsive hind-leg kicking and it was very mild. This contrasts with the severe hind-leg convulsive kicking often observed in other species following CBG stunning. In other species, the presence of convulsive hind-leg kicking has been associated with the onset of insensibility (Blackmore, 1984; Blackmore & Newhook, 1982; Gibson et al., 2012; Gouveia et al., 2009) and is used as an indicator of the success or otherwise of the CBG stun (Gregory & Shaw, 2000). The low incidence or absence of convulsive hind-leg kicking in successfully stunned alpacas in this study suggests that it is an unreliable indicator of early brain dysfunction for this species.

In cattle and sheep, many studies report a gender difference in inadequate stunning, with male animals generally having a higher prevalence of being incompletely concussed (Atkinson et al., 2013; Gibson et al., 2012; Gregory et al., 2007). In the present study, only 5 male alpacas compared to 93 female were shot, such that examination of the data for any gender effect was not possible. Similarly, the majority

of the alpacas shot were of the Huacaya breed; therefore, it was not possible to assess the potential effect of breed.

A substantial number of the shots were left (75%) of midline. This was attributed to the position of the slaughterman performing the CBG shot. The individual was positioned to the right of the animal and held the CBG in his right hand. This potentially created a bias towards shooting to the left of midline due to over compensation by the slaughterman because of his position relative to the animal. Based on the pathology examination, 56% of shots were considered to be placed incorrectly, with poor marksmanship responsible for all cases of incomplete insensibility. The majority of incorrectly placed shots did not result in incomplete insensibility, rather they were >15 mm outside of the top of the head (crown) shooting position. However, the proportion of incorrectly placed shots is not dissimilar to findings for cattle and sheep. In cattle, which are shot in a frontal position, Gregory et al. (2007) reported that of 1608 cattle shot with contact firing penetrating captive bolt that 51% of the shots were inaccurately placed. Meanwhile, other studies have reported the incidence of incorrectly placed shots as 35% (Fries, Schrohe, Lotz, & Arndt, 2012), 8% (Atkinson et al., 2013; von Wenzlawowicz, von Holleben, & Eser, 2012) and 35% without head restraint (von Wenzlawowicz et al., 2012). Sheep are generally shot on the crown or top of the head, similar to what was used in the current study. Gibson et al. (2012) in a study of CBG dispatch of different classes of sheep reported that overall 19% of shots were incorrectly placed with horned rams being more challenging to shoot accurately.

In the current study, factors that may have influenced the accuracy of the shots included: (i) movements of the alpacas when individually penned; the isolation and restraint would have been stressful with the animals becoming restless, and this could have resulted in movements of the unrestrained head and neck at the time of stunning. (ii) The right-handed slaughterman performing the CBG shot was positioned immediately to the right of the head and when performing the shot he had to bring the CBG past the alpaca's field of vision, penetrating its flight zone, and this provoked movement of the head that complicated shooting. This was unavoidable due to the design of the facilities. Ideally, a right-handed slaughterman would be positioned slightly behind the alpaca's head to the left of the shoulder, bringing the gun forwards to the shooting position from the back of the head, with left-handed slaughtermen on the opposite side. Grandin (1980) stated that operators should not be positioned in front of the animal as it can lead to agitation due to entry into its flight zone. Adequate restraint is an essential requirement for safe and effective CBG stunning of livestock. The accuracy of the shot could have been improved with increased restraint, especially to the head and neck region. However, inappropriate and excessive restraint has been associated with signs of distress (Grandin, 1998; Gregory, 2007). (iii) During the study, the slaughterman reported that it was difficult to accurately place the frontal shot, with the animals often moving immediately prior to shooting. For this reason, only 9 frontal shots were attempted. Finally, the lack of experience of the slaughterman in the dispatch of alpacas could have been a factor in the placement and success of the shots. It is likely that all of these factors contributed to the number of incorrectly placed shots.

Performing a ventral neck incision in the low regions of the neck (C2+) was reported to be difficult, as the lateral processes of the cervical vertebrae create an inverted semi U-shaped channel. This provides protection from injury during aggression and fighting (Bonacic, 2011). It is within this U shape that many of the soft tissues of the neck including the trachea, oesophagus, jugular veins, carotid arteries and sensory nerves are located. This anatomical feature makes severing the carotid arteries and jugular veins difficult when performing a cut to the lower aspect of the neck. It is suggested instead that either an incision close to the jaw where the carotids and jugulars are more exteriorised from the vertebral column or a chest stick severing the aorta would result in a better cut and bleed out.

Currently, there is little detailed information about the methods of stunning and dispatch of alpacas and other camelids with CBGs. The

results of this study could be used to update or produce draft guidelines on the humane dispatch of alpacas, which could be extrapolated to llamas. These could be used to improve practices and animal welfare during commercial slaughter. The development of guidelines for the humane dispatch of camelids would also have relevance for the dispatch of individual animals or entire herds for disease control. Nationwide outbreaks of foot and mouth disease (FMD) or the localised identification of *Mycobacterium bovis* infected alpacas or llamas would require humane effective dispatch. In addition, using CBGs in isolated and resource-scarce settings would be feasible and relatively straightforward once slaughtermen in the region have been adequately trained. The use of CBG stunning could provide an effective method of dispatch and would be a significant improvement in terms of welfare compared to the puntilla stab currently performed in South America for immobilising camelids prior to slaughter (Limon, Guitian, & Gregory, 2012, Limon et al., 2009).

In conclusion, the study found that CBG stunning can be reliably used to induce insensibility in alpacas and that the top of the head or crown position maximises damage to the thalamus and brainstem. Damage to these structures was associated with the induction of insensibility. These results could be used for updating guidelines and practices for the stunning and dispatch of alpacas and other camelids.

Conflict of interest

There is no conflict of interest.

Acknowledgements

The authors would like to thank Dr. NG Gregory for helpful discussion and comments on the early draft of the manuscript. This study was partly supported by a Humane Slaughter Association Dorothy Sidley Memorial Award.

References

- Anon (2014). Alpaca Registry. Accessed 21st May 2014. <http://www.alpacaregistry.com/public/reports/alpacas-worldwide>
- Atkinson, S., Velarde, A., & Algers, B. (2013). Assessment of stun quality at commercial slaughter in cattle shot with captive bolt. *Animal Welfare*, 22(4), 473–481.
- Blackmore, D.K. (1979). Non-penetrative percussion stunning of sheep and calves. *Veterinary Record*, 105(16), 372–375.
- Blackmore, D.K. (1984). Differences in behavior between sheep and cattle during slaughter. *Research in Veterinary Science*, 37(2), 223–226.
- Blackmore, D.K., & Newhook, J.C. (1982). Electroencephalographic studies of stunning and slaughter of sheep and calves. 3. The duration of insensibility induced by electrical stunning in sheep and calves. *Meat Science*, 7(1), 19–28.
- Bonacic, C. (2011). South American Camelids. In J. Webster (Ed.), *Management and Welfare of Farm Animals: The UFAW Farm Handbook* (pp. 477–499) (5th ed.). Chichester: Wiley-Blackwell.
- Cardellino, R.C., & Mueller, J.P. (2009). Fibre Production and Sheep Breeding in South America. *Proceedings for the Advancement of Animal Breeding and Genetics*, 18, (pp. 366–373).
- Daly, C.C., Gregory, N.G., & Wotton, S.B. (1987). Captive bolt stunning of cattle—effects on brain-function and role of bolt velocity. *British Veterinary Journal*, 143(6), 574–580.
- Daly, C.C., Gregory, N.G., Wotton, S.B., & Whittington, P.E. (1986). Concussive methods of pre-slaughter stunning in sheep—assessment of brain-function using cortical evoked responses. *Research in Veterinary Science*, 41(3), 349–352.
- Daly, C.C., & Whittington, P.E. (1986). Concussive methods of pre-slaughter stunning in sheep—effects of captive bolt stunning in the poll position on brain-function. *Research in Veterinary Science*, 41(3), 353–355.
- Daly, C.C., & Whittington, P.E. (1989). Investigation into the principal determinants of effective captive bolt stunning of sheep. *Research in Veterinary Science*, 46(3), 406–408.
- Dembo, J.A. (1894). *The Jewish method of slaughter compared with other methods from the humanitarian, hygienic, and economic points of view*. London: Kegan, Paul, Trench, Trübner & Co Ltd.
- Finnie, J.W., Manavis, J., Blumbergs, P.C., & Summersides, G.E. (2002). Brain damage in sheep from penetrating captive bolt stunning. *Australian Veterinary Journal*, 80(1–2), 67–69.
- Fricker, C.H., & Riek, W. (1981). Die Betäubung von Rindern vor dem Schlachten mit Hilfe des Bolzenschuss-Apparates. *Fleischwirtschaft*, 61(1), 124–127.
- Fries, R., Schroe, K., Lotz, F., & Arndt, G. (2012). Application of captive bolt to cattle stunning—a survey of stunner placement under practical conditions. *Animal*, 6(7), 1124–1128.
- Gibson, T.J., Johnson, C.B., Murrell, J.C., Mitchinson, S.L., Stafford, K.J., & Mellor, D.J. (2009a). Amelioration of electroencephalographic responses to slaughter by non-penetrative captive-bolt stunning after ventral-neck incision in halothane-anaesthetised calves. *New Zealand Veterinary Journal*, 57(2), 96–101.
- Gibson, T.J., Johnson, C.B., Murrell, J.C., Mitchinson, S.L., Stafford, K.J., & Mellor, D.J. (2009b). Electroencephalographic responses to concussive non-penetrative captive-bolt stunning in halothane-anaesthetised calves. *New Zealand Veterinary Journal*, 57(2), 90–95.
- Gibson, T.J., Ridler, A.L., Lamb, C.R., Williams, A., Giles, S., & Gregory, N.G. (2012). Preliminary evaluation of the effectiveness of captive-bolt guns as a killing method without exsanguination for horned and unhorned sheep. *Animal Welfare*, 21, 35–42.
- Gouveia, K.G., Ferreira, P.G., Roque de Costa, J.C., Vaz-Pires, P., & Martins da Costa, P. (2009). Assessment of the efficiency of captive-bolt stunning in cattle and feasibility of associated behavioural signs. *Animal Welfare*, 18, 171–175.
- Grandin, T. (1980). Mechanical, electrical and anesthetic stunning methods for livestock. *International Journal for the Study of Animal Problems*, 1(4), 242–263.
- Grandin, T. (1994). Euthanasia and slaughter of livestock. *Journal of the American Veterinary Medical Association*, 204(9), 1354–1360.
- Grandin, T. (1998). The feasibility of using vocalization scoring as an indicator of poor welfare during cattle slaughter. *Applied Animal Behaviour Science*, 56(2–4), 121–128.
- Grandin, T. (2002). Return-to-sensibility problems after penetrating captive bolt stunning of cattle in commercial beef slaughter plants. *Journal of the American Veterinary Medical Association*, 221(9), 1258–1261.
- Gregory, N.G. (1990). Slaughtering methods and equipment. *Veterinary History*, 6(2), 73–84.
- Gregory, N.G. (2007). *Stunning and Slaughter*. *Animal Welfare and Meat Production* (pp. 191–212). Wallingford: CABI Publishing.
- Gregory, N.G., Lee, C.J., & Widdicombe, J.P. (2007). Depth of concussion in cattle shot by penetrating captive bolt. *Meat Science*, 77(4), 499–503.
- Gregory, N., & Shaw, F. (2000). Penetrating captive bolt stunning and exsanguination of cattle in abattoirs. *Journal of Applied Animal Welfare Science*, 3(3), 215–230.
- Jabbar, A., Campbell, A.J.D., Charles, J.A., & Gasser, R.B. (2013). First report of anthelmintic resistance in *Haemonchus contortus* in alpacas in Australia. *Parasites & Vectors*, 6.
- Lambooy, E., & Spanjaard, W. (1981). Effect of the shooting position on the stunning of calves by captive bolt. *Veterinary Record*, 109(16), 359–361.
- Limon, G., Guitian, J., & Gregory, N.G. (2009). A note on the slaughter of llamas in Bolivia by the puntilla method. *Meat Science*, 82(3), 405–406.
- Limon, G., Guitian, J., & Gregory, N.G. (2010). An evaluation of the humaneness of puntilla in cattle. *Meat Science*, 84, 352–355.
- Limon, G., Guitian, J., & Gregory, N.G. (2012). A review of the humaneness of puntilla as a slaughter method. *Animal Welfare*, 21, 3–8.
- Svendsen, O., Jensen, S.K., Karlsen, L.V., Svalastoga, E., & Jensen, H.E. (2008). Observations on newborn calves rendered unconscious with a captive bolt gun. *Veterinary Record*, 162(3), 90–92.
- von Wenzlawowicz, M., von Holleben, K., & Eser, E. (2012). Identifying reasons for stun failures in slaughterhouses for cattle and pigs: a field study. *Animal Welfare*, 21, 51–60.
- Whitehead, C. (2013). Diseases in camelids 1. Common presentations. *In Practice*, 35(6), 317–324.