

Case Report

Revision of a blade cut-out in PFN-A fixation: Blade exchange, cement augmentation and a cement plug as a successful salvage option

M.S. Hanke^a, N.A. Beckmann^{a,*}, M.J.B. Keel^{a,b}, K.A. Siebenrock^a, J.D. Bastian^a

^a Department of Orthopaedic and Trauma Surgery, University of Bern, Inselspital, Freiburgstrasse 3, 3010 Bern, Switzerland

^b Trauma Center Hirslanden, Klinik Hirslanden Zürich, Witellikerstrasse 40, 8032 Zürich, Switzerland

ARTICLE INFO

Keywords:

Hip
Intertrochanteric fracture
PFNA failure
Revision
Salvage
Cephalomedullary nail

ABSTRACT

A potential and feared complication of proximal femur nails with cephalomedullary fixation is migration of the cephalomedullary screw or blade (cut-out or cut-through). In patients not suitable (e.g. low demand, comorbidities) for conversion to total hip arthroplasty blade exchange with cement augmentation may be an option. This article describes the first successful clinical use of a salvage procedure of a previously published technique, which allows the surgeon to avoid intraarticular cement leakage by using a standard cement plug to close the defect in the femoral head.

Introduction

Intertrochanteric fractures are very common in the elderly and show an increasing incidence [1]. The recommended treatment involves reduction and fixation using cephalomedullary nails (CMN) [3]. Attempts have been made to optimize implant designs and techniques [6,7]. Despite such advances, failure still remains one of the main concerns [5], since the stability of screws decrease in osteoporotic bone.

Total hip arthroplasty (THA) is often seen as the best option to salvage fixation failure of CMN in intertrochanteric fractures [8]. Nevertheless, some patients may be unsuitable for conversion to THA. Blade exchange and cement augmentation may be an alternative. This is the first report on the use of a previously described technique to salvage a failed CMN [9].

Methods

A polymorbid 90-year old female, with a known history of severe osteoporosis, was transferred to our emergency department after falling in a nursing home. Physical examination revealed an externally rotated, abducted and shortened leg with severe immobilizing pain of her right hip. Radiologic work-up showed an intertrochanteric femoral fracture (Fig. 1A). The patient was operated by closed reduction and internal fixation (CRIF) on a traction table using a PFN-A (DePuy Synthes, Johnson & Johnson AG, Zuchwil, Switzerland) (Fig. 1B). The patient was allowed to fully weight bear immediately following the procedure. Three weeks later she complained about immobilizing groin pain on the operated side. Radiographic work-up showed secondary fracture dislocation and an anterior cut-out of the helical blade of the PFN-A (Fig. 1C). Due to the polymorbidity and low-demand of the patient (e.g. essential thrombocythemia, recurrent pulmonary artery embolisms) and significantly increased peri-operative risk (ASA Class III [10]) the case

* Corresponding author.

E-mail address: nicholasandreas.beckmann@insel.ch (N.A. Beckmann).

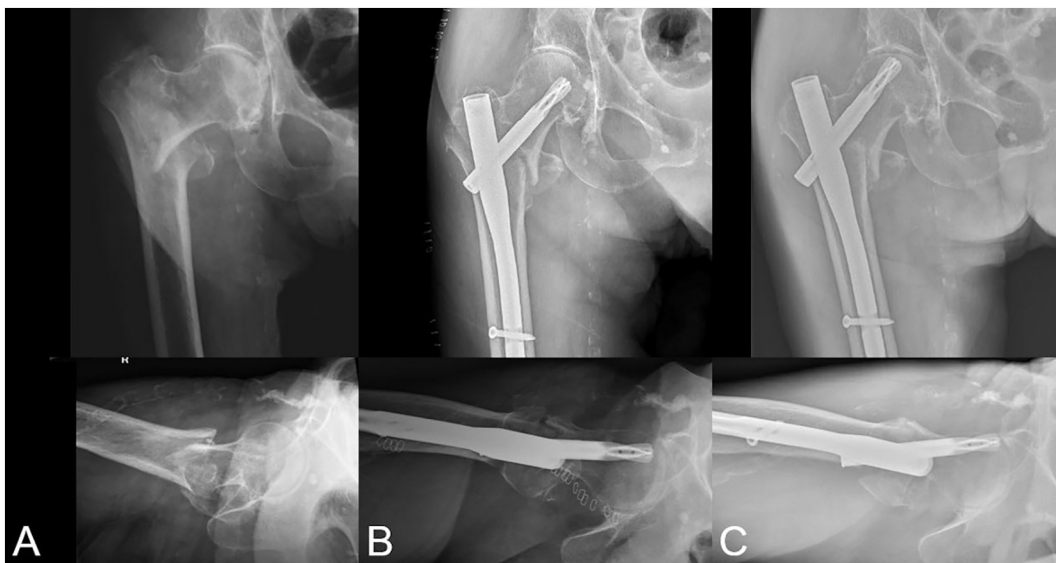


Fig. 1. (A) Pre-operative x-rays demonstrating intertrochanteric femoral fracture. (B) Initial postoperative radiograph after closed reduction and internal fixation with PFNA. (C) Radiograph at three-week follow-up showing secondary fracture dislocation and implant migration with blade cut-out.

was discussed interdisciplinarily and a minimally invasive therapy was preferred to a more invasive conversion to THA. After reviewing the treatment options with the patient and receiving her consent she was taken to the operating room. The patient was positioned supine on a traction table. Prophylactic stabilization of the fracture using threaded K-wires was performed in order not to jeopardize the planned implantation of the cement plug by dislocation of the blade canal after removing the helical blade (Fig. 2A). According to the previously published technique by Hanke et al. [9], a standard medullary cement plug (PE Stüthmer/Weber size 3, diameter: 13.5 mm; Zimmer GmbH, Winterthur, Switzerland) designed for use in cemented hip stem arthroplasty, was cut to 10 mm of length and rounded proximally according to the femoral head sphericity (Fig. 3). The tip of the plug was sealed using cement and subsequently positioned to seal the femoral head defect under fluoroscopic control (Fig. 2B, C). Additionally a small tutoplast cancellous bloc (Novomedics, Zürich, Switzerland) was positioned for additional biological defect filling. Fracture reposition was

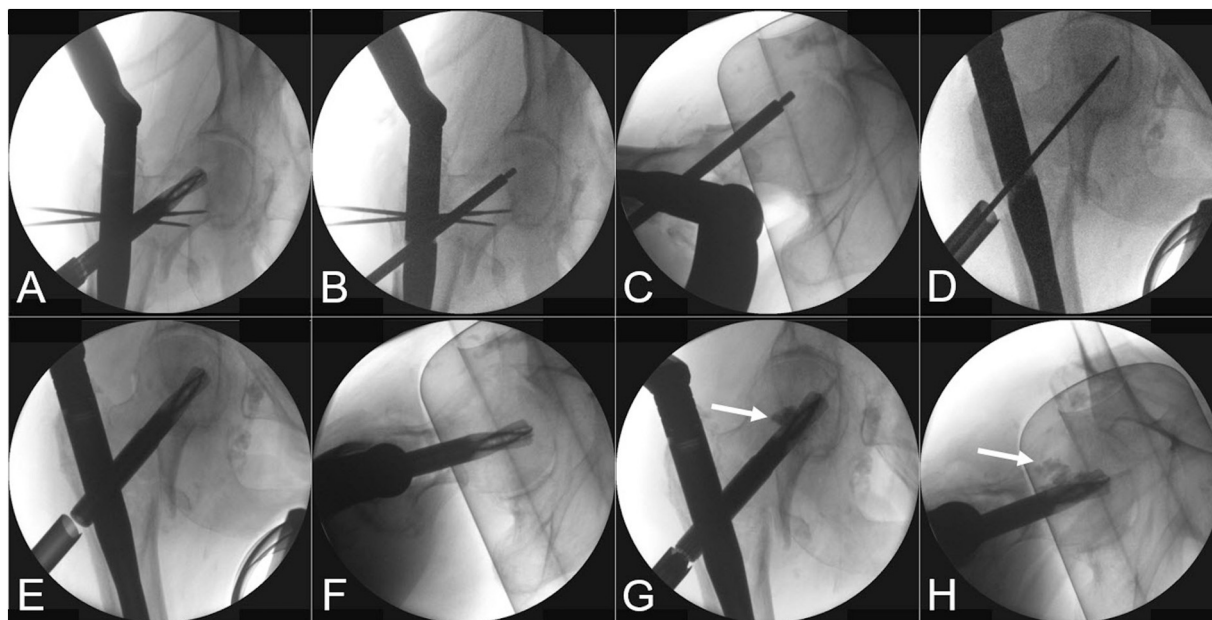


Fig. 2. Radiographs showing (A) Prophylactic fixation and helical blade removal. (B; C) Insertion of the medullary cement plug. (D) Positioning of guide wire in center-center position. (E; F) Replantation of the helical blade in center-center position. (G; H) Cement augmentation and defect filling by the cement augmentation (arrow) is visible.

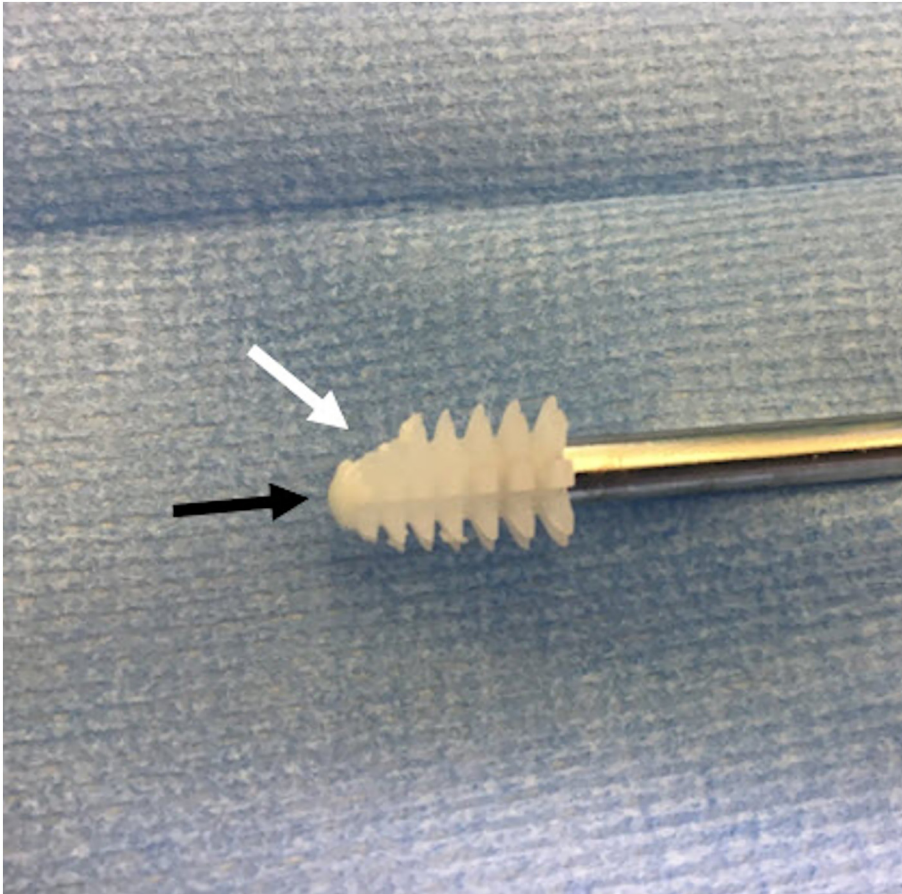


Fig. 3. Medullary cement plug after preparation by shorting and rounding proximally according to the femoral head sphericity (white arrow). The tip of the plug was sealed using cement (black arrow).

accomplished by using in-line traction and internal rotation of the leg via the traction table and additionally by use of the PFN-A insertion handle to add leverage to the nail. Due to callus formation in this three-week-old fracture, a correction of the valgus deformity with the concomitant malposition of the calcar was no longer possible without dissolving the callus, which we considered too invasive. However, the secondary displacement with malposition of the head and neck in retrotorsion was corrected by internally rotating the lower leg on the traction table, which allowed us to re-position the guide wire in center-center position (Fig. 2D). Drilling of the lateral cortex with subsequent helical blade implantation was performed (Fig. 2E; F), followed by cement augmentation (Traumacem V+, DePuy Synthes, Johnson & Johnson AG, Zuchwil, Switzerland) under fluoroscopic leakage control (Fig. 2G; H). The postoperative regime included wheel-chair mobilization for 4 weeks, partial weight-bearing for further 4 weeks and limited flexion of 90°. Full weight-bearing was established 2 months after the revision operation. At 1-year follow-up she presented no grown pain. Her activity level was measured with the New Mobility Score (NMS) [11]; she had regained the pre-trauma NMS level of 6 points (wheel walker). Conventional radiographs showed a healed fracture, with no implant migration and no progression of osteoarthritis (Fig. 4).

Discussion

Implant cut-out remains a feared mode of failure of CMN and resultant patient morbidity [12]. Two predominant modes of failure can be distinguished after treatment with CMN: (1) occurring through progressive varus collapse and retrotorsion of the femoral head resulting in superior migration called “cut-out” and (2) medial perforation also called “cut-through” of the blade without loss of fracture reduction [17–22]. One study reported that almost half of the helical blades failed by cut-through [18]. This was previously attributed to radial compaction of cancellous bone due to blade insertion lowering the risk for cut-out and on the other hand this same mechanism likely contributes to the risk of failure by cut-through [12,17]. In comparison, the classical mechanism of failure for lag screws is cut-out [18]. The contact surface area for screw-design implants compared to helical-blade designs is noted to be four times larger and consequently reduces the risk of medial migration and cut-through. The presented case shows classical cut-out as the mode of failure (Fig. 1).

Cement augmentation of the PFN-A blade might have the potential to prevent reoperations by strengthening the osteosynthesis construct [7]. Biomechanical studies have shown that augmentation of the femoral head yielded a significantly superior rotational

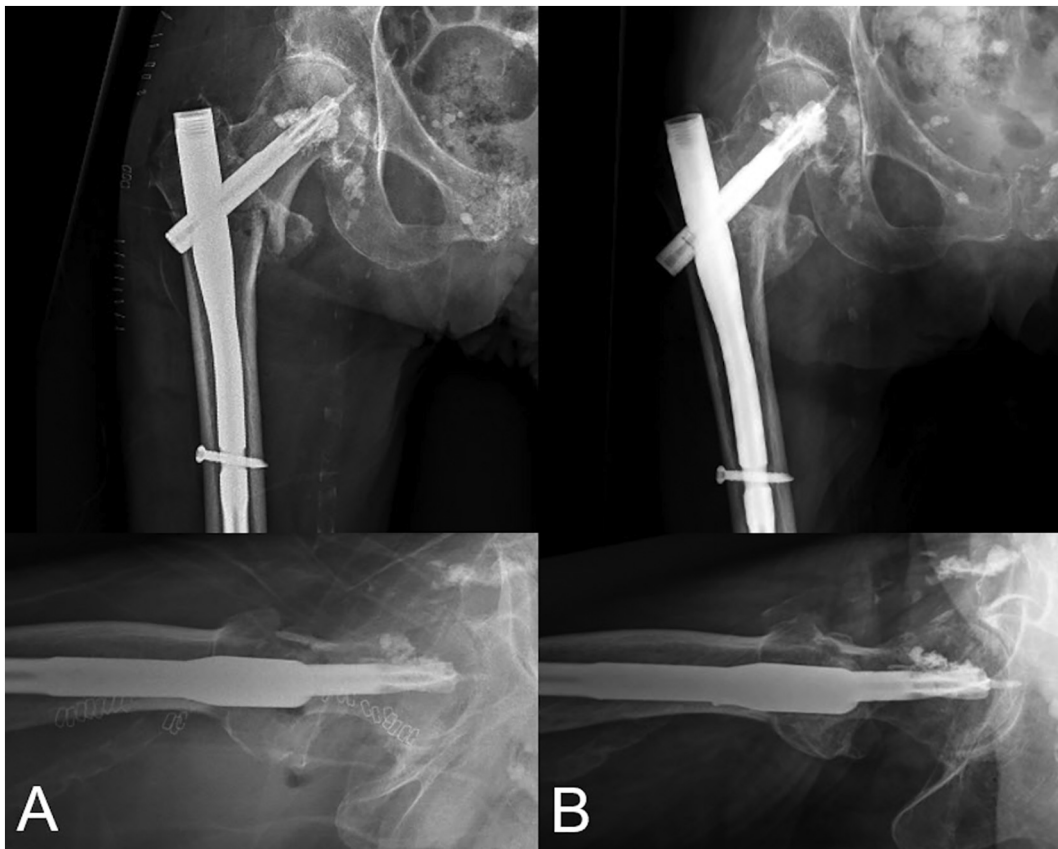

Fig. 4. Radiographs (A) Directly postoperative after the aforementioned revision. (B) At one-year follow-up. Fracture consolidation is visible; neither secondary dislocation nor implant migration is visible.

stability, as well as an enhanced pull-out resistance compared to the non-augmented state [23,24]. Therefore, cement augmentation may play an important role in revision of failed helical blades by providing the needed stability. Nevertheless, cement leakage into the hip joint must be prevented.

Various studies have evaluated factors influencing the risk of implant failure. The quality of reduction was seen as important for mechanical stability of these fractures [28–30]. Avoiding varus reduction is a key factor to prevent mechanical complications and even slight valgus reduction is proposed [28,31]. Furthermore, fracture reduction in the axial plane is found to be significant in preventing mechanical complications [29]. Many authors recommend a center-center or inferior-center position of the head-neck fixation device as the optimal position [28,32–34]. Suboptimal fracture reposition and improper placement of the helical blade could have been the reason for failure in this patient (Fig. 1).

Previous studies have claimed that the only valid option to salvage failure of PFN-A helical blades is the conversion to THA [8]. Conversion of failed CMN to THA is technically demanding and is associated with long operation times, substantial blood loss, need for a revision femoral component, higher risk of periprosthetic fracture and dislocation [35,36]. Consequently, nail revision to prevent the need for THA may be considered in patients unsuitable for THA (e.g. due to severe comorbidities) and in low demand patients.

This report has several limitations. It is a single-case report, with the associated limitations of retrospective follow-up of a single patient. Intraoperative radiographs were carried out, using the known size of the plug, which in combination with the radiographically visible inserter device allowed us to calculate the insertion depth. The plug itself, however, is not radiopaque, and a direct intraoperative radiographic visualization of the depth was not possible. As determined in the previous technical note, sufficient filling of the defect by use of the plug and seating of the plug was seen, as retrograde cementation back along the screw was noted and no intraarticular cement was visualized [9]. In addition, the defect and plug were not in a region of weight bearing, and subsequent osteoarthritis was not noted. A dislocation of the bone plug cannot be ruled out as well, but an osseous defect in the region the bone plug was placed was not visible on radiograph, indicating that a dislocation was unlikely. A further limitation of the report is the short follow-up of only one year after revision surgery. However larger follow-up studies presenting outcomes after the use of a CMN did not present longer minimal follow-up periods and therefore the follow-up time of only one year seems appropriate [7,37,38]. Furthermore, no evaluation regarding avascular femoral head necrosis (AVN) was performed. The risk for AVN after cement augmentation of the femoral head has been discussed controversially [37,40]. Nevertheless, at one year clinical and radiological follow-up no

signs of AVN were apparent.

In conclusion, blade exchange, cement augmentation after sealing with a cement plug may be considered as a salvage procedure in select cases to revise a failed fixation with a CMN.

Compliance with ethical standards

Declaration of competing interest

The authors declare that they have no conflict of interest.

Funding

There is no funding source.

Ethical approval

The local institutional review board approved this study.

Informed consent

Informed consent was obtained from the individual participant included in the study.

CRedit authorship contribution statement

M.S. Hanke: Conceptualization, Data curation, Writing - original draft, Writing - review & editing, Visualization. **N.A. Beckmann:** Conceptualization, Data curation, Writing - original draft, Writing - review & editing, Supervision. **M.J. Keel:** Writing - review & editing, Supervision. **K.A. Siebenrock:** Writing - review & editing, Supervision. **J.D. Bastian:** Conceptualization, Methodology, Data curation, Writing - original draft, Writing - review & editing, Supervision, Project administration.

References

- [1] R. Azagra, F. López-Expósito, J.C. Martín-Sánchez, A. Aguyé, N. Moreno, C. Cooper, A. Díez-Pérez, E.M. Dennison, Changing trends in the epidemiology of hip fracture in Spain, *Osteoporos. Int.* 25 (2014) 1267–1274, <https://doi.org/10.1007/s00198-013-2586-0>.
- [3] J.O. Anglen, J.N. Weinstein, American Board of Orthopaedic Surgery Research Committee, Nail or plate fixation of intertrochanteric hip fractures: changing pattern of practice. A review of the American Board of Orthopaedic Surgery Database, *J. Bone Joint Surg. Am.* 90 (2008) 700–707, <https://doi.org/10.2106/JBJS.G.00517>.
- [5] C. Kammerlander, S. Erhart, H. Doshi, M. Gosch, M. Blauth, Principles of osteoporotic fracture treatment, *Best Pract. Res. Clin. Rheumatol.* 27 (2013) 757–769, <https://doi.org/10.1016/j.berh.2014.02.005>.
- [6] K. Ito, R. Hungerbühler, D. Wahl, R. Grass, Improved intramedullary nail interlocking in osteoporotic bone, *J. Orthop. Trauma* 15 (2001) 192–196, <https://doi.org/10.1097/00005131-200103000-00008>.
- [7] C. Kammerlander, E. Hem, T. Klopfer, F. Gebhard, A. Sermon, M. Dietrich, O. Bach, Y. Weil, R. Babst, M. Blauth, Cement augmentation of the Proximal Femoral Nail Antitraction (PFNA) - a multicentre randomized controlled trial, *Injury* 49 (2018) 1436–1444.
- [8] A. Brunner, M. Büttler, U. Lehmann, H.C. Frei, R. Kratter, M. Di Lazzaro, A. Scola, A. Sermon, R. Attal, What is the optimal salvage procedure for cut-out after surgical fixation of trochanteric fractures with the PFNA or TFN?: a multicentre study, *Injury* 47 (2016) 432–438, <https://doi.org/10.1016/j.injury.2015.11.027>.
- [9] M. Hanke, V. Djonov, M. Tannast, M.J. Keel, J.D. Bastian, Prevention of cement leakage into the hip joint by a standard cement plug during PFN-A cement augmentation: a technical note, *Arch. Orthop. Trauma Surg.* 136 (2016) 747–750, <https://doi.org/10.1007/s00402-016-2447-3>.
- [10] D.J. Doyle, E.H. Garmon, American Society of Anesthesiologists Classification (ASA class), Stat Pearls, Stat Pearls Publishing, Treasure Island (FL), 2019.
- [11] M.J. Parker, C.R. Palmer, A new mobility score for predicting mortality after hip fracture, *J. Bone Joint Surg Br* 75 (1993) 797–798.
- [12] I. Ibrahim, P.T. Appleton, J.J. Wixted, J.P. DeAngelis, E.K. Rodriguez, Implant cut-out following cephalomedullary nailing of intertrochanteric femur fractures: are helical blades to blame? *Injury* 50 (2019) 926–930, <https://doi.org/10.1016/j.injury.2019.02.015>.
- [17] W. Liu, D. Zhou, F. Liu, M.J. Weaver, M.S. Vrahas, Mechanical complications of intertrochanteric hip fractures treated with trochanteric femoral nails, *J. Trauma Acute Care Surg.* 75 (2013) 304–310, <https://doi.org/10.1097/TA.0b013e31829a2c43>.
- [18] L. Stern, J. Gorczyca, S. Kates, J. Ketz, G. Soles, C. Humphrey, Radiographic review of helical blade versus lag screw fixation for cephalomedullary nailing of low-energy peritrochanteric femur fractures: there is a difference in cutout, *J. Orthop. Trauma* 31 (2017) 305–310, <https://doi.org/10.1097/BOT.0000000000000853>.
- [19] S.A. Flores, A. Woolridge, C. Caroom, M. Jenkins, The utility of the tip-apex distance in predicting axial migration and cutout with the trochanteric fixation nail system helical blade, *J. Orthop. Trauma* 30 (2016) e207–e211, <https://doi.org/10.1097/BOT.0000000000000505>.
- [20] A. Brunner, J.A. Jöckel, R. Babst, The PFNA proximal femur nail in treatment of unstable proximal femur fractures—3 cases of postoperative perforation of the helical blade into the hip joint, *J. Orthop. Trauma* 22 (2008) 731–736, <https://doi.org/10.1097/BOT.0b013e3181893b1b>.
- [21] M.A. Frank, R.S. Yoon, P. Yalamanchili, E.W. Choung, F.A. Liporace, Forward progression of the helical blade into the pelvis after repair with the Trochanter Fixation Nail (TFN), *J. Orthop. Trauma* 25 (2011) e100–e103, <https://doi.org/10.1097/BOT.0b013e318206cd20>.
- [22] T. Chapman, B. Zmistowski, J. Krieg, S. Stake, C. Jones, E. Levicoff, Helical blade versus screw fixation in the treatment of hip fractures with cephalomedullary devices: incidence of failure and atypical “medial cutout”, *J. Orthop. Trauma* 32 (2018) 397–402, <https://doi.org/10.1097/BOT.0000000000001193>.
- [23] S. Erhart, W. Schmoelz, M. Blauth, A. Lenich, Biomechanical effect of bone cement augmentation on rotational stability and pull-out strength of the Proximal Femur Nail Antitraction™, *Injury* 42 (2011) 1322–1327, <https://doi.org/10.1016/j.injury.2011.04.010>.
- [24] F. Fensky, J.V. Nüchtern, J.P. Kolb, S. Huber, M. Rupperecht, S.Y. Jauch, K. Sellenschloh, K. Püschel, M.M. Morlock, J.M. Rueger, W. Lehmann, Cement augmentation of the proximal femoral nail antitraction for the treatment of osteoporotic peritrochanteric fractures—a biomechanical cadaver study, *Injury* 44 (2013) 802–807, <https://doi.org/10.1016/j.injury.2013.03.003>.
- [28] A. Turgut, Ö. Kalendarer, L. Karapınar, M. Kumbaracı, H.A. Akkan, H. Ağuş, Which factor is most important for occurrence of cutout complications in patients treated with proximal femoral nail antitraction? Retrospective analysis of 298 patients, *Arch. Orthop. Trauma Surg.* 136 (2016) 623–630, <https://doi.org/10.1007/s00402-016-2447-3>.

- 1007/s00402-016-2410-3.
- [29] N. Takigawa, H. Moriuchi, M. Abe, K. Yasui, H. Eshiro, M. Kinoshita, Complications and fixation techniques of trochanteric fractures with the TARGON(R) PF, *Injury* 45 (Suppl. 1) (2014) S44–S48, <https://doi.org/10.1016/j.injury.2013.10.036>.
- [30] A. Herman, Y. Landau, G. Gutman, V. Ougortsin, A. Chechick, N. Shazar, Radiological evaluation of intertrochanteric fracture fixation by the proximal femoral nail, *Injury* 43 (2012) 856–863, <https://doi.org/10.1016/j.injury.2011.10.030>.
- [31] H. Andruszkow, M. Frink, C. Fromke, A. Matityahu, C. Zeckey, P. Mommsen, S. Suntardjo, C. Krettek, F. Hildebrand, Tip apex distance, hip screw placement, and neck shaft angle as potential risk factors for cut-out failure of hip screws after surgical treatment of intertrochanteric fractures, *Int. Orthop.* 36 (2012) 2347–2354, <https://doi.org/10.1007/s00264-012-1636-0>.
- [32] K. De Bruijn, D. den Hartog, W. Tuinebreijer, G. Roukema, Reliability of predictors for screw cutout in intertrochanteric hip fractures, *J. Bone Joint Surg. Am.* 94 (2012) 1266–1272, <https://doi.org/10.2106/JBJS.K.00357>.
- [33] M.R. Baumgaertner, S.L. Curtin, D.M. Lindskog, J.M. Keggi, The value of the tip-apex distance in predicting failure of fixation of peritrochanteric fractures of the hip, *J. Bone Joint Surg. Am.* 77 (1995) 1058–1064, <https://doi.org/10.2106/00004623-199507000-00012>.
- [34] P. Kane, B. Vopat, W. Heard, N. Thakur, D. Paller, S. Koruprolu, C. Born, Is tip apex distance as important as we think? A biomechanical study examining optimal lag screw placement, *Clin. Orthop. Relat. Res.* 472 (2014) 2492–2498, <https://doi.org/10.1007/s11999-014-3594-x>.
- [35] S.M.J. Mortazavi, M. R Greenky, O. Bican, P. Kane, J. Parvizi, W.J. Hozack, Total hip arthroplasty after prior surgical treatment of hip fracture is it always challenging? *J. Arthroplast.* 27 (2012) 31–36, <https://doi.org/10.1016/j.arth.2011.05.014>.
- [36] M.J. Archibeck, J.T. Carothers, K.R. Tripuraneni, R.E. White, Total hip arthroplasty after failed internal fixation of proximal femoral fractures, *J. Arthroplast.* 28 (2013) 168–171, <https://doi.org/10.1016/j.arth.2012.04.003>.
- [37] C. Kammerlander, H. Doshi, F. Gebhard, A. Scola, C. Meier, W. Linhart, M. Garcia-Alonso, J. Nystal, M. Blauth, Long-term results of the augmented PFNA: a prospective multicenter trial, *Arch. Orthop. Trauma Surg.* 134 (2014) 343–349, <https://doi.org/10.1007/s00402-013-1902-7>.
- [38] L. Ahrengart, H. Törnkvist, P. Fornander, K.-G. Thorngren, L. Pasanen, P. Wahlström, S. Honkonen, U. Lindgren, A randomized study of the compression hip screw and gamma nail in 426 fractures, *Clin. Orthop. Relat. Res.* (2002) 209–222, <https://doi.org/10.1097/00003086-200208000-00024>.
- [40] M. Blankstein, D. Widmer, M. Götzen, L. Hofmann-Fliri, R.G. Richards, B. Gueorguiev, M. Windolf, Assessment of intraosseous femoral head pressures during cement augmentation of the perforated proximal femur nail antirotation blade, *J. Orthop. Trauma* 28 (2014) 398–402, <https://doi.org/10.1097/BOT.000000000000069>.