


ORIGINAL RESEARCH

An *in vitro* endodontic model to quantify the accessory canal filling potential of the vertical and lateral condensation techniques

Thomas Gerhard Wolf, DDS, Priv.-Doz. Dr. med. dent.^{1,2} ; Louisa Willems, DDS, Dr. med. dent.²; and Benjamín Briseño-Marroquín, DDS, MDS, Prof. Dr. med. dent.^{1,2}

¹ Department of Restorative, Preventive and Pediatric Dentistry, School of Dental Medicine, University of Bern, Bern, Switzerland

² Department of Periodontology and Operative Dentistry, University Medical Center of the Johannes Gutenberg-University Mainz, Mainz, Germany

Keywords

accessory canal filling, endodontic model, lateral condensation, vertical condensation.

Correspondence

Priv.-Doz. Dr. Thomas Gerhard Wolf,
Department of Restorative, Preventive and
Paediatric Dentistry, School of Dental Medicine,
University of Bern, Freiburgstrasse 7, CH-3010
Bern, Switzerland. Email:
thomas.wolf@zmk.unibe.ch

doi: 10.1111/aej.12465

(Accepted for publication 25 October 2020.)

Abstract

The purpose of this study was to determine the accessory canal filling potential of vertical and lateral condensation techniques in simulated root canals. A total of 130 prepared transparent, straight-simulated root canals with nine accessory canals (0.02 mm), prepared at different levels from the apical, were obturated with vertical ($n = 100$) and 30 lateral condensation ($n = 30$) techniques. 50.33% of the accessory canals obturated with vertical condensation were completely filled with gutta-percha; 37.78% completely filled with gutta-percha and sealer. 61.11% of the accessory canals were completely filled with sealer only using the lateral condensation technique. The vertical condensation technique filled the accessory canals more frequently than the lateral condensation techniques. The lateral condensation technique was not capable of delivering gutta-percha to any of the accessory canals. The apical third showed the lowest accessory canal filling frequency with both techniques.

Introduction

The final aim of an endodontic treatment is to completely seal the root canal system in order to prevent infiltration by toxins and bacteria, thus preventing further inflammation or re-inflammation of the periapical tissues (1). It is particularly important that the root canal filling materials employed also adapt to unevenly or partially mechanically unprepared root canal system areas in order to be able to seal them three-dimensionally and as hermetically as possible (1). Most of the time the root canal filling consists of a semi-solid material combined with a root canal sealer. The sealer is responsible for sealing the interface between the semi-solid material and the root canal walls. Gutta-percha has been used in endodontics for more than 100 years (2) and has established itself as the most widely employed endodontic semi-solid filling material.

Due to morphological conditions, one third to one half of the root canal system remains un-instrumented during preparation; for this reason, chemical cleaning with adequate irrigating solutions is of utmost importance and has

proven to positively enhance treatment success (3). The internal three-dimensional complexity of the root canal system morphology of all types of teeth has been reported on widely (4,5). Accessory or lateral canals, like the entire root canal system, can contain bacteria and/or necrotic tissue that could cause periodontal disease (6) and persisting endodontic infection (7,8). Therefore, an adequate obturation, also of accessory canals, is of great importance for mid- and long-term endodontic treatment success. The importance of cleaning and filling accessory canals can be reinforced through noting the possibility that endodontic re-infection can also occur from the periodontium towards the pulp space or that periodontal disease can occur in the opposite direction (9).

Although it can only be sustained from a clinical perspective, the cleaning and filling of accessory portals of exit can enhance the success of endodontic therapy. This has been mostly proven based on clinical case reports alone (8,10); however, from a clinical point of view, the possibility that these types of portals of exit could cause a root canal system infection should be taken habitually into consideration (11-13). One of the main problems

when analysing the results obtained in investigations concerning the quality/characteristics of root canal filling methods/materials, either with *in vivo*, *in vitro* or *ex vivo* research models, is to be able to report an objective statistical analysis given through an accurate quantification of the results obtained. Thus, the aim of this investigation was to introduce a novel objective and quantifiable *in vitro* research method to measure the sealing potential of gutta-percha and sealer used with the vertical and lateral condensation techniques.

Material and methods

A total of 130 straight-simulated root canal models ($14 \text{ mm} \pm 0.2 \text{ mm}$; Müller, Konstanz, Germany) were used in this investigation. These were divided into two groups ($n = 65$ each) and the main canals prepared with conventional Reciproc or Reciproc blue (VDW, Munich, Germany) instruments to a tip size ISO 40 (R40) with three pecking motions and under 70% alcohol irrigation after each motion. Nine simulating accessory canals ($\text{Ø} 0.2 \text{ mm} \pm 0.02 \text{ mm}$) with a round shape were drilled in opposite sides of the root canal model (Fig. 1) with a bench drilling machine (Proxxon Tischbohrmaschine TBM 220; PROXXON S.A., Wecker, Luxemburg). The length of the accessory canals varied from 1.5 to 2 mm ($\pm 0.05 \text{ mm}$), depending on their third localisation (coronal to apical) with respect to the main canal. Six accessory canals were located on one side of the main canal at 1, 4, 6, 9, 11 and 14 mm and three more on the opposite side at 2.5, 7.5 and 12.5 mm from the apical level (Fig. 1).

100 of the root canal models were obturated with thermoplastic vertical condensation and the remaining 30 simulated root canals were obturated with lateral condensation; these served as the control group. In the vertical condensation group sealer (2Seal easymiX; VDW,

Munich, Germany) was applied to the main canal with a paper point, and then a master point R40 (VDW, Munich, Germany) was placed at working length. The down-packing was done with a BeeFill 2in1 (VDW, Munich, Germany) device set at a temperature of 100°C , a heat carrier size 40/.03 (VDW, Munich, Germany) and Machtou pluggers (VDW, Munich, Germany). The back-packing was done with the same device with the temperature set at 200°C by injecting 2–3 mm portions of flowable gutta-percha and compacting them with the pluggers until the main canal was filled up to the coronal pre-set level. In the lateral condensation group, the simulated root canals were prepared with Reciproc blue (R40) instruments and the main canal walls were coated with sealer (2seal easymix) by means of a paper point. The canals were laterally condensed with a master point size R40, 4–5 lateral gutta-percha points (Coltene Holding, Altstätten, Switzerland) and finger spreaders (VDW, Munich, Germany) sizes ISO 15 or 20. The lateral gutta-percha points were always coated with sealer prior to insertion. The excess coronal material was removed by means of a Gutta Cut device (VDW, Munich, Germany).

The filling material type, length and third localisation of a total of 900 accessory canals in the vertical condensation and 270 in the lateral condensation (control) groups were visualised under magnification (10x; Keyence VHX Microscope; Keyence, Neu-Isenburg, Germany) and by means of photographic documentation quantitatively analysed by one calibrated operator. A quantitative classification for determining the filling quality was established with the following categories: i) completely filled with gutta-percha, ii) completely filled with gutta-percha and sealer, iii) completely filled with sealer, iv) partially filled with sealer and v) unfilled. The data of the vertical and lateral condensation groups are given in the filling categories frequency tables (Tabs. 1–4). Statistical differences between the accessory canal filling in all canal

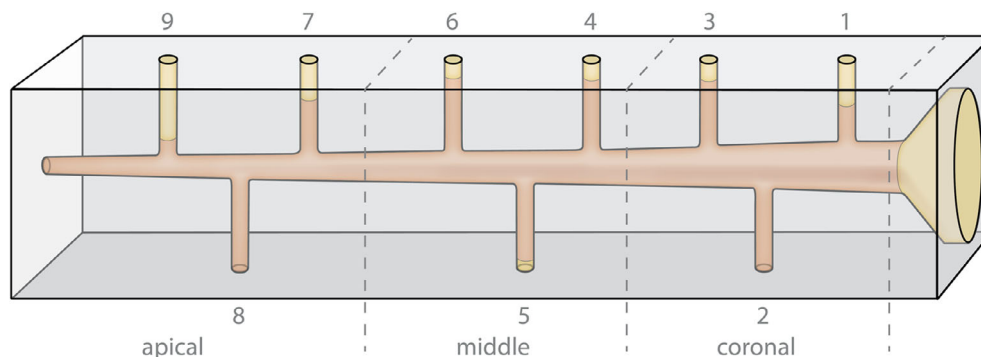


Figure 1 Diagrammatic representation of the model of the simulated straight root canal in a plastic block (LxWxT 24, 9 and 4 mm) already prepared to an apical size 40 with (R40). The preparation, number and location of canal third of the accessory canals ($\text{Ø} 0.2 \pm 0.002 \text{ mm}$) can be observed.

thirds, depending on the preparation instrument in the vertical condensation group, were calculated at the Institute for Medical Biometry, Epidemiology and Informatics (IMBEI, University Medical Center of the Johannes Gutenberg University of Mainz, Mainz, Germany) by means of the two-way analysis of variance (ANOVA). The means of the three thirds were subjected to a normalising transformation ($[\sqrt{\arcsin\{\text{third mean}/100\}}]$) to assure a normal distribution. The results were adjusted according to the Bonferroni method. Significance was established at $p > 0.05$.

Results

The summary of the obturation frequency of all nine accessory canals, regardless of their canal third localisation, with vertical ($n = 900$) and lateral ($n = 270$) condensation are shown in Table 1. 88.11% of all accessory canals were completely filled with either gutta-percha or gutta-percha and sealer in the vertical condensation group. On the other hand, in the lateral condensation group only 61.1% of all accessory canals were completely filled, and only with sealer. Over-fillings with gutta-percha were observed only in the vertical condensation group.

The obturation frequency in the coronal, middle and apical thirds with vertical ($n = 100$) and lateral ($n = 30$) condensation are shown in Table 2. In the coronal third, 92.67% of all accessory canals were completely filled with gutta-percha and gutta-percha and sealer in the vertical condensation group. 57.78% of the accessory canals were completely filled with only sealer in the coronal third in the lateral condensation group. In the middle third, 95.33% of all accessory canals were completely filled with either gutta-percha or gutta-percha and sealer in the vertical condensation group. In the lateral condensation group, 81.11% of all accessory canals were completely filled in this third, but only with sealer. In the apical third, 83.00% of all accessory canals were completely filled with gutta-percha and gutta-percha and sealer in the vertical condensation group. In the lateral condensation group, 44.44% of the accessory canals were completely filled with sealer alone. In the apical third, it

could be observed that the more apical the accessory canal was localised the more deficient the filling quality was with both techniques.

In general, it was observed that a distinct higher frequency of completely filled accessory canals with either gutta-percha and/or gutta-percha and sealer was observed with the vertical condensation technique and that it was not possible with lateral condensation, as expected, to place gutta-percha within the accessory canals. It could also be observed that with lateral condensation, the capacity of the sealer to flow into the accessory canals was higher the more apically the accessory canals were located. A clear difference between vertical (4.44%) and lateral (26.67%) condensation was also observed in accessory canals that were partially or completely unfilled. A significant difference was observed in favour of Reciproc blue when compared with Reciproc ($p = 0003$), but; only in the apical third (Fig. 2).

Discussion

In this *in vitro* study, a novel simulated endodontic model which allowed an objective quantifiable statistical analysis of the results obtained was employed to evaluate the capability of thermoplastic vertical and cold lateral condensation techniques with gutta-percha and sealer to obturate accessory canals. In endodontic research, the use of teeth in *ex vivo* investigation models would certainly be closer to a clinical situation (14,15). Nevertheless, a number of uncontrollable research parameters (root canal morphology, dentin hardness and structure, location of accessory canals etc.) as well as a subjective radiological evaluation of the results (such as yes/no or filled/unfilled) mean that an inherently unsatisfactory statistical analysis of the results is unavoidable. The advantages of an *in vitro* research methodology are the disadvantages of the *ex vivo* research methodology and vice versa. One of the main aims of an *in vitro* study, as with a resin endodontic model, should always be to deliver qualitatively and quantitatively reproducible information of a large number of samples that can also be confidentially extrapolated into daily practice. Simulated root and/or accessory canals allow objective results

Table 1 Accessory canal filling frequency categories with vertical condensation (VC; $n = 900$) and lateral condensation (LC; $n = 270$) techniques irrespective of their third canal localisation (Co = completely filled, GP = gutta-percha, Se = sealer, Part = partially filled; Overfill = only gutta-percha)

Technique	<i>n</i>	1 (Co-GP)		2 (Co-Gp/Se)		3 (Co-Se)		4 (Part-Se)		5 (Unfilled)		Overfill	
		<i>N</i>	%	<i>n</i>	%	<i>n</i>	%	<i>n</i>	%	<i>n</i>	%	<i>n</i>	%
VC	900	453	50.33	340	37.78	20	2.22	71	7.89	16	1.78	73	8.11
LC	270	0	0.00	0	0.00	165	61.11	91	33.70	14	5.19	0	0.00

Table 2 Accessory canal filling frequency categories with vertical condensation (VC; $n = 100$) and lateral condensation (LC; $n = 30$) techniques in the apical, middle and coronal thirds of the canal (Co = completely filled, GP = gutta-percha, Se = sealer, Part = partially filled)

Third	Technique		1 (Co-GP)		2 (Co-Gp/Se)		3 (Co-Se)		4 (Part-Se)		5 (Unfilled)	
		<i>n</i>	<i>n</i>	%	<i>n</i>	%	<i>n</i>	%	<i>n</i>	%	<i>n</i>	%
Coronal	VC-1	100	14	14.00	73	73.00	0	0.00	11	11.00	2	2.00
	VC-2	100	72	72.00	24	24.00	0	0.00	4	4.00	0	0.00
	VC-3	100	74	74.00	21	21.00	0	0.00	5	5.00	0	0.00
	LC-1	30	0	0.00	0	0.00	11	36.67	18	60.00	1	3.33
	LC-2	30	0	0.00	0	0.00	23	76.67	7	23.33	0	0.00
	LC-3	30	0	0.00	0	0.00	18	60.00	11	36.67	1	3.33
Middle	VC-4	100	72	72.00	23	23.00	0	0.00	5	5.00	0	0.00
	VC-5	100	87	87.00	11	11.00	0	0.00	2	2.00	0	0.00
	VC-6	100	63	63.00	30	30.00	0	0.00	6	6.00	1	1.00
	LC-4	30	0	0.00	0	0.00	23	76.67	6	20.00	1	3.33
	LC-5	30	0	0.00	0	0.00	24	80.00	6	20.00	0	0.00
	LC-6	30	0	0.00	0	0.00	26	86.67	4	13.33	0	0.00
Apical	VC-7	100	41	41.00	51	51.00	2	2.00	5	5.00	1	1.00
	VC-8	100	25	25.00	59	59.00	5	5.00	6	6.00	5	5.00
	VC-9	100	5	5.00	48	48.00	13	13.00	27	27.00	7	7.00
	LC-7	30	0	0.00	0	0.00	22	73.33	8	26.67	0	0.00
	LC-8	30	0	0.00	0	0.00	17	56.67	11	36.67	2	6.67
	LC-9	30	0	0.00	0	0.00	1	3.33	20	66.67	9	30.00

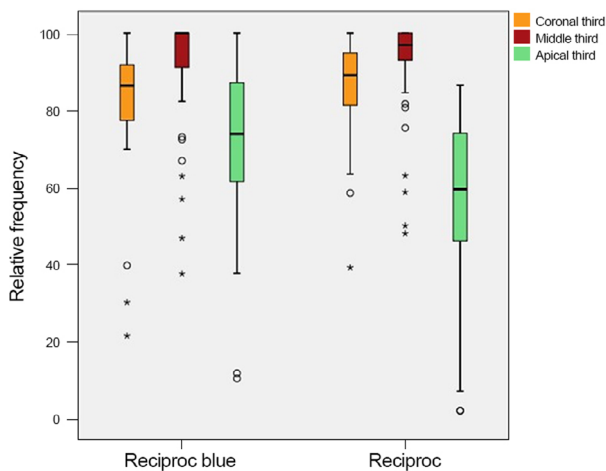


Figure 2 Box plot of the comparison between conventional Reciproc and Reciproc blue regarding a complete accessory canal (gutta-percha and gutta-percha and sealer) filling in the coronal, middle and apical canal thirds ($n = 50$). A significantly higher ($p = 0003$) accessory canal filling of Reciproc blue frequency was observed only in the apical third.

quantification in a large number of samples and the research parameters standardisation (dimensions, preparation size and their number and location). Furthermore, since the aim of the study was not to compare the shaping characteristics of a given system, the use of straight-simulated root canals allowed the reduction of parameters which are also difficult to standardise (curvature

location and degree and operator dexterity). In this study it was decided to irrigate the simulated root canals with 70% alcohol rather than with established irrigating protocols. This rationale is solely based on observations gained by the authors during multiple hands-on courses. The cutting file motion is smoother and plastic clogging is palpably reduced when shaping root canals embedded in plastic blocks with alcohol. The use of 70% alcohol as an irrigating solution in this investigation is certainly not aimed to trivialise the importance of a correct root canal irrigation protocol (3).

The frequent occurrence of accessory canals raises the importance of their cleaning (and shaping if possible) and obturation. The ability and obturation frequency of different techniques using a resin model (16,17), metallic blocks (18) and human teeth (14,15,19) to fill accessory canals with a similar experimental set-up have been reported. Goldberg et al. (14) were of the opinion that their *ex vivo* model is closer to a clinical situation and that it is difficult to compare dentine with resin. However, natural teeth, if not cleared, and metal blocks can only be qualitatively evaluated. Moreover, the ability to discriminate between gutta-percha and sealer in the accessory canals is not possible through radiological evaluation (20). In transparent blocks, as used in our study, or in chemically decalcified teeth as well (19), an objective quantitative evaluation of the corresponding data through direct visualisation becomes feasible. Similar accessory canal obturation results with clearing and

radiographic methods have been reported (21). Nonetheless, it should be taken into consideration that in this study, the preparation and obturation of the accessory canals, as well as control radiographs, were made after the specimens were cleared.

To the best of our knowledge, until now there has not been any *ex vivo* or *in vitro* report that has used a similar number and location of accessory canals as the present one. This rationale could be explained by the need to quantify the behaviour of the different filling techniques employed at different root canal levels. The accessory canals were prepared in each root canal third in this investigation, but; without taking into account their higher occurrence frequency in the apical third (5). However, an homogenous accessory canal distribution in the root thirds allowed an obturation quality and frequency analysis in each one of them. The diameters of the accessory canals (0.2 mm/ 200 μ m) are within the range of the ones reported in the literature (15). Other studies (22,23) report smaller diameters of accessory canals; however, these concern incisor teeth and are also within the range of the accessory canals diameters employed in our study. Venturi *et al.* (19) report a cylindrical shape in 57.6 and 49.7% of accessory canals at the coronal and apical thirds, respectively. Subsequently the authors also observed tapered accessory canals which were not taken into consideration in this study. The shape of the accessory canals in this investigation needed to be cylindrical due to the non-tapered drills employed for their preparation. A smear layer complete removal is desirable, still, it inevitably develops during preparation of the main canals and could lead to a clog of the accessory canal entrances (24,25), thus, influencing one research parameter. Since the accessory canals in human teeth and in this study have a larger diameter than the dentine tubules (25), it is likely that the smear layer could penetrate into natural and simulated accessory canals. No smear clogging was observed either in the main nor accessory canals in this study; however, despite all magnification efforts undertaken, a non-recognisable remaining plastic lubricating layer could have still remained.

The highest degree of partially filled with only sealer and unfilled accessory canals with vertical condensation (7.00%) was observed in the accessory canal located 1 mm from apical. With this technique in all canal thirds, a total of 453 and 340 (88.11%) of the accessory canals were filled with gutta-percha or with gutta-percha and sealer, respectively. These result tendencies are consistent with other observations reported in the literature (15). However, our results with a complete gutta-percha filling (50.33%) are higher than the ones reported by these authors (8.3 and 23.3%) with different techniques for vertical condensation. Our results demonstrate the

capability of vertical condensation to fill accessory canals in the apical region as well. Nevertheless, accessory canals in the apical third (23.67%) were less often completely filled with vertical condensation and gutta-percha alone when compared with the ones in the middle (74.00%) and the coronal (53.33%) thirds. This could be explained by the fact that gutta-percha is actually an outstanding isolation material, and thus the temperature required to achieve an adequate flowability of the gutta-percha point should be applied in the area required (26); this is technically more difficult to accomplish in the apical third of a root canal. This reasoning can be sustained when comparing the results obtained with the lateral condensation at the 1 mm level from apical in which no accessory canal could be filled, either completely or partially, with gutta-percha. The lowest accessory canal filling frequency observed in this investigation with both filling methods was in the apical third. These observations are partially supported by the ones reported in an *ex vivo* radiographic investigation with simulated accessory canals (14). In an external visual and radiographic investigation (27) a filling rate almost two times as high using vertical condensation when compared with lateral condensation was reported; however, no distinction between whether the accessory canals were filled with gutta-percha, sealer or a combination of both is given. When leaving the filling material type of completely filled accessory canals out of the equation, these results are in contrast with ours, in which vertical condensation (95.56%) filled only 1.3 times as many accessory canals as lateral condensation (73.34%). Nevertheless, the tendency of vertical condensation to yield higher filling results can be confirmed.

An epoxy resin-based sealer (2SealEasyMix) was used in this investigation as we were also of the opinion (17,28) that the flowability of gutta-percha into the accessory canals could be positively influenced by it. However, in the apical third, DuLac *et al.* (17) reported significantly higher results of carrier-based gutta-percha and the continuous wave technique when compared with warm and cold lateral condensation, high-temperature gutta-percha and vertical condensation. The authors, as in this investigation, also reported occasional extrusion of gutta-percha and/or sealer beyond the limits of the accessory canals. Different opinions have been reported concerning an inflammatory reaction around implanted or extruded root canal filling material. It could have adverse consequences in clinical treatment (29), or it can slow (30,31) or has no influence (32) on the healing process of the periapical tissues; however, it has no negative consequences on the success of root canal treatment. Yet, it seems reasonable to accept that an endodontic treatment failure rate increase associated with excess

of filling material should be attributed to remaining bacteria in the root canal system rather to the filling material itself (31).

In this investigation a significant difference ($p = 0.003$) was observed between Reciproc blue (higher) and conventional Reciproc only in the apical third. However, this significance is, based on the actual available literature, difficult to explain. One possibility is that the preparation and obturation parameters, in spite of all efforts undertaken to avoid it, could have been influenced by operator dexterity. This possibility could be ruled out by the fact that the authors have data, from a further, as yet unpublished similar investigation that would rule out this possibility. On the other side, Reciproc blue and Reciproc have a slightly different geometric design, especially at the transition angle of the tip, that could explain the differences of the amount of debris produced and the amount of debris coronally transported between these two instruments during root canal preparation. Another research group (33) has reported differences between instruments with conventional and reciprocating motions when removing filling material from simulated root canals; however, a direct comparison with our results is not possible. A different research group (34) with a different investigation set-up also reports on a significantly smaller amount of conventional Reciproc to produce debris during root canal preparation. Caviedes-Bucheli et al. (35) are also of the opinion that the instrument flute and tip design are the cause of the amount of debris extruded into the periapical tissues and, thus, the amount of irritation produced in the periapical tissues after preparation. A different amount and/or extension of debris material obstructing the accessory root canals and consequently the significant accessory canal filling differences obtained in this investigation could be supported based on this evidence. Yet, this possibility needs to be substantiated with further research in which root canal preparation systems with contrasting design differences are investigated.

Conclusions

Under the investigation conditions, it can be concluded that: *in vitro* quantification of different root canal filling materials and methods is possible; filling accessory canals with vertical condensation is more frequent than lateral condensation; 1 mm from the apex had the lowest accessory canal filling frequency with both investigated techniques; coronal and middle thirds accessory canals are filled more frequently with either vertically condensed gutta-percha and/or sealer or laterally with sealer alone; and that lateral condensation is not capable to deliver gutta-percha into accessory canals.

Declaration of interest

The authors deny any conflicts of interest related to this study.

References

- Schilder H. Filling root canals in three dimensions. *Dent. Clin. North Am.* 1967; 11: 723–44.
- Jasper EA. Root-canal therapy in modern dentistry. *Dent. Cosmos* 1933; 75: 823–9.
- Basrani B, Haapasalo M. Update on endodontic irrigating solutions. *Endod. Topics* 2012; 27: 74–102.
- Briseño Marroquín B, Paqué F, Maier K, Willershausen B, Wolf TG. Root canal morphology and configuration of 179 maxillary first molars by means of micro-computed tomography: An ex vivo study. *J. Endod.* 2015; 41: 2008–13.
- Vertucci FJ. Root canal anatomy of the human permanent teeth. *Oral Surg. Oral Med. Oral Pathol.* 1984; 58: 589–99.
- Rubach WC, Mitchell DF. Periodontal disease, accessory canals and pulp pathosis. *J. Periodontol.* 1965; 36: 34–8.
- Rud J, Andreasen JO. A study of failures after endodontic surgery by radiographic, histologic and stereomicroscopic methods. *Int. J. Oral Surg.* 1972; 1: 311–28.
- Xu G, Zhang Z. Filling of the lateral canal. Report of two cases. *Oral Surg. Oral Med. Oral Pathol.* 1984; 58: 221–4.
- Ricucci D, Siqueira JF. Fate of the tissue in lateral canals and apical ramifications in response to pathologic conditions and treatment procedures. *J. Endod.* 2010; 36: 1–15.
- Nicholls E. Lateral radicular disease due to lateral branching of the root canal. *Oral Surg. Oral Med. Oral Pathol.* 1963; 16: 839–45.
- Jang J-H, Lee J-M, Yi J-K, Choi SB, Park SH. Surgical endodontic management of infected lateral canals of maxillary incisors. *Restor. Dent Endod.* 2015; 40: 79–84.
- Ricucci D, Loghin S, Siqueira JF. Exuberant biofilm infection in a lateral canal as the cause of short-term endodontic treatment failure: Report of a case. *J. Endod.* 2013; 39: 712–8.
- Ricucci D, Siqueira JF. Anatomic and microbiologic challenges to achieving success with endodontic treatment: A case report. *J. Endod.* 2008; 34: 1249–54.
- Goldberg F, Artaza LP, De Silvio A. Effectiveness of different obturation techniques in the filling of simulated lateral canals. *J. Endod.* 2001; 27: 362–4.
- Goldberg F, Artaza LP, De Silvio AC. Influence of calcium hydroxide dressing on the obturation of simulated lateral canals. *J. Endod.* 2002; 28: 99–101.
- Reader CM, Van Himel T, Germain LP, Hoen MM. Effect of three obturation techniques on the filling of lateral canals and the main canal. *J. Endod.* 1993; 19: 404–8.
- DuLac KA, Nielsen CJ, Tomazic TJ, Ferrillo PJ, Hatton JF. Comparison of the obturation of lateral canals by six techniques. *J. Endod.* 1999; 25: 376–80.

18. Wong M, Peters DD, Lorton L. Comparison of gutta-percha filling techniques, compaction (mechanical), vertical (warm), and lateral condensation techniques, Part 1. *J. Endod.* 1981; 7: 551–8.
19. Venturi M, Di Lenarda R, Prati C, Breschi L. An in vitro model to investigate filling of lateral canals. *J. Endod.* 2005; 31: 877–81.
20. Karabucak B, Kim A, Chen V, Iqbal MK. The comparison of gutta-percha and Resilon penetration into lateral canals with different thermoplastic delivery systems. *J. Endod.* 2008; 34: 847–9.
21. Sant'Anna-Júnior A, Guerreiro-Tanomaru JM, Martelo RB, Ferreira da Silva G, Tanomaru-Filho M. Filling of simulated lateral canals with gutta-percha or thermoplastic polymer by warm vertical compaction. *Braz. Oral. Res.* 2015; 29: 56–6.
22. Kasahara E, Yasuda E, Yamamoto A, Anzai M. Root canal system of the maxillary central incisor. *J. Endod.* 1990; 16: 158–61.
23. Miyashita M, Kasahara E, Yasuda E, Yamamoto A, Sekizawa T. Root canal system of the mandibular incisor. *J. Endod.* 1997; 23: 479–84.
24. Goldberg F, Massone JE, Spielberg C. Effect of irrigation solutions on the filling of lateral root canals. *Endod. Dent. Traumatol.* 1986; 2: 65–6.
25. Mader CL, Baumgartner JC, Peters DD. Scanning electron microscopic investigation of the smeared layer on root canal walls. *J. Endod.* 1984; 10: 477–83.
26. Briseño Marroquín B, Wolf TG, Schürger D, Willershausen B. Thermoplastic properties of endodontic gutta-percha: A thermographic in vitro study. *J. Endod.* 2015; 41: 79–82.
27. Brothman P. A comparative study of the vertical and the lateral condensation of gutta-percha. *J. Endod.* 1981; 7: 27–30.
28. Yee FS, Marlin J, Krakow AA, Gron P. Three-dimensional obturation of the root canal using injection-molded, thermoplasticized dental gutta-percha. *J. Endod.* 1977; 3: 168–74.
29. Ricucci D. Apical limit of root canal instrumentation and obturation, Part 1. Literature review. *Int. Endod. J.* 1998; 31: 384–93.
30. Sjögren U, Hagglund B, Sundqvist G, Wing K. Factors affecting the long-term results of endodontic treatment. *J. Endod.* 1990; 16: 498–504.
31. Sundqvist G, Figdor D, Persson S, Sjögren U. Microbiologic analysis of teeth with failed endodontic treatment and the outcome of conservative re-treatment. *Oral Surg. Oral Med. Oral Pathol. Oral Radiol. Endod.* 1998; 85: 86–93.
32. Goldberg F, Cantarini C, Alfie D, Macchi RL, Arias A. Relationship between unintentional canal overfilling and the long-term outcome of primary root canal treatments and nonsurgical retreatments: A retrospective radiographic assessment. *Int. Endod. J.* 2020; 53: 19–26.
33. Alfie D, García G, Perez Rodriguez P *et al.* Time and efficacy of different systems and dynamics to penetrate the GuttaCore obturation in the retreatment of simulated curves canals in EndoTraining Blocks. *Rev. Esp. Endod.* 2019; 37: 28–36.
34. Bürklein S, Benten S, Schäfer E. Quantitative evaluation of apically extruded debris with different single-file systems: Reciproc, F360 and OneShape versus Mtwo. *Int. Endod. J.* 2014; 47: 405–9.
35. Caviedes-Bucheli J, Rios-Osorio N, Rey-Rojas M *et al.* Substance P and Calcitonin gene-related peptide expression in human periodontal ligament after root canal preparation with Reciproc Blue, WaveOne Gold, XP EndoShaper and hand files. *Int. Endod. J.* 2018; 51: 1358–66.