

CASE REPORT

Iran J Allergy Asthma Immunol

June 2020; 19(3):313-317.

Doi: 10.18502/ijaai.v19i3.3460

Delay in Diagnosis of Two Siblings with Severe Ocular Problems and Autoimmune Polyglandular SyndromeSamin Sharafian¹, Marzieh Tavakol^{2,3}, Mohammad Gharagozlou⁴, and Nima Parvaneh^{4,5}¹ *Department of Allergy and Clinical Immunology, School of Medicine, Bushehr University of Medical Sciences, Bushehr, Iran*² *Non-Communicable Diseases Research Center, Karaj, Iran*³ *Department of Allergy and Clinical Immunology, Imam Ali Hospital, Alborz University of Medical Sciences, Karaj, Iran*⁴ *Department of Allergy and Clinical Immunology, Children's Medical Center Hospital, Tehran University of Medical Sciences, Tehran, Iran*⁵ *Research Center for Immunodeficiencies, Tehran University of Medical Sciences, Tehran, Iran*

Received: 29 May 2019; Received in revised form: 16 December 2019; Accepted: 20 December 2019

ABSTRACT

Autoimmune polyendocrine syndrome type 1 (APS1) is a scarce polyendocrinopathy with autosomal recessive inheritance results from defects in the human autoimmune regulatory (AIRE) gene. In addition to three major manifestations of APS1 including mucocutaneous candidiasis, hypoparathyroidism, and Addison's disease, ophthalmic problems such as keratoconjunctivitis, dry eye, iridocyclitis, and cataract can be seen in these patients. In this article, we introduced two siblings presented with nail dystrophias, severe photophobia, and keratitis since early childhood which genetic examination revealed single nucleotide T>C translocation in their 2nd exon and heterozygous deletion mutation in their 12th exon.

Keywords: Autoimmune polyglandular syndrome; Photophobia; Keratitis; Vision disorders

INTRODUCTION

Autoimmune polyglandular syndrome type 1 (APS1) is considered as a scarce and complex disease associated with the incidence of fewer than 1/100 000 people per year.¹ It is developed as a result of an autosomal recessive inheritance and mutations in the autoimmune regulator (AIRE) gene which involves different endocrine and non-endocrine organs.²

Patients with APS 1 have a type of primary immunodeficiency accompanying chronic mucocutaneous candidiasis.³ T regulatory (Treg)-cell defects can interrupt immunologic tolerance in the body, leading to autoimmune diseases.⁴ The presence of auto-antibodies to interleukin (IL)-17, IL-22, and Type I interferon is regarded as immunological disorders.³ There are three major symptoms including mucocutaneous candidiasis, hypoparathyroidism, and Addison disease that are used to diagnose APS 1.⁵ Moreover, other manifestations (such as hypergonadotropic hypogonadism, autoimmune thyroid diseases, keratoconjunctivitis, and lymphocytic

Corresponding Author: Nima Parvaneh, MD;
Department of Allergy and Clinical Immunology, Children's Medical Center Hospital, Tehran University of Medical Sciences, Tehran, Iran. Tel: (+98 912) 4057697, E-mail: nparvaneh@tums.ac.ir

hypophysitis), with less frequency are developed in patients with APS1.⁶ Herein we present two siblings with ocular manifestations since early childhood.

CASE PRESENTATION

A 5-year-old girl was referred to the immunology department in Children's Medical Center with a history of severe photophobia that forced her to close her eyes in the light. She had been diagnosed by an ophthalmologist to have severe limbal stem cell deficiency (LSCD) and keratitis when she was about the age of 30-month. Informed consent was obtained from the parents of patients. This study was approved by the Ethics Committee of Tehran University of Medical Sciences (N: 1395.1923).

Her brother had also been referred with conjunctivitis, light sensitivity, and dry eye when he was 9.5-year-old. Moreover; he had been diagnosed to have severe LSCD and keratitis by the ophthalmologist between ages 2 and 3. He additionally had four distinct depigmented skin lesions that started at the age of 7 which diagnosed as vitiligo.

Both siblings had a history of prolonged oral

candidiasis. They were born as term neonates via normal vaginal delivery. Separation of their umbilical cords had occurred during the first two weeks of life. Nail dystrophy was also observed in their mother and their older brother. They didn't show other symptoms of this disease. All tests related to organs and glands involvement were normal. There were 5 deaths without known causes in their mother's family in their first year of life.

In the physical examination, the boy had normal weight and height. He closed his eyes in the light, and there was one 2×1.5 cm hair loss area on his skull and four depigmented lesions were observed on the skin of his abdomen, neck, and face. Apart from those findings, his physical examination showed keratitis, photosensitivity, and all hand and foot nails dystrophia. The negative result was obtained after evaluating nails for fungal infection.

Both siblings were referred from the endocrinology department with the diagnosis of probably Sjogren syndrome and admitted at the hospital for thorough diagnostic evaluation. After immunologic evaluations, both of them developed diarrhea and vomiting, weakness, and hypotension.

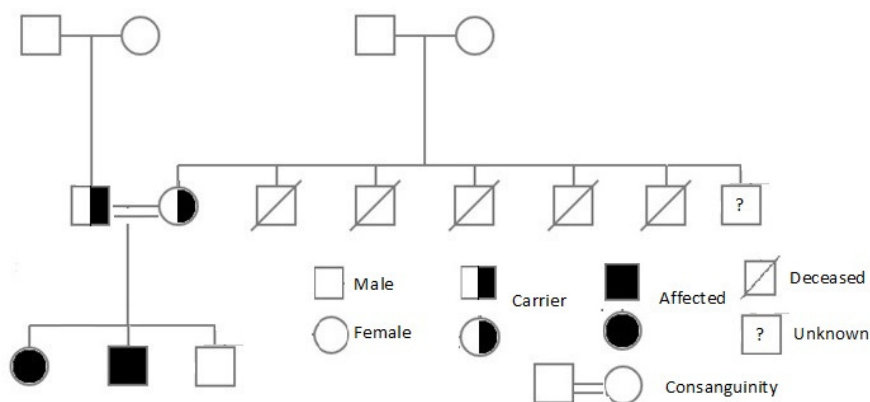


Figure 1. The family pedigree of two siblings with severe ocular problems and autoimmune polyglandular syndrome

Adrenal glands functions were evaluated by checking serum level of cortisol, adrenocorticotropic hormone (ACTH), glucose, calcium, phosphorus, and magnesium. Finally, based on the obtained results, the diagnosis of adrenal insufficiency was proved (Table 1).

Given the co-existence of different autoimmune

manifestations including hypoadrenalism, hypoparathyroidism, and ocular manifestations as well as nail dystrophy in patients and their family and consanguinity of their parents, a genetic assessment was done to rule in an inherited disorder with clinical suspicion of APS 1. Genetic examination of the AIRE

Siblings with Ocular Problems and Autoimmune Polyglandular Syndrome

gene using Sanger sequencing revealed single nucleotide T>C translocation in their 2nd exon with the displacement of tryptophan by arginine and deletion

mutation in their 12th exon. Their mother and father were the carrier of the mutated gene, but no mutation was found in their old brother (Figure 1).

Table 1. Patients' laboratory findings

Laboratory data	The sister (5 y)	The brother (9.5y)	Normal Range
White blood cells (/μL)	8.48×10 ³	8.13×10 ³	4-10×10 ³
Neutrophils (%)	45	48	50-70
Eosinophils (%)	4	5	0.5-5.0
Lymphocytes (%)	45	37	20-40
Monocytes (%)	6	10	3.0-8.0
Hemoglobin(g/dL)	11.7	12.6	12.0-15.0
Hemoglobin A1c	5.7	5.5	<5.7
Platelet (/μL)	348×10 ³	343×10 ³	150-410×10 ³
BUN (mg/dL)	25	20	5-20
Creatinine (mg/dL)	0.8	0.5	0.3-0.7
Serum calcium (mg/dL)	5.7	10	8.6-10.3
Serum phosphor (mg/dL)	7.4	4.8	3-4.5
Serum magnesium (mEq/L)	1.5	2	1.5-2.4
Sodium (mEq/L)	126	115	135-145
Potassium (mEq/L)	4.8	4.7	3.5-5.1
Blood sugar(mg/dL)	78	97	70-105
PTH (pg/mL)	5	18	12-88
ACTH (pg/mL)	360	457	10-60
Cortisol (μg/dL)	8	4	10-20
25-OH Vitamine D3 (ng/mL)	11	15	20-70
T4 (μg/dL)	7	10	4.8-11.6
TSH (mIU/mL)	0.5	2.5	0.39-5.95
Anti TTG	25 (Negative)	42 (Negative)	
Anti TPO	27 (Negative)	65 (Positive)	
Immunoglobulin G (mg/dL)	1281	943	*(463-1236), (608-1572)
Immunoglobulin A (mg/dL)	173	106	*(25-154), (45-236)
Immunoglobulin M (mg/dL)	200	184	*(43-196), (52-242)
Immunoglobulin E (IU/mL)	0	9	*(1.07-68.9), (0.98-570.6)
CD3 (/μL)	2289	2165	*(1400-3700), (1200-2600)
CD4 (/μL)	1640	1443	*(700- 2200), (650-1500)
CD8(/μL)	610	421	*(490-1300),(370-1100)
CD19 (/μL)	1526	661	*(390-1400), (270-860)
CD16 (/μL)	114	15	
CD56 (/μL)	114	15	
Tuberculin skin test	Negative (<5 mm induration)	Negative (<5mm induration)	
FANA	1/160 (Negative)	1/320 (Negative)	
Anti-dsDNA	3 (<100 Negative)	3	

*Age-related normal range of Immunoglobulins and lymphocyte subsets were obtained from The Harriet Lane Handbook.Huges HK, Kahl LK. Twenty-first Edition. BUN (Blood urea nitrogen); PTH (Parathyroid hormone); ACTH (Adrenocorticotrophic hormone); TSH (Thyroid-stimulating hormone); Anti- TTG (Anti-tissue transglutaminase); Anti TPO Ab (Anti-thyroid peroxidase antibodies); FANA (Fluorescent antinuclear antibody test).

Both had taken fludrocortisone, hydrocortisone, and

dextrose saline for this problem, and electrolyte

imbalance were corrected. The girl had a low serum level of calcium and received intravenous calcium gluconate 10%. Both were put on Vitamin D3 supplement for Vitamin D insufficiency. Both received Rituximab 375 mg/m² dose two times to treat the keratoconjunctivitis and their photophobia got better after two weeks. Finally, they were referred to an ophthalmologist for the management of LSCD.

DISCUSSION

Herein we described two siblings referred to our hospital with nail dystrophia, photophobia, keratitis, and LSCD. Following a physical examination and immunologic evaluations, we found vitiligo, alopecia, chronic mucocutaneous candidiasis, hypoparathyroidism, autoimmune thyroiditis, and adrenal insufficiency with a genetically confirmed diagnosis of APS 1.

Keratoconjunctivitis, dry eyes, iridocyclitis, cataract, retinal detachment, and optic atrophy have been identified as ocular symptoms in patients with APS 1.⁷ In a review article by Guo et al, candidiasis and Keratoconjunctivitis had the most and the fewest frequency among clinical symptoms in patients with APS between 1990 and 2017.² The potential problem in the diagnosis of APS is variation in existence and order of the development of clinical features. In our patients, ocular manifestations including severe photophobia and keratitis manifested as the earliest symptoms at the age of about 2.5 years in early childhood. The mere focus on the classic manifestations of APS (hypoparathyroidism, adrenocortical failure, and candidiasis) might lead to delay in the diagnosis and consequently the management of the patients.² In a study by Akil et al, evaluation of endocrinal system and consideration to the diagnosis of APS type 1 has been emphasized in children with visual complications and a history of chronic candidiasis and ectodermal Dysplasias or hypoparathyroidism.⁷

Approximately 50% of APS 1 patients suffer from disabling keratitis which is known as an important characteristic of the disease.⁸ According to the study of Merenmies L et al, two etiological agents to develop keratitis in patients with APS 1 could be hypoparathyroidism and chronic candidiasis. Additionally, about 75% of patients with APS 1 manifested any symptoms of keratitis in their study.⁹ In the study of Yeh et al on AIRE-deficient mice, the

important role of immunological processes in the development of ocular complications in murine APS 1 model was considered.¹⁰

In conclusion, APS 1 is considered as a rare syndrome with different endocrinopathies and autoimmune manifestations. The important point was the onset of nail dystrophy in the patients, their mother, brother, and uncle as well as ophthalmic problems in the patients. The exact clinical history and physical examination were very important in these cases. Physicians especially endocrinologists, ophthalmologists, and clinical immunologists should be aware of this syndrome to do the diagnostic evaluation at the proper time and start the therapeutic measures as soon as possible to improve the patients' quality of life and prevent the complications.

CONFLICT OF INTEREST

The authors declare no conflicts of interest.

ACKNOWLEDGEMENTS

We are grateful for our patients and their parents' utmost cooperation.

REFERENCES

1. Kahaly GJ. Polyglandular autoimmune syndromes. *Eur J Endocrinol.* 2009;161(1):11-20.
2. Guo CJ, Leung PSC, Zhang W, Ma X, Gershwin ME. The immunobiology and clinical features of type 1 autoimmune polyglandular syndrome (APS-1). *Autoimmun Rev.* 2018;17(1):78-85.
3. Pichard DC, Freeman AF, Cowen EW. Primary immunodeficiency update: Part II. Syndromes associated with mucocutaneous candidiasis and noninfectious cutaneous manifestations. *J Am Acad Dermatol.* 2015;73(3):367-82.
4. Pellerin L, Jenks JA, Bégin P, Bacchetta R, Nadeau KC. Regulatory T cells and their roles in immune dysregulation and allergy. *Immunol Res.* 2014;58(2-3):358-68.
5. Husebye ES, Perheentupa J, Rautemaa R, Kampe O. Clinical manifestations and management of patients with autoimmune polyendocrine syndrome type I. *J Intern Med.* 2009;265(5):514-29.
6. Weiler FG, Dias-da-Silva MR, Lazaretti-Castro M. Autoimmune polyendocrine syndrome type 1: case report

Siblings with Ocular Problems and Autoimmune Polyglandular Syndrome

- and review of literature. *Arq Bras Endocrinol Metabol.* 2012;56(1):54-66.
7. Akil H, Bulus AD, Andiran N, Veber PS, Keskin S. A case of autoimmune polyendocrine syndrome type 1 with ocular findings and unique AIRE gene defect. *J Clin Ophthalmol Res.* 2016;4(1):37.
 8. Shoughy SS, Tabbara KF. Topical tacrolimus solution in autoimmune polyglandular syndrome-1-associated keratitis. *Br J Ophthalmol.* 2017;101(9):1230-3.
 9. Merenmies L, Tarkkanen A. Chronic bilateral keratitis in autoimmune polyendocrinopathy-candidiasis-ectodermal dystrophy (APECED). A long-term follow-up and visual prognosis. *Acta Ophthalmol Scand.* 2000;78(5):532-5.
 10. Yeh S, de Paiva CS, Hwang CS, Trinca K, Lingappan A, Rafati JK, et al. Spontaneous T cell mediated keratoconjunctivitis in Aire-deficient mice. *Br J Ophthalmol.* 2009;93(9):1260-4.