



Aalborg Universitet

AALBORG UNIVERSITY
DENMARK

Lateral Augmentation of the Mandible with Different Ratios of Deproteinized Bovine Bone Mineral and Autogenous Bone Graft

Aludden, Hanna

Publication date:
2020

Document Version
Publisher's PDF, also known as Version of record

[Link to publication from Aalborg University](#)

Citation for published version (APA):
Aludden, H. (2020). *Lateral Augmentation of the Mandible with Different Ratios of Deproteinized Bovine Bone Mineral and Autogenous Bone Graft*. Aalborg Universitetsforlag. Aalborg Universitet. Det Sundhedsvidenskabelige Fakultet. Ph.D.-Serien

General rights

Copyright and moral rights for the publications made accessible in the public portal are retained by the authors and/or other copyright owners and it is a condition of accessing publications that users recognise and abide by the legal requirements associated with these rights.

- ? Users may download and print one copy of any publication from the public portal for the purpose of private study or research.
- ? You may not further distribute the material or use it for any profit-making activity or commercial gain
- ? You may freely distribute the URL identifying the publication in the public portal ?

Take down policy

If you believe that this document breaches copyright please contact us at vbn@aub.aau.dk providing details, and we will remove access to the work immediately and investigate your claim.

**LATERAL AUGMENTATION OF THE
MANDIBLE WITH DIFFERENT RATIOS
OF DEPROTEINIZED BOVINE BONE
MINERAL AND AUTOGENOUS
BONE GRAFT**

**BY
HANNA ALUDDEN**

DISSERTATION SUBMITTED 2020



AALBORG UNIVERSITY
DENMARK

**LATERAL AUGMENTATION OF THE MANDIBLE WITH DIFFERENT
RATIOS OF DEPROTEINIZED BOVINE BONE MINERAL AND
AUTOGENOUS BONE GRAFT**

by
Hanna Aludden



AALBORG UNIVERSITY
DENMARK



AALBORG UNIVERSITY HOSPITAL

Dissertation submitted
August 2020

Dissertation submitted: August 2020

PhD supervisor: Prof. Thomas Starch-Jensen, DDS, Ph.D.
Aalborg University Hospital, Denmark
Aalborg University, Denmark

Assistant PhD supervisors: Arne Mordenfeld, DDS, Ph.D.
Uppsala University, Sweden
Prof. Christer Dahlin, DDS, Ph.D., Dr. Odont.
NU-Hospital, Organization Trollhättan, Sweden
University of Gothenburg, Sweden
Mats Hallman, DDS, Ph.D., Associate Professor
Gävle County Hospital, Sweden

PhD committee: Clinical Professor Michael Gaihede
Aalborg University
Professor Nikolas Donos
Centre for Oral Clinical Research, London
Professor Lars Gösta Ingemar Rasmusson
University of Gothenburg

PhD Series: Faculty of Medicine, Aalborg University

Department: Department of Clinical Medicine

ISSN (online): 2246-1302

ISBN (online): 978-87-7210-688-5

Published by:
Aalborg University Press
Kroghstræde 3
DK – 9220 Aalborg Ø
Phone: +45 99407140
aauf@forlag.aau.dk
forlag.aau.dk

© Copyright: Hanna Aludden

Printed in Denmark by Rosendahls, 2020

TABLE OF CONTENT

LIST OF PAPERS	7
ABBREVIATIONS	6
ENGLISH SUMMARY	7
DANSK RESUME	9
TABLES AND FIGURES	11
BACKGROUND	13
INTRODUCTION	15
BONE	15
BONE CELLS	15
BONE FORMATION AND REMODELING	18
GRAFT MATERIALS.....	19
<i>AUTOGENOUS BONE</i>	19
<i>DEPROTEINIZED BOVINE BONE MINERAL</i>	20
<i>RESORBABLE COLLAGEN MEMBRANES</i>	21
GRAFT HEALING.....	22
<i>HEALING OF DEPROTEINIZED BOVINE BONE MINERAL</i>	23
<i>HEALING OF AUTOGENOUS BONE</i>	23
LATERAL AUGMENTATION	25
THE EXPERIMENTAL MODEL	25
HISTOMORPHOMETRY	26
AIMS	27
HYPOTHESES	29
MATERIALS AND METHODS	31
EXPERIMENTAL OUTLINES	31
ETHICAL CONSIDERATION	33
SURGICAL PROCEDURE.....	33

HISTOLOGY AND HISTOMORPHOMETRY	37
RADIOLOGY	40
STATISTICS	44
RESULTS.....	47
DISCUSSION.....	55
CONCLUSION	65
CLINICAL IMPLICATIONS AND FUTURE PERSPECTIVES.....	67
ACKNOWLEDGMENTS.....	69
REFERENCES	71
APPENDIX: PAPER I-IV	89

LIST OF PAPERS

The present Ph.D. thesis is based on the following papers, which will be referred to by their Roman numerals (I-IV).

- I. **H Aludden, A Mordenfeld, M Hallman, C Dahlin, T Jensen.** Lateral ridge augmentation with Bio-Oss alone or Bio-Oss mixed with particulate autogenous bone graft: a systematic review. *International Journal of Oral Maxillofacial Surgery*. 2017 Aug;46(8):1030-1038. doi: 10.1016/j.ijom.2017.03.008. Epub 2017 Mar 31.
- II. **H Aludden, A Dahlin, T Starch-Jensen, C Dahlin, A Mordenfeld.** Histomorphometric analyses of area fraction of different ratios of Bio-Oss® and bone prior to grafting procedures - An in vitro study to demonstrate a baseline. *Clin Oral Implants Res*. 2018 Feb;29(2):185-191. doi: 10.1111/clr.13079. Epub 2017 Oct 27. PMID: 29080268
- III. **H Aludden, A Mordenfeld, M Hallman, C Dahlin, T Starch-Jensen.** Histological and histomorphometrical outcome after lateral GBR augmentation of the mandible with different ratios of deproteinized bovine bone mineral and autogenous bone. A preclinical in vivo study. Accepted for publication in *Clinical Oral Implants Research*, August 2020.
- IV. **H Aludden, A Mordenfeld, A Cederlund, C Dahlin, R Spin-Neto, P Veiss-Pedersen, B Sritharan, T Starch-Jensen.** Radiographic changes in height and volume after lateral GBR procedures with different ratios of deproteinized bovine bone mineral at different time points. An experimental study. *Clinical Oral Implants Research*, Submitted April 2020.

ABBREVIATIONS

AB	Autogenous bone
ABB	Autogenous bone block
CBCT	Cone beam computed tomography
CI	Confidence interval
CT	Computed tomography
DBBM	Deproteinized bovine bone mineral
GBR	Guided bone regeneration
GW	Gained width
LRA	Lateral ridge augmentation
NMT	Non-mineralized tissue
PAB	Particulate autogenous bone
POB	Percentage of bone
RANK	Receptor activator of nuclear factor- κ B ligand
RANKL	Receptor activator of nuclear factor- κ B
RCT	Randomized controlled trial
ROI	Region of interest
SD	Standard deviation
VC	Volumetric changes
WC	Width changes
50:50	50% DBBM and 50% PAB
75:25	75% DBBM 25% PAB
100:0	100% DBBM

ENGLISH SUMMARY

Edentulism can lead to functional and cosmetic problems. Placement of implants is a well-documented treatment to replace missing teeth. Occasionally, long-term edentulism, tooth extractions, or infections can lead to severe atrophy of the alveolar crest. If implants are placed in an inadequate bone volume, it can lead to adverse angulations, mechanical overload, and esthetic dissatisfaction. Alveolar ridge augmentation with autogenous bone grafts from the mandibular ramus or the iliac crest has been the preferred treatment for the reconstruction of horizontal alveolar defects. This procedure demands a second surgical site, risk of donor site morbidity, postoperative complications, and increased costs. To simplify the surgical procedure, to reduce the risk of complications, and to reduce the cost, the use of bone substitutes has increased. Due to the lack of osteoinductive potential of bone substitutes, different ratios of particulate autogenous bone (PAB) have been added to the graft.

However, the optimal ratio of a bone substitute and PAB and its effect on the consolidation period is currently unknown. To avoid inappropriate tissue reactions and to be able to choose the right composition of the graft material as well as the optimal consolidation period to optimize the result, knowledge about the regeneration potential of the graft materials is essential. The present Ph.D. thesis aimed to evaluate the importance of adding different ratios of PAB to a DBBM and compare it to ABB from the mandible covered with DBBM according to the principles of GBR, using a resorbable collagen membrane. The thesis comprises a systematic review (I), a laboratory study (II), and two preclinical studies in minipigs (IV, V). Study I evaluated previous studies on LRA with DBBM alone or in combination with PAB to investigate the extent of previous research on this topic. In study II, different compositions of DBBM and PAB were evaluated in a laboratory to simulate the situation before the graft was placed in the patients. In study III and IV, lateral GBR augmentation was performed in the mandible of minipigs with three different particulate compositions of DBBM and PAB and with ABB covered by DBBM. The animals were euthanized after 10, 20, and 30 weeks, respectively, to assess the outcome after three different

healing periods. The histologic, histomorphometric, and radiographic outcomes were evaluated.

No differences could be detected between the graft materials regarding the formation of bone over time. ABB covered by DBBM maintained the width of the graft material better compared to particulate grafts, but no difference regarding the width gain could be detected among the particulate grafts.

DANSK RESUME

Manglende tænder medfører ofte funktionelle og kosmetiske gener og tandimplantater anses for en veldokumenteret behandlingsmetode til erstatning af manglende tænder. Imidlertid kan indsættelse af tandimplantater i den funktionelle og kosmetiske korrekte position være vanskelig eller umulig som følge af manglende kæbeknogle. Transplantat med knogle fra en anden del af patientens underkæbe eller fra hoftekammen, har i mange år været den mest almindelige metode for at genopbygge manglende kæbeknogle. Anvendelse af patientens egen knogle fra underkæben eller hoftekammen er imidlertid forbundet med risiko for komplikationer svarende til donorstedet, hospitalisering og øgede behandlingsudgifter.

For at simplificere det kirurgiske indgreb, minimere generne for patienter og for at undgå hospitalisering, benytter man sig i stigende grad af knogleerstatningsmaterialer alene eller i kombination med en reduceret mængde knogle fra patienten. Det ville være en fordel hvis patientens egen knogle helt eller delvist kunne erstattes af et knogleerstatningsmateriale.

Det optimale blandingsforhold af knogleerstatningsmateriale og patientens egen knogle i henhold til at generere mest knogle samt den optimale helingsperiode er endnu ukendt. Nærværende ph.d.-afhandling har til formål at undersøge forskellige blandingsforhold af knogleerstatningsmateriale fra kvæg og patientens egen knogle i forbindelse med opbygning af kæbeknoglen.

Nærværende ph.d.-afhandling inkluderer en systematisk oversigtsartikel (I), en laboratorieundersøgelse (II) samt to dyreksperimentelle undersøgelser (III, IV). Den systematiske oversigtsartikel (Studie I) opsummerede den eksisterende viden om anvendelsen af knogleerstatningsmateriale fra kvæg i kombination med patientens egen knogle ved genopbygning af kæbeknoglen. Laboratorieundersøgelsen (Studie II) evaluerede forskellige blandingsforhold af knogleerstatningsmateriale og knogle med det formål at etablere et sammenligningsgrundlag for vurdering af de forskellige blandingsforhold. De dyreksperimentelle forsøg (studie III og IV) evaluerede forskellige blandingsforhold af knogleerstatningsmateriale fra kvæg og egen knogle ved opbygning af kæbeknoglen med det formål at estimere mængden af knogle samt

volumenstabiliteten af transplantationsmaterialet ved forskellige helingsperioder.

Resultaterne viste at der ikke var en forskel på mængden knogle efter genopbygning med knogleerstatningsmateriale alene sammenlignet med når man tilføjede forskellige mængde af patientens egen knogle. Bredden af knoglen bevarede bedre med en knogleblok fra underkæben sammenlignet med forskellige blandinger af knogleerstatningsmateriale og forskellige mængde af patientens egen knogle.

TABLES AND FIGURES

- Table 1: Mean area fraction in percent of DBBM, bone, and NMT in study II
- Table 2: Mean width reduction and gained width for all graft compositions over time where * represents a statistically significant difference ($p < 0.05$)
- Table 3: Mean volume for all ratios overtime where* represents a statistically significant difference ($p < 0.05$)
- Table 4: Comparison of the volumetric changes for the different graft compositions over time where * represents a statistically significant difference ($p < 0.05$)
- Figure 1: Search strategy in study I
- Figure 2: The different graft compositions used in study II
- Figure 3: The different graft compositions used in study III
- Figure 4a: Frame used to ensure a standardized quantity of graft material
- Figure 4b: Grafted region covered by a collagen membrane and fixed with pins
- Figure 5: Illustration of the grafted regions
- Figure 6: Illustration of the three ROIs chosen for histological assessment
- Figure 7: Illustration of the method used to measure the ingrowth of mineralized bone into the graft
- Figure 8: Illustration of the method used to measure the width of the graft
- Figure 9ab: Illustration of the landmarks used for orientation of the CT volumes
- Figure 10a: The augmented region outlined on the CT volume postoperatively
- Figure 10b: The augmented region outlined on the CT volume at euthanasia
- Figure 11: Prediction curve illustrating the relation between the values of the clinically estimated percentage of DBBM and the predicted histomorphometrical area fraction of DBBM
- Figure 12: Mean percentage of bone, NMT, and DBBM after 10 weeks
- Figure 13: Mean percentage of bone, NMT, and DBBM after 20 weeks
- Figure 14: Mean percentage of bone, NMT, and DBBM after 30 weeks
- Figure 15: Ingrowth of mineralized bone into the graft material over time
- Figure 16: Illustration of width changes in mm over time
- Figure 17: Illustration of volumetric changes over time

BACKGROUND

Dental implants have been used increasingly during the last 40 years with high survival rates of suprastructures and implants (1-4). Adequate height and width of the alveolar process are the main requirements for optimal osseointegration of implants (1,5,6). However, tooth extraction, infection, or long-term edentulism may lead to severe atrophy of the alveolar crest and loss of the buccal bone (7-9). Placement of dental implants in inadequate bone volume may lead to adverse angulations, mechanical overload, and esthetic dissatisfaction. Therefore, bone augmentation before implant placement is often necessary when the dimension of the alveolar process is insufficient (1,5,6). Different procedures for bone augmentation have been described to enhance the width of the alveolar process (10-13).

ABB covered by a non-resorbable bone substitute and a resorbable collagen membrane is a commonly used surgical procedure to enhance the width of the alveolar process since it possesses osteoinductive and osteoconductive properties (14-18). However, the harvesting of an ABB from the mandible or the iliac crest is associated with the risk of morbidity at the donor site, increased costs, prolonged treatment time, hospitalization and occasionally the need for general anesthesia, and unpredictable resorption of the graft material (19-21). Hence, bone substitutes alone or in combination with PAB are used increasingly to simplify the surgical procedure. It has been suggested that the ideal bone substitute should be biocompatible, resorbable, and replaced with new bone, and possess properties that increase the incorporation of the graft (22, 23).

One of the most documented bone substitutes for intraoral augmentation is Bio-Oss (Geistlich Pharma, Wolhusen, Switzerland), a DBBM with excellent osteoconductive properties. To add osteoinductive properties to the graft material, different ratios of PAB have been added to DBBM and assessed for LRA, vertical augmentation, and maxillary sinus floor augmentation (24-37). It has been proposed that the ratio of DBBM and PAB could influence the pattern of bone remodeling (38) and that DBBM may delay bone formation in the early healing phase (39-42). However, a RCT, evaluating bone formation histologically and scintigraphically after

sinus floor augmentation, demonstrated no difference in bone formation between 100% DBBM and a mixture of DBBM and PAB (43).

Inconsistent conclusions regarding the composition of DBBM and PAB have also been presented on dimensional stability of different graft compositions. A newly published RCT demonstrated no significant difference in width changes after lateral GBR augmentation with DBBM alone compared with ABB covered by DBBM and a collagen membrane after 18 months (32). However, a previous systematic review concluded that ABB maintained the width better compared with particulate grafts (44), which has been confirmed in a later systematic review that also concluded that DBBM alone revealed reduced resorption of the augmented region compared with different ratios of DBBM and PAB (12). From a patient perspective, it would be an advantage if the need for the harvesting of AB could be reduced and partly or completely replaced by a bone substitute. This could minimize donor site morbidity, patient discomfort and treatment time. However, this requires a greater understanding and knowledge about the regenerative outcome with different compositions of DBBM and PAB and the effect on the consolidation period after lateral GBR augmentation.

INTRODUCTION

BONE

The main supportive organ in the human body is the skeleton, in which bone tissue constitutes the major part. Bone is a complex, cellular, vascularized, and highly mineralized connective tissue. The major functions of bones are to provide mechanical support and a framework for the body, to protect vital organs, to provide an environment for hematopoiesis in the bone marrow, and to act as a metabolic reservoir for minerals, in particular calcium (45, 46).

The bones in the human body can be categorized as long bones, short bones, irregular bones, and flat bones. Morphologically, bones are divided into cortical (80%) and trabecular bone (20%). Cortical bone is compact or dense and forms the hard, outer layer of bones, while trabecular bones have a spongy structure, forms the inner layer of the bone, and ensures the stability and elasticity of the skeleton (47, 48). The outer layer of the cortical bone is called the periosteum, and it consists of an outer and an inner fibrous layer with osteogenic potential. The inner surface of the cortical bone and the surfaces of the trabecular bone has a layer called endosteum. Microscopically, mineralized bone appears in two forms: woven and lamellar. Woven bone appears during early bone formation (i.e. during growth and healing). Lamellar bone is a mature bone and is formed during modeling and remodeling.

Bone is primarily composed of mineral, mainly hydroxyapatite, $\text{Ca}_{10}(\text{PO}_4)_6(\text{OH})_2$ (70%). The bone matrix mainly consists of type I collagen but also proteins such as osteocalcin, bone sialoprotein, osteopontin, osteonectin, and growth factors (e.g. bone morphogenic proteins (BMPs)). The remaining content is water and lipids (49).

BONE CELLS

Four different cell types are found in bone: osteoblasts, bone lining cells, osteocytes, and osteoclasts. The osteoblasts, bone lining cells, and osteocytes derive from

mesenchymal stem cells, while the osteoclasts are formed by giant multinucleated cells (49).

Osteoblasts

Bone formation is the main function of the osteoblast, and they represent 4-6% of the bone cells. Osteoblasts derive from mesenchymal stem cells, which can differentiate into fibroblasts, chondrocytes, myoblasts, and adipocytes (50).

Four stages of maturation have been identified in the differentiation of an osteoblast: the preosteoblasts, osteoblast, osteocyte, and bone-lining cell. If the appropriate stimuli are present, the mesenchymal stem cells form preosteoblasts, which resemble osteoblasts but cannot produce mineralized tissue. They activate mature osteoblasts that secrete the organic component of bone, predominantly type I collagen, which is essential for later mineralization of hydroxyapatite. The collagen excreted from the osteoblasts forms osteoid and later mineralized bone tissue.

During bone formation, osteoblasts can be trapped within the secreted matrix and differentiate into osteocytes. Some osteoblasts remain on the surface of the new bone and differentiate into inactive bone-lining cells, and the majority undergo apoptosis and degenerate (50-70%) (51). Osteoblasts also produce factors like macrophage colony stimulating factor, osteoprotegerin, and RANKL to regulate the differentiation of the bone-resorbing osteoclasts. These factors play an important role in osteoclast formation, activation, and resorption (51).

Osteocytes

Osteocytes are terminally differentiated osteoblasts that are embedded in the matrix of newly formed bone (52), and several theories have been proposed to explain the transformation of osteoblasts into osteocytes (53). The osteocytes represent 95% of all bone cells and are considered to play an important role in bone formation and bone remodeling (54).

Osteocytes lie within lacunae in the newly formed bone matrix where they can exist for a long time but eventually undergo apoptosis. In the lacunae, they are isolated and spatially separated from each other. However, they are still interconnected with

each other and with bone-lining cells as well as osteoblasts on the bone surface via extended projections through channels in the bone matrix called canaliculi (51, 52, 55, 56), in which they can detect mechanical load through a fluid (57, 58), and if microdamage occurs, this function can induce bone repair. Osteocytes can regulate skeletal homeostasis by regulating secretion and expression of insulin-like growth factor, osteocalcin, and sclerostin. They also provide the majority of RANKL that regulates osteoclast formation in cancellous bone (59, 60).

Bone lining cells

The bone lining cells mainly derive from osteoblast and are flattened, thin differentiated cells located on a thin layer of unmineralized collagen matrix covering the bone surface (61) and take part in the homeostasis of minerals and can be activated and differentiated into osteogenic cells (61). If exposed to parathyroid hormone (PTH), bone lining cells secrete collagenase to remove the collagen matrix to make osteoclasts attach to bone (62).

Osteoclasts

Osteoclasts derive from hematopoietic stem cells and share precursors with macrophages and monocytes. Osteoclasts are large multinucleated cells formed by the fusion of mononuclear progenitors (63) and the only cell type that can resorb bone. Osteoclast formation, activation, and resorption are regulated by the ratio of RANKL (which binds to RANK and activates osteoclastogenesis) to osteoprotegerin (which inhibits osteoclastogenesis), Interleukin-1 and Interleukin-6, microphage colony stimulating factor, PTH, 1,25-dihydroxyvitamin D and calcitonin (64).

Resorbing osteoclasts secrete hydrogen ions through proton pumps and chloride channels and generates an acidic environment in the resorption lacunae, and when the pH is decreased to 4.5 within the bone-resorbing space, the hydroxyapatite is dissolved. This is followed by secretion of tartrate-resistant acid phosphatase, cathepsin K, matrix metalloproteinases, and gelatinases from cytoplasmic lysosomes to digest the organic matrix. The result of this process is the formation of Howship's lacunae on the surface of trabecular bone and Haversian canals in cortical bone. The

resorption phase is completed by mononuclear cells when osteoclasts undergo apoptosis. After the resorption phase, the osteoblasts are activated and started to form osteoid to fill the cavities (65). Hence, osteoclast also regulates osteoblast function (47).

BONE FORMATION AND REMODELING

Bone is a dynamic organ that constantly changes. Two types of bone formation have been described: endochondral ossification and intramembranous ossification (47, 49). The long bones, pelvis, skull base, and vertebral column are formed by endochondral ossification, which is the most common mechanism of primary bone formation. Endochondral ossification involves the differentiation of mesenchymal cells into chondrocytes, which produce a framework of hyaline cartilage. Maturation of the cartilage occurs through hypertrophy of chondrocytes, which is followed by erosion of the matrix. The chondrocytes degenerate and die, and the remaining cartilage mineralizes. Mesenchymal cells infiltrate the calcified cartilage template by invading blood vessels and may be differentiated into osteoblasts and subsequently start bone formation (66).

The mandible, the flat bones of the skull, and the clavicle are formed by intramembranous ossification where mesenchymal cells differentiate directly into osteoblasts that deposit organic matrix composed of type I collagen in a trabecular pattern. Calcium phosphate in the form of hydroxyapatite crystals is subsequently deposited in the matrix to form bone (47, 49).

Bone remodeling occurs through the functional unit of cells called the basic multicellular unit. It consists of osteoclasts resorbing the bone, osteoblasts replacing the bone, the osteocytes within the bone matrix, the bone-lining cells covering the bone surface, and the capillary blood supply (51).

Bone remodeling starts with an initiation phase, including recruitment of osteoclast precursors, differentiation into mature osteoclasts, and activation and maintenance of bone resorption. Then, a reversal period will follow where osteoclast activity is converted to osteoblast activity. During the reversal period, osteoclastic

bone formation is inhibited, the osteoclasts undergo apoptosis, and the osteoblasts are recruited and start to differentiate. The final stage is called the termination phase, where the bone is formed by the osteoblasts (67). The resorption process lasts for three to four weeks, and the duration to complete the subsequent bone formation is three to four months. The bone remodeling process is shorter in cortical bone compared to cancellous bone, where the process lasts for about 200 days (51).

GRAFT MATERIALS

AUTOGENOUS BONE

AB originates from the same individual receiving the graft and has been described as the preferred bone grafting material due to its osteoconductive, osteoinductive, and osteogenic properties (68). The most common donor sites for pre-implant reconstruction of the alveolar crest are the mandibular retromolar area, the chin, and the iliac crest (14, 15, 69, 70). Autogenous grafts from the mandible or the iliac crest can be used as a block graft or in particulate form. The use of block grafts is most common for the LRA procedure when treating larger defects or edentulous areas, but particulate grafts have been evaluated as well (71, 72).

Some essential requirements have been described for the successful incorporation of the AB graft (73).

- I) *Embryonic origin:* Membranous bone seems superior over enchondral bone, probably due to the biological difference that leads to an alteration in revascularization.
- II) *Revascularization:* Incorporation, remodeling, and maintenance of the AB graft are related to the revascularization rate.
- III) *Graft structure:* Revascularization differs between cortical and cancellous bone grafts, where the cortical bone is densely packed and cancellous bone is porous with marrow tissue between the trabeculae and the vascular ingrowth occurs more rapidly.

- IV) *Stability of the graft:* A rigid fixation will improve graft integration and decrease the rate of resorption.

DEPROTEINIZED BOVINE BONE MINERAL

DBBM belongs to the group of xenogeneic bone grafts, which means it originates from another species than the host and is a natural bone mineral characterized by its high structural and chemical similarity to the bone. The organic portion of the material is removed to avoid disease transmission. The most documented DBBM used for augmentation procedures before implant placement is Bio-Oss (Geistlich Pharma, Wolhusen, Switzerland). It has been documented in several preclinical and clinical studies and is frequently used for different bone augmentation procedures.

The inorganic bone matrix of Bio-Oss seems to have a microporous structure comparable to the human cancellous bone and several studies have documented that Bio-Oss possesses important properties like biocompatibility and osteoconductivity when used as a grafting material (22, 24, 25, 27, 31-33, 36, 37, 74-82).

In the literature, there is controversy about whether DBBM is a resorbable material. Some authors have claimed that DBBM probably is a non-resorbable material or not (26, 83-85). Several authors have claimed the opposite due to observations of a decreased area fraction of DBBM over time and signs of resorption (i.e. resorption lacunas and the presence of osteoclasts on the particle surface) (74, 86-94). However, histomorphometrical analyses of biopsies harvested 11 years after maxillary sinus floor augmentation with Bio-Oss and PAB demonstrated Bio-Oss particles well integrated into lamellar bone with no significant changes in particle size, indicating that Bio-Oss is a stable non-resorbable bone substitute (95).

Since the organic part in DBBM has been extracted, the material would not possess any osteoinductive properties, and the integration of the graft material to the bone is claimed to be achieved only by osteoconduction (96). To enhance graft integration by osteoinduction, different ratios of PAB have been added to the graft in augmenting procedures of the alveolar ridge and the maxillary sinus. However, the optimal

composition of DBBM and PAB and its effect on the consolidation period is still unknown for lateral augmentation.

RESORBABLE COLLAGEN MEMBRANES

Almost three decades ago, the original hypothesis of GBR was presented (97). It suggested that placement of a resorbable or non-resorbable barrier could exclude certain types of cells, such as connective tissue and rapidly proliferating epithelium, to improve the growth of slower-growing cells capable of forming bone. Hence, by preventing the access of non-osteogenic tissues, mesenchymal stem cells would be solely allowed to repopulate the bone defect (97-99). It has also been proposed that resorbable, naturally derived collagen membranes promote the upregulation of genes related to bone formation and bone remodeling in the underlying defect compared to the expression of these genes in untreated sham defects in the rat femur. Additionally, the presence of the non-resorbable collagen membrane over the defect seemed to improve the expression of the pro-inflammatory cytokine TNF- α (100), which is essential for intra-membranous bone formation (101).

Bio-Gide (Geistlich Pharma, Wolhusen, Switzerland) is a well-documented, double-layered, non-cross-linked, resorbable collagen membrane of porcine origin. The Bio-Gide membrane has been used for different bone augmentation procedures, including LRA, maxillary sinus floor augmentation, ridge preservation, and guided periodontal regeneration, demonstrating decent biocompatibility and an enhanced formation of bone (17, 18, 24, 31-33, 36, 37, 77). The membrane has been proposed to resorb within eight weeks without inflammation (102, 103). As the Bio-Gide membrane is made of collagen, allergic reactions and inflammatory tissue reactions cannot be excluded, though this is extremely rare (103).

GRAFT HEALING

Osteogenesis, osteoinduction, and osteoconduction are the three essential elements of bone regeneration along with osteointegration, which is the final bonding between the host bone and the graft material (104).

Osteoconduction

The process in which biological or non-biological materials serve as a scaffold allows a three-dimensional ingrowth of capillaries, perivascular tissues, and mesenchymal stem cells from the recipient bed into the graft (68, 105, 106). This scaffold permits the formation of new bone determined by the biology of the graft and the mechanical environment of the host-graft interference (107).

Osteoinduction

The process where a material is capable of releasing factors from the graft matrix to stimulate cells from the host to form new bone (68). A potent inductor in osteogenic activities during bone repair is BMPs. They can regulate the production and activity of growth factors that are essential for bone formation (108). The three phases during osteoinduction are chemotaxis, mitosis, and differentiation.

Chemotaxis- In response to a chemical gradient (e.g. BMP), factors inducing bone formation direct the migration of cells to the area in which they are to be utilized.

Mitosis- Stimulation of mitogenic and proliferative activity in these cells.

Differentiation- The cells differentiate into chondroblasts and form cartilage, which becomes revascularized by invading blood vessels. After mineralization of the cartilage, osteoblasts are differentiated to form new bone (109).

Osteogenesis

Osteogenesis is the ability of the graft to produce new bone. This process depends on the presence of living bone cells in the graft. A graft material with osteogenic properties contains cells with the potential to form bone or the ability to differentiate

into bone-forming cells. These cells participate in the process where the graft is incorporated with the host bone. The role of osteogenesis as a mechanism during graft healing of non-vascularized grafts has been advocated to be of less importance compared to the mechanism of osteoconduction (68).

HEALING OF DEPROTEINIZED BOVINE BONE MINERAL

A previous experimental study in dogs described different phases during the incorporation of DBBM collagen in the host tissue (110). In the primary phase, the biomaterial was trapped in the fibrin network of the coagulum, and the polymorphous nuclear (PMN) cells migrated to the surface of the DBBM particles. In the second phase, PMN cells were replaced by osteoclast. The osteoclasts lived through osteopontin-positive cement lines on the surface of the particles, indicating that the cells were properly attached and removed material from the surface of the DBBM particles. After 7-14 days, the osteoclasts disappeared and were followed by osteoblasts, producing bone mineral in the provisional matrix. In the third phase, DBBM particles became integrated into the bone.

A previous experimental study in minipigs assessing the healing of DBBM compared to AB presented a delayed formation of bone in the DBBM group compared to the bone after eight weeks. However, the total fraction of mineralized tissue (DBBM particles + bone) was superior for the DBBM graft (41). It has previously been proposed that it seems likely that this mineralized tissue of bone and DBBM particles provides biological support to implants placed in the graft comparable or even exceeds that of bone (75).

HEALING OF AUTOGENOUS BONE

Several factors influence the integration of ABB, and the most important are the stability of graft, the vascularity of the recipient site, and the quantity of cellular marrow in the graft (111).

During healing of AB graft, most of the graft undergoes necrosis. However, cells of the bone marrow, periosteum, endosteum, and bone surface may survive (112).

Clinically, the fate of non-infected bone graft can be either *incorporation* in the surrounding bone, where the biological, mechanical, and esthetical characteristics will be shared between the graft and the host bone over time, or *sequestration*, where a foreign body reaction will occur and the bone will be encapsulated in fibrous tissue (106).

Histologically, three phases appear during incorporation: inflammation, consolidation, and remodeling (113).

- I) Inflammation- A hematoma surrounds the graft, and platelets are attracted by a fibrin clot. The graft is invaded by leucocytes and macrophages.
- II) Consolidation- Differentiation of osteoclasts that starts to resorb the graft. Recruitment of mesenchymal cells as a response to growth factors and BMPs (osteoinduction). The mesenchymal cells differentiate into osteoblasts that deposit osteoid on the trabeculae of the graft, which serves as a scaffold for the osteoblasts (osteoconduction).
- III) Remodeling- The remodeling process for AB continuous for a week to years and the graft is contentiously replaced by substitution.

Bone blocks from the mandibular ramus undergo reverse creeping substitution, which means it takes longer for the graft to resorb compared to the creeping substitution of cancellous grafts. Hence, it can maintain the osteoconductive purpose for a longer period (68).

The preparation of the recipient bed might be an important factor for incorporation and volume resistance to the graft since it gives access to cells from the host bone and local blood supply (114-116).

LATERAL AUGMENTATION

When the width of the alveolar process at the recipient site presents an insufficient dimension for implant placement, LRA procedures are required. To enhance the width of the alveolar process, several surgical procedures have been used, including GBR, alone or in combination with graft materials, block grafts, split-ridge osteotomy, and osteodistraction. A previous study could not present an advantage to use one augmentation technique over another (10).

When treating larger edentulous defects, ABB has previously been recommended (117). However, due to the risk of donor site morbidity, and a prolonged treatment time, the choice of surgical method must be considered individually. When using particulate grafts with DBBM, the GBR technique with a resorbable membrane has been used widely with satisfactory results (24, 31-33, 36, 37, 77). One common complication in GBR is soft tissue dehiscence and exposure of the membrane, which might lead to a bacterial infection and compromised graft healing. However, this is a more common complication in non-resorbable membrane sites.

The optimal ratio of DBBM and PAB is still unknown, as well as the optimal consolidation period. To the best of the authors' knowledge, different ratios of DBBM and PAB have never been compared to ABB covered by DBBM at different time points after lateral GBR augmentation.

THE EXPERIMENTAL MODEL

Animal studies are useful to study and compare the biological behavior of bone grafting materials. Minipigs are generally attractive for bone research due to their similarity to humans in terms of anatomy, bone mineral density, bone remodeling rate, and healing potential (118). They have an advantage from domestic pigs, which have been proven to be difficult to handle due to their size and aggressive temper (119, 120). Additionally, minipigs have a reduced linear growth pattern compared to domestic pigs, and they reach skeletal maturity earlier (119).

HISTOMORPHOMETRY

Bone histomorphometry is a quantitative histological examination of an undecalcified bone biopsy that is conducted to acquire quantitative information on bone remodeling and bone structure (121). This method is a well-documented research tool to evaluate the healing process of different bone substitutes (122). In histomorphometry, bone has three definitions (123).

- I) Mineralized bone matrix excluding osteoid; this is bone as a hard tissue. Osteoid, also called pre-bone, is a bone matrix that is not yet mineralized.
- II) Bone matrix, which includes both mineralized bone and osteoid.
- III) Tissue that includes bone marrow and other soft tissues as well as bone matrix.

Histological sections are two-dimensional, but they represent a three-dimensional structure. It is possible to measure their area, length, number, and the distance between points or lines. While bone histomorphometry allows us to understand this three-dimensional structure, it has technical limitations, protocol complexities, and financial and time costs. Cutting and grinding bone blocks may also damage the interface and could mar the results (124).

Histomorphometric results should be presented strictly and consistently in two dimensions using the term bone area or the corresponding three-dimensional results using the term bone volume (123). A mixture of the two terms should not be used within the same study, and they should be distinguished.

In dentistry, histomorphometry is used to assess the bone formation and residual DBBM particles through a two-dimensional definition (25, 26, 28, 30, 34, 88, 91, 93, 125). In study III, the histomorphometric results were presented strictly as two-dimensional, and the definition of bone used is the second definition (i.e. bone matrix), which includes both mineralized bone and osteoid. However, when histologically assessing the width measurements of the graft, the first definition was applied (i.e. mineralized bone and osteoid were separated) to assess the level of mineralization of the graft.

AIMS

The overall aim of this thesis is to evaluate the histologic and radiographic outcomes of lateral GBR augmentation with different compositions of DBBM and PAB and ABB covered by DBBM and a resorbable collagen membrane.

Specific aims

1. To demonstrate a histomorphometric baseline for different compositions of DBBM and PAB.
2. To histomorphometrically evaluate the regenerative outcome over time for different compositions of DBBM and PAB, used for lateral GBR augmentation.
3. To histologically evaluate the ingrowth of bone into the graft over time for different compositions of DBBM and PAB used for lateral GBR augmentation.
4. To radiographically evaluate the width changes over time for different compositions of DBBM and PAB and ABB covered by DBBM used for lateral GBR augmentation.
5. To radiographically evaluate the volume changes over time for different compositions of DBBM and PAB and ABB covered by DBBM used for lateral GBR augmentation.

HYPOTHESES

- There is a difference in the clinically estimated area fraction of bone, NMT, and DBBM before grafting with different ratios of DBBM and PAB compared to the histomorphometrically evaluated percentage of bone, NMT, and DBBM.
- There are no histomorphometrical or histological differences between DBBM alone and different compositions of DBBM and PAB used for lateral GBR augmentation.
- There are no differences in width or volumetric changes between different compositions of DBBM and PAB and ABB covered with DBBM and a resorbable collagen membrane used for lateral GBR augmentation.

MATERIALS AND METHODS

EXPERIMENTAL OUTLINES

Paper I

Human studies assessing the outcome of lateral GBR augmentation with different ratios of DBBM and PAB were evaluated on the following parameters:

Primary outcome measures

- Survival of suprastructures
- Survival of implants

Secondary outcome measures

- Bone regeneration
- Gained width of the alveolar process
- Width reduction of the graft material
- Volumetric stability of the graft material
- Patient-reported outcome measures
- Complications related to the surgical procedure

Search strategy:

Medline (PubMed), Cochrane database, and Embase searches were conducted by including studies published in English from January 1, 1990 to May 1, 2016. The search strategy utilized a combination of controlled vocabulary (MeSH) and free-text terms. The search strategy is illustrated in Figure 1.

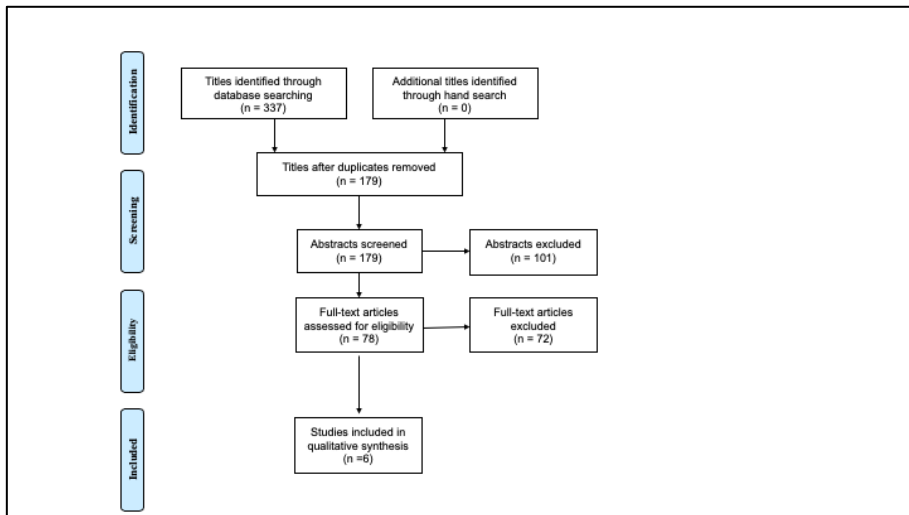


Figure 1. Search strategy in study I

Inclusion criteria:

- Human studies assessing lateral GBR augmentation with Bio-Oss alone or mixed with PAB
- Delayed implant placement
- A minimum of five patients

Exclusion criteria:

- Studies using Bio-Oss blocks alone or Bio-Oss blocks in combination with granules were excluded if the outcome measures could not be identified for granules alone
- Studies using unknown ratios of Bio-Oss and PAB
- Immediate implant placement

Paper II

This study was conducted to estimate the area fraction of different ratios of DBBM and PAB before grafting using an in vitro model. Different ratios of DBBM and PAB were evaluated histologically to estimate the area fraction of the different tissues in the graft material before it was placed in the patient to demonstrate a histomorphometric baseline.

Paper III and IV

The study included 24 adult female Göttingen minipigs (Ellegaard Göttingen Minipigs A/S, Dalmose, Denmark) with a mean age of 18 months (range: 17-19 months) and a mean weight of 31 kg (range: 28-36.5 kg). During the study, the animals were fed daily with a standard laboratory diet (Altromin 9023, Altromin International GmbH, Lage, Germany) and water ad libitum.

ETHICAL CONSIDERATION

For study III and IV, a license to perform the study was obtained from the Danish Experimental Animal Inspectorate, The Danish Veterinary and Food Administration, Ministry of Environment and Food of Denmark, Copenhagen, Denmark (Approval no. 2016-15-0201-00822). The studies design followed the ARRIVE guidelines for animal studies, and the experiment was performed per directive 2010/63/EU.

SURGICAL PROCEDURE

Paper II

AB particles were harvested from the mandible of a pig with a bone scraper. The harvested bone was mixed with DBBM particles (Bio-Oss, Geistlich, Wolhusen, Switzerland), small particles (particle size 0.25-1 mm), and plasma from humans in the different ratios defined by weight. The different ratios of DBBM and PAB are illustrated in Figure 2.

1	50% DBBM : 50% PAB
2	80% DBBM : 20% PAB
3	100% DBBM

Figure 2. The different graft compositions used in study II

The different ratios of DBBM and PAB were packed and condensed with a dental instrument in a roll of rice paper. All specimens were packed on weight in a

standardized way using a calibrated laboratory scale (50 g) to achieve the same pressure in all specimens. The specimens were fixed in formalin immediately after the packing procedure.

Paper III and IV

Harvesting of a mandibular bone block

Through a submandibular skin incision, the lateral and inferior border of the mandible was exposed. With a fissure bur, a cortical bone block involving the lateral and inferior cortex (20 x 10 mm) was harvested. To finish the osteotomy, a chisel was used. The periosteum and skin were readapted and sutured in layers with Vicryl 3-0 and Nylon 3-0 (Ethicon, Norderstedt, Germany). Finally, the wound was covered by tissue glue (Leukosan Adhesive, BSN medical GmbH, Germany).

Lateral GBR augmentation of the mandible

Preparation

Through a submandibular skin incision in the contralateral side of the mandible from where the bone block was harvested, the lateral and inferior border of the mandible was exposed. On the lateral surface of the mandible, perforations were made with a small round bur (\varnothing 1.2 mm, Stryker Corporation, USA) through the lateral cortex on four locations to mark the four recipient sites. The first recipient site was located 15 mm from the posterior border of the mandibular ramus with an inter-recipient site distance of 10 mm. At the inferior border of the mandible, osteosynthesis screws (\varnothing 2.0 mm x 9 mm, Stryker Corporation, USA) were placed, corresponding to the midline of each augmented area, as a reference landmark for the orientation at the later histological preparation. AB from the mandibular ramus was milled in a bone mill (Roswitha Quétin Dentalprodukte, Germany) and mixed with DBBM (Bio-Oss, Geistlich, Wolhusen, Switzerland), small particles (particle size 0.25-1 mm) and blood from an ear vein of the study animals in the different ratios, defined by weight. The ratios of DBBM and bone are shown in Figure 3.

1	50% DBBM : 50% PAB
2	75% DBBM : 25% PAB
3	100% DBBM
4	ABB

Figure 3. The different graft compositions used in study III

Bone block

The piece of the harvested bone block to use for LRA (10 x 10 x 4 mm) was prepared and applied passively to the lateral surface of the mandible and fixed with a titanium screw (Ø2.0 x 9 mm, Stryker Corporation, USA). With a round bur, rough corners were smoothed, and the bone block was covered with a 1 mm layer of 50% DBBM and 50% PAB, estimated by weight and a fixed resorbable collagen membrane (Bio-Gide, Geistlich, Wolhusen, Switzerland).

Different ratios of DBBM and PAB

A specially fabricated stainless-steel frame (10 x 10 x 5 mm) was used to ensure a standardized quantity of the graft material at each recipient site. The grafting material was packed layer by layer with firm pressure until the stainless-steel frame was filled (Figure 4a).

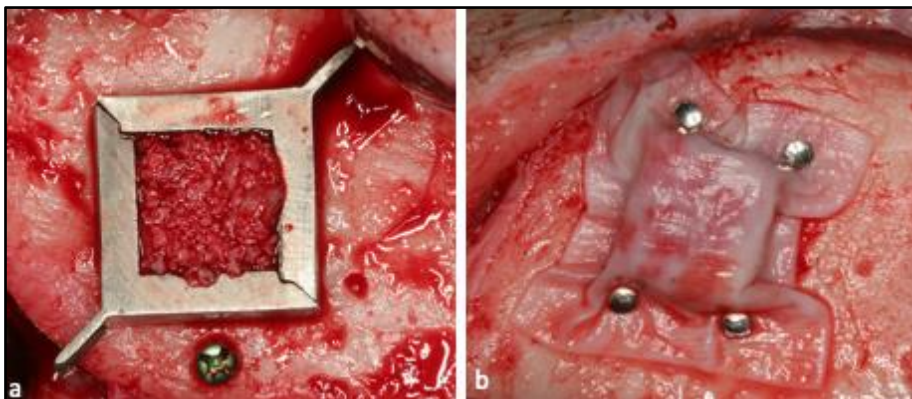


Figure 4a. Frame used to ensure a standardized quantity of graft material
Figure 4b. The grafted region covered by a collagen membrane and fixed with pins

physiological saline solution containing propofol 10 mg/ml (4 mg/kg) and Fentanyl 50 microgram/ml (0.03 microgram/kg) during the surgical procedure.

Antibiotics

Intramuscular injection with Curamox® Prolongatum Vet, Amoxicillinum Trihydricum, 150 mg/ml (0.1 ml/kg, Meda AS, Allerød, Denmark) was given one hour before surgery. Peroral Imacillin 50 mg/ml (14 ml/kg, Meda AS, Allerød, Denmark) was given twice a day on the third and fourth day postoperatively.

Pain control

An intramuscular injection with Metacam®, 5 mg/ml (2 ml/25 kg, Boehringer Ingelheim 3 A/S) was given preoperatively. Metacam®, oral suspension for pigs, 15 mg/ml, (2.7 ml/100 kg, Boehringer Ingelheim Denmark A/S) was given peroral for five days postoperatively.

Euthanasia and perfusion

The animals were euthanized after 10 weeks, 20 weeks, and 30 weeks, respectively. Eight animals were euthanized at each time point. The animals were deeply anesthetized. The left and right common carotid arteries were exposed and dissected through a midline incision of the neck from the thyroid cartilage to just above the suprasternal notch. The carotid arteries were cannulated with a catheter (Avanti, Cordia Cashel, Ireland) and perfused with 1000 ml neutral-buffered Ringer solution (2500 ml/min) followed by 1000 ml neutral-buffered formaldehyde solution (2500 ml/min).

HISTOLOGY AND HISTOMORPHOMETRY

Paper II

The specimens were dehydrated in a graded series of ethanol before plastic embedding (LR White, London Resin Company Ltd, Berkshire, UK). The embedded specimens were then cut longitudinally (EXAKT cutting and grinding equipment; EXAKT®

Apparatebau GmbH & Co, Norderstedt, Germany). Each specimen was divided into the central portion, and processed into two ground sections measuring 12 x 12 mm and of 10-20 μm in thickness. Each specimen was stained with 1% toluidine blue. Descriptive histology and histomorphometric analysis were performed blindly on coded sections using a light microscope (Nikon Eclipse E600) connected to a computer with analytical software (Nikon Eclipse E600; Nikon NIS-Elements software). Histomorphometric analyses were performed using a 10x objective. In each section, three ROI of 2 x 2 mm were randomly assigned in each mixture by a person blinded to the different test groups (Figure 6).

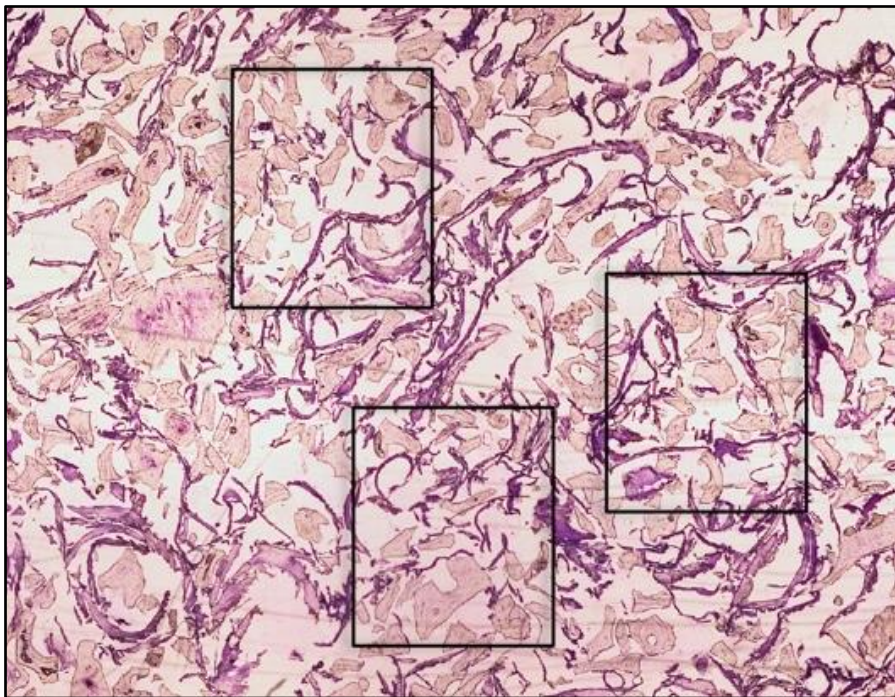


Figure 6. Illustration of the three ROIs chosen for histological assessment

The histomorphometric analysis could be completed in 25 of 26 specimens (nine with the 50:50 ratio, eight with the 80:20 ratio, and eight with the 100:0 ratio) and 74 of 78 ROI (26 with the 50:50 ratio, 24 with the 80:20 ratio, and 24 with the 100:0 ratio).

The following histomorphometric measurements were performed in each ROI:

1. Percentage of DBBM

2. Percentage of bone

3. Percentage of NMT

Data were presented as mean percentage values per section, where the area percentage of DBBM, bone, and NMT were calculated compared with the total area.

Paper III

Each specimen was immersed in 10% buffered formalin until the histological preparation was initiated. The specimens were rinsed in water followed by stepwise dehydration in a graded ethanol series, followed by embedding in plastic resin (LR White, London Resin Co. Ltd, UK). The embedded blocks were bisected corresponding to the reference screw inserted as a landmark inferior to each augmented area. Both bisected blocks of each specimen were used to prepare a 50 μm thick central ground section (EXAKT1 Apparatebau GmbH & Co, Norderstedt, Germany) (126) stained with toluidine blue. All sections were coded and evaluated blindly.

Qualitative and quantitative histology and histomorphometry were performed using light optical microscopy (Nikon Eclipse E600), following a calibration regarding different tissue types among the authors. All measurements were performed manually, directly on the computer screen connected to a microscope in Nikon NIS elements software. Four times magnification was used. In each specimen, a ROI was randomly selected. Following histological and histomorphometric measurements were made in all specimens:

1. Percentage of bone, NMT, and DBBM
2. Width of the augmented area (mm)
3. Ingrowth of mineralized bone into the augmented area (percentage of the total width)

To assess the ingrowth of mineralized bone, a straight line was drawn from the host bone to the lateral border in the central part of the transplant. Two supplementary straight lines were drawn parallel to the first line but 1 mm anterior and posterior for

it. A mean value (mm) for the three lines was calculated and acted as the value of the total width of the transplant.

Three new lines from the host bone to the lateral border of the mineralized part of the transplant were drawn: one in the central part of the transplant and two parallel lines 1 mm anterior and 1 mm posterior for the first line. A mean value (mm) was calculated and acted as the value of the width of the mineralized bone. The width of the mineralized bone was divided with the total width of the transplant and resulted in a value corresponding to the percentage of ingrowth of mineralized bone into the graft (Figure 7).

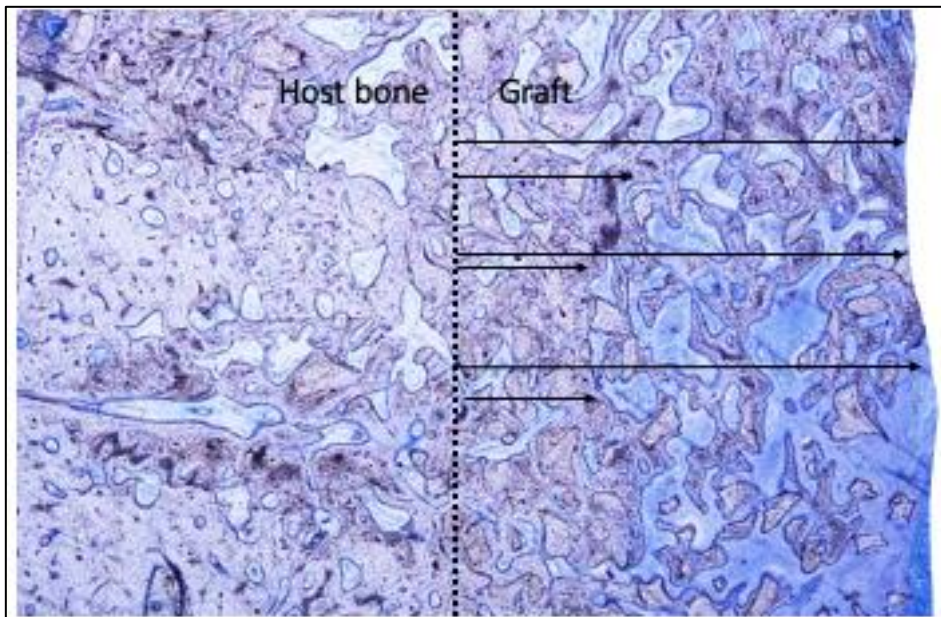


Figure 7. Illustration of the method used to measure the ingrowth of mineralized bone into the graft

RADIOLOGY

Paper IV

CT volumes (Discovery CT750 HD, General Electric Company, United States) were acquired with 0.625 mm section thickness and 0.312 mm distance between the

sections. The animals were placed in a supine position with a horizontal occlusal plane. Two sets of CT volumes were acquired (i.e. immediately after the surgery and after euthanasia). To provide blinding of the radiographic evaluation, the CT volumes were coded.

Width changes

The dimensional (linear) changes of the augmented regions were measured by two-dimensional linear measurements on axial CT images acquired postoperatively and at euthanasia in Romexis software (version 5.3, Planmeca Oy, Finland). A straight line was demarcated through each augmented region corresponding to the middle of the reference screw at the inferior mandibular border. Two parallel lines were drawn anteriorly and posteriorly at two millimeters from the first line, respectively (Figure 8). The vertical distance from the positioning screw to the center of the transplant was measured to find the correct position for the measurements in the corresponding volume at euthanasia. The initial width of the mandible was measured in millimeters from the outer lingual cortical surface to the outer facial cortical surface of the mandible at three points, corresponding to the three parallel lines. The width of the mandible, including the augmented region, was measured in millimeters from the outer lingual cortical surface of the mandible to the most lateral part of the augmented region at three points, corresponding to the three parallel lines. The width of each augmented region was estimated by subtracting the initial width of the mandible from the width of the mandible, including the augmented region. A mean value was calculated for each of the augmented regions corresponding to the three lines on axial CT images obtained immediately postoperatively and after euthanasia. However, the border between the augmented region and the outer facial cortical surface of the mandible was difficult to distinguish on certain CT images at euthanasia. Therefore, the initial width of the mandible, which was measured on postoperative CT images, was subtracted from the width of the mandible, including the augmented region on CT images at euthanasia.

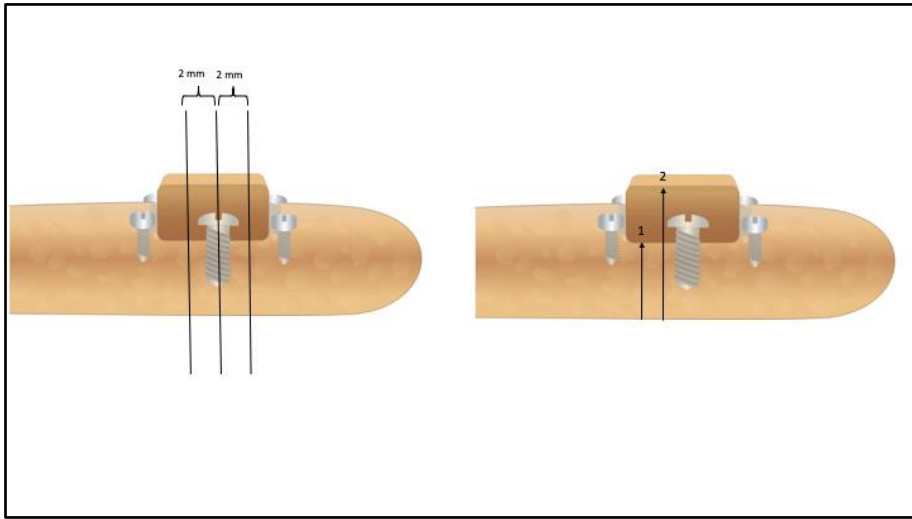


Figure 8. Illustration of the method used to measure the width of the grafted regions

Volumetric changes

To evaluate the volumetric changes of the augmented regions, three-dimensional measurements on coronal CT-scan images were acquired postoperatively and at euthanasia. The two sets of CT scans were uniformly oriented according to the lines using the On Demand software (CyberMed, Seoul, South Korea). Initially, a straight line between the centers of the two most posterior membrane fixation pins was defined based on the sagittal plane (Figure 9a). Perpendicular to the posterior line, a straight line in the lateral-medial direction corresponding to the middle of the inferior fixation pin was demarcated (Figure 9b). The posterior line, which was located posteriorly for the first augmented region, served as a starting point for the selection of CT-scan images when transferred to the coronal plane. The section thickness was set to 1 mm and coronal CT images, from the starting point until the anterior membrane fixation pins of the fourth augmented region were selected, and exported as separated TIF images, thereby ensuring an equal mutual distance between the selected images. Each image included a ruler, which allowed the setting of a linear scale (127, 128). The area of interest of the TIF image was outlined using a software program (ImageJ; National Institutes of Health, Bethesda, MD, USA) by manually tracing the structure with a computer mouse (Figure 10a, 10b) The area of each selected section was multiplied

by 2, providing the volume for that section, due to the 2 mm distance between sections, before the total volume for each of the augmented region was estimated by adding the counted volume value of each selected sections (i.e. Cavalieri's principle). The volumetric changes of the augmented regions in mm³ were finally calculated by subtraction of the estimated volume of the augmented region on CT obtained at euthanasia from the estimated volume on postoperative CT volume.

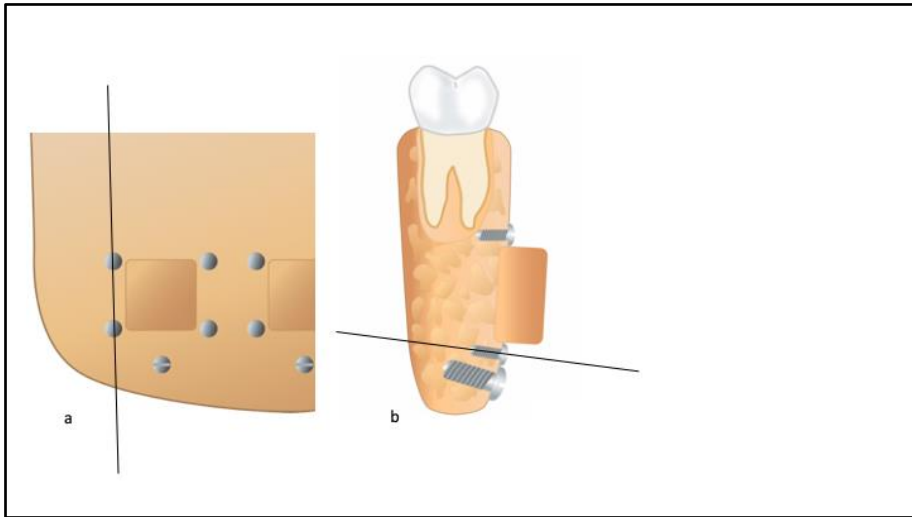


Figure 9ab. Illustration of the landmarks used for orientation of the CT volumes

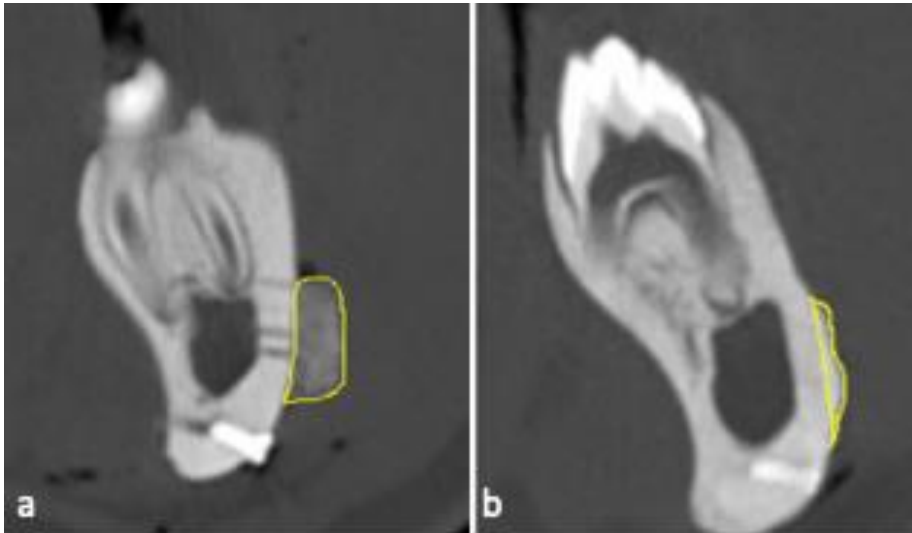


Figure 10a. The augmented region outlined on the CT volume postoperatively
Figure 10b. The augmented region outlined on the CT volume at euthanasia

STATISTICS

Paper II

Results were reported as mean values and 95% CI. Differences in the amount of DBBM, bone, and NMT were tested using mixed models with the mixture as a fixed factor and ROI as a random factor. Model assumptions, that is, normally distributed random effects with constant variance, equal across compositions, were verified by visual inspection of graphs of residuals and predicted values. A statistically significant difference was considered at $p < 0.05$. All statistics were performed using STATA version 14 (Stata Corp P, TX, USA).

Paper III

Data management and statistical analyses, including the calculation of descriptive statistics, were conducted using the statistical software STATA version 16.1 (Stata Corp P, TX, USA). The outcome was the percentage of bone, NMT, and DBBM. Data were analyzed in a mixed model for normally distributed data with the percentage of bone, NMT, and DBBM as the dependent variables. Graft composition, time points,

the interaction between time point and graft composition, and position are fixed factors, while the animal is a random factor. The specified correlation structure allowed the error variance to be different at different time points. The mixed models were fitted using the function `lme` from the R package `nlme`. Pairwise testing of differences in the percentage of bone, NMT, and DBBM between time points within graft compositions and between graft compositions within time points was performed based on marginal means of the mixed models. P-values and CIs were adjusted for multiple testing within time points and graft compositions using Tukey's method. Results were summarized as mean values with a 95% CI. A statistically significant difference was considered at $p < 0.05$.

Paper IV

For a convenient number of animals in Study III and IV, a power calculation based on the outcome in Study IV was conducted to define an adequate number of animals. A post hoc sample size calculation based on an alpha significance level of 0.05 to achieve 80% power to detect a clinically meaningful difference of 8% (SD: 5.0) in volume reduction between two of the groups at one healing period, suggested that 8 animal in each group were enough to detect a difference of 8% why we regarded 24 animals to be an adequate number for the study. Data management and statistical analyses including the calculation of descriptive statistics were conducted using the statistical software R version 2.8.0. (R Foundation for Statistical Computing, Vienna, Austria). Data were analyzed in a mixed model for normally distributed data with the percentage of volumetric and dimensional changes of the graft material as dependent variables. The composition and position of the graft material on the lateral surface of the mandible were selected as fixed factors, while the animal was used as a random factor. The mixed models were fitted. Pairwise testing of differences in volumetric and dimensional changes of the graft material between each ratio was conducted. Results were summarized as mean values with 95% CI and SD. A statistically significant difference was considered at $p < 0.05$.

RESULTS

The main results of studies (I-IV) are presented below.

Paper I

High short-term implant survival was demonstrated for LRA with DBBM in combination with PAB. Lateral GBR augmentation with DBBM alone or in combination with PAB seemed to induce bone formation. No studies evaluating DBBM alone presented results considering the survival of suprastructure, implant survival, gain in the width of the alveolar process, or volumetric stability.

Paper II

The mean area fraction in percent of DBBM, bone, and NMT is presented in Table 1.

Composition	50:50			80:20			100:0	
	DBBM	Bone	NMT	DBBM	Bone	NMT	DBBM	NMT
Mean	20.6	18.9	60.5	33.6	6.8	59.6	43.4	56.6
95% CI	18.2-23.0	16.9-20.9	57.9-63.1	29.7-37.6	5.0-8.6	56.4-62.7	40.5-46.3	53.7-59.5
Minimum	9.2	6.6	46.8	18.0	1.3	44.6	33.8	42.9
Maximum	33.3	30.1	73.8	52.9	17.3	72.3	57.1	66.2

Table 1. Mean area fraction in percent of DBBM, bone, and NMT in study II

Based on the results from the histomorphometric analyses, a prediction curve was calculated, which illustrates the relation between the values of the clinically estimated percentage of DBBM and the predicted histomorphometrical area fraction of DBBM (Figure 11). By the means of the curve, estimated histomorphometrical area fraction at baseline of any composition of DBBM and PAB can easily be predicted using the following formula: $\text{mean [RealDBBM]} = \beta \times \text{[ExpectedDBBM]}$ where β is a coefficient of 0.42, calculated from the observations in this study, and estimating the mean value of the real area fraction of DBBM to be 42% of the expected area fraction.

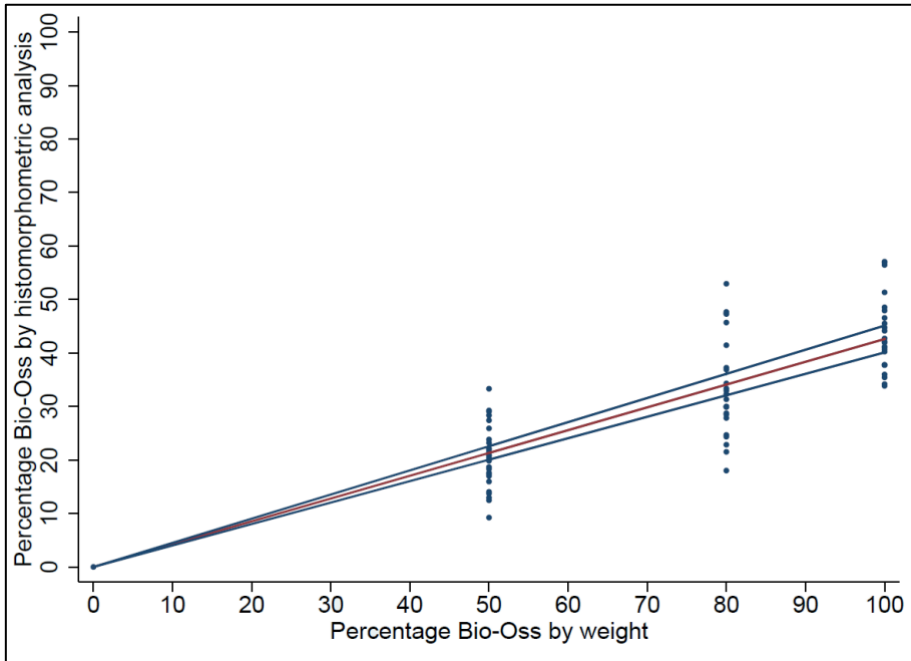


Figure 11. Prediction curve illustrating the relation between the values of the clinically estimated percentage of DBBM and the predicted histomorphometrical area fraction of DBBM

Paper III

The different compositions of DBBM and PAB and ABB displayed various stages of integration with the host bone after 10 weeks, 20 weeks, and 30 weeks of graft healing. Specimens containing different compositions of DBBM and PAB showed DBBM particles embedded in mineralized bone and NMT at all time points. DBBM particles adjacent to the host bone were generally more integrated into mineralized bone compared to particles located adjacent to the periosteum. ABB demonstrated a zone of NMT between the graft and host bone after 10 and 20 weeks, whereas an almost complete integration was observed after 30 weeks. Signs of remodeling and formation of primary osteons were observed after 20 weeks of healing.

The mean POB for the different compositions used during GBR were 54% (50:50), 50% (75:25), and 48% (100:0) after 10 weeks; 60% (50:50), 61% (75:25), and 60% (100:0) after 20 weeks; and 63% (50:50), 62% (75:25), and 62% (100:0) after 30 weeks. The POB were similar for all compositions at all time points, and no

statistically significant differences could be detected ($p>0.05$). However, there was a significant increase in POB from 10 weeks to 30 weeks for 75:25 ($p=0.02$) and 100:0 ($p=0.01$).

The mean percentage of NMT for the different compositions were 25% (50:50), 27% (75:25), and 26% (100:0) after 10 weeks; 18% (50:50), 15% (75:25), and 15% (100:0) after 20 weeks; and 22% (50:50), 16% (75:25), and 16% (100:0) after 30 weeks. The amount of NMT was similar for all compositions at all time points, and no statistically significant differences could be detected ($p>0.05$). However, there was a significant decrease in percentage of NMT from 10 weeks to 30 weeks for 75:25 ($p=0.05$) and 100:0 ($p=0.04$).

The mean percentage of DBBM for the different compositions were 21% (50:50), 23% (75:25), and 26% (100:0) after 10 weeks; 22% (50:50), 24% (75:25), and 25% (100:0) after 20 weeks; and 16% (50:50), 22% (75:25), and 22% (100:0) after 30 weeks.

Histomorphometric results after 10, 20 and 30 weeks are presented in Figures 12, 13, and 14.

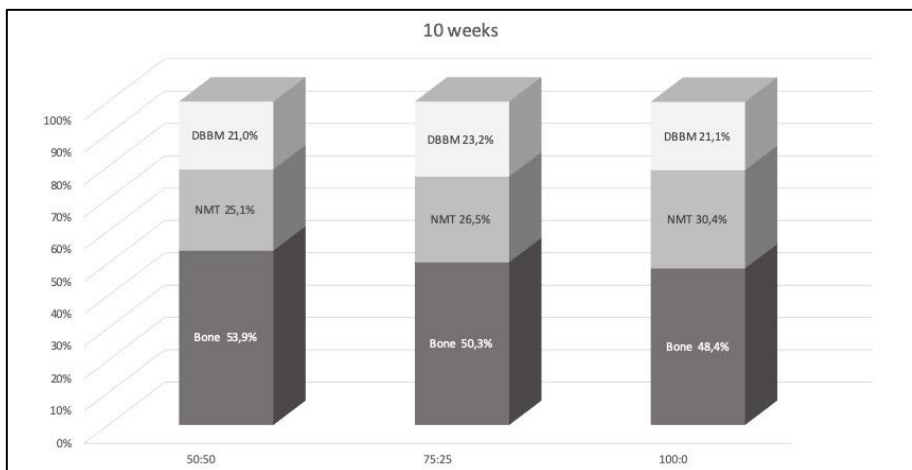


Figure 12. The mean percentage of bone, NMT, and DBBM after 10 weeks

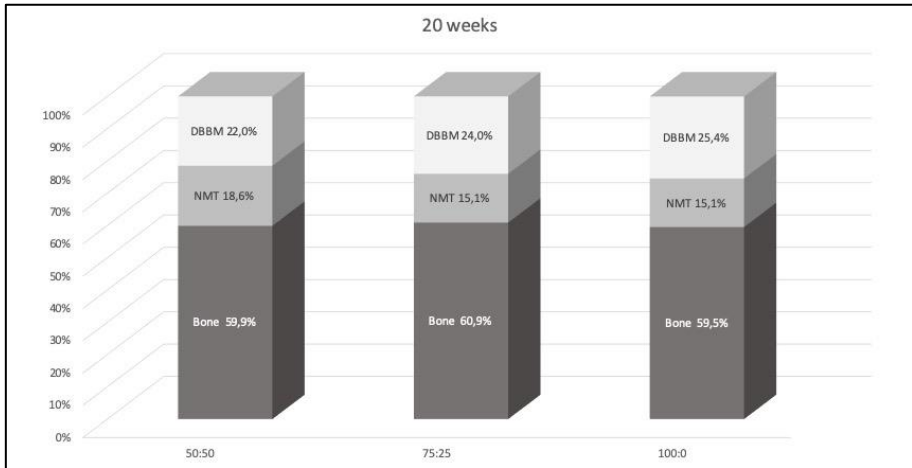


Figure 13. The mean percentage of bone, NMT, and DBBM after 20 weeks

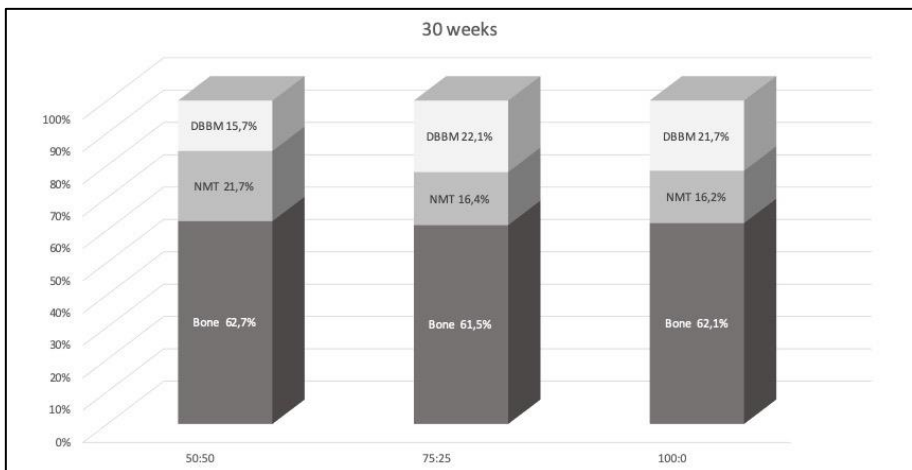


Figure 14. The mean percentage of bone, NMT, and DBBM after 30 weeks

No significant difference regarding the percentage of different tissues was observed between any of the compositions of DBBM and PAB at any time point. There was a significant increase in POB and a significant decrease in NMT for 75:25 and 100:0 from 10 to 30 weeks. All compositions demonstrated a non-complete ingrowth of mineralized bone into the graft after 10 weeks and complete mineralization after 30 weeks (Figure 15).

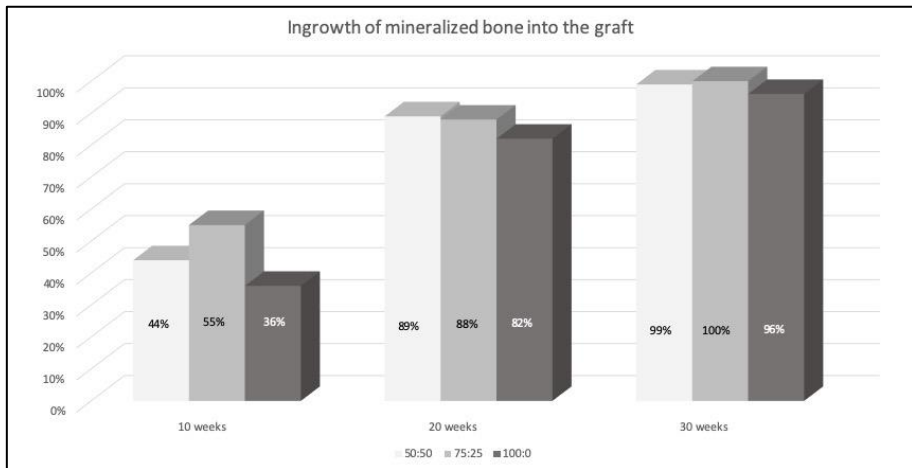


Figure 15. Ingrowth of mineralized bone into the graft material over time

Paper IV

Width changes

The gained width was 3.1 mm (± 2.6) for 50:50, 3.0 mm (± 2.3) for 75:25, 2.9 mm (± 1.0) for 100:0, and 4.6 mm (± 1.4) for ABB after 30 weeks. The width reduction was -1.7 mm (-33.1%) for 50:50, -1.8 mm (-37.8%) for 75:25, -1.7 mm (-35.8%) for 100:0, and -0.2 mm (-3.7%) for ABB after 30 weeks. The width changes over time are illustrated in Table 2 and Figure 16.

The ABB presented significantly less reduction compared to 50:50, 75:25, and 100:0 after 10 weeks ($p=0.00$), after 20 weeks ($p<0.01$), and after 30 weeks ($p<0.05$). There was no significant difference among the particulate grafts.

Graft composition	Baseline	10 weeks				20 weeks				30 weeks			
	GW (SD)	GW (SD)	WC	CI	P value	GW (SD)	WC	CI	P value	GW (SD)	WC	CI	P value
50:50	4.9 (± 0.5)	2.8 (± 1.3)	-2.1 (-42.1%)	-3.2; -1.0	0.00*	2.5 (± 0.9)	-2.4 (-47.1%)	-3.2; -1.0	0.00*	3.2 (± 2.7)	-1.7 (-33.1%)	-2.8; -0.7	0.00*
75:25	5.2 (± 0.9)	4.0 (± 1.3)	-1.2 (-22.8%)	-2.3; -0.1	0.03*	4.1 (± 1.3)	-1.1 (-14.3%)	-2.2; -0.1	0.05	3.4 (± 2.3)	-1.8 (-37.8%)	-3.0; -0.7	0.00*
100:0	4.8 (± 0.6)	3.5 (± 1.4)	-1.3 (-26.5%)	-2.4; -0.2	0.02*	2.7 (± 1.3)	-2.1 (-41.2%)	-3.2; -1.0	0.00*	3.1 (± 1.0)	-1.7 (-35.8%)	-2.8; -0.7	0.00*
ABB	4.4 (± 0.8)	4.4 (± 1.0)	0.0 (0%)	-0.8; 1.6	0.50	4.3 (± 2.0)	-0.1 (-0.3%)	-1.1; 1.1	0.99	4.2 (± 1.4)	-0.2 (-3.7%)	-0.9; 1.3	0.75

Table 2. The mean width reduction and gained width for all graft compositions over time where * represents a statistically significant difference ($p<0.05$).

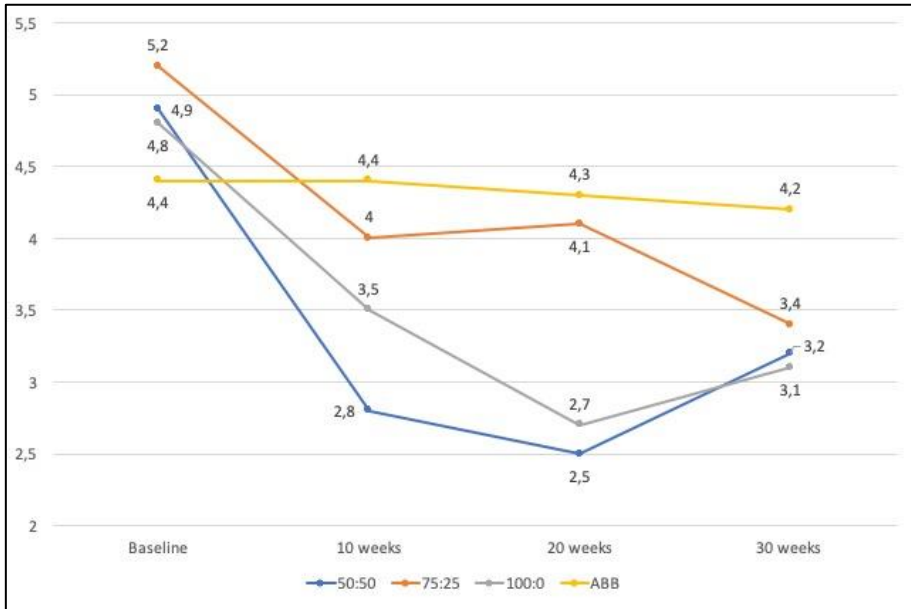


Figure 16. Illustration of width changes in mm over time

Volumetric changes

The number of images for each augmented area varied between five and nine, depending on the displacement of graft material, but the same number of sections was generated and evaluated for each augmented area in both sets of CT images. The mean volume and SD, as well as the volume reduction in percent for all graft materials, are presented in Table 3.

A comparison of the volumetric reduction between the different compositions at each time point is presented in Table 4. There was no statistically significant difference between any of the compositions at 30 weeks, but 100:0 presented a reduced reduction compared to all other grafts at 10 and 20 weeks. The volumetric changes over time are illustrated in Figure 17.

Graft composition	10 weeks			20 weeks			30 weeks		
	Volume (SD)	VC (CI)	P-value	Volume (SD)	VC (CI)	P-value	Volume (SD)	VC (CI)	P-value
50:50	608 mm ³ (± 166)	0.6% (-22.0; 23.3)	0.96	300 mm ³ (± 112)	-37.7% (60.4; -15.0)	0.00*	672 mm ³ (± 376)	20.1% (-2.7; 42.8)	0.08
75:25	488 mm ³ (± 166)	-18.0% (-40.1; 4.8)	0.12	409 mm ³ (± 114)	-18.7% (-41.4; 4.1)	0.11	531 mm ³ (± 377)	1.5% (-21.3; 42.8)	0.90
100:0	718 mm ³ (± 123)	7.8% (-15.0; 30.5)	0.50	566 mm ³ (± 153)	13.2% (-9.5; 35.8)	0.25	558 mm ³ (± 97)	3.4% (-19.3; 26.2)	0.77
ABB	416 mm ³ (± 87)	-15.9% (-38.6; 6.9)	0.17	356mm ³ (±149)	-26.5% (-49.2; -3.7)	0.02*	417 mm ³ (± 151)	-1.2% (-23.9; 21.5)	0.92

Table 3. The mean volume for all compositions overtime where * represents a statistically significant difference (p<0.05).

	10 weeks		20 weeks		30 weeks	
	Reduction contrast	p value	Reduction contrast	p value	Reduction contrast	p value
50:50 vs 75:25	75:25 > 50:50 (18.5%)	0.04*	50:50 > 75:25 (19.0%)	0.02*	75:25 > 50:50 (18.6%)	0.19
50:50 vs 100:0	50:50 > 100:0 (7.1%)	0.42	50:50 > 100:0 (51.0%)	0.00*	100:0 > 50:50 (2.7%)	0.85
50:50 vs ABB	ABB > 50:50 (16.5%)	0.06	50:50 > ABB (11.2%)	0.15	ABB > 50:50 (21.1%)	0.13
75:25 vs 100:0	75:25 > 100:0 (25.7%)	0.00*	75:25 > 100:0 (32.0%)	0.00*	75:25 > 100:0 (2.0%)	0.89
75:25 vs ABB	ABB > 75:25 (2.1%)	0.81	ABB > 75:25 (7.8%)	0.33	ABB > 75:25 (2.7%)	0.85
100:0 vs ABB	ABB > 100:0 (23.6%)	0.01*	ABB > 100:0 (39.7%)	0.00*	ABB > 100:0 (4.6%)	0.74

Table 4. Comparison of the volumetric changes for the different graft compositions over time where * represents a statistically significant difference (p<0.05).

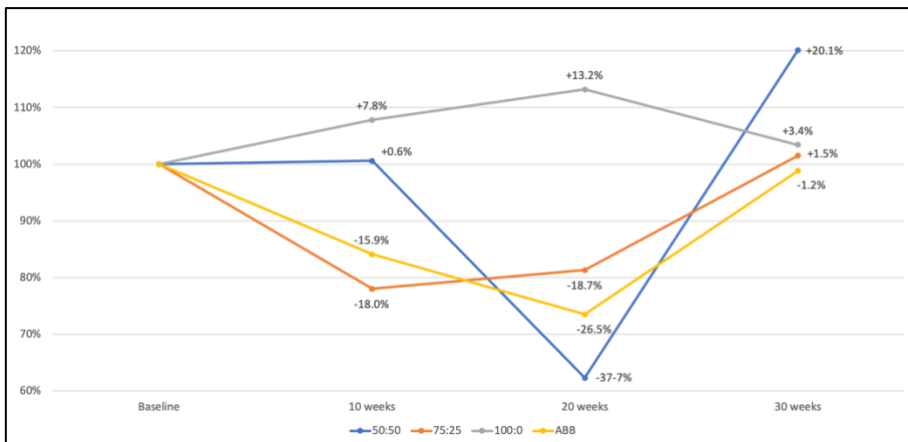


Figure 17. Illustration of volumetric changes over time

DISCUSSION

The purpose of this thesis was to assess the regenerative outcome after lateral GBR augmentation using different compositions of DBBM and PAB and ABB covered with DBBM and a resorbable collagen membrane at different time points.

Comments on material and method

Paper I

The present study was conducted to evaluate conclusions from previous studies assessing LRA with DBBM alone or in combination with PAB. The number of included studies was small, and only five studies met the inclusion criteria. A meta-analysis was not possible due to considerable variations in design. However, well-designed studies on LRA with DBBM alone or in combination with PAB were sparse.

Paper II

Three different compositions were chosen (50:50, 80:20, and 100:0) due to its common use in the clinical situation. It could have been an advantage to choose 75:25 instead of 80:20 due to the use of 75:25 in Study III and IV. However, 5% will probably not have an impact on the results, and it would possibly be in the range of normal variation when the compositions are mixed by weight.

Paper III and IV

DBBM is frequently mixed with PAB in different compositions, varying from 0% to 50% to add osteoinductive properties (24, 27, 31-33, 36, 37, 77, 129). Thus, the optimal composition of DBBM and PAB is presently unknown. In the present study, three different compositions of DBBM and PAB was used: 50:50 since it in larger reconstructions probably demands a donor site to achieve a sufficient amount of bone, 75:25 since the 25% of bone in most cases can be collected with a bone scraper in the surgical site, and 100:0 since it would be a great advantage if no PAB is required.

Previous experimental studies assessing different compositions of DBBM and PAB have mainly assessed bone formation in the early healing phase (8-12 weeks) to

provide information regarding biocompatibility of the material, early cellular response, and persistence and condition of the transplant within the defect. In clinical settings, implants are usually placed seven to ten months after LRA (24, 31-33, 77), and histomorphometrical and histological assessment after a prolonged healing period and at different time points could provide valuable knowledge on bone regeneration and incorporation of the graft material before implant placement. The present study included one healing period to evaluate the early response (ten weeks) and two healing periods that correspond to clinical settings where mineralization and incorporation of the graft material, the quantity of the material, and placement of the evaluated material is comparable to the clinical situation for LRA.

Bone formation

Since the histomorphometric analyses did not differ between newly formed bone and bone from the graft, the analyses of the ABB were not as relevant as for the particulate grafts since it consists only of bone at the moment of grafting. However, the ABB presented with a line of non-mineralized tissue between the graft and the host bone during the first 20 weeks of healing, and complete fusion of the graft with the host bone was first detectable after 30 weeks of healing. Hence, a prolonged healing period had a positive impact on the incorporation of ABB.

The histomorphometric results of Study III revealed no significant difference regarding the percentage of bone between any of the compositions of DBBM and PAB at any time point. However, the percentage of bone increased significantly between 10 and 30 weeks at the expense of non-mineralized tissue. When investigating the pattern of ingrowth of mineralized bone into particulate grafts, mineralization was gradually seen from 10 to 30 weeks with complete mineralization after 30 weeks, which corresponds to a previous statement that bone is formed with an approximate rate of 1 mm per month (130). Hence, the addition of PAB to DBBM did not seem to influence the regenerative outcome, but the consolidation period seems to have an impact on the mineralization of the graft, even for the ABB.

It has previously been stated that DBBM only achieves bone formation by osteoconduction due to the lack of proteins in the material. Hence, the addition of

PAB with its osteoinductive properties is necessary for sufficient bone formation (96). In contrast, it has been suggested that a small amount of proteins is present in DBBM and that the material probably possesses osteoinductive properties in a limited degree (131). This could explain why the results from Study III and clinical studies evaluating LRA histologically with 100% DBBM presented bone formation, comparable to grafts with the addition of PAB (25, 132).

The well-known osteoconductive properties of DBBM make it act like a scaffold to permit the formation of new bone determined by the biology of the graft and the mechanical environment of the host-graft interference (107). It has also been proposed that the process of bone formation depends on the number and size of channels through the grafts to permit the ingrowth of osteoprogenitor cells, capillaries, and perivascular tissue (133).

Study II demonstrated that in a graft consisting of 100% DBBM, the DBBM particles only occupy 43.5% of the total area at the moment of grafting and the remaining 56.6% is non-mineralized tissue (i.e. blood and space between DBBM particles) even after a firm compression of the graft. Hence, in a graft with 100% DBBM, there is probably space enough for bone ingrowth between the DBBM particles if soft tissue ingrowth is occluded by a membrane due to the principles of guided bone regeneration. The results from Study II also concluded that information about the area fraction of a biomaterial at only one specific time point cannot be used to estimate material resorption. As mentioned, a graft material consisting of 100% DBBM consists solely of 43.5% DBBM, and a biopsy assessing the area fraction of DBBM after a healing period is only useful if it is compared to a baseline.

The percentage of DBBM in study III maintained without any significant changes during the entire observation period. Hence, the presented percentage of DBBM of 21% in the 100:0 mixture in study III is not a result of the resorption of DBBM particles. These findings have previously been presented (95).

Dimensional stability

The GBR technique is a well-documented method to enhance bone volume (11, 134, 135). The technique has been applied for lateral augmentation with DBBM in

combination with a resorbable membrane (31-33, 36, 37) as well as with ABB in combination with DBBM and a resorbable membrane (14-16, 18).

ABB remains the gold standard for many clinicians, but the technique has some disadvantages. The increased morbidity caused by bone harvesting, the high resorption rate of the graft, and the lack of long-term studies not only assess implant survival but also the stability of the augmented bone volume over time (15).

To cover the ABB with a non-resorbable ePTFE membrane according to the GBR technique, have previously been documented to minimize the resorption of the ABB with satisfactory results (14). To simplify the technique, resorbable collagen membranes have been utilized. Due to the short duration of barrier function, a non-resorbable bone substitute has been applied on the surface of the ABB to protect the bone block from surface resorption (16, 18).

The use of ABB without coverage of DBBM or in combination with GBR has reported an extensive resorption rate as high as 78% after two years (71) and 87% after six years (136). To cover the ABB only with DBBM has reduced the resorption rate to 9.2% (17) and to apply the GBR technique with a resorbable membrane has been reported to further decrease the resorption rate to 6.9% after six months and 7.7% after ten years (15). When applying the GBR technique on ABB covered by DBBM, a gained width of the ridge presented was 7.75 ± 0.99 mm and the width reduction was 0.38 mm after ten years, and the resorption from six months to ten years was not significant (15). In study IV, the ABB in combination with DBBM and a resorbable collagen membrane presented a gained width of 4.2 ± 1.4 mm after 30 weeks. It is challenging to compare the gained width among studies, since it depends on the amount of correction of the defect.

In Study IV, the bone block was adjusted to 4 mm in width and the covering layer of DBBM was 1 mm to make a comparable starting point with the particulate graft, which was 5 mm in width. However, the resorption of the ABB in study IV was 0.2 mm, which is a more reliable number since it does not depend on the intra- or post-operative width. Hence, it seems possible that the resorption rate for ABB covered by DBBM and a resorbable collagen membrane is less than 0.5 mm, even if the augmented region is exposed to extensive pressure postoperatively, as in study IV.

Even if the resorption rate is minimized by covering the bone block with DBBM and a membrane, the risk of donor site morbidity remains. A previous RCT that applied GBR with ABB and DBBM showed an increased rate of sensory disturbances after augmentation with ABB compared to particulate grafts (32).

Systematic reviews have presented a superior gain for ABB compared to particulate grafts, but it does not seem to have an impact on the implant survival rate of the implants (12, 44). Regarding particulate grafts, there is wide variation in the gained width when different compositions of DBBM and PAB have been evaluated radiologically after lateral GBR augmentation with two-dimensional measurements. In general, the stability of the graft during the consolidation period by fixation of the membrane seems to be an important factor for the increased width. Clinical studies have demonstrated a superior increase in the width of the alveolar process when the graft material was stabilized under a membrane fixed with titanium pins. Fixation of the membrane presented a gained width of 5 mm after seven months (31) and 5.6 mm after seven to nine months (32), while no fixation presented a gained width of 3.6 mm (77) and 3.5 (34) after nine months. The particulate grafts in study IV presented a gained width between 3.1 mm and 3.4 mm after 30 weeks, which is a reduced width compared to previous studies. This could, like in the ABB situation, be explained by less correction of the defects compared to previous studies. It could also be explained by extensive pressure on the augmented regions due to the postoperative behavior of the study animals.

Another challenge in comparing the results between different study designs could be the method applied for the measurements. It has been demonstrated that the coronal aspect of the graft maintains the width to a lesser degree compared to the apical part (24, 137). Hence, the vertical position of the measurements could affect the results. Within the same study, it can also be challenging to apply the measurements in the same position when assessing the width over time.

A disadvantage with preclinical studies like study IV is the lack of clinical measurements, which probably would complement the radiographic measurements since clinical studies have described a softer surface in augmented sites with removable graft particles, which cannot be detected during radiographic assessment.

According to previous studies, assessing width changes after lateral GBR augmentation, it seems like a firm and stable graft probably will counteract compression of the augmented area and might be more important than the graft composition.

It is not possible to evaluate the clinical impact of the difference in gained width in study IV since no implants have been placed. A systematic review concluded that implant survival was higher after placement in augmentation with bone substitutes in combination with PAB compared to implants placed in AB alone (138). To evaluate the benefits and disadvantages of ABB and particulate grafts, clinical studies with long-term follow-up must be conducted.

Volumetric changes

Two-dimensional radiographic measurements will show dimensional changes only in a selected area, which can be misleading. A three-dimensional volumetric assessment will show the full area in which the graft has been placed. In grafted areas, there is always a difference comparing the center of the area and the boundaries, which could be a bias in studies assessing graft materials (128). Two-dimensional measurements are often performed in the center of the graft material. However, in clinical settings after LRA, the center of the graft is probably where you will place your implant, and the boundaries may not be as important as the center of the graft.

CBCT has been proposed to be a potentially efficient tool to evaluate the treatment outcome after grafting procedures or for long-term monitoring of the graft (139, 140) since the technique has a relatively low radiation dose and image acquisition time (141). CBCT images have previously been used to assess the fate of bone grafts (24, 29, 31-33, 136, 142, 143). However, the settings for image sectioning and display, such as section thickness and mapping of scalar values stored within the image shown to the user (e.g. contrast control), can vary (144, 145), and these settings may have a large impact on the characteristics of the final images, as shown in a recent review (146).

CBCT provides a three-dimensional illustration of the grafted area but still, the most common measurements performed in CBCT images following lateral GBR

augmentation are the two-dimensional measurement (15, 24, 31, 32). As well as for dimensional changes, the measurement protocol for volumetric changes varies among studies, and it can be challenging to compare the volumetric changes.

The protocol for volumetric measurements in study IV has previously been applied for evaluating volumetric changes after lateral augmentation (147). The idea of the applied protocol was to generate the same sections on the CT scan at different time points for assessment. The number of sections varied among the animals depending on individual width and the placement of the grafted regions, but the same number of sections was generated and evaluated for each particular augmented area in the scan acquired postoperatively and the scan acquired at euthanasia (127, 128, 147). This standardization is not always present in the studies available in the literature.

In study IV, the graft with 100% DBBM presented significantly less volume reduction compared to all other grafts after 10 and 20 weeks. However, after 30 weeks, there were no differences in the volumetric changes between the ABB and the particulate grafts, nor among the particulate grafts.

The results from the volumetric measurements in study IV should be regarded with caution since some grafted areas presented an increased volume over time instead of a volume reduction. The increased growth in bone mass was mainly seen superiorly and inferiorly and anteriorly and posteriorly for the grafted areas and was primarily seen after 30 weeks of healing and not at the earlier healing periods. The increased bone volume could be explained because of osteoconduction due to the space created by the tenting of the periosteum, which has previously been described (148). The increased growth of bone was rarely seen lateral of the augmented area, why the two-dimensional measurements might be more reliable in study IV.

The fact that a graft comprising DBBM presents less volume reduction has previously been presented. A preclinical study in rabbit calvaria assessing the volume stability of grafts with different compositions of DBBM and PAB in metallic cylinders presented less volume resorption in grafts with 100% DBBM or composition of DBBM and PAB compared to PAB alone (149).

A preclinical study in minipigs assessing different compositions of DBBM and PAB in conjunction with maxillary sinus floor augmentation demonstrated that the

volumetric changes of the graft material were significantly influenced by the composition of DBBM and PAB with minimal resorption of the graft material when DBBM was used alone (29). However, the biological environment and demands on mechanical stability after augmentation in stable metallic cylinders or in the maxillary sinus differ from the demands after lateral augmentation, since the metallic cylinder and the maxillary sinus are closed compartments where no pressure will be applied after the augmentation procedure. The lateral procedure will result in pressure on the augmented from the overlying mucosa, cheeks, and lips.

The volume reduction at 20 weeks was 18-37% for different compositions of DBBM and PAB, including the ABB covered by DBBM in study IV. The graft consisting of 100% DBBM maintained a significantly better volume compared to all other grafts. Since DBBM is a non-resorbable bone substitute, this could explain superior volumetric stability, especially since the grafts presenting the highest reduction were the graft with the highest amount of autogenous bone (i.e. the bone block and the 50:50 composition). PAB has previously shown extensive resorption when used for lateral augmentation (71).

Studies presenting volumetric changes assessed by three-dimensional measurements after lateral ridge augmentation are sparse. Three-dimensional measurements on cone-beam CT volumes for two different compositions of DBBM and PAB (90:10 and 60:40) revealed a volume reduction of 55.3% and 53.8%, respectively, after eight months. There was no significant difference in volume reduction between the two compositions (34). A retrospective study evaluating the volume reduction of an ABB from the iliac crest compared to a particulate graft demonstrated a reduced volume reduction for the particulate graft compared to the ABB (150). Consequently, the conclusions on the volumetric outcome after lateral GBR augmentation with DBBM and PAB, as well as for ABB covered by DBBM, are still inconsistent and must be systematically evaluated in clinical studies.

The radiographic protocol for the volumetric measurements in study IV seems feasible but is time-consuming. Hence, it can be discussed how beneficial the three-dimensional measurements are in the lateral situation since only one dimension of the alveolar process has to be augmented and it might be enough to acquire information

about that particular dimension (i.e. two-dimensional measurements). As opposed to defects where two dimensions must be augmented to achieve sufficient bone volume (i.e. combination of vertical and lateral augmentation or maxillary sinus floor augmentation). The cost-benefit effect could be interesting to include in future studies.

CONCLUSION

1. The histomorphometrically evaluated percentage of DBBM at baseline before grafting is inferior compared to the estimated percentage of DBBM in the graft.
2. The addition of PAB to DBBM does not seem to enhance the bone formation of the graft.
3. A prolonged consolidation period has a positive influence on the ingrowth of mineralized bone into the graft, independent of the composition of DBBM and PAB.
4. The width of the graft material seems to be better maintained with ABB covered with a non-resorbable bone substitute compared to particulate grafts with DBBM alone or in combination with PAB. The addition of PAB to DBBM does not seem to influence the width in particulate grafts.
5. The volumetric changes of the graft material seem to be comparable for ABB covered with a non-resorbable bone substitute and for particulate grafts with different compositions of DBBM and PAB after a prolonged healing period. In the early healing phase, DBBM alone seemed to maintain the width better.

CLINICAL IMPLICATIONS AND FUTURE PERSPECTIVES

It has been suggested that priority should be given to those bone augmentation procedures that simplify the surgical procedure, are less invasive, present the less risk of complications, and reach their goal within the shortest time frame (10). To completely or partly replace the harvesting of AB with bone substitutes will simplify the surgical procedure and be less invasive since there will be no need for bone harvesting from another surgical site; it would reduce the risk of sensory disturbances and shorten the treatment time frame.

The results from this Ph.D. thesis should be regarded with caution since it is an experimental study that is not directly applicable to humans. However, the results demonstrated that ABB covered by DBBM maintains a better width of the grafted region compared to particulate grafts. Adding different compositions of PAB to DBBM could not reveal an enhanced bone formation, an increased gain in width, or a reduced volumetric reduction compared to DBBM alone. It can be discussed whether the superior gain in width for the ABB compared to particulate grafts has a clinical impact or not. This matter was not possible to assess in this Ph.D. thesis since no implants were installed.

Within the limitations of this Ph.D. thesis, it seems like the addition of PAB to DBBM in particulate grafts is not necessary. However, lateral GBR augmentation with 100% DBBM should be investigated in well-designed clinical studies with systematic long-term follow up on implant survival and the stability of augmented bone volume over time with standardized radiographic protocols where the width of the residual bone and the dimension of the applied graft are considered. The cost-benefit effect of different radiographic protocols should be evaluated.

ACKNOWLEDGMENTS

Thomas Starch-Jensen – My main supervisor. Thank you for introducing me to the field of research and for sharing your valuable knowledge. It has been a privilege to work with your constructive and skillful guidance and your sharp deadlines. Thank you for challenging me to my limits, as a researcher, as a surgeon and as a human being. At last, thank you for improving my Danish by always reminding me of my bad pronunciation.

Arne Mordenfeld – My co-supervisor. Thank you for sharing your scientific and surgical skills and for always believing in me. Your contribution to my improvements as a surgeon, as a researcher and as a human being is invaluable. I will always be grateful for all your help and endless support.

Christer Dahlin – My co-supervisor. Thank you for letting me spend time at Department of Biomaterials in Gothenburg where I now will continue my research carrier. Thank you for sharing your knowledge, for supporting me, for valuable discussions and for always finding time in your tight schedule.

Mats Hallman – My co-supervisor. Thank you for all your help and support during this PhD thesis, for sharing your valuable scientific knowledge and for making it possible for me to improve my surgical skills in Gävle.

Lene Boelsmand-Henriksen – Operation nurse at Department of Oral and Maxillofacial Surgery, Aalborg University Hospital for your amazing help and assistance during the operations and for mental support during tough times.

Benedict, Sigga, Ole, Torben and Jens – The staff at the animal facilities, Aalborg University Hospital for your giving me access to the animal facilities and for excellent help with handling of the animals.

Department of Oral and Maxillofacial Surgery, Aalborg University Hospital – To all the staff at the department, especially to Janek Dalsgaard Jensen and Anni Wehrmann Pedersen for making this thesis possible.

Birgitta Norlindh & Lena Emanuelsson – For your valuable help with the histological preparations and for taking so good care of me during my time in Gothenburg that I now will return permanently.

Rubens Spin-Neto – For your valuable help with the volumetric measurements, for excellent discussions and for the quickest responses I have ever experienced.

Andreas Cederlund – For your valuable help with the width measurements.

Pernille Veiss-Pedersen & Jens Brøndum Frøkjær – Department of Radiology, Aalborg University Hospital, for making it possible to run minipigs in the CT scanner.

Lars Henrik Hejlesen – My soon to be husband for always supporting me. I love you and you mean everything to me.

Josephine Sköldstam – For all the valuable discussions, the laughs and for being an amazing bartender when I needed it.

My mother, father and brother – For always believing in and supporting me

REFERENCES

1. Albrektsson T, Zarb G, Worthington P, Eriksson AR. The long-term efficacy of currently used dental implants: a review and proposed criteria of success. *The International Journal of Oral & Maxillofacial Implants*. 1986;1(1):11-25.
2. Leonhardt A, Grondahl K, Bergstrom C, Lekholm U. Long-term follow-up of osseointegrated titanium implants using clinical, radiographic, and microbiological parameters. *Clinical Oral Implants Research*. 2002;13(2):127-32.
3. Lindquist LW, Carlsson GE, Jemt T. A prospective 15-year follow-up study of mandibular fixed prostheses supported by osseointegrated implants: clinical results and marginal bone loss. *Clinical Oral Implants Research*. 1996;7(4):329-36.
4. van Steenberghe D, Quirynen M. [The implant/tissue interface in a clinical perspective]. *Parodontologie (Berlin, Germany)*. 1990;1(4):343-50.
5. de Lange GL. Aesthetic and prosthetic principles for single tooth implant procedures: an overview. *Practical Periodontics and Aesthetic Dentistry: PPAD*. 1995;7(1):51-61; quiz 2.
6. Phillips K, Kois JC. Aesthetic peri-implant site development. The restorative connection. *Dental Clinics of North America*. 1998;42(1):57-70.
7. Araujo MG, Lindhe J. Dimensional ridge alterations following tooth extraction. An experimental study in the dog. *Journal of Clinical Periodontology*. 2005;32(2):212-8.
8. Cawood JI, Howell RA. A classification of the edentulous jaws. *International Journal of Oral and Maxillofacial Surgery*. 1988;17(4):232-6.
9. Schropp L, Kostopoulos L, Wenzel A. Bone healing following immediate versus delayed placement of titanium implants into extraction sockets: a prospective clinical study. *The International Journal of Oral & Maxillofacial Implants*. 2003;18(2):189-99.
10. Chiapasco M, Casentini P, Zaniboni M. Bone augmentation procedures in implant dentistry. *The International Journal of Oral & Maxillofacial Implants*. 2009;24 Suppl:237-59.

11. Donos N, Mardas N, Chadha V. Clinical outcomes of implants following lateral bone augmentation: systematic assessment of available options (barrier membranes, bone grafts, split osteotomy). *Journal of Clinical Periodontology*. 2008;35(8 Suppl):173-202.
12. Elnayef B, Porta C, Suarez-Lopez Del Amo F, Mordini L, Gargallo-Albiol J, Hernandez-Alfaro F. The fate of lateral ridge augmentation: a systematic review and meta-analysis. *The International Journal of Oral & Maxillofacial Implants*. 2018;33(3):622-35.
13. Jensen SS, Terheyden H. Bone augmentation procedures in localized defects in the alveolar ridge: clinical results with different bone grafts and bone-substitute materials. *The International Journal of Oral & Maxillofacial Implants*. 2009;24 Suppl:218-36.
14. Buser D, Dula K, Hirt HP, Schenk RK. Lateral ridge augmentation using autografts and barrier membranes: a clinical study with 40 partially edentulous patients. *Journal of Oral and Maxillofacial Surgery: Official Journal of the American Association of Oral and Maxillofacial Surgeons*. 1996;54(4):420-32; discussion 32-3.
15. Chappuis V, Cavusoglu Y, Buser D, von Arx T. Lateral ridge augmentation using autogenous block grafts and guided bone regeneration: a 10-year prospective case series study. *Clinical Implant Dentistry and Related Research*. 2017;19(1):85-96.
16. Cordaro L, Torsello F, Morcavallo S, di Torresanto VM. Effect of bovine bone and collagen membranes on healing of mandibular bone blocks: a prospective randomized controlled study. *Clinical Oral Implants Research*. 2011;22(10):1145-50.
17. Maiorana C, Beretta M, Salina S, Santoro F. Reduction of autogenous bone graft resorption by means of Bio-Oss coverage: a prospective study. *International Journal of Periodontics & Restorative Dentistry*. 2005;25(1):19-25.
18. von Arx T, Buser D. Horizontal ridge augmentation using autogenous block grafts and the guided bone regeneration technique with collagen membranes: a clinical study with 42 patients. *Clinical Oral Implants Research*. 2006;17(4):359-66.

19. Cricchio G, Lundgren S. Donor site morbidity in two different approaches to anterior iliac crest bone harvesting. *Clinical Implant Dentistry and Related Research*. 2003;5(3):161-9.
20. Johansson B, Grepe A, Wannfors K, Hirsch JM. A clinical study of changes in the volume of bone grafts in the atrophic maxilla. *Dento Maxillofacial Radiology*. 2001;30(3):157-61.
21. Nkenke E, Stelzle F. Clinical outcomes of sinus floor augmentation for implant placement using autogenous bone or bone substitutes: a systematic review. *Clinical Oral Implants Research*. 2009;20 Suppl 4:124-33.
22. Jensen SS, Aaboe M, Pinholt EM, Hjorting-Hansen E, Melsen F, Ruyter IE. Tissue reaction and material characteristics of four bone substitutes. *The International Journal of Oral & Maxillofacial Implants*. 1996;11(1):55-66.
23. Schilling AF, Linhart W, Filke S, Gebauer M, Schinke T, Rueger JM, et al. Resorbability of bone substitute biomaterials by human osteoclasts. *Biomaterials*. 2004;25(18):3963-72.
24. Block MS, Ducote CW, Mercante DE. Horizontal augmentation of thin maxillary ridge with bovine particulate xenograft is stable during 500 days of follow-up: preliminary results of 12 consecutive patients. *Journal of Oral and Maxillofacial Surgery: Official Journal of the American Association of Oral and Maxillofacial Surgeons*. 2012;70(6):1321-30.
25. Friedmann A, Strietzel FP, Marezki B, Pitaru S, Bernimoulin JP. Histological assessment of augmented jaw bone utilizing a new collagen barrier membrane compared to a standard barrier membrane to protect a granular bone substitute material. *Clinical Oral Implants Research*. 2002;13(6):587-94.
26. Hallman M, Lundgren S, Sennerby L. Histologic analysis of clinical biopsies taken 6 months and 3 years after maxillary sinus floor augmentation with 80% bovine hydroxyapatite and 20% autogenous bone mixed with fibrin glue. *Clinical Implant Dentistry and Related Research*. 2001;3(2):87-96.
27. Hellem S, Astrand P, Stenstrom B, Engquist B, Bengtsson M, Dahlgren S. Implant treatment in combination with lateral augmentation of the alveolar

- process: a 3-year prospective study. *Clinical Implant Dentistry and Related Research*. 2003;5(4):233-40.
28. Jensen T, Schou S, Gundersen HJ, Forman JL, Terheyden H, Holmstrup P. Bone-to-implant contact after maxillary sinus floor augmentation with Bio-Oss and autogenous bone in different ratios in mini pigs. *Clinical Oral Implants Research*. 2013;24(6):635-44.
 29. Jensen T, Schou S, Svendsen PA, Forman JL, Gundersen HJ, Terheyden H, et al. Volumetric changes of the graft after maxillary sinus floor augmentation with Bio-Oss and autogenous bone in different ratios: a radiographic study in minipigs. *Clinical Oral Implants Research*. 2012;23(8):902-10.
 30. John HD, Wenz B. Histomorphometric analysis of natural bone mineral for maxillary sinus augmentation. *The International Journal of Oral & Maxillofacial Implants*. 2004;19(2):199-207.
 31. Meloni SM, Jovanovic SA, Urban I, Canullo L, Pisano M, Tallarico M. Horizontal ridge augmentation using GBR with a native collagen membrane and 1:1 ratio of particulated xenograft and autologous bone: a 1-year prospective clinical study. *Clinical Implant Dentistry and Related Research*. 2017;19(1):38-45.
 32. Mendoza-Azpur G, de la Fuente A, Chavez E, Valdivia E, Khouly I. Horizontal ridge augmentation with guided bone regeneration using particulate xenogenic bone substitutes with or without autogenous block grafts: a randomized controlled trial. *Clinical Implant Dentistry and Related Research*. 2019;21(4):521-30.
 33. Mordenfeld A, Aludden H, Starch-Jensen T. Lateral ridge augmentation with two different ratios of deproteinized bovine bone and autogenous bone: a 2-year follow-up of a randomized and controlled trial. *Clinical Implant Dentistry and Related Research*. 2017;19(5):884-94.
 34. Mordenfeld A, Johansson CB, Albrektsson T, Hallman M. A randomized and controlled clinical trial of two different compositions of deproteinized bovine bone and autogenous bone used for lateral ridge augmentation. *Clinical Oral Implants Research*. 2014;25(3):310-20.

35. Simion M, Dahlin C, Rocchietta I, Stavropoulos A, Sanchez R, Karring T. Vertical ridge augmentation with guided bone regeneration in association with dental implants: an experimental study in dogs. *Clinical Oral Implants Research*. 2007;18(1):86-94.
36. Urban IA, Nagursky H, Lozada JL. Horizontal ridge augmentation with a resorbable membrane and particulated autogenous bone with or without anorganic bovine bone-derived mineral: a prospective case series in 22 patients. *The International Journal of Oral & Maxillofacial Implants*. 2011;26(2):404-14.
37. Urban IA, Nagursky H, Lozada JL, Nagy K. Horizontal ridge augmentation with a collagen membrane and a combination of particulated autogenous bone and anorganic bovine bone-derived mineral: a prospective case series in 25 patients. *Int J Periodontics Restorative Dent*. 2013;33(3):299-307.
38. Galindo-Moreno P, Moreno-Riestra I, Avila G, Padiál-Molina M, Paya JA, Wang HL, et al. Effect of anorganic bovine bone to autogenous cortical bone ratio upon bone remodeling patterns following maxillary sinus augmentation. *Clinical Oral Implants Research*. 2011;22(8):857-64.
39. Araujo M, Linder E, Lindhe J. Effect of a xenograft on early bone formation in extraction sockets: an experimental study in dog. *Clinical Oral Implants Research*. 2009;20(1):1-6.
40. Artzi Z, Weinreb M, Givol N, Rohrer MD, Nemcovsky CE, Prasad HS, et al. Biomaterial resorption rate and healing site morphology of inorganic bovine bone and beta-tricalcium phosphate in the canine: a 24-month longitudinal histologic study and morphometric analysis. *The International Journal of Oral & Maxillofacial Implants*. 2004;19(3):357-68.
41. Jensen SS, Brogгинi N, Hjorting-Hansen E, Schenk R, Buser D. Bone healing and graft resorption of autograft, anorganic bovine bone and beta-tricalcium phosphate: a histologic and histomorphometric study in the mandibles of minipigs. *Clinical Oral Implants Research*. 2006;17(3):237-43.
42. Stavropoulos A, Kostopoulos L, Mardas N, Nyengaard JR, Karring T. Deproteinized bovine bone used as an adjunct to guided bone augmentation: an

- experimental study in the rat. *Clinical Implant Dentistry and Related Research*. 2001;3(3):156-65.
43. Pikdoken L, Gurbuzer B, Kucukodaci Z, Urhan M, Baris E, Tezulas E. Scintigraphic, histologic, and histomorphometric analyses of bovine bone mineral and autogenous bone mixture in sinus floor augmentation: a randomized controlled trial--results after 4 months of healing. *Journal of Oral and Maxillofacial Surgery: Official Journal of the American Association of Oral and Maxillofacial Surgeons*. 2011;69(1):160-9.
 44. Troeltzsch M, Kauffmann P, Gruber R, Brockmeyer P, Moser N, Rau A, et al. Clinical efficacy of grafting materials in alveolar ridge augmentation: a systematic review. *Journal of Cranio-maxillo-facial Surgery: Official Publication of the European Association for Cranio-Maxillo-Facial Surgery*. 2016;44(10):1618-29.
 45. Cohen MM, Jr. The new bone biology: pathologic, molecular, and clinical correlates. *American Journal of Medical Genetics Part A*. 2006;140(23):2646-706.
 46. Datta HK, Ng WF, Walker JA, Tuck SP, Varanasi SS. The cell biology of bone metabolism. *Journal of Clinical Pathology*. 2008;61(5):577-87.
 47. Mackiewicz Z, Niklinska WE, Kowalewska J, Chyczewski L. Bone as a source of organism vitality and regeneration. *Folia Histochemica et Cytobiologica*. 2011;49(4):558-69.
 48. Proff P, Romer P. The molecular mechanism behind bone remodelling: a review. *Clinical Oral Investigations*. 2009;13(4):355-62.
 49. Buck DW, 2nd, Dumanian GA. Bone biology and physiology: Part I. The fundamentals. *Plastic and reconstructive surgery*. 2012;129(6):1314-20.
 50. Ducy P, Schinke T, Karsenty G. The osteoblast: a sophisticated fibroblast under central surveillance. *Science (New York, NY)*. 2000;289(5484):1501-4.
 51. Kular J, Tickner J, Chim SM, Xu J. An overview of the regulation of bone remodelling at the cellular level. *Clinical Biochemistry*. 2012;45(12):863-73.

52. Bonewald LF. The amazing osteocyte. *Journal of Bone and Mineral Research: The Official Journal of the American Society for Bone and Mineral Research*. 2011;26(2):229-38.
53. Franz-Odenaal TA, Hall BK, Witten PE. Buried alive: how osteoblasts become osteocytes. *Developmental Dynamics: An Official Publication of the American Association of Anatomists*. 2006;235(1):176-90.
54. Bellido T. Osteocyte-driven bone remodeling. *Calcified Tissue International*. 2014;94(1):25-34.
55. Dudley HR, Spiro D. The fine structure of bone cells. *The Journal of Biophysical and Biochemical Cytology*. 1961;11(3):627-49.
56. Tanaka-Kamioka K, Kamioka H, Ris H, Lim SS. Osteocyte shape is dependent on actin filaments and osteocyte processes are unique actin-rich projections. *Journal of Bone and Mineral Research: The Official Journal of the American Society for Bone and Mineral Research*. 1998;13(10):1555-68.
57. Aarden EM, Burger EH, Nijweide PJ. Function of osteocytes in bone. *Journal of Cellular Biochemistry*. 1994;55(3):287-99.
58. Burger EH, Klein-Nulend J. Mechanotransduction in bone-role of the lacuno-canalicular network. *The FASEB Journal*. 1999;13 Suppl: S101-12.
59. Robling AG, Niziolek PJ, Baldrige LA, Condon KW, Allen MR, Alam I, et al. Mechanical stimulation of bone in vivo reduces osteocyte expression of Sost/sclerostin. *The Journal of Biological Chemistry*. 2008;283(9):5866-75.
60. Rochefort GY, Pallu S, Benhamou CL. Osteocyte: the unrecognized side of bone tissue. *Osteoporosis International*. 2010;21(9):1457-69.
61. Miller SC, de Saint-Georges L, Bowman BM, Jee WS. Bone lining cells: structure and function. *Scanning Microscopy Journal* 1989;3(3):953-60; discussion 60-1.
62. Recker R. Embryology, anatomy, and microstructure of bone. In: Coe FL and Favus M, ed. *Disorders of bone and mineral metabolism*. New York: Raven Press, 1992:219-240.
63. Teitelbaum SL. Bone resorption by osteoclasts. *Science (New York, NY)*. 2000;289(5484):1504-8.

64. Blair HC, Athanasou NA. Recent advances in osteoclast biology and pathological bone resorption. *Histology & Histopathology*. 2004;19(1):189-99.
65. Deal C. Future therapeutic targets in osteoporosis. *Current Opinion in Rheumatology*. 2009;21(4):380-5.
66. Zipfel GJ, Guiot BH, Fessler RG. Bone grafting. *Neurosurgical Focus*. 2003;14(2):e8.
67. Raggatt LJ, Partridge NC. Cellular and molecular mechanisms of bone remodeling. *The Journal of Biological Chemistry*. 2010;285(33):25103-8.
68. Burchardt H. The biology of bone graft repair. *Clinical Orthopaedics and Related Research*. 1983(174):28-42.
69. Gulinelli JL, Dutra RA, Marao HF, Simeao SFP, Groli Klein GB, Santos PL. Maxilla reconstruction with autogenous bone block grafts: computed tomography evaluation and implant survival in a 5-year retrospective study. *International Journal of Oral and Maxillofacial Surgery*. 2017;46(8):1045-51.
70. Sjostrom M, Sennerby L, Nilson H, Lundgren S. Reconstruction of the atrophic edentulous maxilla with free iliac crest grafts and implants: a 3-year report of a prospective clinical study. *Clinical Implant Dentistry and Related Research*. 2007;9(1):46-59.
71. Dasmah A, Thor A, Ekkestubbe A, Sennerby L, Rasmusson L. Particulate vs. block bone grafts: three-dimensional changes in graft volume after reconstruction of the atrophic maxilla, a 2-year radiographic follow-up. *Journal of Cranio-maxillo-facial surgery: Official Publication of the European Association for Cranio-Maxillo-Facial Surgery*. 2012;40(8):654-9.
72. Thor A, Wannfors K, Sennerby L, Rasmusson L. Reconstruction of the severely resorbed maxilla with autogenous bone, platelet-rich plasma, and implants: 1-year results of a controlled prospective 5-year study. *Clinical Implant Dentistry and Related Research*. 2005;7(4):209-20.
73. Gordh M, Alberius P. Some basic factors essential to autogenic nonvascularized onlay bone grafting to the craniofacial skeleton. *Scandinavian Journal of Plastic and Reconstructive Surgery and Hand Surgery*. 1999;33(2):129-46.

74. Berglundh T, Lindhe J. Healing around implants placed in bone defects treated with Bio-Oss: an experimental study in the dog. *Clinical Oral Implants Research*. 1997;8(2):117-24.
75. Haas R, Donath K, Fodinger M, Watzek G. Bovine hydroxyapatite for maxillary sinus grafting: comparative histomorphometric findings in sheep. *Clinical Oral Implants Research*. 1998;9(2):107-16.
76. Hammerle CH, Chiantella GC, Karring T, Lang NP. The effect of a deproteinized bovine bone mineral on bone regeneration around titanium dental implants. *Clinical Oral Implants Research*. 1998;9(3):151-62.
77. Hammerle CH, Jung RE, Yaman D, Lang NP. Ridge augmentation by applying bioresorbable membranes and deproteinized bovine bone mineral: a report of twelve consecutive cases. *Clinical Oral Implants Research*. 2008;19(1):19-25.
78. Hockers T, Abensur D, Valentini P, Legrand R, Hammerle CH. The combined use of bioresorbable membranes and xenografts or autografts in the treatment of bone defects around implants: a study in beagle dogs. *Clinical Oral Implants Research*. 1999;10(6):487-98.
79. Mayfield LJ, Skoglund A, Hising P, Lang NP, Attstrom R. Evaluation following functional loading of titanium fixtures placed in ridges augmented by deproteinized bone mineral: a human case study. *Clinical Oral Implants Research*. 2001;12(5):508-14.
80. Rocchietta I, Fontana F, Simion M. Clinical outcomes of vertical bone augmentation to enable dental implant placement: a systematic review. *Journal of Clinical Periodontology*. 2008;35(8 Suppl):203-15.
81. Terheyden H, Jepsen S, Moller B, Tucker MM, Rueger DC. Sinus floor augmentation with simultaneous placement of dental implants using a combination of deproteinized bone xenografts and recombinant human osteogenic protein-1: a histometric study in miniature pigs. *Clinical Oral Implants Research*. 1999;10(6):510-21.
82. Valentini P, Abensur D, Wenz B, Peetz M, Schenk R. Sinus grafting with porous bone mineral (Bio-Oss) for implant placement: a 5-year study on 15 patients. *International Journal on Periodontics Restorative Dentistry*. 2000;20(3):245-53.

83. Hallman M, Cederlund A, Lindskog S, Lundgren S, Sennerby L. A clinical histologic study of bovine hydroxyapatite in combination with autogenous bone and fibrin glue for maxillary sinus floor augmentation: results after 6 to 8 months of healing. *Clinical Oral Implants Research*. 2001;12(2):135-43.
84. Schlegel AK, Donath K. Bio-Oss: a resorbable bone substitute? *Journal of Long-Term Effects of Medical Implants*. 1998;8(3-4):201-9.
85. Schlegel KA, Fichtner G, Schultze-Mosgau S, Wiltfang J. Histologic findings in sinus augmentation with autogenous bone chips versus a bovine bone substitute. *The International Journal of Oral & Maxillofacial Implants*. 2003;18(1):53-8.
86. Galindo-Moreno P, Hernandez-Cortes P, Mesa F, Carranza N, Juodzbaly G, Aguilar M, et al. Slow resorption of anorganic bovine bone by osteoclasts in maxillary sinus augmentation. *Clinical Implant Dentistry and Related Research*. 2013;15(6):858-66.
87. Karabuda C, Ozdemir O, Tosun T, Anil A, Olgac V. Histological and clinical evaluation of 3 different grafting materials for sinus lifting procedure based on 8 cases. *Journal of Periodontology*. 2001;72(10):1436-42.
88. McAllister BS, Margolin MD, Cogan AG, Buck D, Hollinger JO, Lynch SE. Eighteen-month radiographic and histologic evaluation of sinus grafting with anorganic bovine bone in the chimpanzee. *The International Journal of Oral & Maxillofacial Implants*. 1999;14(3):361-8.
89. Perrotti V, Nicholls BM, Horton MA, Piattelli A. Human osteoclast formation and activity on a xenogenous bone mineral. *Journal of Biomedical Materials Research Part A*. 2009;90(1):238-46.
90. Piattelli M, Favero GA, Scarano A, Orsini G, Piattelli A. Bone reactions to anorganic bovine bone (Bio-Oss) used in sinus augmentation procedures: a histologic long-term report of 20 cases in humans. *The International Journal of Oral & Maxillofacial Implants*. 1999;14(6):835-40.
91. Tadjoedin ES, de Lange GL, Bronckers AL, Lyaruu DM, Burger EH. Deproteinized cancellous bovine bone (Bio-Oss) as bone substitute for sinus floor elevation: a retrospective, histomorphometrical study of five cases. *Journal of Clinical Periodontology*. 2003;30(3):261-70.

92. Taylor JC, Cuff SE, Leger JP, Morra A, Anderson GI. In vitro osteoclast resorption of bone substitute biomaterials used for implant site augmentation: a pilot study. *The International Journal of Oral & Maxillofacial Implants.* 2002;17(3):321-30.
93. Valentini P, Abensur D, Densari D, Graziani JN, Hammerle C. Histological evaluation of Bio-Oss in a 2-stage sinus floor elevation and implantation procedure: a human case report. *Clinical Oral Implants Research.* 1998;9(1):59-64.
94. Yildirim M, Spiekermann H, Biesterfeld S, Edelhoff D. Maxillary sinus augmentation using xenogenic bone substitute material Bio-Oss in combination with venous blood: a histologic and histomorphometric study in humans. *Clinical Oral Implants Research.* 2000;11(3):217-29.
95. Mordenfeld A, Hallman M, Johansson CB, Albrektsson T. Histological and histomorphometrical analyses of biopsies harvested 11 years after maxillary sinus floor augmentation with deproteinized bovine and autogenous bone. *Clinical Oral Implants Research.* 2010;21(9):961-70.
96. Baldini N, De Sanctis M, Ferrari M. Deproteinized bovine bone in periodontal and implant surgery. *Dental Materials.* 2011;27(1):61-70.
97. Dahlin C, Linde A, Gottlow J, Nyman S. Healing of bone defects by guided tissue regeneration. *Plastic and Reconstructive Surgery.* 1988;81(5):672-6.
98. Dimitriou R, Mataliotakis GI, Calori GM, Giannoudis PV. The role of barrier membranes for guided bone regeneration and restoration of large bone defects: current experimental and clinical evidence. *BMC Medicine.* 2012;10:81.
99. Retzeppi M, Donos N. Guided bone regeneration: biological principle and therapeutic applications. *Clinical Oral Implants Research.* 2010;21(6):567-76.
100. Turri A, Elgali I, Vazirisani F, Johansson A, Emanuelsson L, Dahlin C, et al. Guided bone regeneration is promoted by the molecular events in the membrane compartment. *Biomaterials.* 2016;84:167-83.
101. Gerstenfeld LC, Cho TJ, Kon T, Aizawa T, Cruceta J, Graves BD, et al. Impaired intramembranous bone formation during bone repair in the absence of tumor necrosis factor-alpha signaling. *Cells, Tissues, Organs.* 2001;169(3):285-94.

102. Owens KW, Yukna RA. Collagen membrane resorption in dogs: a comparative study. *Implant Dentistry* 2001;10(1):49-58.
103. Rothamel D, Schwarz F, Fienitz T, Smeets R, Dreiseidler T, Ritter L, et al. Biocompatibility and biodegradation of a native porcine pericardium membrane: results of in vitro and in vivo examinations. *The International Journal of Oral & Maxillofacial Implants*. 2012;27(1):146-54.
104. Giannoudis PV, Dinopoulos H, Tsiridis E. Bone substitutes: an update. *Injury*. 2005;36 Suppl 3:S20-7.
105. Salyer KE, Taylor DP. Bone grafts in craniofacial surgery. *Clinics in Plastic Surgery*. 1987;14(1):27-35.
106. Urist MR. Bone: formation by autoinduction. *Science (New York, NY)*. 1965;150(3698):893-9.
107. Stevenson S. Biology of bone grafts. *The Orthopedic Clinics of North America*. 1999;30(4):543-52.
108. Oryan A, Alidadi S, Moshiri A, Bigham-Sadegh A. Bone morphogenetic proteins: a powerful osteoinductive compound with non-negligible side effects and limitations. *BioFactors (Oxford, England)*. 2014;40(5):459-81.
109. Reddi AH, Wientroub S, Muthukumaran N. Biologic principles of bone induction. *The Orthopedic Clinics of North America*. 1987;18(2):207-12.
110. Araujo MG, Liljenberg B, Lindhe J. Dynamics of Bio-Oss collagen incorporation in fresh extraction wounds: an experimental study in the dog. *Clinical Oral Implants Research*. 2010;21(1):55-64.
111. Marx RE. Bone and bone graft healing. *Oral and Maxillofacial Surgery Clinics of North America*. 2007;19(4):455-66, v.
112. Prolo DJ, Rodrigo JJ. Contemporary bone graft physiology and surgery. *Clinical Orthopaedics and Related Research*. 1985(200):322-42.
113. Tagil M. The morselized and impacted bone graft: animal experiments on proteins, impaction, and load. *Acta orthopaedica Scandinavica Supplementum*. 2000;290:1-40.

114. Cha JK, Kim CS, Choi SH, Cho KS, Chai JK, Jung UW. The influence of perforating the autogenous block bone and the recipient bed in dogs. Part II: histologic analysis. *Clinical Oral Implants Research*. 2012;23(8):987-92.
115. de Carvalho PS, Vasconcellos LW, Pi J. Influence of bed preparation on the incorporation of autogenous bone grafts: a study in dogs. *The International Journal of Oral & Maxillofacial Implants*. 2000;15(4):565-70.
116. Gordh M, Alberius P, Lindberg L, Johnell O. Bone graft incorporation after cortical perforations of the host bed. *Otolaryngology—Head and Neck Surgery: Official Journal of American Academy of Otolaryngology-Head and Neck Surgery*. 1997;117(6):664-70.
117. Chen ST, Beagle J, Jensen SS, Chiapasco M, Darby I. Consensus statements and recommended clinical procedures regarding surgical techniques. *The International Journal of Oral & Maxillofacial Implants*. 2009;24 Suppl:272-8.
118. Reinholz GG, Lu L, Saris DB, Yaszemski MJ, O'Driscoll SW. Animal models for cartilage reconstruction. *Biomaterials*. 2004;25(9):1511-21.
119. Bollen P, Ellegaard L. The Gottingen minipig in pharmacology and toxicology. *Pharmacology & Toxicology*. 1997;80 Suppl 2:3-4.
120. Reinwald S, Burr D. Review of nonprimate, large animal models for osteoporosis research. *Journal of Bone and Mineral Research: The Official Journal of the American Society for Bone and Mineral Research*. 2008;23(9):1353-68.
121. Kulak CA, Dempster DW. Bone histomorphometry: a concise review for endocrinologists and clinicians. *Arquivos Brasileiros de Endocrinologia e Metabologia*. 2010;54(2):87-98.
122. A P. Stereologic basis of bone histomorphometry; theory of quantitative microscopy and reconstruction of the third dimension. In: PR R, editor. *Bone histomorphometry: techniques and interpretation*. Boca Raton, FL: CRC Press, USA; 1983. p. 143-244.
123. Dempster DW, Compston JE, Drezner MK, Glorieux FH, Kanis JA, Malluche H, et al. Standardized nomenclature, symbols, and units for bone histomorphometry: a 2012 update of the report of the ASBMR

- Histomorphometry Nomenclature Committee. *Journal of Bone and Mineral Research: The Official Journal of the American Society for Bone and Mineral Research*. 2013;28(1):2-17.
124. Vandeweghe S, Coelho PG, Vanhove C, Wennerberg A, Jimbo R. Utilizing micro-computed tomography to evaluate bone structure surrounding dental implants: a comparison with histomorphometry. *Journal of Biomedical Materials Research Part B, Applied biomaterials*. 2013;101(7):1259-66.
 125. Froum SJ, Wallace SS, Cho SC, Elian N, Tarnow DP. Histomorphometric comparison of a biphasic bone ceramic to anorganic bovine bone for sinus augmentation: 6- to 8-month postsurgical assessment of vital bone formation. A pilot study. *The International Journal of Periodontics & Restorative Dentistry*. 2008;28(3):273-81.
 126. Donath K, Breuner G. A method for the study of undecalcified bones and teeth with attached soft tissues: the Sage-Schliff (sawing and grinding) technique. *Journal of Oral Pathology*. 1982;11(4):318-26.
 127. Spin-Neto R, Stavropoulos A, Coletti FL, Pereira LA, Marcantonio E, Jr., Wenzel A. Remodeling of cortical and corticocancellous fresh-frozen allogeneic block bone grafts: a radiographic and histomorphometric comparison to autologous bone grafts. *Clinical Oral Implants Research*. 2015;26(7):747-52.
 128. Spin-Neto R, Stavropoulos A, Dias Pereira LA, Marcantonio E, Jr., Wenzel A. Fate of autologous and fresh-frozen allogeneic block bone grafts used for ridge augmentation: a CBCT-based analysis. *Clinical Oral Implants Research*. 2013;24(2):167-73.
 129. Beitlitum I, Artzi Z, Nemcovsky CE. Clinical evaluation of particulate allogeneic with and without autogenous bone grafts and resorbable collagen membranes for bone augmentation of atrophic alveolar ridges. *Clinical Oral Implants Research*. 2010;21(11):1242-50.
 130. Schenk RK, Buser D, Hardwick WR, Dahlin C. Healing pattern of bone regeneration in membrane-protected defects: a histologic study in the canine mandible. *The International Journal of Oral & Maxillofacial Implants*. 1994;9(1):13-29.

131. Schwartz Z, Weesner T, van Dijk S, Cochran DL, Mellonig JT, Lohmann CH, et al. Ability of deproteinized cancellous bovine bone to induce new bone formation. *Journal of Periodontology*. 2000;71(8):1258-69.
132. Zitzmann NU, Scharer P, Marinello CP, Schubach P, Berglundh T. Alveolar ridge augmentation with Bio-Oss: a histologic study in humans. *International Journal of Periodontics Restorative Dentology*. 2001;21(3):288-95.
133. Bloomquist DS TT. Bell WH, ed. *Modern practice in orthognatic andreconstructive surgery*. Philadelphia, Pennsylvania, US: W.B. Saunders Company; 1992. 831-53 p.
134. Aghaloo TL, Moy PK. Which hard tissue augmentation techniques are the most successful in furnishing bony support for implant placement? *The International Journal of Oral & Maxillofacial Implants*. 2007;22 Suppl:49-70.
135. Sanz-Sanchez I, Ortiz-Vigon A, Sanz-Martin I, Figuero E, Sanz M. Effectiveness of lateral bone augmentation on the alveolar crest dimension: a systematic review and meta-analysis. *Journal of Dental Research*. 2015;94(9 Suppl):128s-42s.
136. Sbordone C, Toti P, Guidetti F, Califano L, Santoro A, Sbordone L. Volume changes of iliac crest autogenous bone grafts after vertical and horizontal alveolar ridge augmentation of atrophic maxillas and mandibles: a 6-year computerized tomographic follow-up. *Journal of Oral and Maxillofacial Surgery: Official Journal of the American Association of Oral and Maxillofacial Surgeons*. 2012;70(11):2559-65.
137. Mir-Mari J, Wui H, Jung RE, Hammerle CH, Benic GI. Influence of blinded wound closure on the volume stability of different GBR materials: an in vitro cone-beam computed tomographic examination. *Clinical Oral Implants Research*. 2016;27(2):258-65.
138. Al-Nawas B, Schiegnitz E. Augmentation procedures using bone substitute materials or autogenous bone: a systematic review and meta-analysis. *European Journal of Oral implantology*. 2014;7 Suppl 2:S219-34.
139. Ehrhart N, Kraft S, Conover D, Rosier RN, Schwarz EM. Quantification of massive allograft healing with dynamic contrast enhanced-MRI and cone beam-

- CT: a pilot study. *Clinical Orthopaedics and Related Research*. 2008;466(8):1897-904.
140. Grauer D, Cevidanes LS, Proffit WR. Working with DICOM craniofacial images. *American Journal of Orthodontics and Dentofacial Orthopedics: Official Publication of the American Association of Orthodontists, its constituent societies, and the American Board of Orthodontics*. 2009;136(3):460-70.
141. De Vos W, Casselman J, Swennen GR. Cone-beam computerized tomography (CBCT) imaging of the oral and maxillofacial region: a systematic review of the literature. *International Journal of Oral and Maxillofacial Surgery*. 2009;38(6):609-25.
142. MO GBCEB. Clinical and 3-dimensional radiographic evaluation of autogenous iliac block bone grafting and guided bone regeneration in patients with atrophic maxilla. *Journal of Oral and Maxillofacial Surgery: Official Journal of the American Association of Oral and Maxillofacial Surgeons*. 2017;75(4):709-22. doi: 10.1016/j.joms.2016.11.019. Epub Nov 26.
143. Sbordone C, Toti P, Guidetti F, Califano L, Bufo P, Sbordone L. Volume changes of autogenous bone after sinus lifting and grafting procedures: a 6-year computerized tomographic follow-up. *Journal of Cranio-Maxillo-Facial Surgery: Official Publication of the European Association for Cranio-Maxillo-Facial Surgery*. 2013;41(3):235-41.
144. Chadwick JW, Lam EW. The effects of slice thickness and interslice interval on reconstructed cone beam computed tomographic images. *Oral Surgery, Oral Medicine, Oral Pathology, Oral Radiology, and Endodontics*. 2010;110(4): e37-42.
145. Gibaud B. The quest for standards in medical imaging. *European Journal of Radiology*. 2011;78(2):190-8.
146. Spin-Neto R, Marcantonio E, Jr., Gotfredsen E, Wenzel A. Exploring CBCT-based DICOM files: a systematic review on the properties of images used to evaluate maxillofacial bone grafts. *Journal of Digital Imaging*. 2011;24(6):959-66.

147. Hartlev J, Spin-Neto R, Schou S, Isidor F, Norholt SE. Cone beam computed tomography evaluation of staged lateral ridge augmentation using platelet-rich fibrin or resorbable collagen membranes in a randomized controlled clinical trial. *Clinical Oral Implants Research*. 2019;30(3):277-84.
148. Mordenfeld A, Hallman M, Lindskog S. Tissue reactions to subperiosteal onlays of demineralized xenogenous dentin blocks in rats. *Dental Traumatology: Official Publication of the International Association for Dental Traumatology*. 2011;27(6):446-51.
149. Kim YJ, Saiki CET, Silva K, Massuda CKM, de Souza Faloni AP, Braz-Silva PH, et al. Bone Formation in Grafts with Bio-Oss and Autogenous Bone at Different Proportions in Rabbit Calvaria. *International Journal of Dentistry*. 2020;2020:2494128.
150. Gultekin BA, Cansiz E, Borahan MO. Clinical and 3-dimensional radiographic evaluation of autogenous iliac block bone grafting and guided bone regeneration in patients with atrophic maxilla. *Journal of Oral and Maxillofacial Surgery: Official Journal of the American Association of Oral and Maxillofacial Surgeons*. 2017;75(4):709-22.

APPENDIX: PAPER I-IV

- I. **H Aludden, A Mordenfeld, M Hallman, C Dahlin, T Jensen.** Lateral ridge augmentation with Bio-Oss alone or Bio-Oss mixed with particulate autogenous bone graft: a systematic review. *International Journal of Oral Maxillofacial Surgery*. 2017 Aug;46(8):1030-1038. doi: 10.1016/j.ijom.2017.03.008. Epub 2017 Mar 31.

- V. **H Aludden, A Dahlin, T Starch-Jensen, C Dahlin, A Mordenfeld.** Histomorphometric analyses of area fraction of different ratios of Bio-Oss® and bone prior to grafting procedures - An in vitro study to demonstrate a baseline. *Clin Oral Implants Res*. 2018 Feb;29(2):185-191. doi: 10.1111/clr.13079. Epub 2017 Oct 27. PMID: 29080268

- II. **H Aludden, A Mordenfeld, M Hallman, C Dahlin, T Starch-Jensen.** Histological and histomorphometrical outcome after lateral GBR augmentation of the mandible with different ratios of deproteinized bovine bone mineral and autogenous bone. A preclinical in vivo study. Accepted for publication in *Clinical Oral Implants Research*, August 2020.

- III. **H Aludden, A Mordenfeld, A Cederlund, C Dahlin, R Spin-Neto, P Veiss-Pedersen, B Sritharan, T Starch-Jensen.** Radiographic changes in height and volume after lateral GBR procedures with different ratios of deproteinized bovine bone mineral at different time points. An experimental study. *Clinical Oral Implants Research*, Submitted April 2020.

ISSN (online): 2246-1302
ISBN (online): 978-87-7210-688-5

AALBORG UNIVERSITY PRESS