

福島県立医科大学 学術機関リポジトリ



Title	Familial Mediterranean fever phenotype progression into anti-cyclic citrullinated peptide antibody-positive rheumatoid arthritis:a case report
Author(s)	Yago, Toru; Asano, Tomoyuki; Fujita, Yuya; Migita, Kiyoshi
Citation	Fukushima Journal of Medical Science. 66(3): 160-166
Issue Date	2020
URL	http://ir.fmu.ac.jp/dspace/handle/123456789/1360
Rights	© 2020 The Fukushima Society of Medical Science. This article is licensed under a Creative Commons [Attribution-NonCommercial-ShareAlike 4.0 International] license.
DOI	10.5387/fms.2020-07
Text Version	publisher

This document is downloaded at: 2021-11-05T05:20:22Z



Familial Mediterranean fever phenotype progression into anti-cyclic citrullinated peptide antibody-positive rheumatoid arthritis : a case report

Toru Yago, Tomoyuki Asano, Yuya Fujita and Kiyoshi Migita

Department of Rheumatology, Fukushima Medical University School of Medicine

(Received March 13, 2020, accepted October 14, 2020)

Abstract

Familial Mediterranean fever (FMF) is caused by dysfunction of the *MEFV* gene product, pyrin. Here we report a case of FMF phenotype which developed into rheumatoid arthritis (RA), based on a positive result for anti-cyclic citrullinated peptide (CCP) antibody (Ab). A 42-year-old woman presented to our clinic with more than 6 months of intermittent arthralgia in the wrists, feet, and fingers associated with menstruation. No fever was reported and there was no family history of FMF or other autoimmune diseases. Laboratory tests revealed elevated C-reactive protein (CRP) and rheumatoid factor (RF). Tests for autoantibodies including anti-CCP Ab, antinuclear Ab, and anti-DNA Ab were all negative. Genetic analysis identified an R304R homozygous mutation in *MEFV*; however, the pathological significance is unclear because this mutation does not cause amino acid substitution. We diagnosed incomplete FMF phenotype despite the lack of fever due to periodic arthritis, lack of autoantibodies, and complete resolution of arthritis following colchicine treatment within a day. Several months later, increased stiffness and arthralgia persistently occurred in finger joints on both sides. Ultrasonography revealed synovitis at the metacarpophalangeal and metatarsophalangeal joints. Laboratory analysis revealed the patient to be positive for anti-CCP Ab. Therefore, we finally diagnosed RA. Her arthritis diminished following administration of methotrexate and salazosulfapyridine. We consider the possibility that pyrin dysfunction may have affected the acquired immunity, contributing to the onset of RA as an autoimmune disease. This is an interesting case of equivalent FMF progressing into RA and will be valuable to raise awareness of a continuum from autoinflammatory to autoimmune disease.

Key words : Familial Mediterranean fever, Rheumatoid arthritis, Anti-CCP antibody, Autoinflammatory disease, Autoimmune disease

Introduction

Autoinflammatory diseases are characterized by systemic inflammation such as fever and rash, which differentiates them from autoimmune diseases such as rheumatoid arthritis (RA) or infections¹⁾. In terms of pathology, autoinflammatory diseases are caused by innate immunity while autoimmune diseases are caused by adaptive immunity, meaning that the two disorders are on opposite ends of a

disease spectrum even though they share many clinical characteristics. Familial Mediterranean fever (FMF) is the most common autoinflammatory disease, characterized by recurrent attacks of fever and polyserositis²⁾. Recently, pyrin — encoded by the *MEFV* gene — has been revealed to be directly involved in inflammasome activation and enhancement of interleukin (IL)-1 β production³⁾. Genetic and clinical differences have been reported between Japanese and non-Japanese patients with FMF,

Corresponding author : Toru Yago E-mail : toruyago@gmail.com

©2020 The Fukushima Society of Medical Science. This article is licensed under a Creative Commons [Attribution-NonCommercial-ShareAlike 4.0 International] license.

<https://creativecommons.org/licenses/by-nc-sa/4.0/>

indicating that a relationship exists between genotype and clinical phenotype⁴. It is common for FMF to co-exist with established rheumatic disease⁵; however, FMF phenotype in the context of RA is very rare. We report the case of a patient with identical FMF who presented with joint synovitis in whom anti-cyclic citrullinated peptide (CCP) antibody (Ab) began to be detected during the disease course, with eventual progression into RA.

Case report

A 42-year-old woman presented with swelling of the dorsum in the left foot and intermittent arthralgia in both hands lasting for 6 months with no fever. Her medical history included a malignant sweat gland tumor in the head when she was 30 years old. She had been previously diagnosed with iron deficiency anemia because of myoma uteri, for which she was taking iron supplements. No urinary tract infection or diarrhea had occurred before the onset of arthralgia. The joint swelling and arthralgia only occurred during menstruation. She was referred to our clinic for further examination with intermittent polyarthralgia. She had no family history suggestive of FMF or other autoimmune diseases including RA. Cardiovascular and respiratory examinations were unremarkable with no enlargement of the liver or spleen noted. However, physical examination revealed swelling and tenderness of the left foot as well as redness and tenderness in the metacarpophalangeal joint of the left thumb occurring only during menstruation. In addition, her arthritis was not a typical synovitis characterized as “fusiform swelling” that can be seen in RA, but rather, the swelling of an entire digit. No fever or oral ulcers were observed and blood tests showed normal hemoglobin levels and normal leukocyte and platelet counts. Laboratory tests revealed C-reactive protein and rheumatoid factor levels to be elevated (0.41 mg/dL and 64 IU/mL, respectively). Anti-CCP Ab, anti-nuclear Ab (ANA), anti-DNA Ab, anti-SS-A Ab, anti-aminoacyl tRNA synthetase Ab, myeloperoxidase (MPO)-anti-neutrophil cytoplasmic Ab (MPO-ANCA), and proteinase-3 (PR3)-ANCA were all negative. Immunoglobulin G (IgG), IgA, IgM, and IgD levels were normal and parvovirus B19-IgM was negative. Urinalysis showed no proteinuria or occult blood. Genetic analysis revealed a R304R homozygous mutation in the *MEFV* gene; however, the pathological significance is unclear because no amino acid substitution was identified. The patient did

not fulfill the EULAR/ACR 2010 criteria for classification of RA⁶ at that time. Following colchicine treatment (0.5 mg/day), the arthritis entirely disappeared within a day. Then, we applied international Tel-Hashmer criteria by Livneh *et al.*⁷ to the present case, matching two minor criteria, including arthritis and favorable response to colchicine. Therefore, despite the lack of fever, we diagnosed equivalent incomplete FMF phenotype, based on periodic arthritis, complete disappearance of arthritis within a day of initiating oral colchicine treatment, and lack of autoantibodies. Four months later, stiffness and arthralgia persistently developed in some joints despite colchicine treatment up to 1.5 mg/day, and each joint was also fusiform; therefore, we performed ultrasonographic examination which revealed synovitis including the second metacarpophalangeal joints of the right side and the first metatarsophalangeal joints of both sides (Figure 1). Because of the observation of typical synovitis, we assayed anti-CCP Ab again, which was positive at this time (titer 11.2 U/mL). Therefore, the diagnosis of RA emerging from FMF phenotype was made at that time because the symptoms fulfilled the EULAR/ACR 2010 criteria for classification of RA including anti-CCP Ab positivity⁶. Treatment with 5 mg/day prednisolone, methotrexate, and salazosulfapyridine was initiated, and arthritis improved within two months.

Discussion

The pathology of FMF is caused by dysregulation of inflammation due to abnormal function of the protein pyrin. Patients with FMF develop many clinical manifestations such as recurrent attacks of fever, periodic arthritis, and polyserositis. The most characteristic symptom is recurrent fever attacks of more than 38°C lasting several days. The condition usually affects pre-adolescent individuals⁸; however, a Japanese nationwide survey⁹ found the mean age at onset of clinical symptoms to be 19.6 ± 15.3 years in Japanese patients, with around one-third of patients (37.3%) experienced their first attack after they were 20 years old, indicating that Japanese patients with FMF develop their clinical manifestations later compared to non-Japanese cohorts. In the present case, the age of onset was 42 years, which is similar to that in Japanese patients with FMF. Migita *et al.* reported the incidence of fever, chest pain as a result of pleuritis, and arthritis in FMF among a mainly Japanese cohort to be 95.5%, 35%, and 31.3%, respectively¹⁰, which was

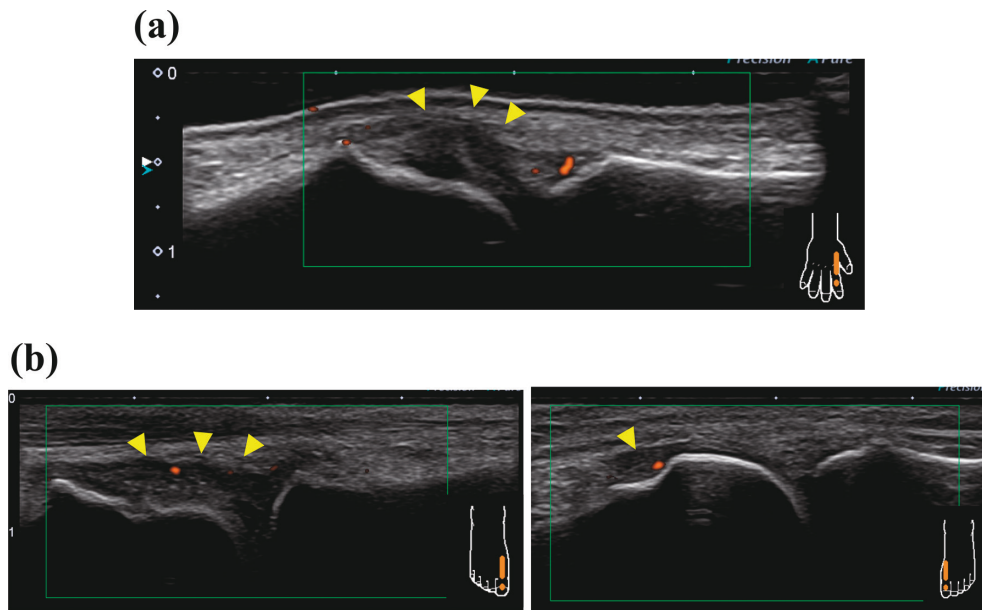


Figure 1. Ultrasound examination showed thickened synovium by Power Doppler, indicating synovitis.
 (a) Ultrasound image of the second metacarpophalangeal joints on the right side (arrowheads indicate synovial thickening).
 (b) Ultrasound image of the first metatarsophalangeal joints on both sides (arrowheads indicate synovial thickening).

comparable to reports from non-Japanese cohorts¹¹. It should be noted that about 5% of Japanese FMF patients are afebrile. In contrast, the prevalence of abdominal pain as a result of peritonitis and AA amyloidosis are higher in non-Japanese than Japanese patients with FMF. Arthritis is one of the common clinical features of FMF; therefore, the possibility of FMF should be considered in patients presenting with arthritis, especially in the absence of RF or anti-CCP Ab, regardless of ethnicity. However, the diagnostic criteria vary for different populations; the Japanese criteria are based upon modified Tel-Hashmer criteria, which are simplified from the diagnostic criteria proposed by Migita's group⁹, which include one major criterion (recurrent febrile episodes) and eight minor criteria (febrile attack with abdominal pain from peritonitis, chest pain from pleuritis, monoarthritis, pericarditis, scrotal pain from orchitis, headache from aseptic meningitis, or a favorable response to colchicine treatment). On the other hand, the Livneh's criteria⁷, also derived from Tel-Hashmer criteria, provide an established international diagnosis of FMF. Importantly, in contrast to the Japanese criteria, periodic fever is not required for diagnosis of FMF in Livneh's criteria. Livneh's criteria are based on for major criteria involving typical attacks (peritonitis, pleuritis or pericarditis, monoarthritis, and fever) and five minor criteria involving

incomplete attacks (abdomen, chest, joint, exertional leg pain, and favorable response to colchicine). If the patient fulfills two minor criteria, we can diagnose incomplete FMF even without periodic fever. Moreover, a diagnosis of FMF also should be concluded after exclusion of differential diagnoses such as infection, malignancy, or other autoinflammatory disease. It is highly important that a diagnosis of FMF be based on clinical manifestations, not solely genetic analysis, according to EULAR recommendations¹². Mindful that this case was afebrile, we diagnosed equivalent incomplete FMF by Livneh's criteria, since the patient had arthritis that rapidly resolved following colchicine treatment.

It remains unclear why the present case was afebrile during the disease course; however, FMF without fever has been described in several case reports¹³⁻¹⁵. It may be that dysfunction of cofactors such as microsomal prostaglandin E synthase-1 (mPGES-1), a terminal enzyme required for PGE₂ synthesis, may suppress fever as pro-inflammatory cytokines are necessary for febrile response. An *in vivo* study demonstrated that lipopolysaccharide (LPS)-stimulated febrile response is attenuated in chimeric mice when mPGES-1 expression is restricted to hematopoietic cells¹⁶. Thus, the synergistic actions of IL-1 β , IL-6, and mPGES1 in non-hematopoietic cells regulate the LPS-induced febrile response. In our case,

insufficient expression of mPGES-1 in non-hematopoietic cells may have resulted in the afebrile presentation; however, further investigation is required to elucidate the exact mechanisms underlying the lack of fever in FMF.

The present case experienced recurrent arthritis but joint swelling and pain was completely absent when she was not menstruating. This phenomenon is an important indicator of FMF, because menstruation is known to be a trigger for clinical attacks of FMF¹⁷. Therefore, in cases such as ours, the patient's arthralgia can be characterized as FMF-related arthropathy.

This case had a homozygous mutation of *MEFV* (R304R), which does not cause amino acid substitution. The *MEFV* gene is responsible for FMF¹⁸ and more than 300 sequence variants have been identified¹⁹; of the 14 reported in 2012, nine are pathogenic and five have unknown significance²⁰. It has been reported that 86.5% of Japanese patients with FMF have one or more *MEFV* mutations or polymorphisms, the most frequent being M694I/E148Q (19.8%)¹⁰. However, about 15% of Japanese FMF patients have no *MEFV* mutations. On the other hand, the frequency of the *MEFV* mutations in RA has been reported by Migita's group²¹. They demonstrated that allele frequencies of R408Q, P369S, E148Q, L110P mutations account respectively for 5.6%, 6.7%, 24.2%, 9.5% in RA patients and that the overall mutation rate was comparable between RA and healthy controls, indicating that *MEFV* mutations are not rare in RA. Their findings also suggest that *MEFV* mutations could not be a genetic factor affecting the susceptibility to RA. In addition, most importantly, recommendations allow a diagnosis of FMF even without *MEFV* mutations¹². Based on these factors, it is possible to diagnose our case as FMF phenotype.

Migita *et al.* reported that, among 192 Japanese patients with FMF, 26 (13.5%) experienced accompanying rheumatic diseases⁵. While the coexistence of autoinflammatory and autoimmune diseases is not rare²², reports of coexisting FMF and RA are relatively rare²³, with anti-CCP Ab-positive RA being particularly rare. Monoarthritis associated with FMF usually occurs in large joints such as the knee or hip and protracted arthritis is rare²⁴, in contrast with early RA where polyarthritis frequently develops in the hand or ankle. On the other hand, Endo *et al.* reported that late-onset FMF patients with onset ≥ 40 years present significantly more frequently with arthritis and myalgia compared to those with onset < 40 years²⁵. The present case

is also late-onset FMF phenotype, therefore occurring predominantly with arthritis, consistent with Endo's report.

Our case exhibited symmetrical arthritis of the finger and ankle that resolved with colchicine treatment in early phase, with ultrasonographic evidence of synovitis in the joint, which is an important indicator of early RA²⁶ in late phase. However, the present case did not fulfill the EULAR/ACR 2010 classification criteria for early RA without anti-CCP Ab positivity in early phase. When the present case developed arthritis just intermittently, each joint exhibited swelling of an entire digit, which made it hard precisely localize synovitis. EULAR/ACR 2010 criteria⁶ refer to target patients who have at least 1 joint with "definitive clinical synovitis". Therefore, the present case was not classifiable as having RA with a score $< 6/10$ (namely, presence of high titers of RF, and elevated levels of CRP). There are very few reports investigating the association FMF with RF positivity. Guler *et al.*²⁷ showed that the proportion of RF-positive FMF was 4% although the number of patients was small. They also demonstrated that RF positivity was not different between FMF and healthy controls.

The anti-CCP Ab is a highly specific biomarker for RA ($> 95\%$ specificity) that indicates a high risk of progressive joint destruction²⁸. A case complicated by anti-CCP Ab-positive RA and FMF has been reported by Migita *et al.*²³. In their case, arthritis refractory to conventional synthetic disease-modifying antirheumatic drugs (csDMARDs) was completely improved by using colchicine. The relationship between FMF and anti-CCP Ab is controversial. One study reported a relationship between FMF and anti-CCP Ab²⁹, while another study reported no such relationship³⁰. Importantly, Karatay's report demonstrated that anti-CCP Ab was negative in all FMF patients³⁰. However, arthritis caused by FMF may disappear with colchicine treatment. In our case, arthritis in early phase was temporarily resolved by colchicine. In contrast, arthritis was refractory to colchicine after anti-CCP Ab was detected, and csDMARDs such as MTX were effective. Moreover, each joint swelling became "fusiform," which is typical for RA synovitis. Therefore, we diagnosed RA when anti-CCP Ab positivity was observed. This change in antibody status presents an interesting case where RA developed and overlapped with equivalent FMF; recently, "autoinflammatory-autoimmune continuum" has been reported as a new disease spectrum³¹. Autoinflammatory diseases are systemic

disorders caused by dysregulations of innate immunity³², whereas autoimmune disorders are caused by dysregulation of adaptive immunity. However, symptoms of systemic juvenile idiopathic arthritis often include fever and polyarthritis, and genome-wide analysis has demonstrated that autoimmune arthritis can develop from a predominantly autoinflammatory disease phenotype³³. Furthermore, patients with haploinsufficiency of A20 (HA20), caused by heterozygous germline mutations in the *TNFAIP3* gene, present with clinical manifestations of autoinflammatory diseases such as Behçet disease, often coexisting with various autoimmune disorders³⁴. Innate immunity is accelerated in RA³⁵; for example, activation of the NLRP3 inflammasome, a major component of autoinflammatory pathogenesis, reportedly contributes to autoinflammatory diseases³⁶ as well as autoimmune diseases including RA³⁷.

The mechanism underlying the development of RA in the present case is unclear; one possible explanation is involvement of the “pyrin inflammasome,” which is a recently proposed concept suggesting that pyrin directly enhances inflammation^{3,38,39} following inactivation of Rho GTPases by bacterial toxins and other effectors, leading to dephosphorylation of pyrin. As a result, the 14-3-3 protein disassociates from pre-active pyrin resulting in pyrin activation. The inflammasome is then activated through polymerization of activated pyrin and apoptosis-associated speck-like protein containing a CARD (ASC). Finally, the pyrin inflammasome induces IL-1 β production and inflammation. Thus, pyrin may function as a sensor of inactivation of Rho GTPases induced by pathogens like intestinal flora.

Patients with FMF could be more sensitive to dysbiosis (disturbance of intestinal bacterial flora and loss of protection from various pathogens), provoking systemic innate or adaptive immunity involving intestinal epithelial cells and other immune cells⁴⁰. Indeed, dysbiosis has been detected in patients with RA⁴¹, as dysbiosis can lead to post-translational modification of autoantibodies and subsequent development of RA^{42,43}. Thus, dysbiosis of gut bacteria could drive adaptive immunity and autoimmunity leading to RA and innate immunity leading to FMF.

We encountered a rare case of equivalent FMF which developed to RA, providing an interesting “hybrid” phenotype which cannot be classified as a purely autoinflammatory or autoimmune disease. Furthermore, our findings suggest that therapy for

RA should be decided according to the conditions which induce the progression to autoinflammatory or autoimmune disease, especially when biological agents are considered. For example, the IL-6 inhibitor tocilizumab has been reported to be beneficial for colchicine-resistant FMF as well as RA among Japanese patients⁴⁴. The present case adds valuable information to current knowledge relating to pathophysiological categorization of autoinflammatory and autoimmune disorders.

References

1. Doria A, Zen M, Bettio S, *et al.* Autoinflammation and autoimmunity: bridging the divide. *Autoimmun Rev*, **12**: 22-30, 2012.
2. Padeh S, Berkun Y. Familial Mediterranean fever. *Curr Opin Rheumatol*, **28**: 523-529, 2016.
3. Jamilloux Y, Magnotti F, Belot A, Henry T. The pyrin inflammasome: from sensing RhoA GTPases-inhibiting toxins to triggering autoinflammatory syndromes. *Pathog Dis*, **76**: doi: 10.1093/femspd/fty020, 2018.
4. Migita K, Agematsu K, Yazaki M, *et al.* Familial Mediterranean fever: genotype-phenotype correlations in Japanese patients. *Medicine (Baltimore)*, **93**: 158-164, 2014.
5. Migita K, Izumi Y, Jiuchi Y, *et al.* Familial Mediterranean fever is no longer a rare disease in Japan. *Arthritis Res Ther*, **18**: 175, 2016.
6. Aletaha D, Neogi T, Silman AJ, *et al.* 2010 Rheumatoid arthritis classification criteria: an American College of Rheumatology/European League Against Rheumatism collaborative initiative. *Arthritis Rheum*, **62**: 2569-2581, 2010.
7. Livneh A, Langevitz P, Zemer D, *et al.* Criteria for the diagnosis of familial Mediterranean fever. *Arthritis Rheum*, **40**: 1879-1885, 1997.
8. El-Shanti H, Majeed HA, El-Khateeb M. Familial Mediterranean fever in Arabs. *Lancet*, **367**: 1016-1024, 2006.
9. Migita K, Uehara R, Nakamura Y, *et al.* Familial Mediterranean fever in Japan. *Medicine (Baltimore)*, **91**: 337-343, 2012.
10. Migita K, Asano T, Sato S, Koga T, Fujita Y, Kawakami A. Familial Mediterranean fever: overview of pathogenesis, clinical features and management. *Immunol Medicine*, **41**: 55-61, 2018.
11. Tunca M, Akar S, Onen F, *et al.* Familial Mediterranean fever (FMF) in Turkey: results of a nationwide multicenter study. *Medicine*, **84**: 1-11, 2005.
12. Giancane G, Ter Haar NM, Wulffraat N, *et al.*

- Evidence-based recommendations for genetic diagnosis of familial Mediterranean fever. *Ann Rheum Dis*, **74** : 635-641, 2015.
13. Hotta Y, Kawasaki T, Kotani T, *et al.* Familial Mediterranean Fever Without Fever. *Intern Med*, **59** : 1267-1270, 2020.
 14. Iwata K, Toma T, Yachie A. 38-year-old woman with recurrent abdominal pain, but no fever. *Int J Gen Med*, **5** : 265-268, 2012.
 15. Mattiassich G, Semlitsch G, Nadler K, Rainer F. Familial Mediterranean fever without fever as a cause of monoarthritis. *BMJ Case Rep*, **4** : bcr2012008395, 2013.
 16. Blomqvist A, Engblom D. Neural Mechanisms of Inflammation-Induced Fever. *Neuroscientist*, **24** : 381-399, 2018.
 17. Karadag O, Tufan A, Yazisiz V, *et al.* The factors considered as trigger for the attacks in patients with familial Mediterranean fever. *Rheumatol Int*, **33** : 893-897, 2013.
 18. French FMF Consortium. A candidate gene for familial Mediterranean fever. *Nat Genet*, **17** : 25-31, 1997.
 19. Touitou I. The spectrum of Familial Mediterranean Fever (FMF) mutations. *Eur J Hum Genet*, **9** : 473-483, 2001.
 20. Shinar Y, Obici L, Aksentijevich I, *et al.* Guidelines for the genetic diagnosis of hereditary recurrent fevers. *Ann Rheum Dis*, **71** : 1599-1605, 2012.
 21. Migita K, Nakamura T, Maeda Y, *et al.* MEFV mutations in Japanese rheumatoid arthritis patients. *Clin Exp Rheumatol*, **26** : 1091-1094, 2008.
 22. Fujita Y, Asano T, Sato S, *et al.* Coexistence of mixed connective tissue disease and familial Mediterranean fever in a Japanese patient. *Intern Med*, **58** : 2235-2240, 2019.
 23. Migita K, Abiru S, Sasaki O, *et al.* Coexistence of familial Mediterranean fever and rheumatoid arthritis. *Mod Rheumatol*, **24** : 212-216, 2014.
 24. Uthman I, Hajj-Ali RA, Arayssi T, Masri AF, Nasr F. Arthritis in familial Mediterranean fever. *Rheumatol Int*, **20** : 145-148, 2001.
 25. Endo Y, Koga T, Ishida M, *et al.* Musculoskeletal manifestations occur predominantly in patients with later-onset familial Mediterranean fever : Data from a multicenter, prospective national cohort study in Japan. *Arthritis Res Ther*, **20** : 257, 2018.
 26. Nam JL, D'Agostino MA. Role of ultrasound imaging in individuals at risk of RA. *Best Pract Res Clin Rheumatol*, **31** : 71-79, 2017.
 27. Guler E, Kaptanoglu E, Sahin O, Candan F, Hayta E, Elden H. Autoantibodies are not associated with familial mediterranean fever. *Acta Reumatol Port*, **37** : 144-148, 2012.
 28. Ohmura K, Terao C, Maruya E, *et al.* Anti-citrullinated peptide antibody-negative RA is a genetically distinct subset : a definitive study using only bone-erosive ACPA-negative rheumatoid arthritis. *Rheumatology (Oxford)*, **49** : 2298-2304, 2010.
 29. Uyanik A, Albayrak F, Uyanik MH, Dursun H, Keles M, Cetinkaya R. Antibodies directed to cyclic citrullinated peptides in familial Mediterranean fever. *Rheumatol Int*, **30** : 467-471, 2010.
 30. Karatay S, Yildirim K, Erdal A, Uzkeser H, Erdem FH, Yanmaz V. Anti-cyclic citrullinated peptide antibodies are not associated with familial Mediterranean fever. *J Back Musculoskelet Rehabil*, **23** : 21-23, 2010.
 31. Hedrich CM. Shaping the spectrum - From autoinflammation to autoimmunity. *Clin Immunol*, **165** : 21-28, 2016.
 32. Henderson C, Goldbach-Mansky R. Monogenic autoinflammatory diseases : new insights into clinical aspects and pathogenesis. *Curr Opin Rheumatol*, **22** : 567-578, 2010.
 33. Ombrello MJ, Remmers EF, Tachmazidou I, *et al.* HLA-DRB1*11 and variants of the MHC class II locus are strong risk factors for systemic juvenile idiopathic arthritis. *Proc Natl Acad Sci U S A*, **112** : 15970-15975, 2015.
 34. Kadowaki T, Ohnishi H, Kawamoto N, *et al.* Haploinsufficiency of A20 causes autoinflammatory and autoimmune disorders. *J Allergy Clin Immunol*, **141** : 1485-1488, 2018.
 35. Croia C, Bursi R, Suter D, Petrelli F, Alunno A, Puxeddu I. One year in review 2019 : pathogenesis of rheumatoid arthritis. *Clin Exp Rheumatol*, **37** : 347-357, 2019.
 36. de Torre-Minguela C, Mesa Del Castillo P, Pelegrín P. The NLRP3 and Pyrin Inflammasomes : Implications in the pathophysiology of autoinflammatory diseases. *Front Immunol*, **8** : 43, 2017.
 37. So A, Ives A, Joosten LA, Busso N. Targeting inflammasomes in rheumatic diseases. *Nat Rev Rheumatol*, **9** : 391-399, 2013.
 38. Xu H, Yang J, Gao W, *et al.* Innate immune sensing of bacterial modifications of Rho GTPases by the Pyrin inflammasome. *Nature*, **513** : 237-241, 2014.
 39. Gao W, Yang J, Liu W, Wang Y, Shao F. Site-specific phosphorylation and microtubule dynamics control Pyrin inflammasome activation. *Proc Natl Acad Sci U S A*, **113** : E4857-E4866, 2016.
 40. Rescigno M. Intestinal microbiota and its effects on the immune system. *Cell Microbiol*, **16** : 1004-1013, 2014.
 41. Scher JU, Sczesnak A, Longman RS, *et al.* Expansion of intestinal *Prevotella copri* correlates with enhanced susceptibility to arthritis. *Elife*, **2** : e01202, 2013.

42. Kalinkovich A, Gabdulina G, Livshits G. Autoimmunity, inflammation, and dysbiosis mutually govern the transition from the preclinical to the clinical stage of rheumatoid arthritis. *Immunol Res*, **66** : 696-709, 2018.
43. Bodkhe R, Balakrishnan B, Taneja V. The role of microbiome in rheumatoid arthritis treatment. *Ther Adv Musculoskelet Dis*, **11** : 1759720X19844632, 2019.
44. Koga T, Migita K, Kawakami A. Biologic therapy in familial Mediterranean fever. *Mod Rheumatol*, **26** : 637-641, 2016.