



1-2021

Laparoscopic Partial Splenectomy for a Splenic Hamartoma

Vashisht Madabhushi

University of Kentucky, vvma222@uky.edu

Timothy Horrell

University of Kentucky

John M. Draus

University of Kentucky, john.draus@uky.edu

Follow this and additional works at: https://uknowledge.uky.edu/surgery_facpub



Part of the [Surgery Commons](#)

[Right click to open a feedback form in a new tab to let us know how this document benefits you.](#)

Repository Citation

Madabhushi, Vashisht; Horrell, Timothy; and Draus, John M., "Laparoscopic Partial Splenectomy for a Splenic Hamartoma" (2021). *Surgery Faculty Publications*. 41.

https://uknowledge.uky.edu/surgery_facpub/41

This Article is brought to you for free and open access by the Surgery at UKnowledge. It has been accepted for inclusion in Surgery Faculty Publications by an authorized administrator of UKnowledge. For more information, please contact UKnowledge@lsv.uky.edu.

Laparoscopic Partial Splenectomy for a Splenic Hamartoma

Digital Object Identifier (DOI)

<https://doi.org/10.1016/j.epsc.2020.101737>

Notes/Citation Information

Published in *Journal of Pediatric Surgery Case Reports*, v. 64, 101737.

© 2020 Published by Elsevier Inc.

This is an open access article under the CC BY-NC-ND license (<https://creativecommons.org/licenses/by-nc-nd/4.0/>).



Laparoscopic partial splenectomy for a splenic hamartoma

Vashisht Madabhushi^a, Timothy Horrell^a, John M. Draus Jr.^{b,*}

^a Department of Surgery, General Surgery Residency Program, University of Kentucky, Lexington, KY, USA

^b Division of Pediatric Surgery, University of Kentucky, Lexington, KY, USA

ARTICLE INFO

Keywords:

Splenic hamartoma
Laparoscopic
Splenectomy
Splenic hemangioma

ABSTRACT

Objective: We discuss current knowledge and management of splenic hamartoma, an uncommon form of benign tumor.

Summary background data: A splenic hamartoma is a rare form of benign splenic mass, often found incidentally while working up other complaints, and is typically treated by surgical resection of the mass. In this case, we discuss the management of an incidentally found splenic hamartoma that was treated with laparoscopic partial splenectomy.

Methods: The patient presented in the Emergency Department complaining of periumbilical pain after having been struck in the abdomen with a soccer ball the previous day. Following a physical exam and blood work, an ultrasound was performed that revealed a hypoechoic area within the spleen. The patient received a diagnosis of gastroenteritis and an appointment for follow-up at 2 months. At 2-month follow-up, an ultrasound indicated that the mass had grown. The mass appeared consistent with a splenic hemangioma, so the patient was scheduled for laparoscopic partial splenectomy.

Results: The mass was completely resected without any complications. The patient had an uncomplicated postoperative course.

Conclusions: When there are no other indications for a total splenectomy and malignancy is unlikely, laparoscopic partial splenectomy appears to be a reasonable treatment modality for a splenic hamartoma.

1. Introduction

First described by Rokitsky in 1861 [1], splenic hamartomas are rare benign tumors of the spleen. Typically, these hamartomas are asymptomatic and found incidentally on imaging or autopsy. Even on autopsy, they are infrequently seen, with an incidence of 0.024%–0.13% [2]. They occur equally in men and women and grow to a significant size causing mass effect, but on average at about 5.1 cm. The pathogenesis of splenic hamartomas is controversial. Some consider them to be congenital, whereas others consider splenic hamartomas to be a neoplastic process or a post-traumatic lesion [3,4]. Hamartomas are typically well-circumscribed, solid lesions, and can cause a mass effect on neighboring structures.

1.1. Case summary

A 7-year 10-month-old boy presented to our emergency department (ED) with complaints of abdominal pain and fevers. The prior day, he

was struck in the abdomen with a soccer ball and started complaining of periumbilical pain. Shortly after, he had an episode of clear emesis and two episodes of non-bloody diarrhea. His mother brought him to the ED. On presentation, his vitals were normal except for an elevated heart rate at 112 bpm. On physical exam, his abdomen was found to be soft, with moderate tenderness in the periumbilical region and right lower quadrants, without any peritonitis or obvious hepatosplenomegaly. His labs showed a leukocytosis, with an elevated erythrocyte sedimentation rate, an elevated C-reactive protein, and normal lactate. An ultrasound of his abdomen was performed, which showed a 4.7 × 5.2 × 4.9 cm hypoechoic area within the superior pole of the spleen (Fig. 1). He was found to have gastroenteritis, treated conservatively, and required follow-up in the pediatric surgery clinic for his splenic mass. The mass appeared consistent with a splenic hemangioma, so the patient was scheduled for laparoscopic partial splenectomy.

A repeat ultrasound obtained 2 months later showed growth of the mass. The mass was still hypoechoic, with areas of increased echogenic-

* Corresponding author. MD Professor of Surgery and Pediatrics Division Chief, Pediatric Surgery University of Kentucky - Chandler Medical Center, 800 Rose Street, MS-463 Lexington, Kentucky, 40536-0298, USA.

E-mail address: john.draus@uky.edu (J.M. Draus).

<https://doi.org/10.1016/j.epsc.2020.101737>

Received 22 October 2020; Received in revised form 22 November 2020; Accepted 25 November 2020

Available online 30 November 2020

2213-5766/© 2020 Published by Elsevier Inc. This is an open access article under the CC BY-NC-ND license (<http://creativecommons.org/licenses/by-nc-nd/4.0/>).

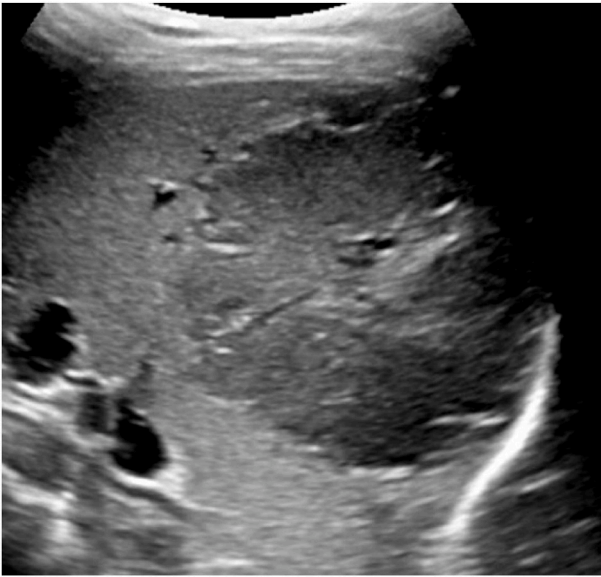


Fig. 1. Mass as seen on ultrasound.

ity in the center of the mass. Furthermore, there was increased blood flow into the lesion noted on Doppler imaging. Concerned about a splenic hemangioma, an MRI was obtained to better characterize the mass. The MRI showed the mass to be $5.1 \times 5.7 \times 4.8$ cm in size, heterogeneous in appearance, and located in the superoposterior aspect of the spleen (Fig. 2).

There was also a central scar noted, which is associated with hemangiomas. Additionally, there was noted to be a slight mass effect on the right kidney. The mass appeared consistent with a splenic hemangioma, so the patient was scheduled for laparoscopic partial splenectomy. First, the upper pole of the spleen was dissected free of the left lobe of the liver and the stomach using a LigaSure™ energy device (Covidian, Medtronic; Minneapolis, MN). Then, the splenic hilar vessels leading to the upper pole and the splenophrenic attachments were divided. The ischemic upper half of the spleen was well demarcated and was resected with an energy device (Fig. 3). EVICEL® Fibrin Sealant (Ethicon, Johnson & Johnson; Cincinnati, OH) hemostatic agent and Surgicel® (Ethicon, Johnson & Johnson; Cincinnati, OH) were used to

ensure continued hemostasis. His postoperative course was uncomplicated, and he is currently doing well. The pathology was found to be a benign splenic hamartoma.

2. Discussion

Radiologically, splenic hamartomas can be challenging to diagnose [5]. On ultrasound, they typically appear round, homogenous, with smooth, well-defined borders. The majority of them are hyperechoic but can be hypoechoic [6,7]. On a non-enhanced CT, they typically appear isodense compared to the splenic parenchyma. Calcifications, cystic changes, and fat can also be seen [6,7]. Splenic hamartomas appear isointense on T1-weighted images and hyperintense heterogeneously on T2-weighted images on an MRI. The signal intensity of splenic hamartomas on T2-weighted imaging is typically not as high as seen with hemangiomas [6].

As in this case, it is often challenging to definitively identify the lesion without histopathological identification and to positively differentiate a splenic hemangioma versus a splenic hamartoma on imaging alone. Histologically, splenic hamartomas contain disorganized vascular channels that are lined by endothelial cells without any atypia. This is mixed with red-pulp like stroma with or without white pulp [3,4,8]. Given the risk of rupture associated with splenic hemangiomas, resection is the treatment of choice for these lesions [9]. There have been several approaches to resection. Until 1990, an open total splenectomy was the standard of treatment for splenic hamartomas. However, in 1990, Havlik described the first-ever open partial splenectomy for a splenic hamartoma [10]. Partial splenectomies are particularly important in children. By performing a total splenectomy, patients are at increased risk for overwhelming post-splenectomy infection (OPSI). Splenectomy, especially at a young age, is known to be associated with severe and sometimes fatal sepsis. By performing a partial splenectomy and maintaining the immunologic function of the spleen, OPSI can be avoided [11].

Since the advent of laparoscopy, there has been a gradual transition to laparoscopic splenectomies for hamartomas. Laparoscopic total splenectomies have been described in the literature for several types of splenic lesions. However, to our knowledge, this is the first time that laparoscopic partial splenectomy of a hamartoma has been described in the literature. Laparoscopic partial splenectomy has been extensively described in the literature for other conditions, such as hereditary spherocytosis.

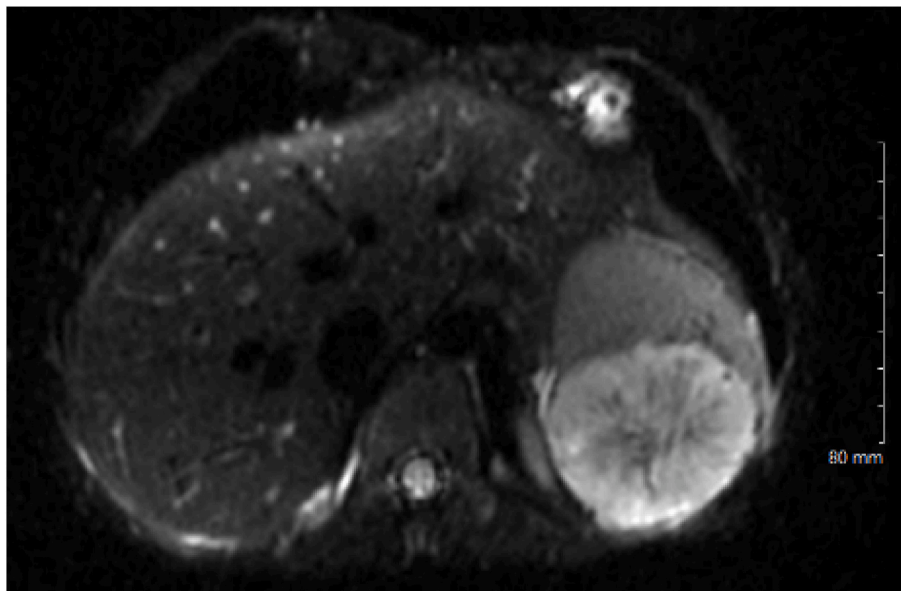


Fig. 2. Hamartoma on MRI.

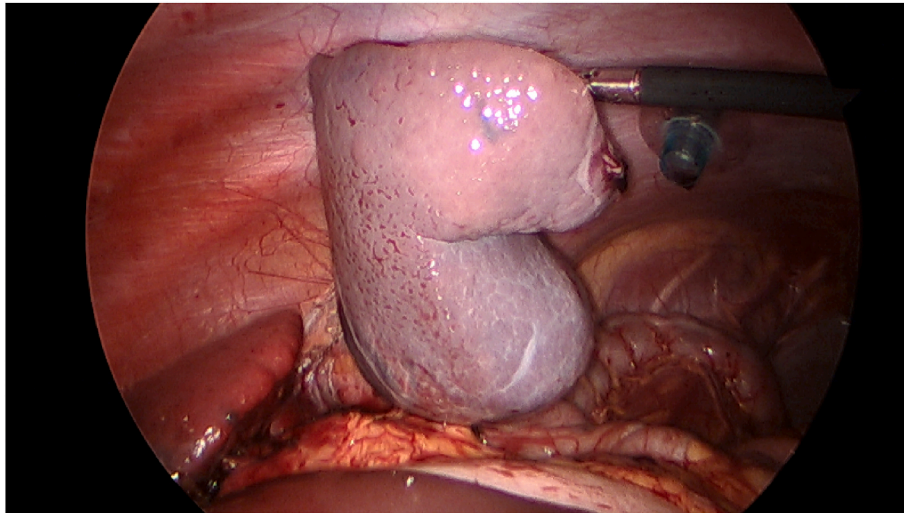


Fig. 3. Intraoperative hamartoma.

rocytosis, and had been described as a safe alternative to laparoscopic total splenectomy [12–14].

3. Conclusion

Splenic hamartomas are rare tumors of the spleen but are often challenging to positively identify on imaging alone. We have described a patient who had a novel treatment for it. We have also discussed the current literature regarding the epidemiology, etiology, diagnosis, and treatment options for this splenic lesion. When there are no other indications for total splenectomy and malignancy is unlikely, laparoscopic partial splenectomy appears to be a reasonable treatment modality for a splenic hamartoma.

Patient consent

Consent to publish the case report was not obtained. This report does not contain any personal information that could lead to the identification of the patient.

Funding

No funding or grant support.

Authorship

All authors attest that they meet the current ICMJE criteria for Authorship.

Declaration of competing interest

The authors declare that they have no known competing financial interests or personal relationships that could have appeared to influence the work reported in this paper.

References

- [1] Rokitsansky KF Two recent cases of spontaneous rupture of the spleen. *Wochenblatt der Zeitschrift der k Gesellschaft der Aerzte in Wien* 1861;17: 42–4.
- [2] Lam KY, Yip KH, Peh WC Splenic vascular lesions: unusual features and a review of the literature. *Aust N Z J Surg* 1999;69:422–5. <https://doi.org/10.1046/j.1440-1622.1999.01550.x>.
- [3] Abbott RM, Levy AD, Aguilar NS, et al. From the archives of the AFIP: primary vascular neoplasms of the spleen: radiologic-pathologic correlation. *Radiographics* 2004;24:1137–373. <https://doi.org/10.1148/rg.244045006>.
- [4] Lee H, Maeda K Hamartoma of the spleen. *Arch Pathol Lab Med* 2009;133: 147–51. <https://doi.org/10.1043/1543-2165-133.1.147>.
- [5] Dhyani M, Anupindi SA, Ayyala R, et al. Defining an imaging algorithm for noncystic splenic lesions identified in young patients. *AJR Am J Roentgenol* 2013;201:EW893-W899. <https://doi.org/10.2214/AJR.12.10105>.
- [6] Thipphavong S, Duigenan S, Schindera ST, et al. Nonneoplastic, benign, and malignant splenic diseases: cross sectional imaging findings and rare disease entities. *AJR Am J Roentgenol* 2014;202:315–22. <https://doi.org/10.2214/AJR.13.11777>.
- [7] Wang J-H, Ma X-L, Ren F-Y, et al. Multi-modality imaging findings of splenic hamartoma: a report of nine cases and review of the literature. *Abdom Imag* 2013;38:154–62. <https://doi.org/10.1007/s00261-012-9880-8>.
- [8] Hayes TC, Britton HA, Mewborne EB, et al. Symptomatic splenic hamartoma: case report and literature review. *Pediatrics* 1998;101:E10. <https://doi.org/10.1542/peds.101.5.e10>.
- [9] Giovagnoni A, Giorgi C, Goteri G, et al. Tumours of the spleen. *Canc Imag* 2005;5:73–7. <https://doi.org/10.1102/1470-7330.2005.0002>.
- [10] Havlik RJ, Touloukian RJ, Markowitz RI, et al. Partial splenectomy for symptomatic splenic hamartoma. *J Pediatr Surg* 1990;25:1273–5. [https://doi.org/10.1016/0022-3468\(90\)90529-i](https://doi.org/10.1016/0022-3468(90)90529-i).
- [11] Sheikh AK, Salih ZT, Kasnazan KH, et al. Prevention of overwhelming postsplenectomy infection in thalassemia patients by partial rather than total splenectomy. *Can J Surg* 2007;59:382–6 18031639.
- [12] Slater BJ Institutional experience with laparoscopic partial splenectomy for hereditary spherocytosis. *J Pediatr Surg* 2010;45:1682–6. <https://doi.org/10.1016/j.jpedsurg.2010.01.037>.
- [13] Uranues S, Grossman D, Ludwig L, Bergamaschi R Laparoscopic partial splenectomy. *Surg Endosc* 2007;21:57–60. <https://doi.org/10.1007/s00464-006-0124-2>.
- [14] Hery G, Becmeur F, Mefat L, et al. Laparoscopic partial splenectomy: indications and results of a multicenter retrospective study. *Surg Endosc* 2008;22:45–9. <https://doi.org/10.1007/s00464-007-9509-0>.