

University of Groningen

Recognizing differentiating clinical signs of CLN3 disease (Batten disease) at presentation

Kuper, Willemijn F. E.; Talsma, Herman E.; van Schooneveld, Mary J.; Pott, Jan Willem R.; Huijgen, Barbara C. H.; de Wit, Gerard C.; van Hasselt, Peter M.; van Genderen, Maria M.

Published in:
Acta ophthalmologica

DOI:
[10.1111/aos.14630](https://doi.org/10.1111/aos.14630)

IMPORTANT NOTE: You are advised to consult the publisher's version (publisher's PDF) if you wish to cite from it. Please check the document version below.

Document Version
Publisher's PDF, also known as Version of record

Publication date:
2020

[Link to publication in University of Groningen/UMCG research database](#)

Citation for published version (APA):

Kuper, W. F. E., Talsma, H. E., van Schooneveld, M. J., Pott, J. W. R., Huijgen, B. C. H., de Wit, G. C., van Hasselt, P. M., & van Genderen, M. M. (2020). Recognizing differentiating clinical signs of CLN3 disease (Batten disease) at presentation. *Acta ophthalmologica*, 1-8. <https://doi.org/10.1111/aos.14630>

Copyright


Other than for strictly personal use, it is not permitted to download or to forward/distribute the text or part of it without the consent of the author(s) and/or copyright holder(s), unless the work is under an open content license (like Creative Commons).

Take-down policy

If you believe that this document breaches copyright please contact us providing details, and we will remove access to the work immediately and investigate your claim.

Downloaded from the University of Groningen/UMCG research database (Pure): <http://www.rug.nl/research/portal>. For technical reasons the number of authors shown on this cover page is limited to 10 maximum.

Recognizing differentiating clinical signs of CLN3 disease (Batten disease) at presentation

Willemijn F. E. Kuper,¹  Herman E. Talsma,² Mary J. van Schooneveld,^{2,3} Jan Willem R. Pott,⁴ Barbara C. H. Huijgen,⁵ Gerard C. de Wit,² Peter M. van Hasselt¹ and Maria M. van Genderen^{2,6}

¹Department of Metabolic Diseases, Wilhelmina Children's Hospital, University Medical Center Utrecht, Utrecht University, Utrecht, The Netherlands

²Bartiméus Diagnostic Center for Complex Visual Disorders, Zeist, The Netherlands

³Department of Ophthalmology, Amsterdam University Medical Center, Amsterdam, The Netherlands

⁴Department of Ophthalmology, University Medical Center Groningen, University of Groningen, Groningen, The Netherlands

⁵Department of Psychology, University of Groningen, Groningen, The Netherlands

⁶Department of Ophthalmology, University Medical Center Utrecht, Utrecht University, Utrecht, The Netherlands

ABSTRACT.

Purpose: To help differentiate CLN3 (Batten) disease, a devastating childhood metabolic disorder, from the similarly presenting early-onset Stargardt disease (STGD1). Early clinical identification of children with CLN3 disease is essential for adequate referral, counselling and rehabilitation.

Methods: Medical chart review of 38 children who were referred to a specialized ophthalmological centre because of rapid vision loss. The patients were subsequently diagnosed with either CLN3 disease (18 patients) or early-onset STGD1 (20 patients).

Results: Both children who were later diagnosed with CLN3 disease, as children who were later diagnosed with early-onset STGD1, initially presented with visual acuity (VA) loss due to macular dystrophy at 5–10 years of age. VA in CLN3 disease decreased significantly faster than in STGD1 ($p = 0.01$). Colour vision was often already severely affected in CLN3 disease while unaffected or only mildly affected in STGD1. Optic disc pallor on fundoscopy and an abnormal nerve fibre layer on optical coherence tomography were common in CLN3 disease compared to generally unaffected in STGD1. In CLN3 disease, dark-adapted (DA) full-field electroretinogram (ERG) responses were either absent or electronegative. In early-onset STGD1, DA ERG responses were generally unaffected. None of the STGD1 patients had an electronegative ERG.

Conclusion: Already upon presentation at the ophthalmologist, the retina in CLN3 disease is more extensively and more severely affected compared to the retina in early-onset STGD1. This results in more rapid VA loss, severe colour vision abnormalities and abnormal DA ERG responses as the main differentiating early clinical features of CLN3 disease.

Key words: Batten disease – childhood retinal dystrophy – CLN3 disease – deep phenotyping – early recognition – early-onset STGD1

[†]These authors contributed equally to this work.

Acta Ophthalmol.

© 2020 The Authors. Acta Ophthalmologica published by John Wiley & Sons Ltd on behalf of Acta Ophthalmologica Scandinavica Foundation

This is an open access article under the terms of the Creative Commons Attribution-NonCommercial License, which permits use, distribution and reproduction in any medium, provided the original work is properly cited and is not used for commercial purposes.

doi: 10.1111/aos.14630

Introduction

The majority of children presenting with vision loss, who on ocular examination prove to have macular dystrophy, suffer from early-onset Stargardt disease (STGD1) (OMIM #248200), which is a retina-only disease (Lambertus et al. 2015). A significant minority, however, actually suffer from CLN3 disease (Batten disease) (OMIM #204200), which is a devastating metabolic disease impacting both retina and brain, generally limiting life expectancy to the early twenties (Mole & Cotman 2015). At disease onset, patients with CLN3 disease generally present with rapid loss of vision as their main or only complaint at the ophthalmologist (Bohra et al. 2000; Ouseph et al. 2016). Early distinction between CLN3 disease and early-onset STGD1 is essential to tailor counselling, minimizing both a diagnostic odyssey in those with CLN3 disease, and unnecessary concerns in those with early-onset STGD1. However, the initial close resemblance between these disorders complicates differentiation in ophthalmological practice.

In more frequent disorders, repeated exposure facilitates a pattern recognition process that allows clinicians to identify differentiating features that aid a correct and early diagnosis. The rareness of particularly CLN3 disease precludes this naturally occurring learning curve. We hypothesized that

recognition of a rare disorder could be improved by an in-depth analysis of all phenotypic abnormalities observed—also known as deep phenotyping—compared to an apparently similar, but more frequent, disorder to identify differentiating phenotypic abnormalities (Robinson 2012). By doing so, pattern recognition could be made available for rare disorders as well.

In this study, we aimed to delineate defining clinical characteristics of CLN3 disease as compared to early-onset STGD1 at presentation at the ophthalmologist. The differentiating characteristics identified in this study could aid ophthalmologists in the early recognition of CLN3 disease, minimizing a diagnostic odyssey.

Materials and Methods

Patients

We retrieved the medical records of those patients referred to Bartiméus for the ophthalmological assessment of their vision loss, who were at a later stage diagnosed with either CLN3 disease or early-onset STGD1 (Lambertus et al. 2015; Mole & Cotman 2015). Diagnosis was considered confirmed upon identification of either bi-allelic mutations in *ABCA4* (in the case of early-onset STGD1) or bi-allelic mutations in *CLN3* (in the case of CLN3 disease). Of note, in the case of CLN3 disease, genetic confirmation has only been possible since 1995 (International Batten Disease Consortium 1995). Therefore, for patients diagnosed before or around this time, we considered the presence of vacuolated lymphocytes—if found in an individual with retinal dystrophy, pathognomonic for CLN3 disease, sufficient proof (Anderson et al. 2005; Kuper et al. 2020).

Ophthalmological centre

Bartiméus is the national tertiary referral centre for rare ophthalmic diseases in children. Children suspected of an unusual ophthalmic disease in general practice are generally quickly referred to Bartiméus for an extensive ophthalmological assessment. Since this assessment occurs usually within two to four weeks after referral, we regarded this examination as ‘upon presentation’.

A waiver of requirement for ethical review was granted by The Medical

Ethical Research Committee of the University Medical Center Utrecht.

Data collection

From the clinical history, we retrieved the onset of vision loss and the presence of additional ophthalmological complaints (specifically night vision problems, photophobia) upon presentation. We regarded the moment at which the first signs of rapid vision loss were noticed as the time-point of onset ($T = 0$). If the onset was not reported, then the first rapid vision loss-related doctor visit was regarded as $T = 0$. From the validated clinical assessments, we retrieved visual acuity (VA), colour vision, and contrast sensitivity. To analyse vision loss over time, we included all VA measurements available prior to, around, and following the first ophthalmological assessment at Bartiméus. We retrieved the best corrected VA (BCVA) of both eyes (VODS) from each measurement. If the VA of the right eye (VOD) and the VA of the left eye (VOS) were described only separately, we used the BCVA in the better eye. Regarding colour vision, we included the severity of a colour vision deficiency if the Hardy Rand Rittler (HRR) test was included in the test battery. From ophthalmoscopy, we retrieved imaging [fundus photography, fundus autofluorescence (FAF), and optical coherence tomography (OCT)], and full-field electroretinography (ffERG). If available, we collected the original images and graphs in addition to the descriptive conclusion of these assessments. From the globally tested assessments, we retrieved peripheral visual field results (examined with confrontational techniques because of the young age of the patients).

Fundus photography and FAF were made using the Canon CX-1 camera. Optical coherence tomography (OCT) images were obtained with RT-Vue (Optovue, Fremont, CA, USA). Full-field ERG recordings were performed in accordance with the guidelines of the International Society for Clinical Electrophysiology of Vision (ISCEV) (McCulloch et al. 2015). To obtain the responses, Dawson–Trick–Litzkow (DTL) corneal electrodes were used. For flash stimulation, an Espion E3 System with ColorDome Stimulator (Diagnosys LLC, Cambridge, UK) was used. From the extended ISCEV

series measured at Bartiméus, we extracted the light adapted (LA), 3.0 and 30Hz flicker responses and the dark adapted (DA) 0.01 and 3.0 responses (Brouwer et al. 2019).

All ophthalmological examinations (with the exception of VA tests performed before $t = 0$) were performed at the same day at the Bartiméus institute.

Data analysis

Due to the retrospective nature of the study, VA was measured using different methods and thus reported in different units. To be able to analyse VA loss for all patients per diagnosis combined, we converted all VA measurements into decimals. We used multilevel modelling—that accounts for imbalanced repeated measurements—to assess the velocity of the vision loss per diagnosis (Snijders & Bosker 2012). We analysed the velocity of the vision loss during the complete follow-up (starting from $t = 0$) in general, as during the first year of follow-up specifically.

Of all analyses, except for the OCT analyses of the inner retina described below, blinding was not necessary since we retrieved and analysed the original descriptive conclusions of these assessments when the underlying diagnosis was not yet known. In addition to the original descriptive conclusions of the OCT scans, an additional retrospective analysis of the OCT scans was performed. Optical coherence tomography (OCT) scans were analysed by comparison of the MM6 scan capturing the foveal region (manually extracted from the 12 radial line scans by WK). The MM6 scan was used based on the recognition that the more commonly used line scans due to eccentric fixation often failed to capture the foveal region. Due to this technical limitation, a reliable quantitative analysis of the MM6 OCT scans was not possible. Alternatively, the OCT scans of $n = 9$ CLN3 disease patients and $n = 13$ early-onset STGD1 patients were subjected to a qualitative assessment of the inner retina/nerve fibre layer (NFL) by three experienced ophthalmologists (MvS, JWP, and MvG) who were blinded for the underlying diagnosis. All three assessors were asked to classify the NFL of each OCT scan as normal—doubtfully (ab)normal—or abnormal. This assessment was tabulated and qualitatively described.

Statistical analysis

For multilevel modelling, MLwiN version 3.0.1 was used to investigate longitudinal changes in VODS over time (Centre for Multilevel Modelling, University of Bristol, Bristol, UK). An advantage of multilevel modelling over the traditional repeated-measurement approach is that all of the available results can be incorporated within the analysis, even if the number of measurements varies between the patients because of missing data, assuming that the missing data are random. A 2-level multilevel structure was used; level 1 represented repeated measures within participants, level 2 represented differences among patients. The predictor ‘years since onset’ was entered into the model to find the best model fit. The model fit was evaluated by comparing the deviance (ln – 2 log-likelihood) of the empty model with the final model.

The differences in age at onset, VA at onset and vision loss velocity (as denominated by the multilevel equation) between CLN3 disease and early-onset STGD1 were calculated using the unpaired two-tailed t test in GRAPHPAD PRISM version 8.0.1 (GraphPad Prism, San Diego, CA, USA). p-Values below 0.05 were considered statistically significant.

Results

Between 1987 and 2019, a total of 38 patients were referred to a specialized ophthalmological centre because of rapid loss of vision, who were subsequently diagnosed with either CLN3 disease (*n* = 18) or early-onset STGD1 (*n* = 20) (Table S1 and S2).

Vision loss

Upon ophthalmological assessment, patients who were later diagnosed with CLN3 disease (from hereafter referred to as patients with CLN3 disease), reported a somewhat earlier onset of vision loss (mean age at onset of 6.4 years, range 5–8 years) than patients with early-onset STGD1 (mean age at onset of 7.5 years, range 5–10 years, *p* = 0.009). In addition, there was a trend towards a worse VA at CLN3 disease presentation (mean VODS of 0.2 (comparable to 6/30 in Snellen (m) ratios) in CLN3 disease compared to mean VODS of 0.3 (comparable to 6/19 in Snellen (m) ratios) in

STGD1, *p* = 0.12). However, given their clinically significant overlap, neither age at onset nor VODS at presentation allowed to differentiate between early-onset STGD1 or CLN3 disease. The subsequent course of vision loss, in contrast, did discriminate CLN3 disease from early-onset STGD1 (Fig. 1). Already within the first year after vision loss onset, VA decreased in CLN3 disease significantly faster (VODS_{1yr} = 0.267–0.259*part of the year since onset) than in early-onset STGD1 (VODS_{1yr} = 0.411–0.357*part of the year since onset) (*p* = 0.01).

Colour vision

Systematic assessment revealed that the severity of colour vision deficiency allowed to distinguish most patients with CLN3 disease from those with early-onset STGD1. Normal colour vision was only seen in patients with early-onset STGD1. Conversely, severely affected colour vision—most

pronounced in red-green (RG) colour vision but also in tritan colour vision—indicated that the patient was suffering from CLN3 disease (Fig. 2 and Table S1). Of note, in the only one (male) early-onset STGD1 patient exhibiting a severe RG colour vision deficiency, a highly ordered Farnsworth D15 pattern was found suggestive of a congenital deutan deficiency as relatively commonly occurring in males (Table S1) (Simunovic 2010).

Fundoscopy

Macular pigmentary changes were present in all CLN3 disease patients and the majority of early-onset STGD1 patients (*n* = 17/20), but the presence of optic disc pallor and attenuated vessels proved somewhat more discriminatory: their presence was observed in the majority (*n* = 12/17 and *n* = 15/17, respectively) of patients with CLN3 disease, being rare in patients with early-onset STGD1 (*n* = 2/20 and *n* = 2/19, respectively) (Fig. 3, Table S1). Of note, as in previous studies on the early-onset type of STGD1, typical STGD1 fundus abnormalities—that is irregular yellow-white posterior fundus flecks—were only rarely seen in our early-onset STGD1 cohort, underscoring the difficulty to distinguish CLN3 disease from early-onset STGD1 in this initial phase (Lambertus et al. 2015; Bax et al. 2019).

Optical coherence tomography

Patients with CLN3 disease and patients with early-onset STGD1 presented with macular atrophy on OCT. The optic disc pallor observed on funduscopy suggested a CLN3 disease-specific early involvement of the inner retina. To further explore this hypothesis, we used the OCT scans to assess the different retinal layers. As expected, the outer photoreceptor related layers were severely affected in both CLN3 disease and early-onset STGD1. When focusing on the inner retina, the NFL was indeed often regarded abnormal in CLN3 disease but regarded normal in early-onset STGD1 (Fig. 3; Table 1).

Electroretinogram

In all CLN3 disease patients who underwent visual electrophysiology

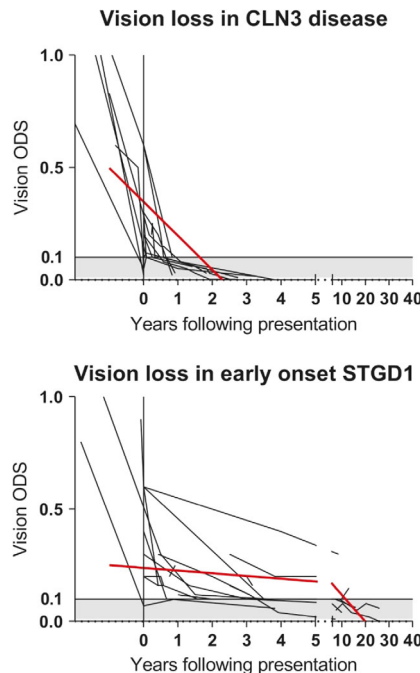
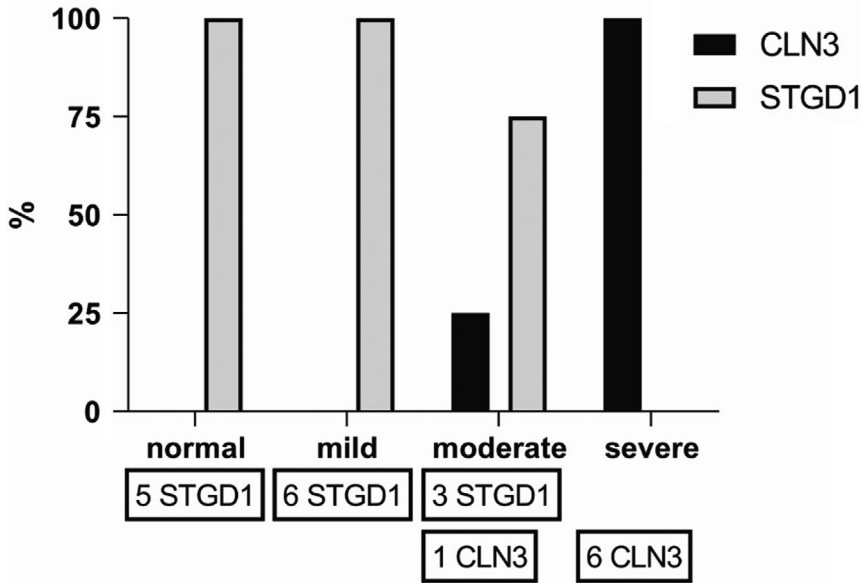


Fig. 1. Vision loss course in CLN3 disease and early-onset STGD1. Visual acuity measurements in CLN3 disease compared to early-onset Stargardt disease (STGD1). Velocity coefficient calculations confirm similar VODS around presentation but subsequently a significantly faster decrease of visual acuity in CLN3 disease (VODS_{overall} = 0.347–0.151*years since onset) compared to early-onset STGD1 (VODS_{overall} = 0.347–0.151*years since onset; *p* = 0.02) for the complete follow-up period as shown in figure). In both disease cohorts, VOD = VOS.

Severity of red-green color vision deficiency



Severity of tritan color vision deficiency

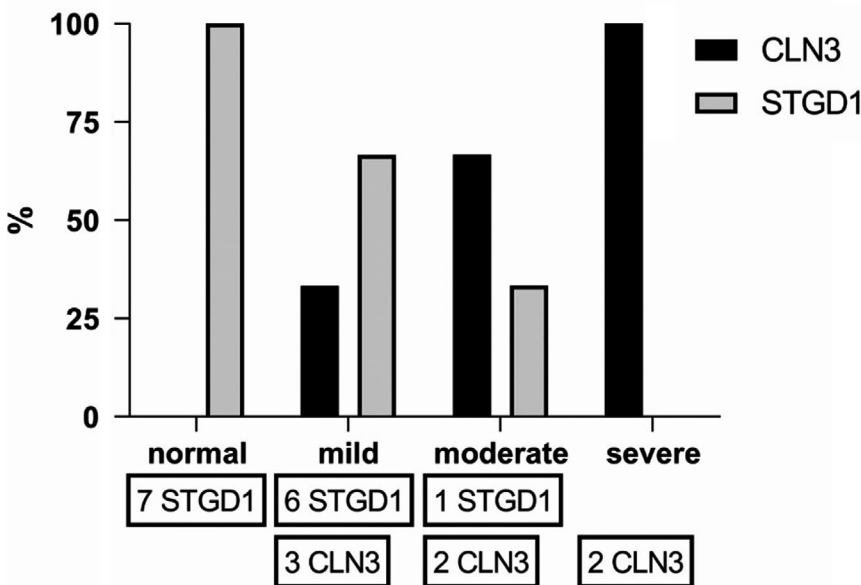


Fig. 2. Severity of colour vision deficiency around diagnosis in CLN3 disease and early-onset STGD1. Red-green and tritan colour vision deficiency in $n = 7$ CLN3 disease patients and $n = 14^*$ early-onset STGD1 patients tested with (at least) the HRR around diagnosis. *Excluded from this figure is one (male) early-onset STGD1 patient with a suspected co-occurring congenital colour vision deficiency (see also Table S1 and S2).

testing ($n = 13$), the DA ERG was described as markedly abnormal. In $n = 7$ CLN3 disease patients, we could retrieve the raw ERG responses to further zoom in on the different responses. In these, DA 0.01 responses were severely reduced or absent. The DA 3.0 bright flash responses showed a b-wave which was much smaller than the a-wave, also called an

electronegative ERG. In addition, the photoreceptor-driven a-wave was reduced in $n = 4/7$ patients. These results confirm that inner retinal dysfunction occurs (as represented in the b-wave) very early in CLN3 disease, in some patients preceding deterioration of the photoreceptors (as represented in the a-wave) (Audo et al. 2008). While the DA ERG was severely

reduced and electronegative in all CLN3 disease patients, the DA responses were unaffected ($n = 8/11$) or only mildly reduced ($n = 3/11$) in early-onset STGD1. None of the early-onset STGD1 patients had an electronegative bright flash ERG (Fig. 4 and Table S1).

Of note, in our analysis, the LA ERG did not always discriminate CLN3 disease from early-onset STGD1, as it was within normal limits not only in 6 STGD1 patients, but also in 1 CLN3 disease patient. Thus, the DA ERG was necessary to distinguish CLN3 disease and early-onset STGD1 without any doubt.

Multidimensional analysis of retinal involvement in CLN3 disease compared to early-onset STGD1

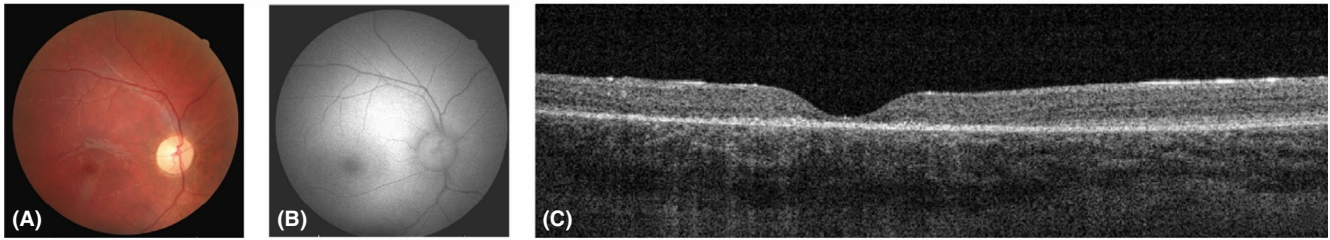
Based on the ophthalmological test results, CLN3 disease and early-onset STGD1 may seem very similar at presentation (Fig. 5A), but can actually be distinguished clearly both on the extensiveness of retina involvement—that is the different components affected—as on the degree to which the different components were affected (Fig. 5B).

Discussion

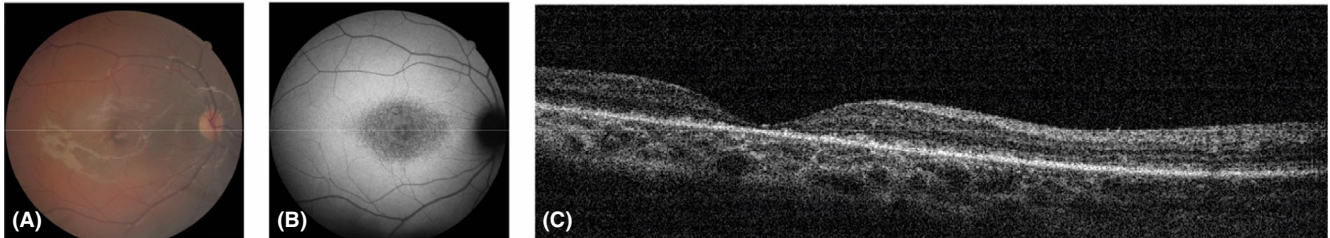
In this study, we explored whether we could aid the ophthalmologist to differentiate between a devastating metabolic disorder and a retina-only disease, despite their similar clinical presentation. To the best of our knowledge, we provide the most extensive overview of the ophthalmological characteristics early in CLN3 disease described so far. Previous reports on ocular abnormalities in CLN3 disease generally discussed either relatively old patients years after diagnosis or small patient numbers, without or with only few control patients with an isolated retinal disease (Eksandh et al. 2000; Hainsworth et al. 2009; Dulz et al. 2016; Hansen et al. 2016; Preising et al. 2017; Wright et al. 2019).

Rapid vision loss in a young child may be caused by a number of diseases, including optic neuropathies, intracerebral tumours, and retinal dystrophies. In the case of a child with CLN3 disease, however, an ophthalmologist will identify macular degeneration as the primary cause of vision loss,

CLN3 disease



Early-onset STGD1



Healthy individual

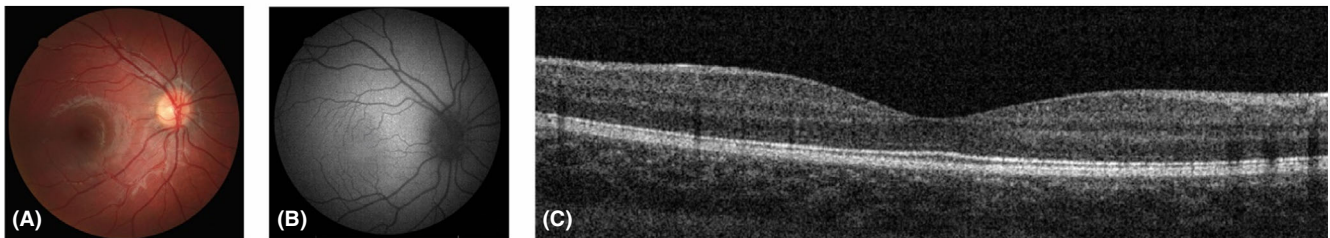


Fig. 3. Funduscopy, and optical coherence tomography (OCT) around diagnosis in CLN3 disease and early-onset STGD1. Representative funduscopy (A), fundus autofluorescence (FAF) (B) and OCT (C), from $n = 1$ CLN3 disease patient (CLN3-5) and $n = 1$ early-onset STGD1 patient (STGD1-18) (see Table S2) around presentation compared to $n = 1$ age-matched healthy control. Of note, due to eccentric fixation in both the CLN3 disease and early-onset STGD1 patients, line scans often did not capture the macula and while (one of the radial) MM6 image(s) did, often the retina was not centered so clearly as seen in the early-onset STGD1 patient.

Table 1. Qualitative assessment of the nerve fibre layer on optical coherence tomography (OCT) around diagnosis in CLN3 disease and early-onset STGD1.

NFL	Assessor 1	Assessor 2	Assessor 3
CLN3, $N = 9$			
Normal	3	4	
Doubt	3	1	7
Abnormal	3	4	2
STGD1, $N = 13$			
Normal	10	10	11
Doubt	2	1	
Abnormal	1	2	2

Qualitative assessment of the NFL performed by three independent assessors (experienced ophthalmologists) in $n = 9$ CLN3 disease and $n = 13$ early-onset STGD1 radial MM6 OCT scans made around diagnosis.

because of the abnormalities seen on funduscopy and OCT. Since our study focuses specifically on patients with macular degeneration presenting around the age of 6 years, early-onset STGD1 is the main disorder in the

differential diagnosis of CLN3 disease (or the other way around).

Using a deep phenotyping approach, we unveiled that compared to early-onset STGD1, already in this early stage of the disease, the retina in CLN3 disease is affected more extensively (involving both cones and rods, as optic nerve associated layers) and more severely, resulting in several consistent clinical and electrophysiological differentiating features of CLN3 disease. Three of these features most clearly aided us to distinguish CLN3 disease from early-onset STGD1: dramatically rapid loss of vision, severe colour vision deficiency (both indicative of severe cone involvement) and absent or electronegative DA ERG responses (indicative of severe rod and optic nerve involvement). The ability to recognize a rare disorder such as CLN3 disease on clinical characteristics only is essential for speedy referral to a metabolic paediatrician, and for adequate rehabilitation, especially since

(untargeted) genetic analysis is not always available or desirable. Patients with CLN3 disease often already face learning problems from disease presentation requiring more than practical adjustments for their visual impairment alone (Spalton et al. 1980; Kuper et al. 2018).

By making the implicit explicit, our approach has made pattern recognition of the differentiating features of a rare retinal dystrophy available to the clinical practice in various contexts. We were able to show that while the VA itself may not be clearly different between CLN3 disease and early-onset STGD1 at presentation, the velocity of the vision loss clearly is different—already within the first year of follow-up. Thus, in circumstances when referral to a specialized centre is not yet possible, re-examining VA within a few months will already help to determine the probability of CLN3 disease as the underlying diagnosis. Next, we argue that colour vision should be assessed

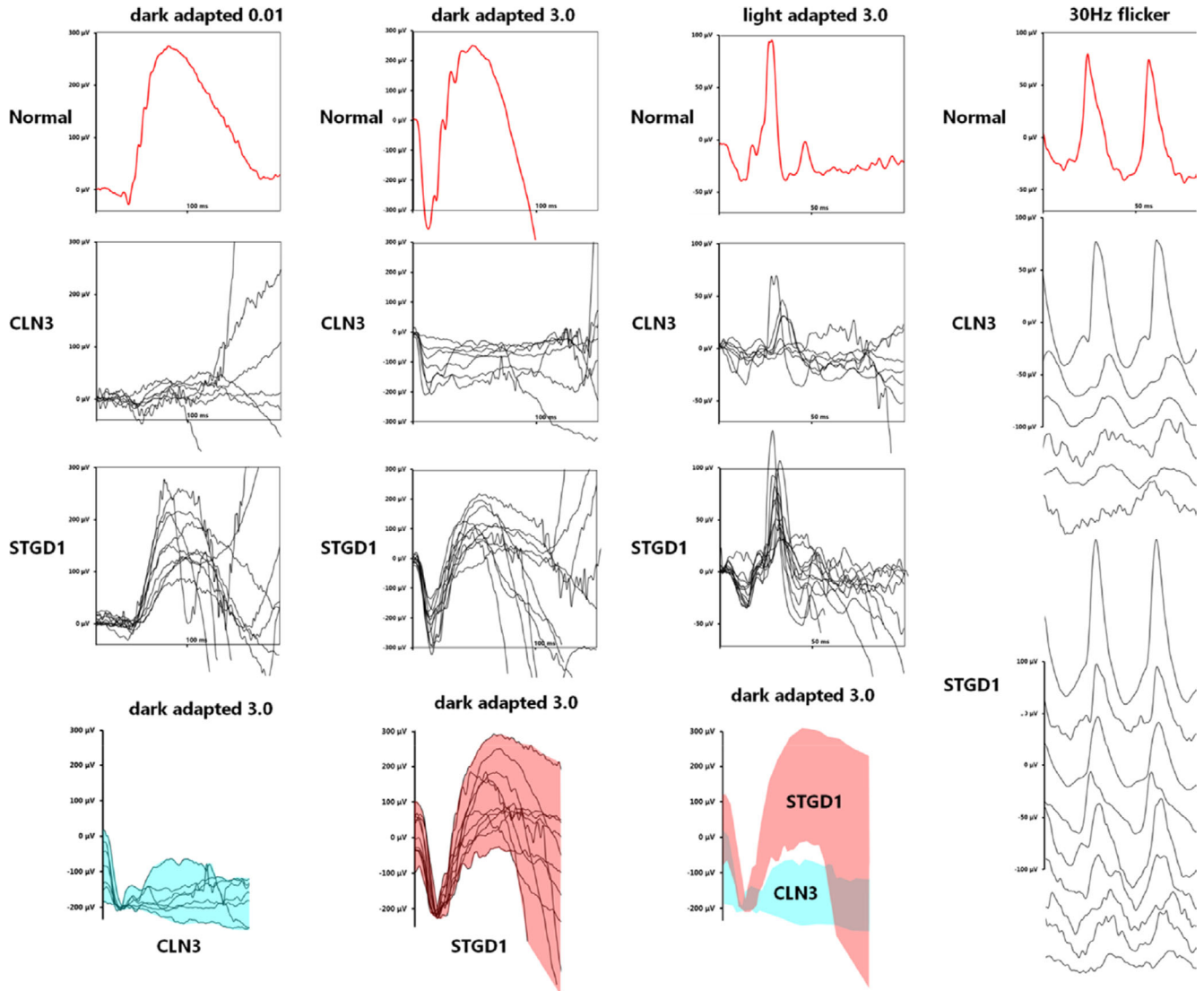


Fig. 4. Light adapted and dark adapted ERG responses around diagnosis in CLN3 disease and early-onset STGD1. Dark adapted (DA 0.01, 3.0) and light adapted (LA 3.0 and 30 Hz flicker) full-field ERG responses in $n = 7$ CLN3 disease patients and $n = 11$ early-onset STGD1 patients examined around presentation compared to $n = 1$ age-matched healthy control. In the lower row, the composite DA 3.0 responses are shown.

with a test that specifies the severity of a colour vision deficiency, such as the HRR. Our results indicate that in most children with vision loss due to macular atrophy, the probability of CLN3 disease as the underlying diagnosis can already reliably be determined based on the severity of a colour vision deficiency. Finally, although it is more invasive than most of the other tests, our results clearly emphasize the relevance of the ERG. Importantly, to distinguish between CLN3 disease and early-onset STGD1, a dark-adapted ERG must be included. This was in our study most strikingly exemplified by the one CLN3 disease patient with only a moderate (red-green) colour vision deficiency and an unaffected light adapted ERG in whom thus only

the—electronegative—dark-adapted ERG responses were clearly outside the range of early-onset STGD1 and within the range of CLN3 disease. We advise to perform the ERG in these (young) children—who may in the case of CLN3 disease already suffer from subtle cognitive and/or behavioural problems—in a specialized centre to maximize the chance to get (reliable) results (Spalton et al. 1980; van Genderen et al. 2006; Kuper et al. 2018).

The apparent early involvement of the inner retina and optic nerve in CLN3 disease not only aids clinical recognition and understanding, but may also provide a clue towards understanding the function of the CLN3 protein, which has to date remained enigmatic. Early optic nerve atrophy is

rare in most retinal dystrophies, but relatively common in mitochondrial disorders (Carelli et al. 2004). In CLN3 disease, the predominant component of the accumulated storage material is the subunit c of mitochondrial F0 ATP synthase, a major component of the inner mitochondrial membrane. It has been postulated that the CLN3 protein functions in a specific part of mitochondrial turnover. When the CLN3 protein is deficient, particularly those areas that require a highly efficient mitochondrial turnover—such as the optic nerve associated layers—might deteriorate. CLN3 was found to primarily localize to the inner retina layers in mice and when deficient optic nerve atrophy was an early feature, but ongoing difficulties with

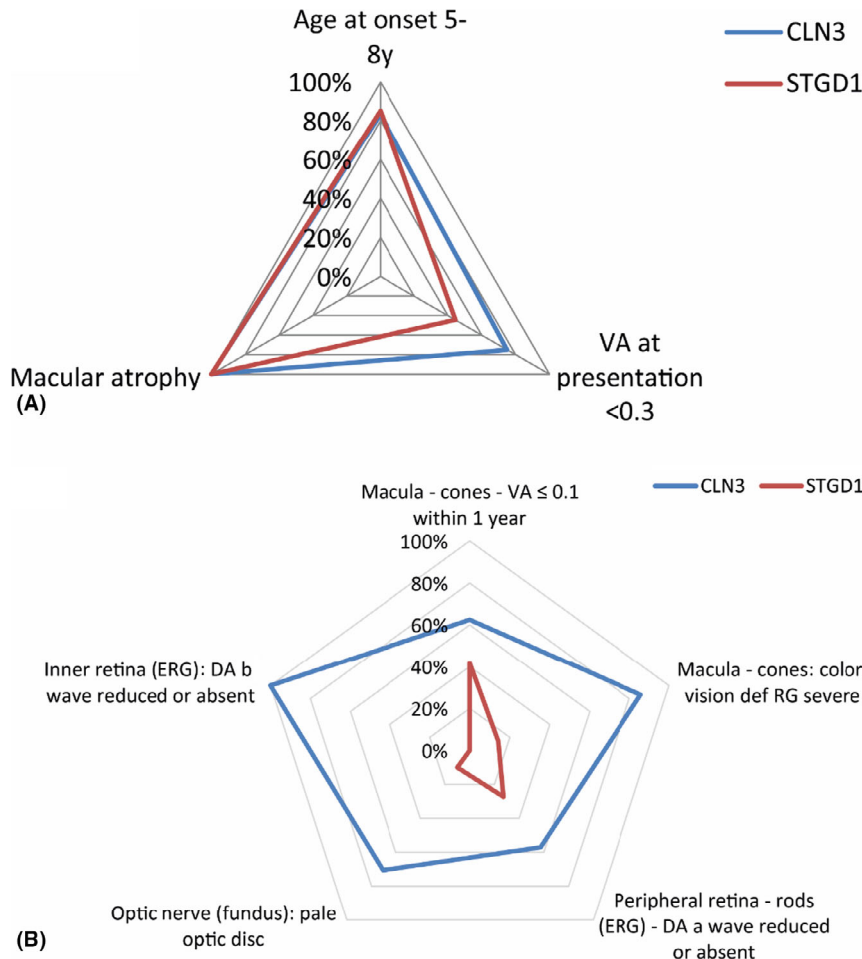


Fig. 5. Multidimensional analysis of retinal involvement in CLN3 disease compared to early-onset STGD1. CLN3 disease and early-onset STGD1 present seemingly similar (A), but in-depth analysis of ophthalmological test results performed around diagnosis reveals that the retinal disease is in CLN3 disease already more extensive (B). In CLN3, more ocular components are involved compared to STGD1: not only photoreceptors (cones and rods) but also inner retina and optic nerve. In addition, the different components are more severely affected, for example a severe cone involvement resulting in a severely impaired VA and severe colour vision deficiency around diagnosis. VA, visual acuity; def, deficiency; RG, red-green.

CLN3 antibody specificity preclude definite conclusions on CLN3 location and function (Katz et al. 1997; Sappington et al. 2003; Weimer et al. 2006; Nelson et al. 2017).

The extensive nature of the current study allowed us to gain new insights, yet still with some limitations. First, the eccentric fixation and limited cooperation of the children led us to use MM6 OCT images in this study. While very useful to identify retinal dystrophy with macular atrophy, these images are less useful for an in-depth and quantitative analysis of retinal layers in these children. This may explain why we did not corroborate a CLN3 disease-specific macular striation pattern (Dulz et al. 2016; Wright et al. 2019). Although there were some differences

between the three assessors in this study, they did point towards an apparent CLN3 disease-specific early inner retina/NFL involvement (Preisling et al. 2017). Second, we previously described a subtle, but measurable early onset of neurologic decline in CLN3 disease (Kuper et al. 2018; Kuper et al. 2019). Possibly, these early learning and/or behavioural difficulties contribute to less effective coping strategies when vision gets lost and thus an earlier presentation to the ophthalmologist. In the present study, we did not find any statistically significant evidence to support this notion, but patients with CLN3 disease did present at a slightly earlier age and with a slightly worse VA than patients with early-onset STGD1. To what degree

the early subtle neurologic impairments impact the results of the (other) ophthalmologic assessments, particularly colour vision and (peripheral) field vision, is difficult to determine with certainty. Finally, since this study is focused on the differentiating characteristics of CLN3 early in the disease course, we did not include follow-up measurements of the different assessments, except for VA. Extensive visual function testing and imaging are generally not repeated in CLN3 disease, because of the rapidly progressive vision loss and the current lack of consequences for therapy. However, when retina-targeting treatments will arrive, longitudinal assessments of ocular changes in CLN3 disease will become more relevant.

The phenotype of CLN3 disease is distributed among a spectrum. While most patients suffer from classical CLN3 disease at the severe end of the spectrum, protracted phenotypes have been described as well (Mole & Cotman 2015; Kuper et al. 2018). In protracted CLN3 disease, neurodegeneration may be delayed, but the retinal phenotype is similar as in classical CLN3 disease underscoring the importance of CLN3 in the retina (Kuper et al. 2018). Interestingly, recent research has revealed a new phenotypic entity at the mild end of the phenotypic spectrum, named CLN3 associated (isolated) retinal degeneration, in which neurodegeneration may never occur at all, and which has a different retinal phenotype as well (Wang et al. 2014; Ku et al. 2017; Kuper et al. 2017). Whereas in classical and protracted CLN3 disease, the retinal phenotype is characterized by a cone-rod dystrophy with childhood onset rapidly deteriorating to blindness, in the CLN3-retina-only phenotype rather a rod-cone dystrophy is seen with adolescence-adult onset more slowly progressing over years to decades. Whereas the contents of our study may only be applicable to classical up to and including protracted CLN3 disease, the approach of our study may similarly be used to improve recognition and understanding of CLN3-associated retinal degeneration.

In conclusion, this study may aid clinicians in differentiating between two rare but clinically relevant disorders of the retina—CLN3 disease and early-onset STGD1—based on their

presenting clinical characteristics only. This differentiation allows early identification of children with CLN3 disease which is essential for adequate referral, counselling and rehabilitation.

References

Anderson G, Smith VV, Malone M & Sebire NJ (2005): Blood film examination for vacuolated lymphocytes in the diagnosis of metabolic disorders; retrospective experience of more than 2,500 cases from a single centre. *J Clin Pathol* **58**: 1305–1310.

Audo I, Robson AG, Holder GE & Moore AT (2008): The negative ERG clinical phenotypes and disease mechanisms of inner retinal dysfunction. *Surv Ophthalmol* **53**: 16–40.

Bax NM, Lambertus S, Cremers FPM, Klevering BJ & Hoyng CB (2019): The absence of fundus abnormalities in Stargardt disease. *Graefes Arch Clin Exp Ophthalmol* **257**: 1147–1157.

Bohra LI, Weizer JS, Lee AG & Lewis RA (2000): Vision loss as the presenting sign in juvenile neuronal ceroid lipofuscinosis. *J Neuroophthalmol* **20**: 111–115.

Brouwer AH, de Wit GC, Ten Dam NH, Wijnhoven R, van Genderen MM & de Boer JH (2019): Prolonged cone b-wave on electroretinography is associated with severity of inflammation in non-infectious uveitis. *Am J Ophthalmol* **207**: 121–129.

Carelli V, Ross-Cisneros FN & Sadun AA (2004): Mitochondrial dysfunction as a cause of optic neuropathies. *Progress in retinal and eye research. Prog Retin Eye Res* **23**: 53–89.

Dulz S, Wagenfeld L, Nickel M, Richard G, Schwartz R, Bartsch U, Kohlschütter A & Schulz A (2016): Novel morphological macular findings in juvenile CLN3 disease. *Br J Ophthalmol* **100**: 824–828.

Eksandh LB, Ponjavic VB, Munroe PB, Eiberg HE, Uvebrant PE, Ehinger BE, Mole SE & Andréasson S (2000): Full-field ERG in patients with Batten/Spielmeier-Vogt disease caused by mutations in the CLN3 gene. *Ophthalmic Genet* **21**: 69–77.

van Genderen MM, Riemsdag F, Jorritsma F, Hoeben F, Meire F & Stilma J (2006): The key role of electrophysiology in the diagnosis of visually impaired children. *Acta Ophthalmol Scand* **84**: 799–806.

Hainsworth DP, Liu GT, Hamm CW & Katz ML (2009): Funduscopy and angiographic appearance in the neuronal ceroid lipofuscinoses. *Retina* **29**: 657–668.

Hansen MS, Hove MN, Jensen H & Larsen M (2016): Optical coherence tomography in juvenile neuronal ceroid lipofuscinosis. *Retin Cases Brief Rep* **10**: 137–139.

Katz ML, Gao CL, Prabhakaram M, Shibuya H, Liu PC & Johnson GS (1997): Immunohistochemical localization of the Batten disease

(CLN3) protein in retina. *Invest Ophthalmol Vis Sci* **38**: 2375–2386.

Ku CA, Hull S, Arno G et al. (2017): Detailed clinical phenotype and molecular genetic findings in CLN3-associated isolated retinal degeneration. *JAMA Ophthalmol* **135**: 749–760.

Kuper WFE, van Alfen C, van Eck L, van den Broek BTA, Huisman A, van Genderen MM & van Hasselt PM (2017): A case of unexpected adult-onset neurologic decline in CLN3-associated retinal degeneration. *JAMA Ophthalmol* **135**: 1451–1453.

Kuper WFE, van Alfen C, van Eck L, Huijgen BCH, Nieuwenhuis EES, van Brussel M & van Hasselt PM (2019): Motor function impairment is an early sign of CLN3 disease. *Neurology* **93**: e293–e297.

Kuper WFE, van Alfen C, Riegerink RH, Fuchs SA, van Genderen MM & van Hasselt PM (2018): Timing of cognitive decline in CLN3 disease. *J Inher Metab Dis* **41**: 257–261.

Kuper WFE, Oostendorp M, van den Broek BTA et al. (2020): Quantifying lymphocyte vacuolization serves as a measure of CLN3 disease severity. *JIMD Rep* **54**: 87–97.

Lambertus S, van Huet RA, Bax NM, Hoef-sloot LH, Cremers FP, Boon CJ, Klevering BJ & Hoyng CB (2015): Early-onset stargardt disease: phenotypic and genotypic characteristics. *Ophthalmology* **122**: 335–344.

McCulloch DL, Marmor MF, Brigell MG, Hamilton R, Holder GE, Tzekov R & Bach M (2015): ISCEV standard for full-field clinical electroretinography (2015 update). *Doc Ophthalmol* **130**: 1–12.

Mole SE & Cotman SL (2015): Genetics of the neuronal ceroid lipofuscinoses (Batten disease). *Biochim Biophys Acta* **1852**(10 Pt B): 2237–2241.

Nelson T, Pearce DA & Kovács AD (2017): Lack of specificity of antibodies raised against CLN3, the lysosomal/endosomal transmembrane protein mutated in juvenile Batten disease. *Biosci Rep* **37**: BSR20171229.

Ouseph MM, Kleinman ME & Wang QJ (2016): Vision loss in juvenile neuronal ceroid lipofuscinosis (CLN3 disease). *Ann N Y Acad Sci* **1371**: 55–67.

Preising MN, Abura M, Jäger M, Wassill KH & Lorenz B (2017): Ocular morphology and function in juvenile neuronal ceroid lipofuscinosis (CLN3) in the first decade of life. *Ophthalmic Genet* **38**: 252–259.

Robinson PN (2012): Deep phenotyping for precision medicine. *Hum Mutat* **33**: 777–780.

Sappington RM, Pearce DA & Calkins DJ (2003): Optic nerve degeneration in a murine model of juvenile ceroid lipofuscinosis. *Invest Ophthalmol Vis Sci* **44**: 3725–3731.

Simunovic MP (2010): Colour vision deficiency. *Eye (Lond)* **24**: 747–755.

Snijders TAB & Bosker RJ (2012): *Multilevel Analysis: An Introduction to Basic and Advanced Multilevel Modeling*, 2nd edn. Los Angeles, CA: SAGE Publications Inc.

Spalton DJ, Taylor DS & Sanders MD (1980): Juvenile batten's disease: an ophthalmological assessment of 26 patients. *Br J Ophthalmol* **64**: 726–732.

The International Batten Disease Consortium (1995): Isolation of a novel gene underlying Batten disease, CLN3. *Cell* **82**: 949–957.

Wang F, Wang H, Tuan HF et al. (2014): Next generation sequencing-based molecular diagnosis of retinitis pigmentosa: identification of a novel genotype-phenotype correlation and clinical refinements. *Hum Genet* **133**: 331–345.

Weimer JM, Custer AW, Benedict JW, Alexander NA, Kingsley E, Federoff HJ, Cooper JD & Pearce DA (2006): Visual deficits in a mouse model of Batten disease are the result of optic nerve degeneration and loss of dorsal lateral geniculate thalamic neurons. *Neurobiol Dis* **22**: 284–293.

Wright GA, Georgiou M, Robson AG et al. (2019): Juvenile Batten Disease (CLN3): detailed ocular phenotype, novel observations, delayed diagnosis, masquerades, and prospects for therapy. *Ophthalmol. Retina* **4**: 433–445.

Received on June 5th, 2020.
Accepted on August 14th, 2020.

Correspondence:

Peter M. van Hasselt, MD, PhD
Wilhelmina Children's Hospital
University Medical Center Utrecht
P.O. box 85090
3508 AB Utrecht
The Netherlands
Tel: +31 88 75 540 01
Fax: +31 88 75 553 49
Email: P.vanhasselt@umcutrecht.nl

Willemijn F.E. Kuper receives unrestricted financial support from the Beat Batten Foundation, the Friends of the Wilhelmina Children's Hospital Foundation and the Bartiméus foundation. The funding organizations had no role in the design or conduct of this research.

Supporting Information

Additional Supporting Information may be found in the online version of this article:

Table S1. Overview of ophthalmological examinations* around presentation in CLN3 disease and early-onset STGD1.

Table S2. Overview of individual CLN3 disease patients and early-onset STGD1 patients examined around presentation at the Bartiméus Institute.