

Chapman University

Chapman University Digital Commons

Physical Therapy Faculty Articles and Research

Physical Therapy

11-11-2020

Proposing a New Algorithm for Premanipulative Testing in Physical Therapy Practice

Brent Harper

Daniel Miner

Harrison Vaughan

Follow this and additional works at: https://digitalcommons.chapman.edu/pt_articles



Part of the [Other Rehabilitation and Therapy Commons](#), and the [Physical Therapy Commons](#)

Proposing a New Algorithm for Premanipulative Testing in Physical Therapy Practice

Comments

This article was originally published in *Journal of Physical Therapy Science*, volume 32, issue 11, in 2020.
<https://doi.org/10.1589/jpts.32.775>

Creative Commons License



This work is licensed under a [Creative Commons Attribution-Noncommercial-No Derivative Works 4.0 License](https://creativecommons.org/licenses/by-nc-nd/4.0/).

Copyright

The Society of Physical Therapy Science



Review Article

Proposing a new algorithm for premanipulative testing in physical therapy practice

BRENT HARPER, PT, DPT, DSc, OCS, FAAOMPT¹⁾*, DANIEL MINER, PT, DPT, NCS²⁾,
HARRISON VAUGHAN, PT, DPT, OCS³⁾

¹⁾ Crean College of Health and Behavior Sciences, Chapman University: 9401 Jeronimo Road, Irvine, CA 92618, USA

²⁾ Department of Physical Therapy, Waldron College of Health and Human Services, Radford University, USA

³⁾ PhysioFit, USA

Abstract. In the field of physical therapy, there is debate as to the clinical utility of premanipulative vascular assessments. Cervical artery dysfunction (CAD) risk assessment involves a multi-system approach to differentiate between spontaneous versus mechanical events. The purposes of this inductive analysis of the literature are to discuss the link between cervical spine manipulation (CSM) and CAD, to examine the literature on premanipulative vascular tests, and to suggest an optimal sequence of premanipulative testing based on the differentiation of a spontaneous versus mechanical vascular event. Knowing what premanipulative vascular tests assess and the associated clinical application facilitates an evidence-informed decision for clinical application of vascular assessment before CSM.

Key words: Manipulation, Algorithm, Cervical

(This article was submitted Jun. 18, 2020, and was accepted Aug. 4, 2020)

INTRODUCTION

Traditionally, vertebrobasilar insufficiency (VBI) has been considered the most concerning risk factor for an adverse event during cervical spine manipulation (CSM)^{1, 2)}. The majority of investigations of CSM adverse events have focused on VBI, specifically injury to the vertebral artery (VA)^{3–6)}. Another vascular concern reported in the literature involves internal carotid artery (ICA) dissection^{4, 7–11)} which would indicate an immediate need for medical referral¹²⁾. The purposes of this clinical perspectives manuscript are to discuss the link between cervical spine manipulation (CSM) and cervical artery dysfunction (CAD), to examine premanipulative vascular tests in the literature, and to suggest an optimal sequence of premanipulative testing based on the differentiation of a spontaneous versus mechanical vascular event.

METHODS

A non-comprehensive inductive analysis of the literature addressing links between CSM and CAD and a review of premanipulative vascular tests in order to propose a new algorithm for premanipulative testing in physical therapy. The answers to this question were determined through the following 5-step process: a literature search was conducted in order to identify information; copies of articles were identified through the literature search and obtained; a synopsis of each article was written in order to capture any information pertaining to the purpose of the study, the research design, sources and kinds of data, data collection and analysis, results, and conclusions. Any manual therapy safety options used to screen patients with neck

*Corresponding author. Brent Harper (E-mail: brharper@chapman.edu)

©2020 The Society of Physical Therapy Science. Published by IPEC Inc.



This is an open-access article distributed under the terms of the Creative Commons Attribution Non-Commercial No Derivatives (by-nc-nd) License. (CC-BY-NC-ND 4.0: <https://creativecommons.org/licenses/by-nc-nd/4.0/>)

pain was noted on each synopsis. MEDLINE and CINAHL search terms included “classify”, “candidates”, “manipulation”, “upper cervical spine manipulation”, “clinical decision making”, “clinical reasoning”, “evidence-based medicine”, “predictive rule”, and “clinical prediction rule”. All articles were searched, but only English language articles were obtained because English abstracts of non-English articles indicated irrelevance. All years were searched with, emphasis was placed on articles published within the last ten-years. Reference articles from reviewed journals garnered additional articles.

RESULTS

In their discussion of vascular insufficiencies, Kerry et al.¹³⁾ and Kerry & Taylor¹⁴⁾ proposed a revision of the nomenclature, suggesting the term *cervical artery dysfunction (CAD)* since it encompasses potential complications of all arteries in the cervico-cranial region. The authors identified inherent risks from a global hemodynamic perspective rather than structural or pathological, as historically categorized. Kerry et al.¹³⁾ defined CAD as: the completeness of the arterial anatomy (e.g., the vertebrobasilar system, the internal carotid arteries, and the Circle of Willis), and the range of pathologies that the manual therapist may encounter (e.g., local dissection, atherosclerotic events, vessel injury, non-ischaemic [sic] events, ischemic events).

This definition of CAD is the International Framework for Examination of the Cervical Region standard as adopted by the International Federation of Orthopaedic Manual Physical Therapists (IFOMPT) for identification of vascular involvement before orthopedic manual therapy intervention¹⁵⁾. IFOMPT does not discourage mechanical vascular patency assessments, and the Australian Physiotherapy Association (APA)¹⁶⁾ protocol includes evaluation for vascular symptoms while performing mechanical movements that stress vascular patency.

Neurovascular structures can be compromised both externally and internally, resulting in symptoms. CAD symptoms from extrinsic or mechanical factors, in which anatomical structures play a role, including osteophytes, skeletal anomalies, muscular entrapment, fibrous bands, and nerve entrapment, may compromise neurovascular structures. Excessive mechanical forces, like cervical spine rotation and hyperextension or CSM, are also extrinsic causes which may result in mechanical arterial dissection¹⁷⁾. Intrinsic CAD symptoms relate to the pathology of the artery itself, a narrowing of the lumen. Intrinsic factors include atherosclerosis, aneurysms, thrombosis, and emboli, any of which may result in spontaneous arterial dissection^{17, 18)}.

The incidence of mechanical arterial dissections due to an extrinsic factor such as CSM ranges from 1 in 9,000 to 1 in 10 million with inherent under-reporting, making the actual incidence challenging to calculate accurately^{19–24)}. The incidence of spontaneous arterial dissection due to intrinsic factors is 1 to 1.5 per 100,000 people^{19–24)}. Thus, a spontaneous arterial dissection event is probably more prevalent than those associated with CSM or vertebral artery testing like deKleyn's, pre-manipulative holds or cervical rotation^{19–24)}. Consequently, there appear to be other factors involved in arterial compromise besides the biomechanical forces associated with CSM or vertebral artery testing^{17, 20, 21, 25)}. These other factors focus on various medical co-morbidities, resulting in turbulence in the arteries, specifically atherosclerosis, hypertension, or diabetes mellitus^{18, 26, 27)}. Spontaneous arterial dissections appear to be related to co-morbidities that affect vasculature, primarily ICAs, as well as the VAs. The ICAs affected by vascular turbulence issues are more likely to present with signs and symptoms. It is no surprise, then, that ICA dissection rates are nearly double the rates of VA dissection²⁸⁾. Given the various cortical and subcortical regions these vessels supply, clinical signs, and symptoms associated with ICA dissection differ significantly from those associated with VA dissection. A full description of ICA symptoms is beyond this paper's scope, but initial signs of ICA disruption are often seen by testing eye functions^{17, 29)}. The critical element regarding mechanical extrinsic and intrinsic testing is that biomechanical arterial testing will not assist in identifying those at risk of spontaneous arterial dissection. In fact, the actual performance of a biomechanical test on someone at risk for intrinsic pathology may enable a spontaneous event to occur more readily¹⁷⁾.

Clinicians must be able to effectively screen for and rule out concern for vascular compromise before any mechanical evaluation of the cervical spine. The ability to effectively screen for vascular complication threats is essential to understanding the underlying risk factors which may predispose an individual to cervical artery dissection (Fig. 1)¹⁷⁾.

The ICAs provide 80–89% of blood flow to the brain and give rise to the middle and anterior cerebral arteries. The VAs join to form the basilar artery and contribute 11–20% of cerebral blood flow to the posterior circulation of the brain^{30, 31)}. The course of the VA varies and is more likely to be anomalous in individuals with congenital deformities of the cranio-cervical junction or with a history of trauma involving atlantoaxial subluxation^{32, 33)}. Up to 20% of the population has a normal anatomical variation of some type. Theoretically, anomalies of the VA, or any artery, may alter hemodynamics by increased turbulence, which may predispose the individual to aneurysms, thus increasing the risk for cerebrovascular accident (CVA)^{17, 27)}. Despite anatomical variations, their impact on the risk of VA dissection is unknown^{34, 35)}.

The VA passes through four distinct anatomical zones. In zone 3, the VA passes through the transverse foramen of C1 and makes a sharp turn horizontally across it before piercing through the dura mater. Fifty percent of cervical rotation occurs within zone 3 at the atlantoaxial (AA) joint between C1 and C2, causing the most significant impact on the VA as it may be “tethered” at various points^{11, 34, 35)}. Therefore, the tortuous course of the VA in zone 3 correlates with the location most frequently at risk from CSM^{36–38)}.

The anatomical course of the VA and its potential vulnerability at fixation points might affect blood flow during cervical

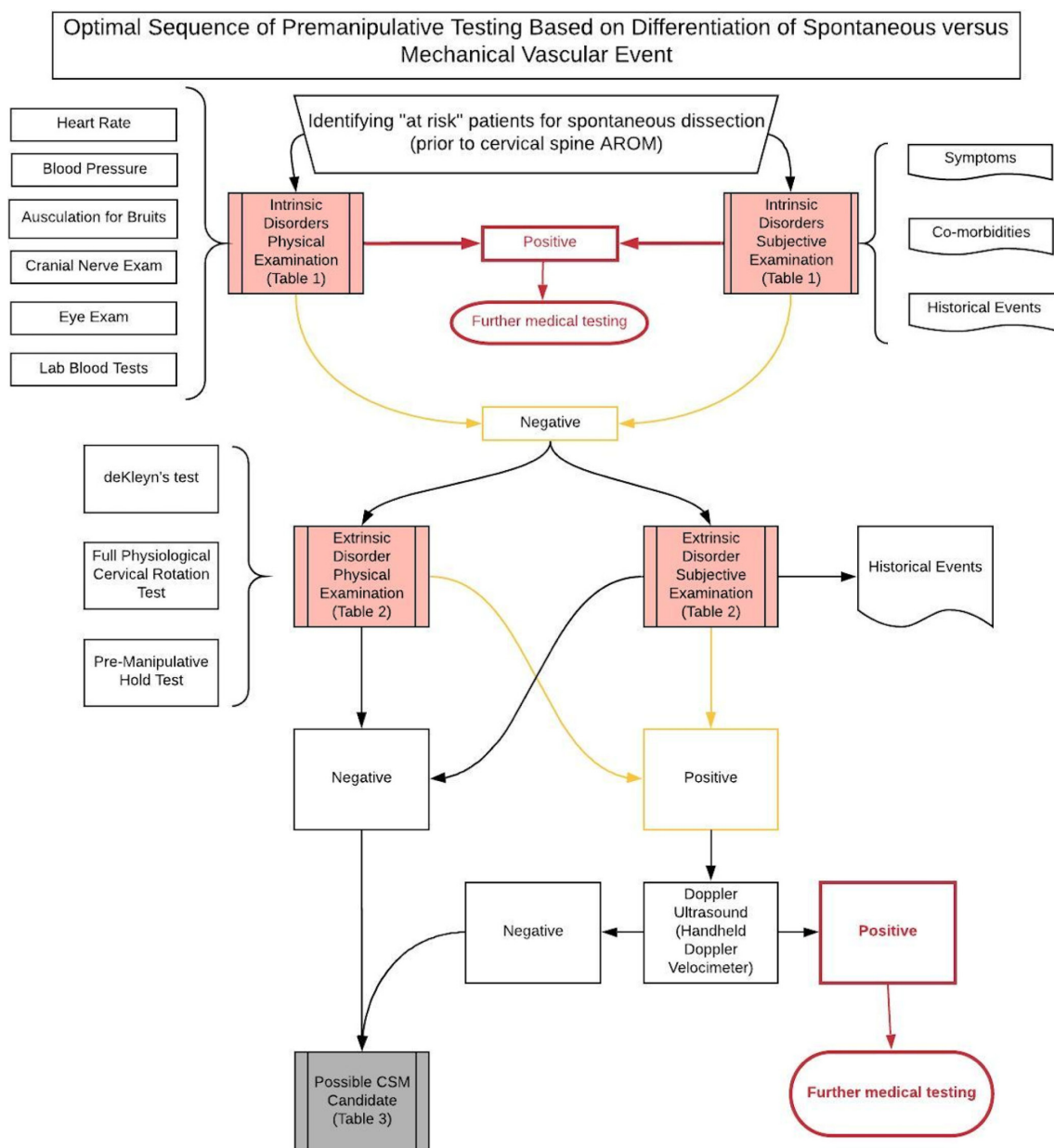


Fig. 1. Algorithm: clinical reasoning sequence for determining vascular risk¹⁷.
 AROM: Active Range of Motion; CSM: Cervical Spine Manipulation.

active range of motion, premanipulative mechanical testing, or CSM. The VA is stretched more significantly during rotation, whereas the ICA is stretched more during extension^{39, 40}. These findings have been the foundational premise for using premanipulative testing to assess for compromised circulation in the cervico-cranial arteries⁴¹.

Premanipulative mechanical (extrinsic) vascular assessments are the established standard of care; deKleyn's test is one of the most common⁴². Symptom provocation with positional testing indicates a positive deKleyn's test consistent with CAD and indicates CSM contraindication. Researchers⁴³ measured cervical blood flow in neutral and deKleyn's position using doppler ultrasound to measure blood flow velocity on 20 individuals with a positive deKleyn's test. Significant clinical inconsistencies were found between deKleyn's test and doppler findings. The researchers concluded a positive premanipulative test, such as deKleyn's, does not indicate an absolute contraindication to CSM, but would indicate a need for referral for doppler ultrasound examination of the arterial flow. Finally, the authors stated that if the follow up doppler ultrasound is normal, then CSM is not contraindication, even with positive premanipulative test⁴³.

The most significant risk of upper CSM is cervical arterial dissection leading to stroke or death⁴⁴. Zaina et al.⁴⁵ examined the effect of cervical rotation on C1–2 contralateral VA blood flow peak velocity and on C5–6 ipsilateral VA volume flow

rate, and whether there was a cumulative blood flow. Twenty participants were examined with ultrasound doppler in a seated position with head neutral, at 45 degrees, and in end range cervical rotation. None of the participants were symptomatic during testing, and no significant differences were found at 45 degrees or end-range rotations in the blood flow parameters of peak velocity at C1–2 and volume flow rate at C5–6. Repetition of the rotational positioning did not have a cumulative effect, demonstrating that cumulative premanipulative testing did not harm the VAs in those participants⁴⁵). Furthermore, Erhardt et al.⁴⁶) assessed haemodynamics on healthy adults at C1–2 and found no deleterious effects to VA blood flow when comparing high-velocity low amplitude (HLVT) thrust technique to premanipulative holds.

Specific blood flow turbulence assessments such as doppler ultrasonography have demonstrated that spontaneous changes in VA and ICA blood flow^{16, 47, 48}) are not always directly related to CSM mechanical forces, but may be intrinsically based. At present, there are no definitive findings relating blood flow changes to CSM and literature is mixed; several studies show a reduction in contralateral blood flow during cervical rotation^{49–53}), while others show no blood flow changes^{54–57}). One study⁵⁸) used MRI to assess blood flow of healthy individuals during various non-manipulative procedures such as end-range cervical rotation, upper cervical rotation, or firm axial distraction and found no alterations in blood flow and concluded it unlikely that end-range neck rotation and distraction positions are hazardous to the cerebral circulation. Furthermore, the authors suggested specific segmentally localized techniques posed no higher risk to cerebral circulation than the mechanical positions tested⁵⁸). Other research⁵⁹) on healthy, asymptomatic patients with decreased blood flow in VAs and ICAs, as confirmed by magnetic resonance angiography, had negative positional tests for CAD during mechanical end range rotation testing. The results of these studies call into question the utility of mechanical vascular assessment procedures. Thomas et al.⁵⁹) hypothesized that compromised blood flow in one artery is naturally compensated for by collateral flow through the arterial Circle of Willis, which helps to mitigate any symptoms which may have resulted from decreased circulation. This evidence may suggest that individuals who experience end-range cervical rotation symptoms may not have CAD, but may have dysfunction more proximally (intrinsic) in the intracranial circulation of the Circle of Willis⁵⁹).

Furthermore, Symons & Westaway²⁷) argue that biomechanical vertebral arterial tests, like deKleyn's, and manual interventions, like CSM, may not disrupt vertebral artery blood flow for two reasons. First, most people have four major arteries that supply the Circle of Willis, allowing collateral reflexive vascular compensation for any brain perfusion deficits. The authors provide evidence that compensatory blood flow occurs without resulting in an incident of VBI, even when 100% of the vertebral artery is occluded. Second, the authors report that CSM is too fast, occurring at 200 milliseconds, if performed correctly in mid-range and not at end-range tension, which does not stress the neurovascular structures like a prolonged stretch. Therefore, CSM procedures are too fast to cause arterial damage if performed in the proper range of motion. The authors conclude that if CSM induces VBI signs and symptoms, it does so only in the presence of other factors like when a spontaneous event is already in progress²⁷).

Even though premanipulative mechanical vascular assessments are taught in entry-level physical therapy programs, they continue to be challenged and questioned as objective clinical tests. Due to reduced sensitivity^{11, 13, 14, 48, 60}), these tests are associated with a high rate of false negatives⁶) and have poor ability to discriminate between individuals with or without arterial pathology. Evidence-informed practice indicates that clinicians cannot rely solely on symptom provocation with mechanical vascular assessments to definitively rule out cervical artery dysfunction due to the poor diagnostic accuracy of these tests^{3, 60}).

In summary, one of the first clinical tests for cervical arterial dysfunction was described by deKlyne over 50-years ago and continues to be commonly used⁴) even though concerns related to diagnostic accuracy have prevented its integration into clinical prediction rules. Blood flow^{45, 54, 57, 58}), VA^{61, 62}), and ICA⁶¹) strain studies found a complete lack of construct validity for premanipulative vascular screening tests. The literature fails to support the ability of premanipulative tests to identify, through positive or negative test findings, individuals at risk for a post-CSM vascular event^{3, 5, 11, 13, 39, 63}), to provide any useful additional diagnostic information⁶⁴); and has identified a high frequency of false negative VA tests⁶⁵). Many authors advise against using mechanical vascular tests to assess vascular patency, primarily when a thorough history identifies signs and symptoms consistent with CAD^{13, 60, 64}). Finally, the evidence suggests that active range of motion puts more strain on the ICA than CSM⁶¹).

Limitations included lack of access to non-published professional conferences and the possibility that some non-English professional writings in the form of books and journal articles might have been relevant to the subject studied in this paper.

DISCUSSION

The Australian Physiotherapy Association (APA) VA protocol¹⁶) recommends conducting active range of motion (AROM) and positional vascular patency test when symptoms of VBI/CAD are unclear on patients with a vague subjective history for potential VBI/CAD symptoms. In the United States, vascular screening remains common practice prior to CSM. Despite the current research, IFOMPT¹⁵) does not specifically discourage mechanical vascular patency assessments. ICA vascular compromise is associated with spontaneous arterial dissection; thus, assessments for overt symptoms or the presence of vague signs and symptoms associated with ICA ischemia is vital, in conjunction with a thorough history of co-morbidities and events (Tables 1 and 3) before any mechanical stress is placed in the region¹⁷), such as vascular screening or mechanical stressors (AROM),

Despite the lack of support for mechanical vascular assessments for CAD, there remains some clinical value in premanipulative screening tests. The key to understanding their clinical value is in acknowledging that mechanical tests cannot

Table 1. Optimal sequence of premanipulative assessment (intrinsic)^{11, 13, 14, 17, 67)}

Spontaneous arterial dissection (intrinsic disorder)	
History – Subjective exam/SE	<ol style="list-style-type: none"> 1. Symptoms: 5Ds (Diplopia, Dizziness, Drop Attacks, Dysarthria, & Dysphagia), 3Ns (Nausea, Nystagmus, & Numbness), Headache, Ataxia 2. Co-Morbidities (Anything that increases turbulence): Atherosclerosis, Hypertension (HTN), Diabetes Mellitus (DM), history of migraine, genetic defects (e.g., increased levels of amino acid homocysteine creating fragility of the arterial walls) 3. Historical Events <ol style="list-style-type: none"> a) A sudden onset of severe sharp posterior cervical and occipital pain. b) A history of smoking (especially long-standing history). c) Episodic dizziness or vertigo lasting greater than one minute in isolation or with pre-manipulative screening test. d) Previous history of ischemic attacks. e) A history of trauma (especially if it included whiplash that involved a flexion-distraction-and-rotation force).
Tests & Measures – Objective exam (Physical exam/PE)	Heart Rate (HR), Blood Pressure (BP), Auscultation for bruits, cranial nerve examination, general eye examination, lab blood tests (amino acid homocysteine levels).

Table 2. Optimal sequence of premanipulative assessment (extrinsic)^{11, 13, 14, 17, 67)}

Mechanical arterial compromise (extrinsic disorder)	
History – Subjective exam/SE	<ol style="list-style-type: none"> 1. Historical Events <ol style="list-style-type: none"> a) A sudden onset of severe sharp posterior cervical and occipital pain. b) A history of smoking (especially long-standing history). c) Episodic dizziness or vertigo lasting greater than one minute in isolation or with pre-manipulative screening test. d) Previous history of ischemic attacks. e) A history of trauma (especially if it included whiplash that involved a flexion-distraction-and-rotation force).
Tests & Measures – Objective exam (Physical exam/PE)	deKleyn's test, Full Physiological Cervical Rotation test, Pre-Manipulative Hold (PMH) test, Handheld Doppler Velocimeter.

identify risk for spontaneous CAD and, as previously stated, may cause a vascular event. If there are no risk factors for vascular disease and negative non-vascular patency screening tests (like heart rate, blood pressure, bruits) for system-wide spontaneous vascular compromise, then there is minimal risk of provoking a vascular event through the use of mechanical vascular screens. On the other hand, if positive risk factors are identified for a spontaneous event or if the clinician is unsure, the clinician would be unwise to attempt provocation through mechanical testing. Therefore, mechanical premanipulative tests are not employed when the clinician has any suspicion that a spontaneous vascular event is imminent or highly probable^{13, 17, 66)}, but may be useful to assess an individual's physical and emotional tolerance in the range in which the CSM will occur¹⁷⁾.

It is the opinion of the authors that the current evidence does not support the utility of routinely performing premanipulative screens, such as deKlyne's, to identify CAD. Presently, based on the current medico-legal constraints governing the profession, premanipulative screens should be done, when appropriate, for medico-legal purposes due to the societal perception of the risks for adverse events, even though the evidence does not support the tests, until which time the expectations of excluding mechanical premanipulative testing becomes "standard" practice¹⁷⁾.

This clinical usefulness of this study is in its emphasis on the order of operations for safely screening for spontaneous arterial dissection prior to AROM, and in the recommendation that vascular screening tests are not useful for assessing vascular patency, but might be useful after clearance for spontaneous dissection (Table 1) to assess an individual's mechanical and emotional tolerance within the range CSM will occur. This algorithm is intended to add to APA¹⁶⁾ and IFOMPT¹⁵⁾ premanipulative CAD guidelines (Fig. 1) and is based on intrinsic versus extrinsic disorders. Screening for spontaneous hemodynamic CAD involves a combination of assessing for co-morbidities, investigating patient historical events, evaluating subjective complaints, and providing appropriate physical examination procedures^{11, 13, 14, 17, 67)}. Once spontaneous vascular sequelae events (intrinsic disorders) (Table 1) have been screened as negative for vascular co-morbidities, then premanipulative screening for mechanical arterial compromise (extrinsic disorders) (Table 2) can be performed, not to assess arterial patency in terms of VBI/CAD, but to evaluate for potential intolerance to mechanical forces which may occur during CSM¹⁷⁾ (Table 3).

Table 3. Clinical reasoning sequence for determining vascular risk (Fig. 1)^{11, 13–15, 17, 43, 67}

History – Subjective exam (SE)	<p>Review of Systems (General Health): Intake questionnaire screening.</p> <p>Co-Morbidities: Higher Suspicion with Increased System Involvement and Subjective Reports Atherosclerosis; associated factors include: Hypertension, Hypercholesterolemia, Hyperlipidemia, Hyperhomocysteinemia, Heart disease, Diabetes mellitus, Lupus erythematosus, alcoholism, Genetic clotting disorders, infections, smoking, Direct vessel trauma, Iatrogenic causes (surgery, medical interventions).</p> <p>Genetic / Lifestyle Factors: Female gender, advancing age, obesity, sedentary lifestyle and prolonged bed rest, cigarette smoking.</p> <p>Subjective complaints of: Dizziness (vertigo, giddiness, lightheadedness), Drop attacks (loss of consciousness), Diplopia, Dysarthria, Dysphagia, Nystagmus, Nausea, Numbness, Headache, and Ataxia.</p> <p>History of: Headache or neck pain, especially if sudden and severe, vomiting, facial sensation alteration, blurred vision, tinnitus, history of past trauma, (particularly a high-velocity flexion-distraction with rotational forces, like those occurring during a whiplash incident), nystagmus, altered blood pressure, previous transient ischaemic attacks, Horner’s syndrome.</p> <p>Historical Events: A sudden onset of severe sharp posterior cervical and occipital pain. A history of smoking (especially long standing history). Episodic dizziness or vertigo lasting greater than one minute in isolation or with pre-manipulative screening test. Previous history of ischemic attacks. A history of trauma (especially if it included whiplash that involved a flexion-distraction-and-rotation force).</p>
Tests & Measures – Objective exam (OE)	<p>Structural Inspection Systems Review (Specific Systems): Vital Signs e.g., Heart Rate (HR), Blood Pressure (BP), Respiratory Rate (RR), Oxygen saturation, etc.</p> <p>Palpation Auscultation of bruits. Pulse palpation/examination and general vascular assessment (e.g., nail bed refill, etc.).</p> <p>Special Tests Cranial nerve examination (may be listed under Neurological Tests or Special Test). CN II (vision and eye exam; acuity (Snellen charts), color vision (Ishihara plates), visual fields, visual reflexes (reactivity to light), fundoscopy, CN III, IV, VI (Extraocular Muscles) General Eye examination may include: 1. Eye position & alignment / Upper & Lower eyelids in relation to eyeball. 2. Pupil PERRLA P = Pupil size with chart in MM (3–4.5 normal) E = Equal / Symmetrical sizes (subtle differences is normal) R = Shape (normal is round) R = Reactive to light (direct response = pupil narrows with direct light to eye) (consensual response = pupil narrows light opposite eye) L = Lacrimal (inspect regions lacrimal gland/sac for swelling) (look for excessive tearing or dryness) A = Accommodation (pupil constricts and expands when focusing on short and near objects) 3. Visual Acuity (Snellen Chart) 4. Extraocular Muscles (checking smooth pursuit/ gaze in “H” pattern; pause during upward & lateral gaze to detect nystagmus) (Normal = a few beats of nystagmus on extreme lateral gaze is WNL) Direct Mechanical Testing Options Include/Functional Position Tests: 1. Full physiological cervical rotation. 2. deKleyn’s Test (subject positioned at the end of the bed at 3rd thoracic segment with cervical segments hanging off the table to allow for full supported extension-rotation). 3. Pre-manipulative hold/PMH (positioned in cranio-vertebral side flexion combined with contralateral rotation down to and including atlanto-axial joint with digital pressure on C1–C2 just short of manipulative thrust and held for a minimum of 10 seconds). 4. Hand held Doppler velocimetry. If mechanical premanipulative tests are positive, refer patient for Doppler ultrasonography.</p> <p>LAB Values Elevated levels of amino acid homocysteine. Normal Levels (plasma): Males 4–12 micromoles/L, Females 4–10 micromoles/L. Level may be considered elevated if > 9 micromoles/L.</p>

Funding

None.

Conflict of interest

The authors have no conflict of interests to disclose.

REFERENCES

- 1) Carlesso LC, Gross AR, Santaguida PL, et al.: Adverse events associated with the use of cervical manipulation and mobilization for the treatment of neck pain in adults: a systematic review. *Man Ther*, 2010, 15: 434–444. [[Medline](#)] [[CrossRef](#)]
- 2) Chung CL, Côté P, Stern P, et al.: The association between cervical spine manipulation and carotid artery dissection: a systematic review of the literature. *J Manipulative Physiol Ther*, 2015, 38: 672–676. [[Medline](#)] [[CrossRef](#)]
- 3) Di Fabio RP: Manipulation of the cervical spine: risks and benefits. *Phys Ther*, 1999, 79: 50–65. [[Medline](#)]
- 4) Grant R: Vertebral artery testing—the Australian Physiotherapy Association Protocol after 6 years. *Man Ther*, 1996, 1: 149–153. [[Medline](#)] [[CrossRef](#)]
- 5) Haldeman S, Kohlbeck FJ, McGregor M: Unpredictability of cerebrovascular ischemia associated with cervical spine manipulation therapy: a review of sixty-four cases after cervical spine manipulation. *Spine*, 2002, 27: 49–55. [[Medline](#)] [[CrossRef](#)]
- 6) Haneline MT, Croft AC, Frishberg BM: Association of internal carotid artery dissection and chiropractic manipulation. *Neurologist*, 2003, 9: 35–44. [[Medline](#)] [[CrossRef](#)]
- 7) Beatty RA: Dissecting hematoma of the internal carotid artery following chiropractic cervical manipulation. *J Trauma*, 1977, 17: 248–249. [[Medline](#)] [[CrossRef](#)]
- 8) Hamann G, Felber S, Haas A, et al.: Cervicocephalic artery dissections due to chiropractic manipulations. *Lancet*, 1993, 341: 764–765. [[Medline](#)] [[CrossRef](#)]
- 9) Lyness SS, Wagman AD: Neurological deficit following cervical manipulation. *Surg Neurol*, 1974, 2: 121–124. [[Medline](#)]
- 10) Peters M, Bohl J, Thömke F, et al.: Dissection of the internal carotid artery after chiropractic manipulation of the neck. *Neurology*, 1995, 45: 2284–2286. [[Medline](#)] [[CrossRef](#)]
- 11) Taylor AJ, Kerry R: Neck pain and headache as a result of internal carotid artery dissection: implications for manual therapists. *Man Ther*, 2005, 10: 73–77. [[Medline](#)] [[CrossRef](#)]
- 12) Willett GM, Wachholtz NA: A patient with internal carotid artery dissection. *Phys Ther*, 2011, 91: 1266–1274. [[Medline](#)] [[CrossRef](#)]
- 13) Kerry R, Taylor AJ, Mitchell J, et al.: Manual therapy and cervical arterial dysfunction, directions for the future: a clinical perspective. *J Manual Manip Ther*, 2008, 16: 39–48. [[Medline](#)] [[CrossRef](#)]
- 14) Kerry R, Taylor AJ: Cervical arterial dysfunction: knowledge and reasoning for manual physical therapists. *J Orthop Sports Phys Ther*, 2009, 39: 378–387. [[Medline](#)] [[CrossRef](#)]
- 15) Rushton A, Rivett D, Carlesso L, et al.: International framework for examination of the cervical region for potential of Cervical Arterial Dysfunction prior to Orthopaedic Manual Therapy intervention. *Man Ther*, 2014, 19: 222–228. [[Medline](#)] [[CrossRef](#)]
- 16) Magarey ME, Rebbeck T, Coughlan B, et al.: Pre-manipulative testing of the cervical spine review, revision and new clinical guidelines. *Man Ther*, 2004, 9: 95–108. [[Medline](#)] [[CrossRef](#)]
- 17) Harper B: Clinical reasoning for upper cervical spine manipulation: modified extensive literature review. (Doctoral dissertation). Ola Grimsby Institute, Salt Lake City, UT. 2008.
- 18) Mitchell J: Vertebral artery atherosclerosis: a risk factor in the use of manipulative therapy? *Physiother Res Int*, 2002, 7: 122–135. [[Medline](#)] [[CrossRef](#)]
- 19) Cassidy JD, Boyle E, Côté P, et al.: Risk of vertebrobasilar stroke and chiropractic care: results of a population-based case-control and case-crossover study. *Spine*, 2008, 33: S176–S183. [[Medline](#)] [[CrossRef](#)]
- 20) Hart RG, Easton JD: Dissections of cervical and cerebral arteries. *Neurol Clin*, 1983, 1: 155–182. [[Medline](#)] [[CrossRef](#)]
- 21) Lee VH, Brown RD Jr, Mandrekar JN, et al.: Incidence and outcome of cervical artery dissection: a population-based study. *Neurology*, 2006, 67: 1809–1812. [[Medline](#)] [[CrossRef](#)]
- 22) Murphy DR: Current understanding of the relationship between cervical manipulation and stroke: what does it mean for the chiropractic profession? *Chiropr Osteopat*, 2010, 18: 22. [[Medline](#)] [[CrossRef](#)]
- 23) Rothwell DM, Bondy SJ, Williams JI: Chiropractic manipulation and stroke: a population-based case-control study. *Stroke*, 2001, 32: 1054–1060. [[Medline](#)] [[CrossRef](#)]
- 24) Whedon JM, Song Y, Mackenzie TA, et al.: Risk of stroke after chiropractic spinal manipulation in medicare B beneficiaries aged 66 to 99 years with neck pain. *J Manipulative Physiol Ther*, 2015, 38: 93–101. [[Medline](#)] [[CrossRef](#)]
- 25) Schievink WI, Mokri B, Whisnant JP: Internal carotid artery dissection in a community. Rochester, Minnesota, 1987–1992. *Stroke*, 1993, 24: 1678–1680. [[Medline](#)] [[CrossRef](#)]
- 26) Rosner AL: Spontaneous cervical artery dissections and implications for homocysteine. *J Manipulative Physiol Ther*, 2004, 27: 124–132. [[Medline](#)] [[CrossRef](#)]
- 27) Symons BP, Westaway M: Virchow's triad and spinal manipulative therapy of the cervical spine. *J Can Chiropr Assoc*, 2001, 45: 225–231.
- 28) Biller J, Sacco RL, Albuquerque FC, et al. American Heart Association Stroke Council: Cervical arterial dissections and association with cervical manipulative therapy: a statement for healthcare professionals from the American heart association/American stroke association. *Stroke*, 2014, 45: 3155–3174. [[Medline](#)] [[CrossRef](#)]
- 29) Chaibi A, Russell MB: A risk-benefit assessment strategy to exclude cervical artery dissection in spinal manual-therapy: a comprehensive review. *Ann Med*, 2019, 51: 118–127. [[Medline](#)] [[CrossRef](#)]
- 30) Grieve GP: Common vertebral joint problems. New York: Churchill Livingstone Inc, 1981.
- 31) Cailliet R: Head and face pain syndromes, 1st ed. Philadelphia: F.A. Davis Company, 1992.
- 32) Yamazaki M, Okawa A, Furuya T, et al.: Anomalous vertebral arteries in the extra- and intraosseous regions of the craniovertebral junction visualized by

- 3-dimensional computed tomographic angiography: analysis of 100 consecutive surgical cases and review of the literature. *Spine*, 2012, 37: E1389–E1397. [[Medline](#)] [[CrossRef](#)]
- 33) Vaněk P, Bradáč O, de Lacy P, et al.: Vertebral artery and osseous anomalies characteristic at the craniocervical junction diagnosed by CT and 3D CT angiography in normal Czech population: analysis of 511 consecutive patients. *Neurosurg Rev*, 2017, 40: 369–376. [[Medline](#)] [[CrossRef](#)]
 - 34) Johnson CP, How T, Scraggs M, et al.: A biomechanical study of the human vertebral artery with implications for fatal arterial injury. *Forensic Sci Int*, 2000, 109: 169–182. [[Medline](#)] [[CrossRef](#)]
 - 35) Macchi C, Giannelli F, Cecchi F, et al.: The inner diameter of human intracranial vertebral artery by color Doppler method. *Ital J Anat Embryol*, 1996, 101: 81–87. [[Medline](#)]
 - 36) Frumkin LR, Baloh RW: Wallenberg's syndrome following neck manipulation. *Neurology*, 1990, 40: 611–615. [[Medline](#)] [[CrossRef](#)]
 - 37) George B, Laurian C: Vertebro-basilar ischaemia with thrombosis of the vertebral artery: report of two cases with embolism. *J Neurol Neurosurg Psychiatry*, 1982, 45: 91–93. [[Medline](#)] [[CrossRef](#)]
 - 38) Sim E, Schwarz N, Biowski-Fasching I, et al.: Color-coded Duplex sonography of vertebral arteries. 11 cases of blunt cervical spine injury. *Acta Orthop Scand*, 1993, 64: 133–137. [[Medline](#)] [[CrossRef](#)]
 - 39) Rivett DA, Sharples KJ, Milburn PD: Effect of premanipulative tests on vertebral artery and internal carotid artery blood flow: a pilot study. *J Manipulative Physiol Ther*, 1999, 22: 368–375. [[Medline](#)] [[CrossRef](#)]
 - 40) Scheel P, Ruge C, Schöning M: Flow velocity and flow volume measurements in the extracranial carotid and vertebral arteries in healthy adults: reference data and the effects of age. *Ultrasound Med Biol*, 2000, 26: 1261–1266. [[Medline](#)] [[CrossRef](#)]
 - 41) Barker S, Kesson M, Ashmore J, et al.: Professional issue. Guidance for pre-manipulative testing of the cervical spine. *Man Ther*, 2000, 5: 37–40. [[Medline](#)] [[CrossRef](#)]
 - 42) Magee D: *Orthopaedic physical assessment*, 5th ed. St. Louis: Saunders Elsevier, 2008.
 - 43) Licht PB, Christensen HW, Høilund-Carlens PF: Is there a role for premanipulative testing before cervical manipulation? *J Manipulative Physiol Ther*, 2000, 23: 175–179. [[Medline](#)] [[CrossRef](#)]
 - 44) Miley ML, Wellik KE, Wingerchuk DM, et al.: Does cervical manipulative therapy cause vertebral artery dissection and stroke? *Neurologist*, 2008, 14: 66–73. [[Medline](#)] [[CrossRef](#)]
 - 45) Zaina C, Grant R, Johnson C, et al.: The effect of cervical rotation on blood flow in the contralateral vertebral artery. *Man Ther*, 2003, 8: 103–109. [[Medline](#)] [[CrossRef](#)]
 - 46) Erhardt JW, Windsor BA, Kerry R, et al.: The immediate effect of atlanto-axial high velocity thrust techniques on blood flow in the vertebral artery: A randomized controlled trial. *Man Ther*, 2015, 20: 614–622. [[Medline](#)] [[CrossRef](#)]
 - 47) Herzog W, Leonard TR, Symons B, et al.: Vertebral artery strains during high-speed, low amplitude cervical spinal manipulation. *J Electromyogr Kinesiol*, 2012, 22: 740–746. [[Medline](#)] [[CrossRef](#)]
 - 48) Rivett D, Shirley D, Magarey M, et al.: APA clinical guidelines for assessing vertebrobasilar insufficiency in the management of cervical spine disorders, 2006. <https://www.scribd.com/doc/90011859/APA-VBI-Guidelines> (Accessed May 27, 2015)
 - 49) Arnold C, Bourassa R, Langer T, et al.: Doppler studies evaluating the effect of a physical therapy screening protocol on vertebral artery blood flow. *Man Ther*, 2004, 9: 13–21. [[Medline](#)] [[CrossRef](#)]
 - 50) Licht PB, Christensen HW, Højgaard P, et al.: Triplex ultrasound of vertebral artery flow during cervical rotation. *J Manipulative Physiol Ther*, 1998, 21: 27–31. [[Medline](#)]
 - 51) Li YK, Zhang YK, Lu CM, et al.: Changes and implications of blood flow velocity of the vertebral artery during rotation and extension of the head. *J Manipulative Physiol Ther*, 1999, 22: 91–95. [[Medline](#)] [[CrossRef](#)]
 - 52) Mitchell J, Keene D, Dyson C, et al.: Is cervical spine rotation, as used in the standard vertebrobasilar insufficiency test, associated with a measureable change in intracranial vertebral artery blood flow? *Man Ther*, 2004, 9: 220–227. [[Medline](#)] [[CrossRef](#)]
 - 53) Rossiti S, Volkmann R: Changes of blood flow velocity indicating mechanical compression of the vertebral arteries during rotation of the head in the normal human measured with transcranial Doppler sonography. *Arq Neuropsiquiatr*, 1995, 53: 26–33. [[Medline](#)] [[CrossRef](#)]
 - 54) Bowler N, Shamley D, Davies R: The effect of a simulated manipulation position on internal carotid and vertebral artery blood flow in healthy individuals. *Man Ther*, 2011, 16: 87–93. [[Medline](#)] [[CrossRef](#)]
 - 55) Haynes M, Milne N: Color duplex sonographic findings in human vertebral arteries during cervical rotation. *J Clin Ultrasound*, 2001, 29: 14–24. [[Medline](#)] [[CrossRef](#)]
 - 56) Quesnele JJ, Triano JJ, Noseworthy MD, et al.: Changes in vertebral artery blood flow following various head positions and cervical spine manipulation. *J Manipulative Physiol Ther*, 2014, 37: 22–31. [[Medline](#)] [[CrossRef](#)]
 - 57) Thiel H, Wallace K, Donat J, et al.: Effect of various head and neck positions on vertebral artery blood flow. *Clin Biomech (Bristol, Avon)*, 1994, 9: 105–110. [[Medline](#)] [[CrossRef](#)]
 - 58) Thomas LC, Rivett DA, Bateman G, et al.: Effect of selected manual therapy interventions for mechanical neck pain on vertebral and internal carotid arterial blood flow and cerebral inflow. *Phys Ther*, 2013, 93: 1563–1574. [[Medline](#)] [[CrossRef](#)]
 - 59) Thomas LC, McLeod LR, Osmotherly PG, et al.: The effect of end-range cervical rotation on vertebral and internal carotid arterial blood flow and cerebral inflow: a sub analysis of an MRI study. *Man Ther*, 2015, 20: 475–480. [[Medline](#)] [[CrossRef](#)]
 - 60) Childs JD, Flynn TW, Fritz JM, et al.: Screening for vertebrobasilar insufficiency in patients with neck pain: manual therapy decision-making in the presence of uncertainty. *J Orthop Sports Phys Ther*, 2005, 35: 300–306. [[Medline](#)] [[CrossRef](#)]
 - 61) Herzog W, Tang C, Leonard T: Internal carotid artery strains during high-speed, low-amplitude spinal manipulations of the neck. *J Manipulative Physiol Ther*, 2015, 38: 664–671. [[Medline](#)] [[CrossRef](#)]
 - 62) Wuest S, Symons B, Leonard T, et al.: Preliminary report: biomechanics of vertebral artery segments C1–C6 during cervical spinal manipulation. *J Manipulative Physiol Ther*, 2010, 33: 273–278. [[Medline](#)] [[CrossRef](#)]
 - 63) Côté P, Kreitz BG, Cassidy JD, et al.: The validity of the extension-rotation test as a clinical screening procedure before neck manipulation: a secondary analysis. *J Manipulative Physiol Ther*, 1996, 19: 159–164. [[Medline](#)]

- 64) Thiel H, Rix G: Is it time to stop functional pre-manipulation testing of the cervical spine? *Man Ther*, 2005, 10: 154–158. [[Medline](#)] [[CrossRef](#)]
- 65) Dunning J, Butts R, Juntilla U: Pre-manipulative testing prior to cervical manipulation: time to abandon the VBI test? 2015. <https://osteopractor.wordpress.com/2015/01/08/pre-manipulative-testing-prior-to-cervical-manipulation-time-to-abandon-the-vbi-test/>.
- 66) Symons BP, Leonard T, Herzog W: Internal forces sustained by the vertebral artery during spinal manipulative therapy. *J Manipulative Physiol Ther*, 2002, 25: 504–510. [[Medline](#)] [[CrossRef](#)]
- 67) Taylor AJ, Kerry R: A “system based” approach to risk assessment of the cervical spine prior to manual therapy. *Int J Osteopath Med*, 2010, 13: 85–93. [[Cross-Ref](#)]