

Washington University School of Medicine

Digital Commons@Becker

Open Access Publications

3-1-2018

**Wild-type transthyretin cardiac amyloidosis (ATTRwt-CA),
previously known as senile cardiac amyloidosis: Clinical
presentation, diagnosis, management and emerging therapies**

Iliia G. Halatchev

Jingsheng Zheng

Jiafu Ou

Follow this and additional works at: https://digitalcommons.wustl.edu/open_access_pubs

Wild-type transthyretin cardiac amyloidosis (ATTRwt-CA), previously known as senile cardiac amyloidosis: clinical presentation, diagnosis, management and emerging therapies

Ilia G. Halatchev^{1,2}, Jingsheng Zheng³, Jiafu Ou^{1,2}

¹Division of Cardiology, John Cochran Veterans Affairs Medical Center, St. Louis, USA; ²Division of Cardiology, Washington University School of Medicine, St. Louis, MO, USA; ³Department of Cardiology, AtlantiCare Regional Medical Center, Pomona, NJ, USA

Contributions: (I) Conception and design: All authors; (II) Administrative support: J Ou, J Zheng; (III) Provision of study materials or patients: IG Halatchev; (IV) Collection and assembly of data: IG Halatchev, J Ou; (V) Data analysis and interpretation: IG Halatchev, J Ou; (VI) Manuscript writing: All authors; (VII) Final approval of manuscript: All authors.

Correspondence to: Jingsheng Zheng, MD, PhD. Department of Cardiology, AtlantiCare Regional Medical Center, 65 W Jimmie Leeds Road, Pomona, NJ 08240, USA. Email: jszheng@comcast.net; Jiafu Ou, MD. Division of Cardiology, John Cochran Veterans Affairs Medical Center, 915 North Grand Boulevard, St. Louis, MO 63106, USA. Email: jou@wustl.edu.

Abstract: Cardiac amyloidosis is thought to be a rare group of diseases caused by extracellular deposition of misfolded proteins in the extracellular cardiac matrix resulting in heart failure with preserved ejection fraction (HFpEF). This review focuses on the similarities and differences between the pathophysiology, clinical presentation and diagnostic tests of wild-type transthyretin cardiac amyloidosis (ATTRwt-CA) compared to immunoglobulin light chain amyloidosis and hereditary cardiac amyloidosis. We address some obstacles to timely diagnosis and opportunities for management of the clinical symptoms as well as possibility of future novel disease modifying therapies.

Keywords: ATTRwt cardiac amyloidosis (ATTRwt-CA); heart failure with preserved ejection fraction (HFpEF); left ventricular hypertrophy (LVH); transthyretin; senile amyloidosis

Submitted Jan 12, 2018. Accepted for publication Mar 19, 2018.

doi: 10.21037/jtd.2018.03.134

View this article at: <http://dx.doi.org/10.21037/jtd.2018.03.134>

Clinical case

A 72-year-old male who presented with progressive dyspnea on exertion down to 100 feet. His prior cardiac history includes severe aortic stenosis for which he underwent bovine bioprosthetic aortic valve replacement. He also had a bypass graft with left internal mammary artery to left anterior descending artery at the time of aortic valve replacement. Patient further had atrial fibrillation and flutter for which he underwent direct current cardioversion. His other chronic condition has been hypertension (HTN) for which he was on β -blockers and angiotensin converting enzyme inhibitors (ACE-i) but had worsening fatigue, dyspnea and low blood pressures of 100/60 requiring cessation of their use. Of note, patient also has been treated for peripheral neuropathy, of unknown etiology, with diffuse

peripheral neuropathic pain and left focal ulnar neuropathy (at the elbow) as well as left carpal tunnel syndrome.

Based on the patient's clinical presentation and prior cardiac history, he was initially evaluated by electrocardiogram (EKG) which showed normal sinus rhythm with first degree atrioventricular (AV) block, right bundle branch block, and poor R-wave progression. A pharmacological stress test (exercise treadmill was attempted but patient became dyspneic after 20 seconds) with myocardial perfusion imaging showed normal myocardial perfusion with no evidence of stress induced ischemia. An echocardiography (Echo) showing normal left ventricular (LV) size with moderate hypertrophy, low normal systolic function and grade III diastolic dysfunction as well as apical sparing by longitudinal strain mapping

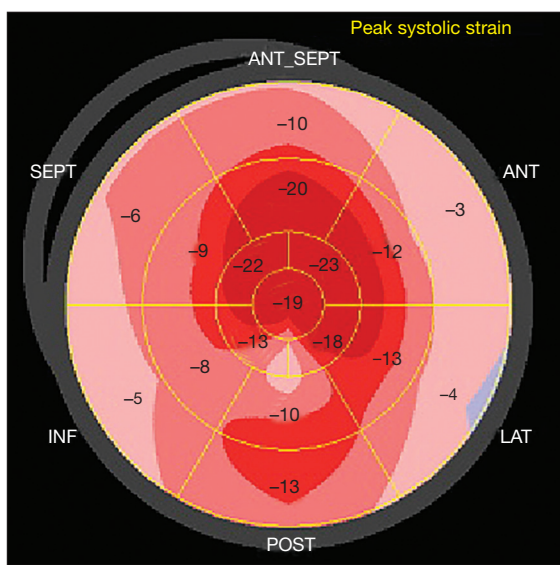


Figure 1 Longitudinal echocardiography strain depicted in bull's-eye map showing preserved apical strain with reduction of mid and basal strain that results in hallmark “cherry on the top” pattern, a characteristic strain finding for cardiac amyloidosis.

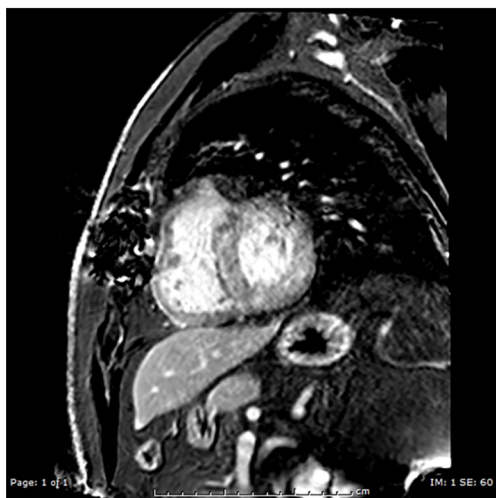

Figure 2 Characteristic late gadolinium enhancement with phase-sensitive inversion recovery sequence shows diffuse subendocardial enhancement that is evenly distributed throughout the left ventricular wall.

(*Figure 1*) and normal functioning bioprosthetic aortic valve. Brain natriuretic peptide was not obtained at that time as patient did not appear volume overloaded on exam and by Echo. Based on the clinical presentation of

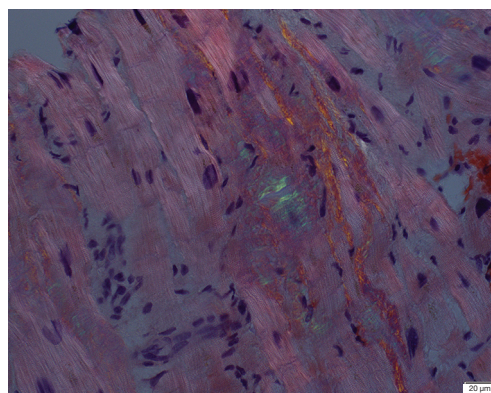


Figure 3 Polarized light histologic slide, at 400 \times magnification, showing apple-green birefringence in areas of Congo red stain bound to transthyretin amyloid deposit in the extracellular matrix of the myocardium. Of note, this should be distinguished from the white birefringence of collagen fibrosis, which is also seen in this figure.

β -blockers/ACE-i intolerance and peripheral neuropathies as well as normal stress test and Echo findings of moderate hypertrophy, grade III diastolic dysfunction and apical sparing by longitudinal strain mapping pattern it was suspected that patient may have infiltrative cardiac process contributing to his condition. This was further evaluated by cardiovascular magnetic resonance (CMR) showing diffuse subendocardial infiltration by gadolinium (*Figure 2*) and marked increase in T1 relaxation, which has consistent with likely infiltrative process such as cardiac amyloidosis. After discussion with patient, he wanted to proceed with endomyocardial biopsy (EMB) which showed positive Congo red staining with apple-green birefringence under polarized light (*Figure 3*) and mass spectroscopy analysis of deposited endocardial amyloid fibrils showing transthyretin with normal amino acid sequence. The final diagnosis was most consistent with wild-type transthyretin cardiac amyloidosis (ATTRwt-CA). After the diagnosis of ATTRwt-CA, the patient was offered to be evaluated for participation in several of the ongoing clinical trials, testing novel therapies for cardiac amyloidosis, but he declined. The patient has been treated with conservative management for the past few years, focused on symptomatic control.

Introduction and epidemiology

The incidence and prevalence of congestive heart failure (CHF) is increasing throughout the world, especially in

aging population (1). In US, it affected 5.7 million adults in 2016 (2), 16 million in EU in 2016 (<http://www.ahnheart.org>) and 4.2 million in China in 2011 (publication still pending from the China Heart Failure Registry Study in 2015) (3). There are three types of CHF: (I) LV ejection fraction (LVEF) of less than 40%, called heart failure with reduced EF (HFrEF); (II) LVEF of 40–50%, called heart failure with mid-range EF (HFmrEF); and (III) LVEF greater than 50% called heart failure with preserved EF (HFpEF). The epidemiology, pathophysiology and outcomes of HFmrEF are poorly understood due to limited studies. While, HFrEF has higher incidence and prevalence in males (4), with more than 60% caused by coronary artery disease (5), HFpEF is more common in women with incidence that increases with aging resulting in higher prevalence in older adults (4). The pathophysiologies of HFpEF are poorly understood and are likely to be due to numerous factors resulting in a heterogeneous patient population. It is possible that due to the heterogeneity in patient population and conditions contributing to HFpEF there have been numerous negative clinical trials aimed at potential treatment strategies (6).

Cardiac involvement of systemic amyloidosis is one of the causes of HFpEF. Systemic amyloidosis is thought to be a rare group of diseases, as it is likely underdiagnosed, and is characterized by progressive tissue infiltration of insoluble fibrillar proteins resulting in extracellular architecture disruption that causes organ dysfunction. There are three main types of systemic amyloidosis that are known to cause cardiac dysfunction and are identified by the amyloid fibril protein deposited in the heart, namely; (I) immunoglobulin light chain (AL) amyloidosis, (II) ATTRwt-CA, previously known as senile cardiac amyloidosis; and (III) a mutated ATTR causing hereditary cardiac amyloidosis (ATTRm-CA). AL amyloidosis is most commonly diagnosed amyloidosis due to the dysfunction it causes to organs, other than the heart, by the amyloid light chain deposition. The diagnosis of ATTRm and ATTRwt cardiac amyloidosis is more elusive as the clinical presentation and severity of organ dysfunction is gradual and variable. Studies have shown that 10–25% of patients with HFpEF have LV ATTRwt deposition at the time of autopsy (7–9). In this review, our aim was to summarize the main pathophysiologic changes caused by ATTRwt amyloidosis, their clinical presentation and diagnostic evaluation. The early identification and diagnosis of this condition can result in better current symptomatic management and identification of novel emerging therapies aimed at

altering the progression and hopefully the prognosis of this condition.

Pathophysiology and clinical features

ATTRwt-CA is likely significantly underdiagnosed. Although it thought to affect 10–25% of patients with HFpEF, suggesting a high prevalence in the elderly population, there are less than 100 cases annually at the National Amyloidosis Center in UK (10) resulting in limited understanding of the natural history of the disease due to small patient cohorts. The reason for the low diagnostic rate is likely due to the nature of the disease pathophysiology that results in a subtle clinical presentation in an elderly population who also has frequent comorbid conditions and the belief that diagnosis will not affect the patients' outcomes.

In contrast to other forms of amyloidosis, ATTRwt-CA almost exclusively causes clinically evident pathophysiology to the heart and the peripheral nerves as well as non-clinically relevant deposits in the liver and lungs. The cardiac manifestations of amyloid wild-type amyloid proteins deposition are LV hypertrophy (LVH) with increased filling pressure and the “typical” HFpEF with symptoms of breathlessness, reduced exercise tolerance, fatigue, lower extremities/abdominal swelling, early satiety and erectile dysfunction. However, the constellation of these cardiac signs and symptoms are very similar to other conditions affecting the ATTRwt-CA patient population of mostly males who are often greater than 65 years of age (11), such as HTN, coronary artery disease, aortic stenosis, diabetes, arrhythmias, obstructive sleep apnea and/or obesity. Hypertrophic cardiomyopathy or hypertensive heart disease are also close mimickers of ATTRwt-CA clinically and by traditional Echo imaging findings, leading to frequent misdiagnosis (12). Additionally, patients at that age group often have concomitant monoclonal gammopathy of undetermined significance (MGUS) (13) and the extracardiac ATTRwt deposition results in bilateral carpal tunnel syndrome (14) that precedes cardiac manifestations leading to evaluations by non-cardiovascular specialists and delay from definitive diagnosis.

High index of suspicion is necessary for the timely diagnosis and treatment of ATTRwt-CA. The key factors that may help increase the sensitivity for diagnosis of ATTRwt-CA are: LVH without presence of prior history of severe or uncontrolled HTN, new onset of hypotension, inability to tolerate ACE-i or β -blockers, atrial

arrhythmias (15,16), AV nodal dysfunction (13) requiring permanent pacemakers and the presence of bilateral carpal tunnel syndromes (14) and/or spinal stenosis. Right heart failure symptoms are also associated with ATTRwt-CA with persistently elevated internal jugular veins, hepatic congestion, ascites, abdominal bloating with early satiety and chronic lower extremity edema.

Diagnosis

The definitive diagnosis of ATTRwt-CA is made by histology of cardiac biopsy and subsequent genotyping. However, EMB is an invasive procedure with associated potential risks and is not readily available in many centers. There are several non-invasive testing modalities that have variable sensitivities and specificities for the diagnosis of ATTRwt-CA, including EKG, biomarkers, Echo, scintigraphy, CMR, as well as liver and fat pat biopsies that should be discussed.

EKG

EKG is one of the oldest, best described and most widely used cardiac diagnostic modalities worldwide. However, its use as diagnostic tool for ATTRwt-CA has likely lead to falsely reduced clinical suspicion and its underdiagnoses of the disease. This is largely from the “classical” teaching which dictates that cardiac amyloidosis is associated with low voltage (defined as ≤ 5 mV amplitude in the limb leads or ≤ 10 mV amplitude in the precordial leads) despite the presence of LVH and comes from studies of AL amyloid (16,17). In recent ATTRwt-CA studies, low voltage has been found to have poor independent sensitivity (~30%) for its diagnosis (18,19).

There are numerous other EKG findings that are seen in patients with ATTRwt-CA but have low sensitivity and specificity for the disease because they are also common in age and comorbidities matched patient cohorts: (I) 38–63% have pseudoinfarct pattern (17,19); (II) 34% have poor R-wave progression (19); (III) 16–80% have atrial fibrillation (15,18); (IV) 21% have first degree AV block (20); and (V) 16% have nonspecific ST-T-wave abnormalities (20). Left bundle branch block can be potentially useful to differentiate ATTRwt-CA and AL-CA as it occurs in 40% *vs.* 4%, respectively (14).

Voltage-to-mass ratio, calculated by sum of S wave in lead V1 plus R wave in lead V5 or V6 (SV1 + RV5 or V6) divided by the echocardiographic muscle cross-

sectional area (21), has been shown to have high sensitivity and specificity for ATTRwt-CA (14) as compared to ATTRm-CA, AL-CA and other age related cardiac conditions. Additionally, patients with HTN or LVH usually have normal or increased EKG voltage while patients with tamponade, pericardial effusion or emphysema usually have low EKG voltages with normal LV mass (21).

Echo

Echo is the most frequently used noninvasive imaging test for evaluation of suspected cardiomyopathies, like ATTRwt-CA, as it provides both structural and functional information with minimal risk to the patient. Two-dimensional (2D) imaging, pulse wave and tissue Doppler velocities findings in ATTRwt-CA by Echo are similar to other forms of amyloidosis and other causes of HFpEF, like HTN, obesity, hypertrophic cardiomyopathy, Fabry’s disease and aortic stenosis.

The most common 2D finding in cardiac amyloidosis is the presence of increased left ventricular thickness or LVH, however, unlike the other forms of HFpEF mentioned above, the LVH associated with cardiac amyloidosis is not due to cardiac myocyte hypertrophy but rather due to amyloid fibrils deposited in the extracellular matrix. The increase in LV wall thickness associated with ATTRwt-CA is significantly greater than either AL (13) and ATTRm-CA (14). Another 2D finding that is associated with extracellular deposition of amyloid fibrils is a visually discernable “speckled” or granular “sparkling” texture appearance that seen by initial Echo machines, however, it is now less evident with modern echocardiographic machines due to almost exclusive use of harmonic frequency imaging.

Diastolic dysfunction with preserved EF is a hallmark of cardiac amyloidosis by Echo. It is characterized by the evidence of grade I–II mitral valve inflow Doppler patterns with concomitant reduction of S’ and e’ tissue Doppler velocities at the basal septal and lateral walls and impaired systolic dysfunction assessed by myocardial strain (22,23) at the early stages of the disease. Forty percent of ATTRwt-CA of patients have moderate LV systolic dysfunction compared to 8–22% patients with ATTRm-CA and AL-CA (14). At the later stages, ATTRwt-CA patients develop severe diastolic dysfunction characterized by grade III mitral valve inflow pattern associated with very low S’/e’ velocities, and eventually reduction of EF (24). In fact, the development of systolic dysfunction may be present with preserved EF and predictive of poor outcomes in patients with cardiac

amyloidosis, measured by a reduction of myocardial contraction fraction (MCF), which is the calculated stroke volume divided by myocardial volume (25). Other non-specific findings with ATTRwt-CA are: (I) biatrial enlargement; (II) thickening of the mitral/aortic leaflets and intra-atrial septum; (III) small pericardial effusion; (IV) moderate pulmonary HTN; and (V) intracardiac thrombus (22,26).

Advanced echocardiographic techniques, such as strain and strain rate imaging, have shown promise to help differentiate cardiac amyloidosis from hypertrophic cardiomyopathy or other causes of LVH. Strain and strain rate are echocardiographic techniques that use vendor specific proprietary software to track the longitudinal shortening of speckles within the 2D image of the left ventricular wall during systole and are quickly becoming clinically readily available. With all forms of cardiac amyloidosis, there is much greater restriction of basal speckle longitudinal movement compared to apical movement resulting in a relative 'apical sparing' pattern of longitudinal strain with bulls-eye plot (*Figure 1*) (27). Furthermore, Pagourelis *et al.* reported that EF global longitudinal strain ratio (EFSR), calculated by ratio of left ventricular EF and global longitudinal strain, had nearly 90% sensitivity and 92% specificity for all form of cardiac amyloidosis in the challenging subgroups with left ventricular wall thickness <16 mm with preserved EF (28).

Cardiac biomarkers

Brain natriuretic peptide (BNP), N-terminal fragment of BNP (NT-proBNP) and cardiac troponins have been widely used to help with diagnosis, monitor treatment and prognostic evaluation both HF_rEF and HF_pEF. Elevation of NT-proBNP above >82 pg/mL has been shown to have sensitivity of 92% and specificity of 90% for presence of left ventricular abnormalities in patients with familial mutation in ATTR thus could be used as a potential screening test to initiate workup for ATTRm-CA (29). This observation may translate to patients with ATTRwt-CA in whom the log of BNP has been shown to have direct correlation with left ventricular thickness (30). Increasing serum levels of BNP, NT-proBNP and troponins were shown to have progressive correlation with disease severity and worse outcomes at increasing levels in patients with ATTRwt-CA (31). Furthermore, monitoring of these cardiac biomarkers is being employed to monitor treatment in ongoing clinical trials using disease modifying approaches for the

treatment of ATTR cardiac amyloidosis (see "investigational medications" section later in the article).

Nuclear imaging

Nuclear imaging has emerged as important non-invasive tool in the diagnosis of suspected ATTR cardiac amyloidosis due to wide availability at a low cost, having few contraindications and the capacity to differentiate from other cardiomyopathies. Bone-avid tracers, like ^{99m}Tc-DPD (technetium-3,3-diphosphono-1,2-propanodicarboxylic acid), ^{99m}Tc-PYP (technetium-pyrophosphate) and ^{99m}Tc-HMDP [technetium-hydroxymethylene diphosphonate (Tc-HMDP)] have been shown to have high sensitivity and specificity for differentiating patients with ATTR CA, irrespective of genotype, from patients with AL-CA or others with HF_pEF (32-37). The exact mechanism by which these radiotracers differentially accumulate in myocardium is not completely clear but may be due to differences in deposited amyloid proteins (38,39), higher calcium levels seen during the repair process (40) and/or higher degree of tissue microcalcifications in ATTR compared to AL cardiac amyloidosis (41). Irrespective of the mechanism, an international consensus document has confirmed that the combination of grade 2 or 3 cardiac uptake on a bone-avid tracer scan in the setting of absent monoclonal protein by serum immunofixation electrophoresis (IFE), urine IFE, and serum free light chain assay is diagnostic of ATTR cardiac amyloidosis as compared to AL-CA or other wall thickening diseases (42). Bokhari *et al.* (37) described a standardized imaging protocol using ^{99m}Tc-PYP to diagnose ATTR CA using Heart/Contralateral ratio ≥ 1.5 . Nuclear imaging with ^{99m}Tc-DPD (43) and ^{99m}Tc-PYP (44) can diagnose the presence of cardiac involvement prior to any overt echocardiographic abnormalities and can predict major adverse cardiac events (34,35,39,43). Future studies are needed to establish the role of bone-avid nuclear tracers for the early identification of ATTRwt-CA, differentiating it from ATTRm-CA (confirmed by genetic testing) and evaluation of subsequent outcomes.

Scintigraphy imaging, which is inherently qualitative, falls short of being able to quantify the radioactivity at the affected sites thus cannot be used in assessing disease burden and response to therapy. Positron emission tomography (PET) is a nuclear modality that can circumvent this problem, emerging as a promising tool in the monitoring and management of cardiac amyloidosis. Recently discovered

amyloid binding PET tracers 18-F florbetapir (45,46) and 11C-Pittsburgh compound B (PiB) (47,48) can identify both AL and ATTR cardiac amyloidosis. Case reports have shown cardiac uptake of another PET tracer [18F]-sodium fluoride only in patients with ATTRwt-CA and ATTRm-CA, but not in ones with AL-CA (49,50).

Cardiovascular magnetic resonance

CMR is an important diagnostic and prognostic tool for cardiac amyloidosis. Various techniques utilizing different tissue imaging timing, with and/or without gadolinium contrast, and strain can provide detailed information about the presence, location, and distribution of hypertrophy, as well as cardiac function. One major drawback of using CMR is that gadolinium contrast is contraindicated in patients with moderate to severe kidney disease.

T1 sequence of CMR, a composite measure of extracellular matrix and myocardial cells, with the use of gadolinium can help differentiate extracellular tissue thickening due to myocardial hypertrophy *vs.* extracellular deposition. Utilizing pre- and post-contrast T1 mapping, extracellular volume (ECV) can be calculated and is a direct measurement of the cardiac interstitium (51). ECV expansion can detect amyloid fibrils infiltration in AL and ATTR cardiac amyloidosis earlier than conventional testing and is quantitative marker of the amyloid burden lending itself with the potential use in early diagnosis and disease monitoring (52,53). Marked increased non-contrast T1 relaxation times also seen in patients who have interstitial infiltration by amyloid fibrils and has good correlation with disease severity, future prognosis, and the potential to track changes over time (from natural progression or disease modifying therapy) (54-56). One of the major advantages of T1 mapping is that it does not require contrast which is contraindicated in advanced kidney disease, however, currently this technique has limited clinical availability due to technical challenges related to sequence- and vendor-specific differences (57,58).

The myocardial deposition of amyloid fibrils in ATTR-CA increases ECV which serves as a reservoir for gadolinium accumulation leading to characteristic continuum of late gadolinium enhancement (LGE) (59). In the early stages of the disease there usually is no LGE enhancement that progresses to subendocardial and finally transmural (in non-ischemic pattern) LGE enhancement at the late stages (*Figure 2*), which also tracks with increasing ECV and a worse prognosis (58,60). In contrast, a diffuse-

subendocardial patterns is most commonly described in AL-CA disease (58,60), which has led to CMR based LGE scoring system that seems to differentiate between ATTR and AL cardiomyopathies (61). Future studies are necessary to establish similarities and differences between the LGE in patients with ATTRm-CA and ATTRwt-CA.

Traditional LGE imaging technique depends on normal myocardium to enhance the diseased area and has been limited in ATTR-CA due to difficult nulling, which have led to early and advanced disease misclassification. Phase-sensitive inversion recovery (PSIR) sequence that reduces the need for an optimal null point setting [initially described CMR evaluation of myocardial infarction (62)] makes LGE assessment in cardiac amyloidosis faster and operator-independent (58).

Feature tracking software applied to cine CMR datasets for assessment of left ventricular strain has shown good agreement between CMR and 2D Echo-derived myocardial longitudinal strain measurements (63) with apical sparing in longitudinal strain (64).

Histopathological diagnosis

EMB with histopathology remains the gold standard for diagnosis of cardiac amyloidosis by showing deposition of amorphous deposits of amyloid fibrils in the heart. The binding of Congo red stain to the deposited amyloid fibrils leads to characteristic apple-green birefringence under polarized light microscopy (*Figure 3*) and an intense yellow-green fluorescence is seen when binding to thioflavin (image not shown). Precursor protein identification can be accomplished by immunohistochemistry, electron microscopy, or mass spectrometry (preferred), depending upon institutional expertise. Fat pat biopsy with Congo red staining has sensitivity of 70-90% for diagnosis of systemic AL amyloidosis (65,66), but only 45% and 15% sensitivity for diagnosis of ATTRm-CA and ATTRwt-CA respectively (67). Adjunctive laboratory tests to rule out AL include assaying for other organ dysfunction (e.g., proteinuria, alkaline phosphatase) and directly measuring the circulating light chains in plasma.

EMB is an invasive procedure that is associated with risks of complications including ventricular free-wall perforation of up to 0.4%, arrhythmia 0.5-1.0%, conduction abnormalities 0.2-0.4% (68) and requires expertise that is not readily available in many centers. With recent advance in Echo, CMR and nuclear imaging, multiple diagnostic

algorithms have been proposed for patients with suspected ATTRwt-CA (12,42,59,69,70).

Genetic testing

Once diagnosis of ATTR is confirmed via EMB with histology, it is important to offer DNA sequencing for the transthyretin gene (especially in clinical research studies) since the presence of a pathologic mutation can affect clinical trial options, predict sites of organ involvement, and have relevance for family members. The absence of amino acid sequence abnormalities by mass spectrometry is consistent with ATTRwt-CA, although mass spectrometry cannot detect all transthyretin mutations.

Treatment

Limitations in treatment due to insufficient evidence-based approaches

While there are great advances in the treatment of AL amyloidosis by chemotherapy (71,72) and emerging new therapies for ATTRm-CA aimed at the reduction of mutant gene expression (73), TTR tetramer stabilization (74,75) and dissolution (76), currently there are no proven curative or disease modifying therapies for ATTRwt-CA. There are several possible reasons why ATTRwt-CA does not have any proven therapies: (I) it is a underrecognized and underdiagnosed leading to small patient cohorts to study and incomplete understanding of its natural history of the disease (13); (II) the disease presents late in life with multitude of age related comorbidities and mortality (13,14); and (III) the disease process is likely gradual thus curative or disease modifying therapeutic effects are difficult to measure (13). Consequently, most of the therapeutic considerations for ATTRwt-CA are based on expert opinion and observations from therapeutic effects on the other type of amyloidosis affecting the heart.

Symptomatic relief and supportive care

The mainstay of therapy is supportive care aimed at symptomatic relief. The main symptoms of patients with ATTRwt-CA are congestion, fatigue, peripheral nerve pain, and hypotension. Relief of congestive symptoms and associated fatigue can be accomplished with the use of diuretics, including loop diuretics and thiazides in combination with mineralocorticoid receptor antagonist

to help with potassium reabsorption. Diuretics should be used sparingly as these patients are preload dependent due to high filling pressures and can be used with weight-based parameters. Other medications typically used in cardiomyopathies, such as β -blockers, ACE-i and angiotensin receptor blockers (ARB), do not seem to modify the disease progression and often result in worsening fatigue and hypotension. B-blockers are usually not tolerated as they can reduce the inotropy of the heart resulting in decreased stroke volume and have a maladaptive blunting of chronotropy on which ATTRwt-CA patients rely for augmentation of their cardiac output. ACE-i and ARB medications often worsen hypotension in ATTRwt-CA patients due pre-existing peripheral neuropathy affecting the autonomic nervous system of these patients. Hypotension can be managed with α -1 blocker midodrine and compression stockings.

Atrial arrhythmias

The symptoms associated with ATTRwt-CA are further exacerbated by atrial arrhythmias which are frequently associated with the condition (15). Rate control is difficult in these patients as β -blockers can worsen hypotension at higher doses, calcium channel blockers are contraindicated as they bind to the amyloid fibrils causing sustained worsening of CHF (77-79) and digoxin can cause cardiac toxicity due to progressive accumulation in the amyloid rich heart despite normal serum levels (80). Antiarrhythmic medications, such as amiodarone, can be used for rhythm control as patients are older and is overall well tolerated because it is usually not associated with deleterious hemodynamic changes. Symptomatic relief from atrial arrhythmias has been reported in a small cohort of ATTRwt-CA patients with catheter ablation (81). However, catheter ablation for atrial arrhythmias have high recurrence rate, necessitating AV ablation with permanent pacemaker placement in refractory cases.

Investigational medications

Currently there are no known curative or disease modifying agents for the treatment of ATTRwt-CA. However, there are several investigational medications that may have the potential to modify or even reverse the disease process. The strategies employed are ATTR disruption to reduced amyloid fibril aggregation, ATTR destabilization, and ATTR suppression. The combination of bile acid

tauroursodeoxycholic acid (TUDCA) and doxycycline have been shown to reduce ATTR aggregation in a mouse model of TTR V30M transgenic mouse model (82) as well as to be tolerated in a phase II clinical trial (75) and currently being evaluated [with un-reported results from a phase III clinical trial (clinicaltrials.gov; NCT01855360)]. Tafamidis meglumine, a ATTR destabilizing agent has been shown to reduce the progression of peripheral neuropathy in patients with TTR V30M TTRm-CM with ongoing clinical trials to evaluate its long-term cardiac effects in ATTRm as well as ATTRwt cardiomyopathies (clinicaltrials.gov; NCT00935012 and NCT02791230). Patisiran is a siRNA, inhibiting ATTR mRNA translation, which has shown significant reduction of serum ATTR levels when administered intravenously in patients with familial amyloid polyneuropathy in a phase II clinical trial (83) with an ongoing long-term clinical trial in patients with familial ATTR (clinicaltrials.gov; NCT01960348).

Permanent pacemaker and defibrillator implantation

Cardiac infiltration with amyloid fibrils can precipitate conduction system abnormalities, like bundle branch blocks and AV node dysfunction (84). A significant portion of patients with ATTRwt-CA have pacemakers at the time of diagnosis or have one implanted for high degree AV block (13). ACC/AHA guidelines suggest a case by case consideration for implantable cardioverter-defibrillator (ICD) implantation in patients for primary and secondary prevention due to limited clinical trials to show associated outcomes (85).

Advanced therapies: left ventricular assist devices (LVAD) and heart transplantation

ATTRwt-CA patients have advanced heart failure symptoms and reduced life expectancy, findings which may qualify them to be considered for advanced heart failure options such as LVAD and/or heart transplantation. In a small single center report of 9 patients, LVAD implantation is technically feasible for ATTRwt-CA but it was associated with higher 24-month mortality and morbidity compared to other indications for LVAD implantation (86). A review of the Interagency Registry for Mechanically Assisted Circulatory Support (INTERMACS) database is necessary to be able to better evaluate outcomes of LVAD implantation for ATTRwt-CA. Patients with ATTRwt-CA are usually not considered for heart transplantation due to their advanced disease presentation, age, and

associated comorbidities. Indeed, in a literature review there was a single case report found of a 68-year-old patient who underwent heart transplantation for biopsy proven ATTRwt-CA who was reported to have a good 3-year outcome (87,88).

Conclusions

Cardiac amyloidosis is a group of diseases caused by extracellular deposition of misfolded proteins. ATTRwt-CA is currently thought to have lowest prevalence among the different types of systemic amyloidosis, which is likely due to a low incidence from underdiagnosis, as it is found in 10–25% of all patients with HFpEF on autopsy studies. High clinical suspicion is necessary to initiate discussion with the affected patient about the risk, cost and benefit of early diagnosis and potential management, both of which often requiring a referral to a tertiary center. The total cost of testing, including EKG, Echo, CMR, and EMB is \$5,000 to \$15,000 (the variable cost to the patient) with the potential risks inherent to of each procedure. However, as in many rare or underdiagnosed conditions, an accurate diagnosis and appropriate level of follow up is needed to increase the patients able to participate in goal directed therapies and improve our understanding of the disease process as well as future possible treatments. Patients with signs and symptoms of heart failure (especially right sided symptoms), LVH out of proportion of duration and severity of HTN, arrhythmias, bundle branch blocks, have extracardiac manifestations of carpal tunnel syndrome and show intolerance to common cardiac medications should be evaluated for presence of ATTRwt-CA. Initial, diagnostic evaluation the highest sensitivity followed by ones with highest specificity should be performed to help diagnoses ATTRwt-CA: (I) Echo strain patterns with characteristic apical sparing and reduction of ratio of stroke volume to myocardial volume; (II) quantitative and qualitative characterization by nuclear scintigraphy; and (III) CMR tissue characterization with LGE, ECV and T1 mapping. Only if those non-invasive modalities are highly suggestive of ATTRwt-CA, EMB, followed by genetic testing should be performed as the diagnostic gold standard as it is not readily available and is invasive. Once patients are diagnosed to have ATTRwt-CA clinical consideration should be taken to adjust their medical therapy to best support their unique pathophysiology and patients should be considered to participate in the ongoing or upcoming clinical trials testing possible novel disease modifying therapies.

Acknowledgements

We thank Dr. Nadeem Parker for providing the CMR images and Dr. Ian Hagemann for the pathologic picture. We also thank Dr. Abhinav Diwan for the critical review of our manuscript.

Footnote

Conflicts of Interest: The authors have no conflicts of interest to declare.

References

- Chen WW, Gao RL, Liu LS, et al. China cardiovascular diseases report 2015: a summary. *J Geriatr Cardiol* 2017;14:1-10.
- Writing Group Members, Mozaffarian D, Benjamin EJ, et al. Heart Disease and Stroke Statistics-2016 Update: A Report From the American Heart Association. *Circulation* 2016;133:e38-360.
- Li H, Ge J. Cardiovascular diseases in China: Current status and future perspectives. *Int J Cardiol Heart Vasc* 2014;6:25-31.
- Dunlay SM, Roger VL, Redfield MM. Epidemiology of heart failure with preserved ejection fraction. *Nat Rev Cardiol* 2017;14:591-602.
- He J, Ogden LG, Bazzano LA, et al. Risk factors for congestive heart failure in US men and women: NHANES I epidemiologic follow-up study. *Arch Intern Med* 2001;161:996-1002.
- Gladden JD, Linke WA, Redfield MM. Heart failure with preserved ejection fraction. *Pflugers Arch* 2014;466:1037-53.
- Mohammed SF, Mirzoyev SA, Edwards WD, et al. Left Ventricular Amyloid Deposition in Patients With Heart Failure and Preserved Ejection Fraction. *JACC Heart Fail* 2014;2:113-22.
- Cornwell GG, Murdoch WL, Kyle RA, et al. Frequency and distribution of senile cardiovascular amyloid. A clinicopathologic correlation. *Am J Med* 1983;75:618-23.
- González-López E, Gallego-Delgado M, Guzzo-Merello G, et al. Wild-type transthyretin amyloidosis as a cause of heart failure with preserved ejection fraction. *Eur Heart J* 2015;36:2585-94.
- Patel KS, Hawkins PN. Cardiac amyloidosis: where are we today? *J Intern Med* 2015;278:126-44.
- Ruberg FL, Appelbaum E, Davidoff R, et al. Diagnostic and Prognostic Utility of Cardiovascular Magnetic Resonance Imaging in Light-Chain Cardiac Amyloidosis. *Am J Cardiol* 2009;103:544-9.
- Aljaroudi WA, Desai MY, Tang WH, et al. Role of imaging in the diagnosis and management of patients with cardiac amyloidosis: state of the art review and focus on emerging nuclear techniques. *J Nucl Cardiol* 2014;21:271-83.
- Pinney JH, Whelan CJ, Petrie A, et al. Senile systemic amyloidosis: clinical features at presentation and outcome. *J Am Heart Assoc* 2013;2:e000098.
- Rapezzi C, Merlini G, Quarta CC, et al. Systemic cardiac amyloidoses: disease profiles and clinical courses of the 3 main types. *Circulation* 2009;120:1203-12.
- Röcken C, Peters B, Juenemann G, et al. Atrial amyloidosis: an arrhythmogenic substrate for persistent atrial fibrillation. *Circulation* 2002;106:2091-7.
- Kyle RA, Spittell PC, Gertz MA, et al. The premortem recognition of systemic senile amyloidosis with cardiac involvement. *Am J Med* 1996;101:395-400.
- Damy T, Maurer MS, Rapezzi C, et al. Clinical, ECG and echocardiographic clues to the diagnosis of TTR-related cardiomyopathy. *Open Heart* 2016;3:e000289.
- Cyrille NB, Goldsmith J, Alvarez J, et al. Prevalence and prognostic significance of low QRS voltage among the three main types of cardiac amyloidosis. *Am J Cardiol* 2014;114:1089-93.
- González-López E, Gagliardi C, Dominguez F, et al. Clinical characteristics of wild-type transthyretin cardiac amyloidosis: disproving myths. *Eur Heart J* 2017;38:1895-904.
- Murtagh B, Hammill SC, Gertz MA, et al. Electrocardiographic findings in primary systemic amyloidosis and biopsy-proven cardiac involvement. *Am J Cardiol* 2005;95:535-7.
- Carroll JD, Gaasch WH, McAdam KP. Amyloid cardiomyopathy: characterization by a distinctive voltage/mass relation. *Am J Cardiol* 1982;49:9-13.
- Tsang W, Lang RM. Echocardiographic Evaluation of Cardiac Amyloid. *Curr Cardiol Rep* 2010;12:272-6.
- Bellavia D, Pellikka PA, Abraham TP, et al. Evidence of impaired left ventricular systolic function by Doppler myocardial imaging in patients with systemic amyloidosis and no evidence of cardiac involvement by standard two-dimensional and Doppler echocardiography. *Am J Cardiol* 2008;101:1039-45.
- Mohty D, Damy T, Cosnay P, et al. Cardiac amyloidosis: updates in diagnosis and management. *Arch Cardiovasc Dis* 2013;106:528-40.

25. Tendler A, Helmke S, Teruya S, et al. The myocardial contraction fraction is superior to ejection fraction in predicting survival in patients with AL cardiac amyloidosis. *Amyloid* 2015;22:61-6.
26. Feng D, Syed IS, Martinez M, et al. Intracardiac thrombosis and anticoagulation therapy in cardiac amyloidosis. *Circulation* 2009;119:2490-7.
27. Phelan D, Collier P, Thavendiranathan P, et al. Relative apical sparing of longitudinal strain using two-dimensional speckle-tracking echocardiography is both sensitive and specific for the diagnosis of cardiac amyloidosis. *Heart* 2012;98:1442-8.
28. Pagourelas ED, Mirea O, Duchenne J, et al. Echo Parameters for Differential Diagnosis in Cardiac Amyloidosis: A Head-to-Head Comparison of Deformation and Nondeformation Parameters. *Circ Cardiovasc Imaging* 2017;10:e005588.
29. Damy T, Deux JF, Moutereau S, et al. Role of natriuretic peptide to predict cardiac abnormalities in patients with hereditary transthyretin amyloidosis. *Amyloid* 2013;20:212-20.
30. Usuku H, Obayashi K, Shono M, et al. Usefulness of plasma B-type natriuretic peptide as a prognostic marker of cardiac function in senile systemic amyloidosis and in familial amyloidotic polyneuropathy. *Amyloid* 2013;20:251-5.
31. Kristen AV, Maurer MS, Rapezzi C, et al. Impact of genotype and phenotype on cardiac biomarkers in patients with transthyretin amyloidosis - Report from the Transthyretin Amyloidosis Outcome Survey (THAOS). *PLoS One* 2017;12:e0173086.
32. Perugini E, Guidalotti PL, Salvi F, et al. Noninvasive Etiologic Diagnosis of Cardiac Amyloidosis Using 99m Tc-3,3-Diphosphono- 1,2-Propanodicarboxylic Acid Scintigraphy. *J Am Coll Cardiol* 2005;46:1076-84.
33. Rapezzi C, Quarta CC, Guidalotti PL, et al. Usefulness and limitations of 99mTc-3,3-diphosphono-1,2-propanodicarboxylic acid scintigraphy in the aetiological diagnosis of amyloidotic cardiomyopathy. *Eur J Nucl Med Mol Imaging* 2011;38:470-8.
34. Castano A, Haq M, Narotsky DL, et al. Multicenter Study of Planar Technetium 99m Pyrophosphate Cardiac Imaging: Predicting Survival for Patients With ATTR Cardiac Amyloidosis. *JAMA Cardiol* 2016;1:880-9.
35. Vranian MN, Sperry BW, Hanna M, et al. Technetium pyrophosphate uptake in transthyretin cardiac amyloidosis: Associations with echocardiographic disease severity and outcomes. *J Nucl Cardiol* 2017. [Epub ahead of print].
36. Cappelli F, Gallini C, Di Mario C, et al. Accuracy of 99mTc-Hydroxymethylene diphosphonate scintigraphy for diagnosis of transthyretin cardiac amyloidosis. *J Nucl Cardiol* 2017. [Epub ahead of print].
37. Bokhari S, Morgenstern R, Weinberg R, et al. Standardization of 99mTechnetium pyrophosphate imaging methodology to diagnose TTR cardiac amyloidosis. *J Nucl Cardiol* 2018;25:181-90.
38. Bokhari S, Castaño A, Pozniakoff T, et al. 99mTc-pyrophosphate scintigraphy for differentiating light-chain cardiac amyloidosis from the transthyretin-related familial and senile cardiac amyloidoses. *Circ Cardiovasc Imaging* 2013;6:195-201.
39. Kristen AV, Haufe S, Schonland SO, et al. Skeletal scintigraphy indicates disease severity of cardiac involvement in patients with senile systemic amyloidosis. *Int J Cardiol* 2013;164:179-84.
40. Janssen S, Piers DA, van Rijswijk MH, et al. Soft-tissue uptake of 99mTc-diphosphonate and 99mTc-pyrophosphate in amyloidosis. *Eur J Nucl Med* 1990;16:663-70.
41. Stats MA, Stone JR. Varying levels of small microcalcifications and macrophages in ATTR and AL cardiac amyloidosis: implications for utilizing nuclear medicine studies to subtype amyloidosis. *Cardiovasc Pathol* 2016;25:413-7.
42. Gillmore JD, Maurer MS, Falk RH, et al. Nonbiopsy diagnosis of cardiac transthyretin amyloidosis. *Circulation* 2016;133:2404-12.
43. Rapezzi C, Quarta CC, Guidalotti PL, et al. Role of 99mTc-DPD Scintigraphy in Diagnosis and Prognosis of Hereditary Transthyretin-Related Cardiac Amyloidosis. *JACC Cardiovasc Imaging* 2011;4:659-70.
44. Haq M, Pawar S, Berk JL, et al. Can 99m Tc-Pyrophosphate Aid in Early Detection of Cardiac Involvement in Asymptomatic Variant TTR Amyloidosis? *JACC Cardiovasc Imaging* 2017;10:713-4.
45. Dorbala S, Vangala D, Semer J, et al. Imaging cardiac amyloidosis: a pilot study using 18F-florbetapir positron emission tomography. *Eur J Nucl Med Mol Imaging* 2014;41:1652-62.
46. D'Estaque E, Chambert B, Moranne O, et al. 18F-Florbetaben: A New Tool for Amyloidosis Staging? *Clin Nucl Med* 2017;42:50-3.
47. Lee SP, Lee ES, Choi H, et al. 11C-Pittsburgh B PET imaging in cardiac amyloidosis. *JACC Cardiovasc Imaging* 2015;8:50-9.
48. Antoni G, Lubberink M, Estrada S, et al. In vivo

- visualization of amyloid deposits in the heart with ¹¹C-PIB and PET. *J Nucl Med* 2013;54:213-20.
49. Morgenstern R, Yeh R, Castano A, et al. (18)Fluorine sodium fluoride positron emission tomography, a potential biomarker of transthyretin cardiac amyloidosis. *J Nucl Cardiol* 2017. [Epub ahead of print].
 50. Van Der Gucht A, Galat A, Rosso J, et al. [18F]-NaF PET/CT imaging in cardiac amyloidosis. *J Nucl Cardiol* 2016;23:846-9.
 51. Mongeon F-P, Jerosch-Herold M, Coelho-Filho OR, et al. Quantification of extracellular matrix expansion by CMR in infiltrative heart disease. *JACC Cardiovasc Imaging* 2012;5:897-907.
 52. Martinez-Naharro A, Treibel TA, Abdel-Gadir A, et al. Magnetic Resonance in Transthyretin Cardiac Amyloidosis. *J Am Coll Cardiol* 2017;70:466-77.
 53. Banyersad SM, Fontana M, Maestrini V, et al. T1 mapping and survival in systemic light-chain amyloidosis. *Eur Heart J* 2015;36:244-51.
 54. Banyersad SM, Sado DM, Flett AS, et al. Quantification of Myocardial Extracellular Volume Fraction in Systemic AL Amyloidosis: An Equilibrium Contrast Cardiovascular Magnetic Resonance Study. *Circ Cardiovasc Imaging* 2013;6:34-9.
 55. Fontana M, Banyersad SM, Treibel TA, et al. Native T1 mapping in transthyretin amyloidosis. *JACC Cardiovasc Imaging* 2014;7:157-65.
 56. Karamitsos TD, Piechnik SK, Banyersad SM, et al. Noncontrast T1 mapping for the diagnosis of cardiac amyloidosis. *JACC Cardiovasc Imaging* 2013;6:488-97.
 57. Fontana M, Chung R, Hawkins PN, et al. Cardiovascular magnetic resonance for amyloidosis. *Heart Fail Rev* 2015;20:133-44.
 58. Fontana M, Pica S, Reant P, et al. Prognostic value of late gadolinium enhancement cardiovascular magnetic resonance in cardiac amyloidosis. *Circulation* 2015;132:1570-9.
 59. White JA, Fine NM. Recent Advances in Cardiovascular Imaging Relevant to the Management of Patients with Suspected Cardiac Amyloidosis. *Curr Cardiol Rep* 2016;18:77.
 60. White JA, Kim HW, Shah D, et al. CMR imaging with rapid visual T1 assessment predicts mortality in patients suspected of cardiac amyloidosis. *JACC Cardiovasc Imaging* 2014;7:143-56.
 61. Dungu JN, Valencia O, Pinney JH, et al. CMR-based differentiation of AL and ATTR cardiac amyloidosis. *JACC Cardiovasc Imaging* 2014;7:133-42.
 62. Kellman P, Arai AE, McVeigh ER, et al. Phase-sensitive inversion recovery for detecting myocardial infarction using gadolinium-delayed hyperenhancement. *Magn Reson Med* 2002;47:372-83.
 63. Williams LK, Urbano-Moral JA, Rowin EJ, et al. Velocity vector imaging in the measurement of left ventricular myocardial mechanics on cardiac magnetic resonance imaging: correlations with echocardiographically derived strain values. *J Am Soc Echocardiogr* 2013;26:1153-62.
 64. Williams LK, Forero JE, Popovic ZB, et al. Patterns of CMR measured longitudinal strain and its association with late gadolinium enhancement in patients with cardiac amyloidosis and its mimics. *J Cardiovasc Magn Reson* 2017;19:61.
 65. Libbey CA, Skinner M, Cohen AS. Use of abdominal fat tissue aspirate in the diagnosis of systemic amyloidosis. *Arch Intern Med* 1983;143:1549-52.
 66. Gertz MA, Li CY, Shirahama T, et al. Utility of subcutaneous fat aspiration for the diagnosis of systemic amyloidosis (immunoglobulin light chain). *Arch Intern Med* 1988;148:929-33.
 67. Quarta CC, Gonzalez-Lopez E, Gilbertson JA, et al. Diagnostic sensitivity of abdominal fat aspiration in cardiac amyloidosis. *Eur Heart J* 2017;38:1905-8.
 68. Frustaci A, Pieroni M, Chimenti C. The role of endomyocardial biopsy in the diagnosis of cardiomyopathies. *Ital Heart J* 2002;3:348-53.
 69. Narotsky DL, Castano A, Weinsaft JW, Bokhari S, Maurer MS. Wild-Type Transthyretin Cardiac Amyloidosis: Novel Insights From Advanced Imaging. *Can J Cardiol* 2016;32:1166.e1-10.
 70. Siddiqi OK, Ruberg FL. Challenging the myths of cardiac amyloidosis. *Eur Heart J* 2017;38:1909-12.
 71. Venner CP, Lane T, Foard D, et al. Cyclophosphamide, bortezomib, and dexamethasone therapy in AL amyloidosis is associated with high clonal response rates and prolonged progression-free survival. *Blood* 2012;119:4387-90.
 72. Mikhael JR, Schuster SR, Jimenez-Zepeda VH, et al. Cyclophosphamide-bortezomib-dexamethasone (CyBorD) produces rapid and complete hematologic response in patients with AL amyloidosis. *Blood* 2012;119:4391-4.
 73. Butler JS, Chan A, Costelha S, et al. Preclinical evaluation of RNAi as a treatment for transthyretin-mediated amyloidosis. *Amyloid* 2016;23:109-18.
 74. Maurer MS, Elliott P, Merlini G, et al. Design and Rationale of the Phase 3 ATTR-ACT Clinical Trial (Tafamidis in Transthyretin Cardiomyopathy Clinical Trial). *Circ Heart Fail* 2017;10. doi: 10.1161/

- CIRCHEARTFAILURE.116.003815
75. Obici L, Cortese A, Lozza A, et al. Doxycycline plus tauroursodeoxycholic acid for transthyretin amyloidosis: a phase II study. *Amyloid* 2012;19 Suppl 1:34-6.
 76. Hawkins PN, Ando Y, Dispenzeri A, et al. Evolving landscape in the management of transthyretin amyloidosis. *Ann Med* 2015;47:625-38.
 77. Griffiths BE, Hughes P, Dowdle R, et al. Cardiac amyloidosis with asymmetrical septal hypertrophy and deterioration after nifedipine. *Thorax* 1982;37:711-2.
 78. Gertz MA, Falk RH, Skinner M, et al. Worsening of congestive heart failure in amyloid heart disease treated by calcium channel-blocking agents. *Am J Cardiol* 1985;55:1645.
 79. Gertz MA, Skinner M, Connors LH, et al. Selective binding of nifedipine to amyloid fibrils. *Am J Cardiol* 1985;55:1646.
 80. Rubinow A, Skinner M, Cohen AS. Digoxin sensitivity in amyloid cardiomyopathy. *Circulation* 1981;63:1285-8.
 81. Tan NY, Mohsin Y, Hodge DO, et al. Catheter Ablation for Atrial Arrhythmias in Patients With Cardiac Amyloidosis. *J Cardiovasc Electrophysiol* 2016;27:1167-73.
 82. Cardoso I, Martins D, Ribeiro T, et al. Synergy of combined doxycycline/TUDCA treatment in lowering Transthyretin deposition and associated biomarkers: studies in FAP mouse models. *J Transl Med* 2010;8:74.
 83. Suhr OB, Coelho T, Buades J, et al. Efficacy and safety of patisiran for familial amyloidotic polyneuropathy: a phase II multi-dose study. *Orphanet J Rare Dis* 2015;10:109.
 84. Ridolfi RL, Bulkley BH, Hutchins GM. The conduction system in cardiac amyloidosis. Clinical and pathologic features of 23 patients. *Am J Med* 1977;62:677-86.
 85. Russo AM, Stainback RF, Bailey SR, et al. ACCF/HRS/AHA/ASE/HFSA/SCAI/SCCT/SCMR 2013 Appropriate Use Criteria for Implantable Cardioverter-Defibrillators and Cardiac Resynchronization Therapy. *Heart Rhythm* 2013;10:e11-58.
 86. Swiecicki PL, Edwards BS, Kushwaha SS, et al. Left ventricular device implantation for advanced cardiac amyloidosis. *J Heart Lung Transplant* 2013;32:563-8.
 87. Fuchs U, Zittermann A, Suhr O, et al. Heart Transplantation in a 68-Year-Old Patient with Senile Systemic Amyloidosis. *Am J Transplant* 2005;5:1159-62.
 88. Sousa M, Monohan G, Rajagopalan N, et al. Heart transplantation in cardiac amyloidosis. *Heart Fail Rev* 2017;22:317-27.

Cite this article as: Halatchev IG, Zheng J, Ou J. Wild-type transthyretin cardiac amyloidosis (ATTRwt-CA), previously known as senile cardiac amyloidosis: clinical presentation, diagnosis, management and emerging therapies. *J Thorac Dis* 2018;10(3):2034-2045. doi: 10.21037/jtd.2018.03.134