



FOLIA MEDICA CRACOVIENSIA

Vol. LX, 1, 2020: 103–113

PL ISSN 0015-5616

DOI: 10.24425/fmc.2020.133491

Correct human cardiac nomenclature

ELŻBIETA SZCZEPANEK¹, KATARZYNA A. JASIŃSKA¹, DAROMIR GODULA¹,
EWA KUCHARSKA², JERZY WALOCHA¹, MAŁGORZATA MAZUR¹

¹Department of Anatomy, Jagiellonian University Medical College, Kraków, Poland

²Department of Gerontology, Geriatrics and Social Work, Jesuit University Ignatianum, Kraków, Poland

Corresponding author: Małgorzata Mazur, M.D., Ph.D.

Department of Anatomy, Jagiellonian University Medical College

ul. Kopernika 12, 31-034 Kraków, Poland

Phone/Fax: +48 12 422 95 11; E-mail: heart@cm-uj.krakow.pl

Abstract: Proper heart's nomenclature is very important in daily clinical practice and research studies, and when it is consistent, it can facilitate better communication between different medical specialists. The general rule of the anatomy is to describe organs and their structures in attitudinally correct position. However, the use of the old-fashioned Valentine position (where the heart is described as if it were standing on its apex) is still in use to describe important cardiac structures. Upon closer analysis, all main chambers of the heart and their associated subcomponents have mislabeled structures that should be renamed. In this article we aimed to emphasize the limitations of Valentinian nomenclature, present proper anatomical names of the most important heart's structures and advocate to change certain mislabeled anatomical structures. Attitudinally correct designations presented in this study will benefit all medical specialties, and they will reinforce the importance of consistent orientational naming. Correct naming of heart's structures will also help improve communication between different medical specialists.

Keywords: myocardium, left ventricle, right ventricle, left atrium, right atrium, valves, Valentine position, cardiac nomenclature, heart anatomy, attitudinally correct anatomy.

Introduction

The human heart is a cone-shaped fibromuscular organ and its wall is composed of three layers of tissue: the pericardium, myocardium and endocardium [1]. In normal human anatomy, the heart is positioned within the middle inferior mediastinum such that usually one third lies to the right of the midline, and two thirds lie to the left. Proper heart's nomenclature is very important in daily clinical practice, and when it is consistent, it can facilitate better communication between different medical specialists.

The general rule of the anatomy is to describe organs and their structures in attitudinally correct position [2]. However, both in in daily practice and research studies, the use of the old-fashioned Valentine position (where the heart is described as if it were standing on its apex) is still in use to describe important heart's structures [2–4]. When the heart is removed from the thoracic cavity and placed as is seen in Fig. 1 (Valentine position) it is possible to discern the timeless heart shape recognizable by all, and it is also the basis of known heart's nomenclature [5]. These common names are not entirely false, but some of them need to be revisited. However, this is not how the heart looks like in situ and thinking about the heart's anatomy with the Valentine position can neglect proper anatomical orientation [6].

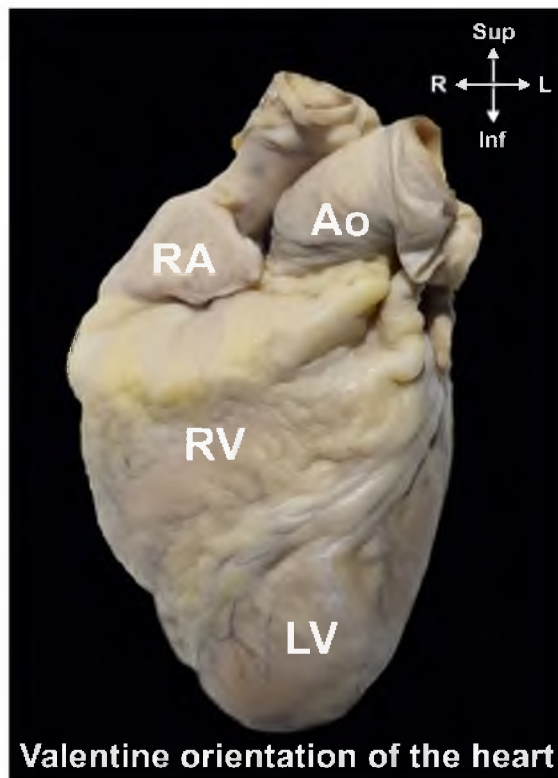


Fig. 1. Heart standing on its apex, in the so-called Valentine position, anterior view. Ao — ascending aorta, LV — left ventricle, RA — right appendage, RV — right ventricle.

One of the main drawbacks of the Valentine heritage concerns the distinction between the left and right heart. Technically, the left vs. right division is a little misleading [3, 4]. The cardiac chambers are never related to one another this way.

The long axis of the heart lies more or less from the right shoulder to the left hypochondrium, with the apex usually positioned in the fifth intercostal space in the midclavicular line. The leftward border of the heart's silhouette extends laterally to the cardiac apex, but only a small part of the anterior wall is formed by the left ventricle. When looking at the heart in correct in situ position (Fig. 2), it is possible to observe that the anterior surface of the heart is mainly occupied by the "right" heart. The right atrium and right ventricle are the major components of the anterior wall of the heart. Thus, instead of distinguishing between the left and right sides of the heart, it is more fitting to refer to the heart chambers as either anterior or posterior [4]. However, assumptions standing behind determining structures as positioned on the right and left site are not completely correct their change is not possible and desirable for chambers naming as it is too deeply rooted in medical world [7].

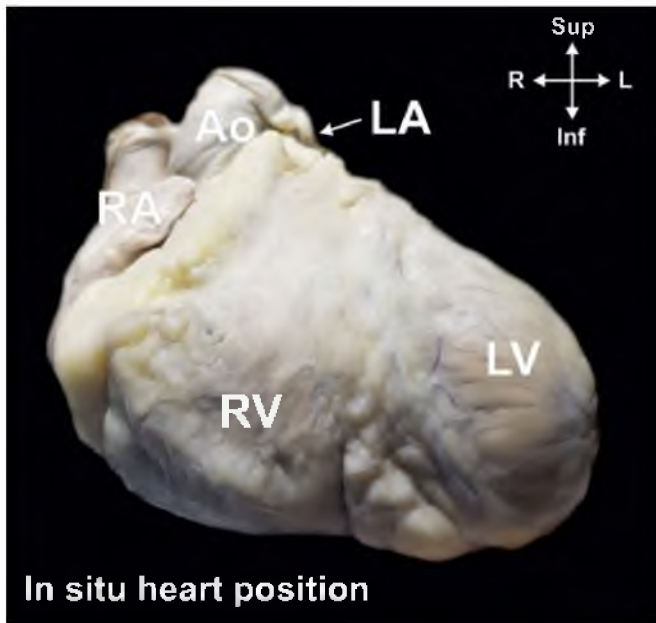


Fig. 2. Heart in situ seen, anterior view. Ao — ascending aorta, LA — left appendage, LV — left ventricle, RA — right appendage, RV — right ventricle.

The posterior vs. inferior designation is one of the major issues that has been brought to the attention of cardiologists. In 2002, Cerqueira *et al.* made recommendations about heart's nomenclature, and one of the most important suggestions proposed by these researchers was to designate the formerly called posterior cardiac wall as the inferior myocardial wall [8]. Despite this, clinical cardiologists and anatomist

are continuing naming the wall opposite the inferior (diaphragmatic) wall as anterior. Moreover, we seek to further highlight that the heart lies in an oblique plane and its structures are named along its longitudinal axis, and this is another factor contributing to incorrect naming of heart structures.

It is the legacy of the Valentine position which perpetuates major misconceptions. Upon closer analysis, all main chambers of the heart and their associated subcomponents have mislabeled structures that should be renamed. In this article we aimed to emphasize the limitations of Valentinian nomenclature, present proper anatomical names of the most important cardiac structures and advocate to change certain mislabeled anatomical structures.

Right heart

Due to oblique orientation of the human heart the right atrium and ventricle are anterior to the left atrium and ventricle.

Right atrium

In the anatomical position, the spatial positioning of the right atrium is posterior to the right ventricle and slightly anterior and to the right to the left atrium. The Valentine position makes us believe that the right atrium is just a tiny fragment, when really it is quite big cavity. It consists of the following main parts: venous component (located posteriorly), an appendage (located anteriorly, superiorly and laterally) and a vestibule [9–12]. The correct orientation of the heart would show that the superior vena cava is not draining into the right atrium perpendicularly; rather, it enters the atrium obliquely, at the superior end of the right atrium, slightly to the right to the interatrial septum [9]. It would also emphasize that the inferior vena cava drains into the atrium from a caudal angle, and at a more posterior angle than what we are accustomed to [13].

The emphasis on appropriate nomenclature would not affect the names of the structures found within the interior of the right atrium cavity. Names such as fossa ovalis or crista terminalis associated with embryological development would remain unaffected by our proposed changes [14]. Moreover structures like the Thebesian valve, Eustachian valve, Koch's triangle would be safe from these rectifications [15].

Right atrioventricular valve

The right atrioventricular valve is commonly name tricuspid. The first concern that needs to be addressed pertains to the generic name of both atrioventricular valves — the bicuspid and tricuspid valves. The term “cuspid” is not an accurate term to

describe heart atrioventricular valves [3]. The word *cuspid* stems from the latin word *cuspis*, symbolizing an apex or rounded projection. Since the partitions of this valve are not in either of these shapes, they should be referred to as leaflets to reflect the right shape of said structures. Second, it is believed that right atrioventricular valve, has three leaflets. However, several more recent anatomical studies have highlighted that this valve is more heterogeneous than previously thought and seldom has only three leaflets and in 42.5% of hearts it has four-leaflet configuration [16]. Furthermore, the leaflets of the tricuspid valve are named incorrectly. Currently, if we obey the classical rules of anatomical nomenclature, these partitions are known as the anterior, posterior and septal, which are tethered at the commissures by fan-shaped cords arising from the papillary muscle [17]. Instead, since the right atrioventricular valve lies in an oblique plane, the leaflets of the right atrioventricular valve should be designated as superior (not anterior) and mural (not posterior). The septal leaflet, however, is located on the interventricular septum thereby justifying its name [2, 16]. In a four-leaflet valve configuration the additional leaflet should be termed as inferior, due to its most inferior position within this valve annulus [16]. In three-leaflet valve leaflets are connected by muro-septal, supero-mural, and supero-septal commissures respectively, while in four-leaflet configuration we can distinguish infero-septal, infero-mural, supero-mural, and supero-septal commissures [16].

Right ventricle

When looking at a heart as it is situated in the thoracic cavity, the majority of the surface area seen from the anatomical position is occupied by the right ventricle, despite having that is significantly smaller than the left ventricle [18]. Situated behind and to the left of the sternum, it occupies the majority of the anterior silhouette of the heart. It also constitutes the inferior border of the heart's silhouette. The interventricular septum forms the posterior wall of the right ventricle cavity. The free wall of the right ventricle may be divided into inferior, lateral and superior parts.

Two to four major papillary muscles could be found within the right ventricle [16]. The papillary muscles could be named in two different ways: alike corresponding commissure or according to their location within the cavity. The supero-septal papillary muscle is usually absent and replaced by septal band. The muro-septal (or infero-mural and infero-septal) papillary muscles are located more posteriorly within the right ventricle, while supero-mural papillary muscle is found in an anterior position when looking at the heart in its correct position [16, 19].

Other structures found within the right ventricle, like the moderator band, tendinous cords or right ventricular outflow tract, do not contain any orientational indication, and as such are immune to the proposed emphasis of correct naming of cardiac structures [20, 21].

Pulmonary valve

Lastly, correct nomenclature would also affect the designated leaflets of the pulmonary valve. The term cusp is considered to be correct for naming the pocketlike semilunar valve components to emphasize a different morphology than the atrioventricular valves. It is widely accepted that the pulmonary valve is comprised of three cusps — a right, left and anterior one [22, 23]. The last one is carelessly named, because the anterior leaflet is actually situated slightly above the left and right leaflet [8].

Left heart

Left atrium

According to the anatomical position, the left atrium is the most posterior cavity of the four main cardiac chambers [5, 24]. When looking at the heart in situ, the only visible part of the left atrium is the tip of its appendage, which peeks around the left side of the pulmonary trunk (Fig. 2) [25]. Anatomically, the left atrium consists of four components: venous part, vestibule leading to the mitral valve, the left atrial appendage and left side of interatrial septum, which divides it from the right atrium. The left atrium walls can be described as anterior, superior, left lateral, septal (or medial), and posterior where pulmonary veins drain to the atrium [9]. These accurate names would further emphasize the posterior location of the left atrium within the human body.

Names for pulmonary veins i.e. left superior and inferior pulmonary veins as well as right superior and inferior pulmonary veins are correct both in valentine and attitudinally correct position of the heart. The vestibule of the left atrium contains several clinically important lines (isthmuses) which are used for linear ablations to treat atrial flutter and fibrillation. The line located between left inferior pulmonary vein ostium and the mitral valve annulus is called as the mitral (or lateral) isthmus. The analogous line located between the mitral valve annulus and right inferior pulmonary vein ostium is called alternative (or medial) isthmus and between the mitral valve annulus and left atrial appendage ostium is named as a left atrial appendage isthmus [26]. The left atrial appendage is separated from the left sided pulmonary veins by left atrial ridge (or left lateral ridge or the coumadin ridge) [9, 27, 28]. The names of the structures located within the interatrial septum, such as patent foramen ovale channel and septal pouches would remain unaffected.

Mitral valve

The mitral valve consists of two leaflets (no cusps). It should be emphasized that the normal mitral valve has only two leaflets, and variations are observed only in scallops. There were only three described cases of the true trileaflet mitral valve [29].

Leaflets are commonly designated as anterior and posterior. However, in situ, these leaflets are not actually in the aforementioned positions. Within the human body, the mitral valve lies in an oblique plane and its posterior leaflet is also inferior to the anterior one. This perpetuated misnomer should be rectified, and these leaflets should actually be designated as anterosuperior and posteroinferior so as to respect attitudinally correct nomenclature [2]. Alternatively, it would also be possible to designate these separations as the aortic and mural leaflets, since they do not contradict the anatomic position of the heart. The commissures which connect two adjacent leaflets should be not be named as anterolateral and posteromedial but as superolateral and inferoseptal, respectively [29].

Left ventricle

In the anatomical position, the left ventricle forms the apex of the heart, and it delineates the left and diaphragmatic borders of the heart. Just as in the right ventricle, it has an inflow and outflow portion [30]. Nonetheless, when viewing the heart as it lies naturally inside the chest cavity, the only visible part of the left ventricle is a small area extending to the leftward border of the cardiac silhouette. The leftward border of the silhouette extends laterally to the cardiac apex, but very little of the anterior and superior surface of the heart is formed by the left ventricle [5].

Calling this ventricle as left may be slightly misleading, as the left ventricle is positioned not only to the left but also more posteriorly to the right ventricle. Moreover, the confusion may also arise from the oblique positioning of the left ventricle within the thorax. Using Valentine nomenclature, the rightfully inferior (or diaphragmatic) wall of the left ventricle is referred to as the „posterior” wall [8]. The anterior wall of the left ventricle is in fact the superior one, and the interatrial septum is located in the anterior position when the heart is described in attitudinally correct position. The ventricles are separated by externally visible: superior (not anterior) and inferior (not posterior) interventricular sulcus.

The nomenclature of the papillary muscles, located within the left ventricle and linked to the mitral valve by tendinous cords is also flawed [5]. Current terminology designates the papillary muscle adjacent to the ventricular septum as posterior and medial, even though this designation is erroneous. The muscle situated in the closest vicinity of the interventricular septum is positioned inferiorly and is anterior to its alleged posterior counterpart. Using attitudinally appropriate terminology,

the papillary muscles, like commissures, should be re-labeled as inferoseptal and superolateral.

Aortic valve

The aortic valve separates the left ventricular outflow tract from the ascending aorta. The aortic valve has three cusps, commonly referred to as the left coronary cusp, the right coronary cusp and the non-coronary cusp, which is also sometimes known as the posterior cusp (although some patients may have bicuspid aortic valve) [31]. The left coronary cusp and right coronary cusp are so named not because of their location but due to the coronary arteries that arise from respectively sinuses of Valsalva (the left coronary artery and right coronary artery, respectively). In attitudinal orientation, however, the sinuses are in anterior (for right coronary), left posterolateral (for left coronary), and right posterolateral (for non-coronary) positions respectively [32]. Moreover, naming the non-coronary leaflet of the aorta as the posterior is may steers away from the initial logic and we recommend calling this leaflet as a non-coronary.

Coronary circulation

The coronary vessels system is comprised of arteries, arterioles, capillaries, venules and veins [33]. The ostia of the coronary arteries arise in the aortic sinuses superior to the attachment of the base of the relevant cusp — the right from the anterior sinus and the left from the left posterior sinus [32, 34]. The left coronary artery shortly after origin bifurcates into the two vessels named left anterior descending artery and left circumflex artery. Unfortunately, the left anterior descending artery, which runs in superior interventricular sulcus is not really „anterior”, which results from above mentioned orientation of the left ventricle. Therefore, this vessel should be named as a superior branch of the left coronary artery. The same is observed for so called posterior descending artery, which typically is a branch of the right coronary artery (70%, known as right dominance) or could be a branch of the circumflex coronary artery (10%, known as left dominance); it can emerge as an anastomosis of the left and right coronary artery (20%, known as co-dominance). Also this name should be revisited because the artery is located inferiorly, not posteriorly as its name indicates [2]. It is also questionable whether arteries that run in the interventricular sulcus should be described as descending, since they courses horizontally toward the heart apex.

The coronary venous system, which consists of coronary sinus and its tributaries as well as anterior and smallest cardiac veins is highly variable [33]. Clinicians and researches are challenged not only by the variability of the coronary venous system morphology, but also different nomenclatures of the coronary sinus tributaries, which

often brings unnecessary confusion [35]. The most prominent difference in relation to commonly used, wrong terminology is the name of the vein located on the infero-lateral wall of the left ventricle, which is named as the “posterior vein of the left ventricle” and should be correctly called as the infero-lateral vein of the left ventricle. The middle cardiac vein, which runs in the inferior interventricular sulcus (together with inferior interventricular artery) could be also called inferior interventricular vein to highlight its location [36]. Other veins such: the great cardiac vein, small cardiac vein, left marginal vein and oblique vein of left atrium may keep their names, which are correct in both Valentine and attitudinally correct positions of the heart.

Conclusion

If we want to remain credible and expect medical professionals to use correct anatomical terminology, then the heart cannot be exempt from the classic nomenclature rules. Cardiac imaging techniques are allowing us to see the heart clearer than ever before, which is why to avoid further confusion, we must teach medical professionals to recognize correct anatomical position. Attitudinally correct designations will benefit everyone, and they will reinforce the importance of consistent orientational naming. Correct naming of heart’s structures will also help to improve communication between different medical specialists.

Conflict of interest

None declared.

References

1. Loukas M., Youssef P., Gielecki J., Walocha J., Natsis K., Tubbs R.S.: History of cardiac anatomy: A comprehensive review from the Egyptians to today. *Clin Anat.* 2016; 29 (3): 270–284.
2. Hill A.J.: Attitudinally Correct Cardiac Anatomy. In: *Handbook of Cardiac Anatomy, Physiology, and Devices.* Cham: Springer International Publishing; 2015: 15–21. doi: 10.1007/978-3-319-19464-6_2.
3. Hotta V.T., Aiello V.D.: Correct Anatomical Orientation of the Heart and Reflections on the Nomenclature Used in Daily Practice. *Arq Bras Cardiol.* 2015; 104 (4): e34–e36. doi: 10.5935/abc.20150029.
4. Cook A.C., Anderson R.H.: Attitudinally correct nomenclature. *Heart.* 2002; 87 (6): 503–506. <http://www.ncbi.nlm.nih.gov/pubmed/12010926>. Accessed March 21, 2018.
5. Anderson R.H., Loukas M.: The importance of attitudinally appropriate description of cardiac anatomy. *Clin Anat.* 2009. doi: 10.1002/ca.20741.
6. Mori S., Spicer D.E., Anderson R.H.: Revisiting the Anatomy of the Living Heart. *Circ J.* 2016; 80 (1): 24–33. doi: 10.1253/circj.CJ-15-1147.
7. Farré J., Anderson R.H., Cabrera J.A., Sanchez-Quintana D., Rubio J., Benezet-Mazuecos J., Del Castillo S., Macia E.: Cardiac anatomy for the interventional arrhythmologist: I. Terminology and fluoroscopic projections. *PACE — Pacing Clin Electrophysiol.* 2010; 33 (4): 497–507. doi: 10.1111/j.1540-8159.2009.02644.x.

8. *Cerqueira M.D., Weissman N.J., Dilsizian V., Jacobs A.K., Kaul S., Laskey W.K., Pennell D.J., Rumberger J.A., Ryan T., Verani M.S.*: Standardized Myocardial Segmentation and Nomenclature for Tomographic Imaging of the Heart. *Circulation*. 2002; 105: 539–542.
9. *Ciuk S., Janas P., Klimek-Piotrowska W.*: Clinical anatomy of human heart atria and interatrial septum — anatomical basis for interventional cardiologists and electrocardiologists. Part 2: left atrium. *Kardiol Pol*. Jan 2018. doi: 10.5603/KP.a2018.0001.
10. *Malik S.B., Kwan D., Shah A.B., Hsu J.Y.*: The Right Atrium: Gateway to the Heart — Anatomic and Pathologic Imaging Findings. *RadioGraphics*. 2015; 35 (1): 14–31. doi: 10.1148/rg.351130010.
11. *Sheren R., Lee S., Salandy S., Roberts W., Loukas M.*: A comprehensive review of the anatomical variation in the right atrium and their clinical significance. *TRIA* 2019; 17; <https://doi.org/10.1016/j.tria.2019.100049>.
12. *Wang J.M.H., Rai R., Carrasco M., Sam-Odusina T., Salandy S., Gielecki J., Żurada A., Loukas M.*: An anatomical review of the right ventricle. *TRIA*. 2019; 17; <https://doi.org/10.1016/j.tria.2019.100049>.
13. *Anderson R.H., Cook A.C.*: The structure and components of the atrial chambers. *Europace*. 2007; 9 Suppl 6. doi: 10.1093/europace/eum200.
14. *Loukas M., Tubbs R.S., Tongson J.M., Polepalli S., Curry B., Jordan R., Wagner T.*: The clinical anatomy of the crista terminalis, pectinate muscles and the teniae sagittalis. *Ann Anat*. 2008; 190 (1): 81–87.
15. *Ueda A., McCarthy K.P., Sánchez-Quintana D., Yen Ho S.*: Right atrial appendage and vestibule: further anatomical insights with implications for invasive electrophysiology. *EP Eur*. 2013; 15 (5): 728–734. doi: 10.1093/europace/eus382.
16. *Holda M.K., Sanchez J., Bateman M., Iaizzo P.*: Right Atrioventricular Valve Leaflet Morphology Redefined. Implications for Transcatheter Repair Procedures. *JACC Cardiovasc Interv*. 2019; 12 (2): 169–178. doi: 10.1016/j.jcin.2018.09.029.
17. *Akhter S.A.*: The Heart and Pericardium. *Thorac Surg Clin NA*. 2011; 21: 205–217. doi: 10.1016/j.thorsurg.2011.01.007.
18. *Dell'Italia L.J.*: Anatomy and Physiology of the Right Ventricle. *Cardiol Clin*. 2012. doi: 10.1016/j.ccl.2012.03.009.
19. *Nigri G.R., Di Dio L.J., Baptista C.A.*: Papillary muscles and tendinous cords of the right ventricle of the human heart: morphological characteristics. *Surg Radiol Anat*. 2001; 23 (1): 45–49. doi: 10.1007/s00276-001-0045-7.
20. *Wafae N., Ruiz C.R., Abraham M., Freire C.H., Demarchi G.T.S., Wafae G.C.*: Anatomy of the tendinous cords of the interventricular septum of the human heart. *Ital J Anat Embryol*. 113 (4): 273–279. <http://www.ncbi.nlm.nih.gov/pubmed/19507468>. Accessed November 21, 2018.
21. *Ho S.Y., Nihoyannopoulos P.*: Anatomy, echocardiography, and normal right ventricular dimensions. *Heart*. 2006; 92 (Suppl 1): i2–13. doi: 10.1136/hrt.2005.077875.
22. *Gami A.S., Noheria A., Lachman N., et al.*: Anatomical correlates relevant to ablation above the semilunar valves for the cardiac electrophysiologist: a study of 603 hearts. *J Interv Card Electrophysiol*. 2011; 30 (1): 5–15. doi: 10.1007/s10840-010-9523-3.
23. *Saremi F., Gera A., Yen Ho S., Hjazzi Z.M., Sánchez-Quintana D.*: CT and MR Imaging of the Pulmonary Valve. *Radiographics*. 2014; 34 (1): 51–71. doi: 10.1148/rg.343135026.
24. *Whiteman S., Saker E., Courant V., Salandy S., Gielecki J., Żurada A., Loukas M.*: An anatomical Review of the left atrium. *TRIA*, 2019; 17; <https://doi.org/10.1016/j.tria.2019.100052>.
25. *Ellis H.*: *The Anatomy of the Heart*; 2012. doi: 10.1016/j.mpaic.2012.05.003.
26. *Holda M.K., Koziej M., Hołda J., Tyrak K., Piątek K., Bolechała F., Klimek-Piotrowska W.*: Anatomic Characteristics of the Mitral Isthmus Region: The Left Atrial Appendage Isthmus as a Possible Ablation Target. *Ann Anat*. 2017; 210: 103–111. doi: 10.1016/j.aanat.2016.11.011.
27. *Mazur M., Jasińska K.A., Walocha J.*: The morphology, clinical significance and imaging methods of the atrial septal puch: A critical review. *TRIA* 2018, 13: 11–18; <https://doi.org/10.1016/j.tria.2018.11.002>.
28. *Piątek-Koziej K., Hołda J., Tyrak K., Bolechała F., Strona M., Koziej M., Lis M., Jasińska K.A., Hołda M.K.*: Anatomy of the left atrial ridge (coumadin ridge) and possible clinical implications for

- cardiovascular imaging and invasive procedures. *J Cardiovasc Electrophysiol.* 2020; 31: 220–226. doi: 10.1111/jce.14307.
29. *Krawczyk-Ożóg A., Hołda M.K., Sorysz D., Koziej M., Siudak Z., Dudek D., Klimek-Piotrowska W.:* Morphologic variability of the mitral valve leaflets. *J Thorac Cardiovasc Surg.* 2017. doi: 10.1016/j.jtcvs.2017.07.067.
 30. *Ho S.Y.:* Anatomy and myoarchitecture of the left ventricular wall in normal and in disease. *Eur J Echocardiogr.* 2009; 10 (8): iii3–iii7. doi: 10.1093/ejehocardi/jep159.
 31. *De Biase C., Mastrokostopoulos A., Philippart R., Desroche L.M., Blanco S., Rehal K., Dumonteil N., Tchetché D.:* Aortic valve anatomy and outcomes after transcatheter aortic valve implantation in bicuspid aortic valves. 2018. doi: 10.1016/j.ijcard.2018.01.018.
 32. *Ho S.Y.:* Structure and anatomy of the aortic root. *Eur J Echocardiogr.* 2009; 10 (1): i3–i10. doi: 10.1093/ejehocardi/jen243.
 33. *Mazur M., Tomaszewska R., Pasternak A., Kuniewicz M., Walocha J.:* The Thebesian valve and its significance for electrophysiologists. *Folia Morph.* 2014; 73 (3): 298–301.
 34. *Whitaker R.H.:* Anatomy of the Heart; 2018. doi: 10.1016/j.mpmed.2018.05.010.
 35. *Ho S.Y., Sánchez-Quintana D., Becker A.E.:* A review of the coronary venous system: a road less travelled. *Hear Rhythm.* 2004; 1 (1): 107–112. doi: 10.1016/j.hrthm.2003.12.001.
 36. *Mazur M., Żabówka A., Bolechała F., Kopacz P., Klimek-Piotrowska W., Hołda M.K.:* Variations and angulation of the coronary sinus tributaries: Implications for left ventricular pacing. *Pacing Clin Electrophysiol PACE.* 2019.