

Jan Witowski, Mateusz Sitkowski, Mateusz K. Hołda,
and Michał Pędziwiatr

5 Three-dimensional printing in preoperative and intraoperative decision making

5.1 Introduction

The expansion of minimally invasive surgery and transcatheter interventions put greater meaning on imaging techniques in patient qualification and procedure planning. For better understanding of the anatomy on standard volumetric medical images, modern three-dimensional (3D) visualization methods have found to be especially beneficial. They include 3D printing, augmented and virtual reality, or advanced rendering techniques, such as cinematic rendering. The major advantages of 3D printing above other methods include element of tactility, which makes the experience more realistic for the surgeon, and ability to simulate procedures. Having said that, there is no strong evidence right now whether there are differences between those techniques in terms of clinical outcomes or decision making.

This chapter will introduce basic concepts of 3D printing, overview of methodology, and state of the art in current clinical practice. We will put special attention to real-life cases where 3D printing is being implemented routinely for preoperative and intraoperative decision making. This chapter covers only the main field of clinical 3D printing, which consists of personalized anatomical models. We will not discuss topics related to 3D printed implants, dental 3D printing, or bioprinting.

5.2 Introduction of 3D printing to clinical practice

Although 3D printing has its history reaching back to 1980s and first attempts to use it in medicine were in the 1990s and early 2000s (especially in the U.S. military), truly clinical 3D printing started in 2008 in Mayo Clinic in Rochester, MN, USA. This case and establishing the first clinical 3D printing lab at Mayo's Department of Radiology by Jonathan Morris and Jane Matsumoto in 2013 were the starting points to the great expansion of clinical 3D printing [1]. Initial reports and reviews suggested extremely high benefits of using the technology and broad range of possible implementations in all medical fields [2, 3]. However, just within next few years, researchers have found areas that can gain from 3D printing the most and quickly experimented with it. So far, orthopedics, maxillofacial surgery, and cardiology have been the fields with most 3D printed models. Anatomical models and surgical guides are the most common types of printouts. These initial reports, though, have helped to move the field forward quickly. Special interest groups and working teams within societies were created, with

Radiological Society of North America (RSNA) in the front. Currently, it unites several hundred medical professionals and researchers working on 3D printing.

It is important to notice that although 3D printing is available for about a decade now, clinical evidence is still relatively sparse. The most published research consists of case studies, as the personalization of 3D printing comes most useful in rare and complex cases. The first meta-analyses have been published very recently, virtually only in orthopedic surgery [4, 5]. Systematic reviews have been performed for most medical fields, however, and have shown that models are accurate and helpful. Having said that, those conclusions are drawn usually just from physicians' reports and with no quantitative data to support it. In-hospital 3D printing labs are still located in almost only large university hospitals, often with industry support. There is a slow change toward more desktop, user-friendly, and accessible machines, and the process itself is simplifying, helping the expansion of the technology. It is still most likely that smaller, rural hospitals will never need 3D printing services.

5.3 The 3D printing process

There are many definitions for 3D printing. To simplify, it can be described as fabricating physical 3D object based on virtual 3D mesh, by successively printing layers on top of one another. In medical scenario, “physical 3D object” is usually an anatomical model, and “virtual 3D mesh” is a computer representation of anatomical structure. The crucial part of clinical 3D printing, however, is the process that leads to creating that virtual model based on medical imaging. This process, called *segmentation*, has been widely explored in computer vision for decades, which led to partial automatization [6]. Several open-source software packages are available to speed up segmentation process with access to semiautomatic algorithms, e.g., thresholding or region growing. Having said that, segmentation is still considered one of the main bottlenecks of 3D visualization and 3D printing processes.

The idea of segmentation is simple: anatomical regions of interests (ROIs) have to be annotated (contoured) slice by slice, preferably by an expert in medical imaging. Today, it is a common practice in medical 3D printing labs to have a team of engineers performing segmentations and have them reviewed and confirmed by experienced radiologists. This task, depending on body area and quality of imaging, can take anywhere from 1 min to 5 h. Good examples of more complex cases are as follows: visceral anatomy (hepatic veins, renal vasculature), tumors with heterogenous attenuation, and vague borders, nerves, or lymph nodes. Segmented ROIs can be exported as “masks” or “labelmaps,” usually in binary format (0, background; 1, area of interest), relative pixelwise to input data. They can also be easily exported straight to virtual 3D mesh, usually in .stl or .obj formats, and subsequently displayed—this process is called *surface rendering*. Once the mesh is exported, it—theoretically—is ready to be 3D printed. However, some sort of postprocessing is usually performed

before sending files to a printer. The most common postprocessing operations are making the model hollow, cutting through the model, dividing model into several parts, smoothing, and adding identifiers or text onto the mesh. There is a final step before the model can be 3D printed. Files with models have to be loaded into the software that is handling communication with the printer and “translating the mesh language into 3D printer language.” The language of 3D printers (and other CNC machines), called *G-code*, consists of instructions on how to create physical 3D object layer by layer. This translation from 3D mesh to G-code is sometimes referred to as *slicing*, and software packages are called *slicers*. Although for most 3D printers there are dedicated, proprietary solutions, some open-source slicers are available. The most commonly used currently are Cura (open-source) and Simplify3D (Fig. 5.1). (Note: do not confuse *slicers* with 3D Slicer—popular open-source software for segmentation that does not perform *slicing* for 3D printing.)

Again, physical 3D objects are created by successively printing layers on top of one another. There are a number of methods that make it possible; however, they usually are based on two ideas: melting hard filaments or solidification of liquid or powder. The first method uses filaments (usually polylactic acid [PLA] or acrylonitrile

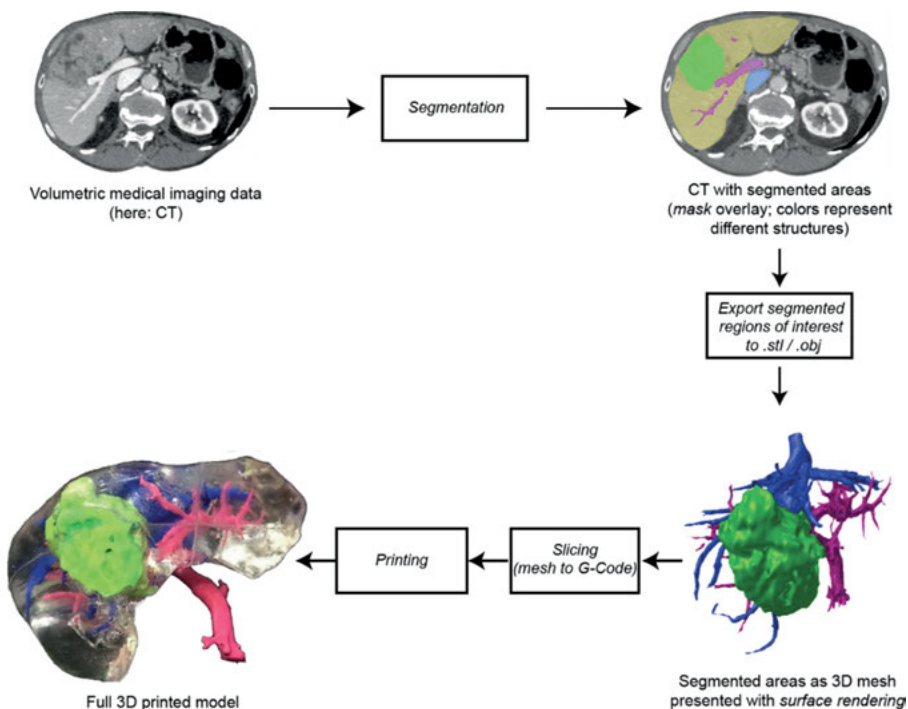


Fig. 5.1: Workflow of 3D printing: all phases from image acquisition to printed model. Case of 3D printing liver models for preoperative planning, done routinely at Jagiellonian University (Kraków, Poland).

butadiene styrene [ABS]) that are being heated up in printer and disposed layer by layer through a nozzle. Filament solidifies just after extrusion as it cools off, forming a 3D structure. The second approach uses fluids (usually resins) solidified with UV light or powder solidified with laser beam. Is it important to know the trade-off between all methods. Some of them may not be useful in specific clinical applications (Fig. 5.2, Tab. 5.1).

5.4 Clinical example: liver models

Laparoscopic liver surgery is often the treatment of choice for patients with intra-hepatic malignancies. Those procedures require extensive preoperative workup,

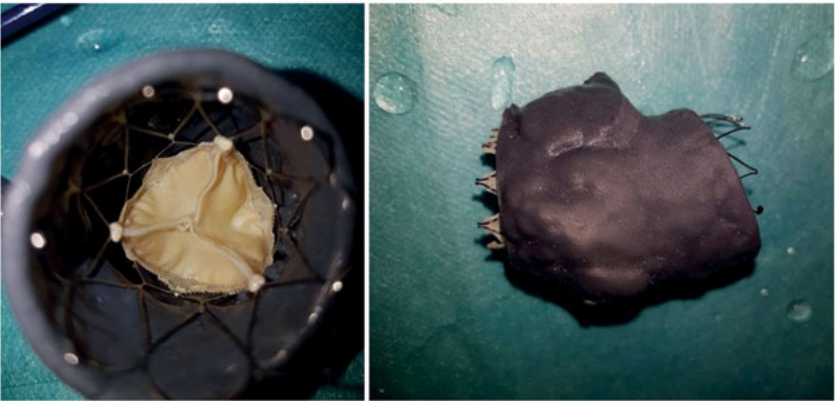


Fig. 5.2: Model of aortic root 3D printed with stereolithography technique. Semiflexible resin allowed the simulation of transcatheter aortic valve implantation (TAVI) and proper valve sizing. Model was created in 2017 for cardiologists from Warsaw Medical University (Warsaw, Poland).

Tab. 5.1: Comparison of the most common 3D printing fabrication methods

	Fused deposition modeling (FDM)	Stereolithography (SLA; or DLP)	Selective laser sintering (SLS)	“PolyJet”/“multicolor printing”
Printing method	Melting hard filaments	Solidifying fluid	Solidifying powder	Solidifying fluid
Costs	Very low	Low/medium	Medium/high	Extremely high
Materials	Very limited, virtually no flexible materials	From tough to slightly flexible	From tough to very flexible	From tough to very flexible
Clinical potential	Good visualization potential, low simulation potential	Good visualization potential, medium simulation potential	Medium visualization potential, good simulation potential	Very good visualization and simulation potential

including imaging (computed tomography or magnetic resonance) and precise planning. Understanding 3D relationships between tumors and hepatic vessels is crucial in performing safe and effective resections. As laparoscopic hepatectomies are elective procedures, 3D printing seems perfect as an aid in decision making.

There are approximately 20 studies published in the area of liver surgery [7, 8]. Most of them, unfortunately, are case studies or case series. As liver models require visualization of multiple structures at once, PolyJet is the fabrication method of choice in most cases, although cost-effective approaches are also explored [9]. Our research group has also shown that 3D printed liver models are highly accurate [10]. A 2019 study by Yang et al. [11] presents that printed models result in the improved assessment of tumor location in comparison with MDCT and standard virtual 3D reconstruction. They also proved that understanding 3D relationship is easier with printed model, as time spent on assessing the tumor location was lowest between all groups (93 s in 3D printing group, over 200 s in other two). Unfortunately, no large randomized or standard prospective trials have been published yet. Our group is running a clinical trial (registered in ClinicalTrials.gov database under NCT03744624 identifier), which is aimed to recruit approximately 85 patients and end before the end of 2022.

Three-dimensional printing in liver surgery is a great example of difficulties related to getting strong evidence of clinical benefits. Patient group is very heterogeneous, and getting statistically significant results requires the recruitment of a large number of individuals. Liver models are also more costly and require more work than others because they have to be multimaterial and multicolor for full immersion. PolyJet-based liver models can cost up to a few thousand dollars per one model [12]. Low-cost methods can reduce this to approximately \$150, although they require more manpower and time. In oncological patients qualified for resection, these models are extremely helpful in choosing the most optimal resection plane and establishing safe resection margins. Preoperative decision making can reduce number of alterations to surgical plan during complex procedure and may help in finding patients who are most exposed to posthepatectomy liver failure. Trial results in coming years should answer whether this is the case (Fig. 5.3).

5.5 Clinical example: congenital heart disease and transcatheter interventions

Congenital heart disease printed models are one of the most explored and proven applications of medical 3D printing. There are a number of studies proving its utility and several labs dedicated to work specifically in this area (Fig. 5.4).

In 2018, the RSNA 3D Printing Special Interest Group published their first guidelines on clinical use of 3D printing. Guidelines included congenital heart disease, craniomaxillofacial, genitourinary, musculoskeletal, vascular, and breast 3D

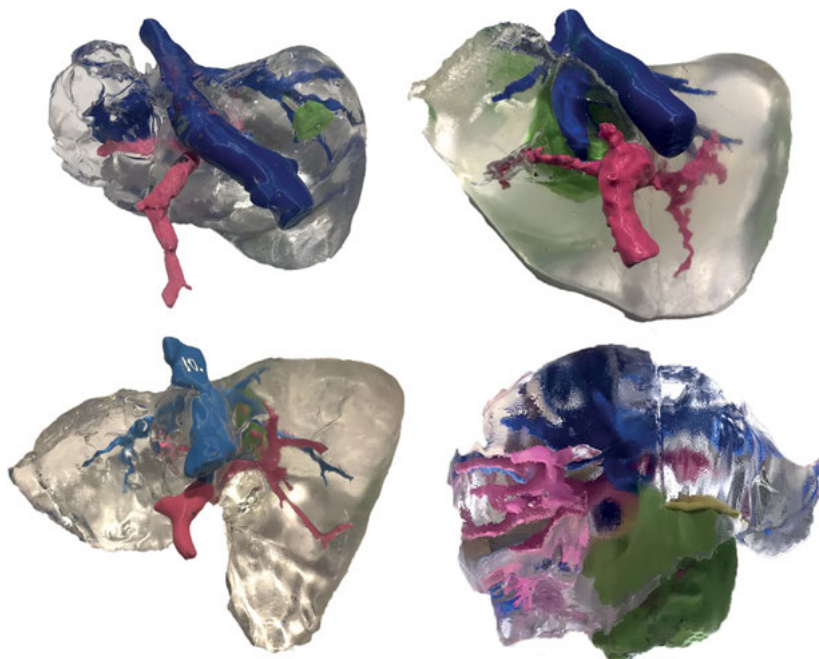


Fig. 5.3: Examples of 3D liver models, developed routinely at Jagiellonian University (Kraków, Poland). They are fully personalized, full sized, and multimaterial. Our unique low-cost approach allowed to reduce production from approximately \$2,000 to \$150 per model. Average time from CT acquisition to model delivery is 5 days. Transparent parenchyma is made with silicone by casting it into a mold printed on a desktop FDM 3D printer.

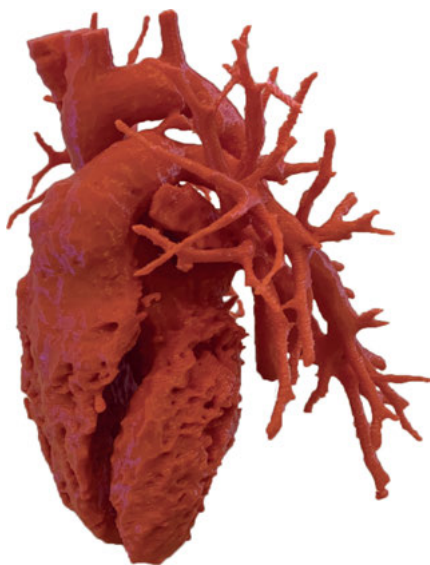

Fig. 5.4: Fused deposition modeling approach allows labs to create personalized models of congenital heart diseases with approximately 24-h turnaround time from image acquisition. This fabrication technique was satisfactory here, as models are used only for visualization and not for simulation. The model in this picture was delivered to cardiologists from University Children's Hospital of Kraków.

models [13]. Appropriateness Guidelines scored medical conditions on a scale from 1 to 10 (10 being most useful and with strongest clinical evidence). Double outlet right ventricle, truncus arteriosus, and anomalous pulmonary venous connection were the conditions found to benefit the most from 3D printing and scored 8 and above. Surprisingly, arterial and ventricular septal defects scored very low, between 2 and 5, although 3D printed models have been proven to be very useful in simulating closure procedures. Flexible models of septal defects can be used to perform mock transcatheter procedures and may help in choosing proper device size, improving the safety of surgery [14]. They help to understand spatial relationships between structures normally seen by cardiologists in echocardiography and learn how to proceed with the catheter delivery system. Models for nonvalvular structural heart diseases, usually meaning left atrial appendage occlusion, help in choosing the proper device, similarly to septal defects.

At Jagiellonian University, we have created an “atlas” of 3D printed congenital heart disease models. Based on real cases and imaging, they show variability within a single condition. The atlas can be used for parent and patient education and for getting an informed consent. More complex models may also be available for less experienced cardiology and cardiac surgery residents for learning complex repair procedures. Although structures are relatively small, the resolution of 3D printers is high enough to make accurate representations of the anatomy. In addition, models can be scaled and divided in any way, providing many possibilities for visualization at request. Segmentation can be tricky, as mentioned before, although there is commercial software dedicated for cardiovascular segmentation, e.g., Mimics (Materialise NV, Leuven, Belgium), that can make this part as quick as 30 min. Elastic or multicolor models are preferred, although in our experience even rigid and monocolored models are useful.

Research shows that 3D printed cardiovascular models can be as effective in educational setting as cadaveric specimens, offering a way to avoid ethical issues. In some cases, they have also been proven to have similar mechanical properties and echocardiography visualization [15].

5.6 Creating in-house 3D lab and summary

There are multiple challenges necessary to consider when planning a new 3D printing in-hospital lab. Considering the budget, it is often forgotten that 3D printing is a work-consuming process, and it requires engagement of qualified people. Clinicians, preferably radiologists, should perform or at least review segmentations before model printing. Engineers should be able to properly choose the fabrication method to meet physician expectations and have a good insight into hardware. Three-dimensional printing is still fairly experimental, so it is safe to assume that some percentage of prints will either fail or not meet clinical expectations. The location of

the lab is important too. To maintain maximum safety by avoiding fumes and fire risk, the lab should be well ventilated and separate from the clinical area. It is crucial to ask surgeons for intraoperative photo.

In medical 3D printing field, it is now clear that this technology will benefit both patients and clinicians. However, it will not be used everywhere and will not dramatically change the landscape. It seems that in the future, we will see more focus on simulations and preprocedural planning with 3D printing and routine use of it in complex cases. Advances in segmentation software and further reduction of costs related to 3D printers should automatize the process and make it more accessible to smaller institutions, especially outside the United States (Fig. 5.5).

We have not discussed topics related to ethical and legal issues. For example, who is the owner of a patient's data? Do we consider 3D models or printers equipment requiring FDA approval? For more information on this, please refer to FDA's Technical

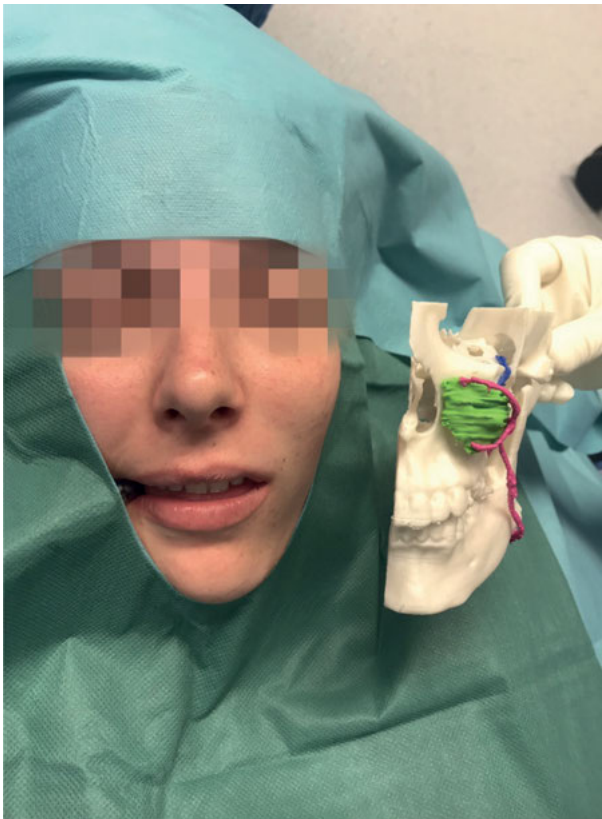

Fig. 5.5: Intraoperative photo of 3D printed facial lesion model with close proximity to facial artery and infraorbital nerve. Created with fused deposition modeling approach, was used by plastic surgeons in Wrocław, Poland.

Considerations for Additive Manufactured Medical Devices, which is currently the only official guideline from U.S. government bodies regarding medical 3D printing [16] as well as James Coburn and Gerald Grant [17] commentary on the FDA process. We have also omitted validation and verification issues: there is no standardization in this area. The largest 3D printing labs have established their own, internal quality assessment protocols. Please refer to a chapter written by Dimitrios Mitsouras, Elizabeth George, and Frank Rybicki [18] to learn more about this. There are also strong efforts in several 3D printing working groups, especially RSNA 3DP SIG, toward assuring high model accuracy and quality.

5.7 References

- [1] Matsumoto, Jane S, Jonathan M. Morris, Thomas A. Foley, Eric E. Williamson, Shuai Leng, Kieran P. McGee, Joel L. Kuhlmann, Linda E. Nesberg, Terri J. Vrtiska. “Three-dimensional physical modeling: applications and experience at Mayo Clinic.” *Radiographics* 35, no. 7 (2015): 1989–2006.
- [2] Ventola, Lee C. “Medical applications for 3D printing: current and projected uses.” *Pharmacy and Therapeutics* 39, no. 10 (2014): 704–11. <http://www.ncbi.nlm.nih.gov/pmc/articles/PMC4189697/>.
- [3] Rengier F, Mehndiratta A, Von Tengg-Kobligh H, Zechmann CM, Unterhinninghofen R, Kauczor HU, Giesel FL. “3D printing based on imaging data: review of medical applications.” *International Journal of Computer Assisted Radiology and Surgery* 5, no. 4 (2010): 335–41. <https://doi.org/10.1007/s11548-010-0476-x>.
- [4] Zhang YD, Wu RY, Xie DD, Zhang L, He Y, Zhang H. “Effect of 3D printing technology on pelvic fractures: a meta-analysis.” *Zhongguo Gu Shang = China Journal of Orthopaedics and Traumatology* 31, no. 5 (2018): 465–71.
- [5] Bai, Jianzhong, Yongxiang Wang, Pei Zhang, Meiying Liu, Peian Wang, Jingcheng Wang, Yuan Liang. “Efficacy and safety of 3D print-assisted surgery for the treatment of pilon fractures: a meta-analysis of randomized controlled trials.” *Journal of Orthopaedic Surgery and Research* 13, no. 1 (2018): 283. <https://doi.org/10.1186/s13018-018-0976-x>.
- [6] Pal, Nikhil R, Sankar K. Pal. “A review on image segmentation techniques.” *Pattern Recognition* 26, no. 9 (1993): 1277–94. [https://doi.org/https://doi.org/10.1016/0031-3203\(93\)90135-J](https://doi.org/https://doi.org/10.1016/0031-3203(93)90135-J).
- [7] Witowski, Jan Sylwester, Jasamine Coles-Black, Tomasz Zbigniew Zuzak, Michal Pędziwiatr, Jason Chuen, Piotr Major, Andrzej Budzyński. “3D printing in liver surgery: a systematic review.” *Telemedicine Journal and E-Health : The Official Journal of the American Telemedicine Association* 23, no. 12 (2017): 943–47. <https://doi.org/10.1089/tmj.2017.0049>.
- [8] Perica, Elizabeth Rose, Zhonghua Sun. “A systematic review of three-dimensional printing in liver disease.” *Journal of Digital Imaging* 31, no. 5 (2018): 692–701. <https://doi.org/10.1007/s10278-018-0067-x>.
- [9] Witowski, Jan Sylwester, Michał Pędziwiatr, Piotr Major, Andrzej Budzyński. “Cost-effective, personalized, 3D-printed liver model for preoperative planning before laparoscopic liver hemihepatectomy for colorectal cancer metastases.” *International Journal of Computer Assisted Radiology and Surgery* 12, no. 12 (2017): 2047–54. <https://doi.org/10.1007/s11548-017-1527-3>.

- [10] Witowski, Jan, Nicole Wake, Anna Grochowska, Zhonghua Sun, Andrzej Budzynski, Piotr Major, Tadeusz Jan Popiela, Michal Pedziwiatr. "Investigating accuracy of 3d printed liver models with computed tomography." *Quantitative Imaging in Medicine and Surgery* 9, no. 1 (2019): 43–52. <https://doi.org/10.21037/qims.2018.09.16>.
- [11] Yang, Tianyou, Shuwen Lin, Qigen Xie, Wenwei Ouyang, Tianbao Tan, Jiahao Li, Zhiyuan Chen, et al. "Impact of 3D printing technology on the comprehension of surgical liver anatomy." *Surgical Endoscopy* 33, no. 2 (2019): 411–17. <https://doi.org/10.1007/s00464-018-6308-8>.
- [12] Zein, Nizar N, Ibrahim A. Hanouneh, Paul D. Bishop, Maggie Samaan, Bijan Eghtesad, Cristiano Quintini, Charles Miller, Lisa Yerian, Ryan Klatte. "Three-dimensional print of a liver for preoperative planning in living donor liver transplantation." *Liver Transplantation* 19 (2013): 1304–10. <https://doi.org/10.1002/lt.23729>.
- [13] Chepelev, Leonid, Nicole Wake, Justin Ryan, Waleed Althobaity, Ashish Gupta, Elsa Arribas, Lumarie Santiago, et al. "Radiological Society of North America (RSNA) 3D Printing Special Interest Group (SIG): guidelines for medical 3D printing and appropriateness for clinical scenarios." *3D Printing in Medicine* 4, no. 1 (2018): 11. <https://doi.org/10.1186/s41205-018-0030-y>.
- [14] Yan, Chaowu, Cheng Wang, Xiangbin Pan, Shiguo Li, Huijun Song, Qiong Liu, Nan Xu, Jianpeng Wang. "Three-dimensional printing assisted transcatheter closure of atrial septal defect with deficient posterior–inferior rim." *Catheterization and Cardiovascular Interventions* 92, no. 7 (2018): 1309–14. <https://doi.org/10.1002/ccd.27799>.
- [15] Sabbagh, Abdallah El, Mackram F. Eleid, Mohammed Al-hijji, Nandan S. Anavekar, David R. Holmes, Vuyisile T. Nkomo, Gustavo S. Oderich, et al. "The various applications of 3D printing in cardiovascular diseases," *Current Cardiology Reports* 20 (2018): 1–9. <https://doi.org/10.1007/s11886-018-0992-9>.
- [16] U.S. Food and Drug Administration. *Technical Considerations for Additive Manufactured Medical Devices. Guidance for Industry and Food and Drug Administration Staff*. Silver Spring, MD: Center for Biologics Evaluation and Research, 2017. <https://www.fda.gov/media/97633/download>.
- [17] Coburn, James C, Gerald T. Grant. "FDA regulatory pathways and technical considerations for the 3D printing of medical models and devices." In *3D Printing in Medicine: A Practical Guide for Medical Professionals*, edited by Frank J. Rybicki and Gerald T. Grant, pp. 97–111. Cham: Springer International Publishing, 2017. https://doi.org/10.1007/978-3-319-61924-8_10.
- [18] Mitsouras, Dimitrios, Elizabeth George, Frank J. Rybicki. "Quality and safety of 3D-printed medical models." In *3D Printing in Medicine: A Practical Guide for Medical Professionals*, edited by Frank J. Rybicki and Gerald T. Grant, pp. 113–23. Cham: Springer International Publishing, 2017. https://doi.org/10.1007/978-3-319-61924-8_11.