

СЛУЧАИ ИЗ ПРАКТИКИ

doi: 10.18484/2305-0047.2020.3.339

S.A. MARKOSYAN



TESTICULAR DERMOID CYST IN A 14-YEAR-OLD CHILD

National Research Ogarev Mordovia State University, Institute of Medicine, Saransk,
The Russian Federation

В работе представлен клинический случай ребенка, 14 лет, с дермоидной кистой правого яичка. Образование впервые было выявлено при профилактическом осмотре в поликлинике. В последующем пациенту неоднократно проводилось ультразвуковое исследование наружных половых органов, при котором в верхнем полюсе правого яичка выявлялась неоднородная эхоструктура размерами 14 мм, 13,7 мм и 12 мм с четким, ровным контуром.

Результаты иммуноферментного анализа крови не показали увеличение основных маркеров опухолевого процесса. При биохимическом тестировании крови отмечалось незначительное повышение уровня прямого билирубина и сывороточного железа.

Для уточнения диагноза проведена магнитно-резонансная томография органов малого таза с внутривенным контрастированием. После проведения указанного обследования был выставлен диагноз «кистозное образование правого яичка».

После проведения необходимых дополнительных диагностических мероприятий (УЗИ периферических лимфатических узлов, обследование брюшной полости с внутривенным контрастным усилением) выполнена операция, заключающаяся в ревизии правой половины мошонки и удалении образования правого яичка. Интраоперационно по данным экспресс-биопсии диагностировалась дермоидная киста правого яичка, что подтвердилось при последующем гистологическом исследовании. Послеоперационный период протекал гладко. Пациент выписался в удовлетворительном состоянии.

Таким образом, представленное клиническое наблюдение подчеркивает необходимость оптимизации профилактической работы медицинского персонала первичного звена по своевременной диагностике опухолевых процессов наружных половых органов, особенно у детей пубертатного возраста.

Ключевые слова: дермоидная киста, яичко, ультразвуковое исследование, магнитно-резонансная томография, ребенок

The paper presents a clinical case of a 14-year-old child with a dermoid cyst of the right testicle. The formation was first detected during a routine check-up in the polyclinic. Then the external genitalia were evaluated with ultrasound examination repeatedly and it revealed an inhomogenous echostructure with dimensions of 14 mm, 13.7 mm and 12 mm with a clear, even contour in the upper pole of the right testicle.

The enzyme-linked immunosorbent assay (ELISA) did not show an increase in the main tumour markers. The biochemical blood test revealed an insignificant rise in conjugated bilirubin and serum iron.

To clarify the diagnosis, magnetic resonance tomography of the pelvic organs with intravenous contrast was recommended. After examination, the cystic lesion of the right testicle was diagnosed.

After carrying out the necessary additional diagnostic measures (ultrasound examination of the peripheral lymphatic nodes, the abdominal cavity exploration with intravenous contrast enhancement), the child underwent an operation consisting in revising the right half of the scrotum and removing the formation of the right testicle. Intraoperatively, according to the express biopsy test, the dermoid cyst of the right testicle was diagnosed, which was confirmed by the subsequent histological examination. The postoperative period was uneventful. The patient was discharged in satisfactory state.

Thus, the presented clinical observation emphasizes the need to optimize the preventive work of primary care medical personnel for timely diagnosis of tumor processes in the external genital organs, especially in children of puberty.

Keywords: dermoid cyst, testicle, ultrasound, magnetic resonance tomography, child

Novosti Khirurgii. 2020 May-Jun; Vol 28 (3): 339-343
Testicular Dermoid Cyst in a 14-Year-Old Child
S.A. Markosyan

The articles published under CC BY NC-ND license



Introduction

Among various germinogenic formations dermoids occur a special place [1, 2, 3]. The development of a tumor in the embryonic period with the localization in the area of deepening of the ectoderm, crevices, furrows and the skin primordia predetermines the diversity of its spread

to organs and tissues [4]. The indicated features of the dermoid cyst morphogenesis contribute to its manifestation at different terms of postnatal ontogenesis and multiform localization, which significantly complicates the timely diagnosis of the formation [5, 6, 7].

This problem is especially acute in pediatric surgery. Despite a significant arsenal of examination

methods, the highest number of neoplasms encountered in children significantly complicates the differential diagnosis of the dermoid cyst and, above all, its localization in atypical sites of [8, 9]. This gives rise to frequent diagnostic errors and complicates the choice of surgical intervention [10, 11, 12].

Objective. To carry out the analysis of providing medical care to a 14-year-old child with the dermoid testicular cyst.

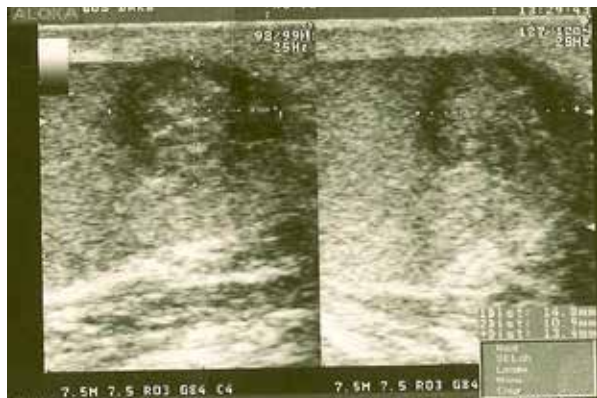A clinical case

On the 27th of October, 2016 during a routine examination in the clinic, a 14-year-old boy was found to have a formation in his right testicle. Before the detection of a tumor-like formation the patient made no complaints. No pains in the right half of the scrotum and swollen testicle detected in this site. On the same day, the patient underwent ultrasound examination of the external genitalia, where an inhomogeneous echostructure of 14 mm, 13.7 mm and 12 mm in size with a clear, even contour was revealed in the upper pole of the right testicle. The sizes of both testicles and their appendages corresponded to age norms. Moderate blood flow was registered via color Doppler mapping flow scanning.

The patient was re-examined by a pediatric surgeon who recommended to conduct an enzyme-linked immunosorbent assay (ELISA) and dynamic ultrasound of the scrotum and abdominal cavity.

An enzyme-linked immunosorbent assay performed after 12 days at the Republican Oncology Center did not show an increase in the main markers of the tumor process (the level of α -fetoprotein in the blood did not exceed 0.5 ng / ml, human β -chorionic gonadotropin – 0.1 mIU / ml). After 18

Fig. 1. A heterogeneous heteroechoic formation of 14×10.9×13.4 mm in the upper pole of the right testicle with a clear, even contour.



days in the consultative polyclinic of Saransk Children's Republican Clinical Hospital, the formation was detected, a second ultrasound of the scrotum was performed, in which no dynamics was observed (Fig. 1). Ultrasound examination demonstrated a chronic non-calculous cholecystitis.

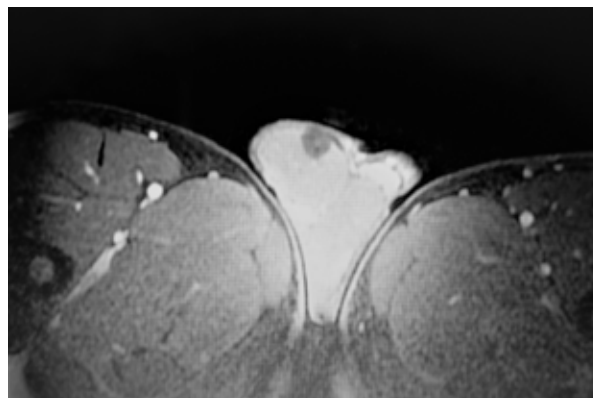
According to the results of the biochemical analysis of blood testing, there was a slight increase in the level of direct bilirubin and serum iron. The indicated values were 3.6 μ mol / L and 22.0 μ mol / L, respectively. The levels of transferrin and ferritin did not exceed normal values.

The boy was sent to Dmitry Rogachev National Medical Research Center of Pediatric Hematology, Oncology and Immunology.

Diagnosis of a dense formation was made upon palpation in the upper part of the right testicle, small in size, displaced relative to adjacent tissues, painless. To clarify the diagnosis, magnetic resonance imaging (MRI) of the abdomen and pelvis with intravenous contrast dye and repeated consultation was recommended to the patient.

On the 6th of December, 2016, in conducting magnetic resonance tomography 7 ml of contrast medium (Gadovist) was injected into the ulnar vein with a flow rate of 2 mL/s. On a series of MRI tomograms of the pelvic organs, the heterogeneity of the structure of the right testicle was revealed due to the inclusion of a high signal at the site (1.2×4.1×2.4 cm) characterized by the clear even contours without signs of homogeneous contrast medium accumulation in a bolus injection (Fig. 2). With intravenous contrasting the persuasive evidence for the paramagnetic pathological prevalence along the rest were not obtained. No visible changes of the left testicle, spermatic cord, appendages of both testicles, as well as pelvic organs were determined. Based on the examination, a diagnosis of cystic lesion of the right testicle was made.

Fig. 2. An inhomogeneous formation of 12×41×24 mm with clear even contours without signs of accumulation of a contrast agent in the upper pole of the right testicle. The arrow indicates the heterogeneous formation of the upper pole of the right testicle.



When re-consulting with a pediatric oncologist, it was recommended to perform an ultrasound examination of the peripheral lymph nodes, an abdominal examination with intravenous contrast agent, as well as hospitalization of the patient in the department of surgery of children and adolescents of Dmitry Rogachev Federal Scientific and Clinical Center for Pediatric Hematology, Oncology and Immunology, Ministry of Health of RF for examination and determining further treatment tactics on the 23rd of January, 2017.

For surgical treatment, the patient was referred to Morozov Children's City Clinical Hospital of the Moscow City Healthcare Department, where he was admitted on 11th of December, 2016.

Examination revealed the formation of the external sex organs were of the male type, pain and testicular swelling were not observed. In the area of the upper pole of the right testicle, the dense mass (D=1 cm) was estimated by palpating it displaced relative to adjacent tissues. Scrotal skin discoloration was not detected. On the basis of the objective and previous examinations, a child with a volumetric formation of the right testicle was prescribed surgical treatment in a planned manner and express biopsy with a decision on the volume of surgical intervention.

On the 12th of December, 2016 the operation was in revising of the right half of the scrotum and removing the formation of the right testicle. According to express biopsy, the dermoid cyst of the right testicle was intraoperatively diagnosed, which was confirmed by subsequent histological examination. In the postoperative period, the patient received antibacterial (ceftriaxone), antihistamine therapy (suprastin) and probiotics (bifidumbacterin). Local treatment of the wound with betadine solution was carried out. On the 13th of December, 2016 the patient was discharged in a satisfactory condition. The sutures were removed on the eighth day after surgery in the polyclinic. Postoperative wound healing occurred by primary intention.

Discussions

Testicular neoplasms in pediatric surgery are not so common [3, 4]. This is quite convincingly evidenced by the literature data and our own observations. The complexity of the diagnosis of testicular formations directly depends on the terms of clinical manifestations, the nature of the tumor process and the individual patient characteristics [5, 8, 12].

The described clinical case indicates a fairly late diagnosis of cystic testicular formation, which had reached a considerable size and was found

during a routine examination of the external genital organs. Conducting the ultrasound in dynamics, enzyme-linked immunosorbent assays and biochemical analyzes allowed reducing the likelihood of a malignant process presence in the testicle, but not completely excluding it. The use of magnetic resonance imaging with intravenous contrast and intraoperative express biopsy significantly facilitated the diagnosis of the dermoid cysts and made it possible to carry out organ-preserving surgery.

Conclusion

Thus, the presented clinical observation indicates the need to optimize the preventive work of primary care of medical personnel for the timely diagnosis of tumor processes of the external genital organs, especially in puberty children. The solution to this problem is impossible without knowledge of the etiopathogenetic basis of this pathology, the use of an integrated comprehensive examination of patients and the development of therapeutic tactics, depending on the results of diagnosis.

Conflict of interest

The author declares that he has no conflict of interest.

Ethical aspects

Consent. The consent of the legal representative of a child under the age of 15 years has been obtained to provide a description of the clinical case in print and in Internet for scientific and educational purposes.

ЛИТЕРАТУРА

1. Давидов МИ, Малков АД. Дермоидная киста яичка. *Урология*. 2003;(2):52-55.
2. Немцова МВ, Андреева ЮЮ. Молекулярно-генетические и клиничко-морфологические аспекты герминогенных опухолей яичка. *Онкоурология*. 2015;11(1):12-19. doi: 10.17650/1726-9776-2015-1-12-19
3. Singh AP, Tanger R, Mishra D, Ansari M, Gupta AK, Shukla AK. Testicular mixed germ cell tumor in a newborn child: a rare case. *J Indian Assoc Pediatr Surg*. 2019 Apr-Jun;24(2):144-46. doi: 10.4103/jiaps.JIAPS_87_18
4. Васильева ИГ, Стрельников АИ, Богданов ГП, Алексеев ПВ, Семенова ЕВ. Случай дермоидной кисты яичка у ребенка с синдромом недифференцированной соединительнотканной дисплазии. *Вест ИвГМА*. 2011;16(1):71-72. <https://cyberleninka.ru/article/n/sluchay-dermoidnoy-kisty-yaichka-u-rebenka-s-sindromom-nedifferentsirovannoy-soedinitelnotkannoy-displazii>
5. Носов АК, Мамижев ЭМ, Рева СА, Новиков РВ,

Воробьев АВ, Гафтон ГИ, Петров СБ. Влияние задержки диагностики на догоспитальном этапе на результаты лечения больных с герминогенными опухолями яичка в Санкт-Петербурге. *Онкоурология*. 2013;9(2):63-68. <https://doi.org/10.17650/1726-9776-2013-9-2-63-68>

6. Shen J, Bi Y, Wang X, Lu L, Tang L, Liu Y, Chen H, Zhang B. Epidemiologic study of 230 cases of testicular/paratesticular tumors or masses: 15-year experience of a single center. *J Pediatr Surg*. 2017 Dec;52(12):2056-60. doi: 10.1016/j.jpedsurg.2017.08.027

7. Akiyama S, Ito K, Kim WJ, Tanaka Y, Yamazaki Y. Prepubertal testicular tumors: a single-center experience of 44 years. *J Pediatr Surg*. 2016 Aug;51(8):1351-54. doi: 10.1016/j.jpedsurg.2016.02.042

8. Кулева СА, Фасеева НД, Иванова СВ. Номограмма для определения первично-резистентных форм герминогенных опухолей у детей. *Рос Журн Детской Гематологии и Онкологии*. 2019;6(3):26-30. doi: 10.21682/2311-1267-2019-6-3-26-30

9. Gilbert D, Rapley E, Shipley J. Testicular germ cell tumours: predisposition genes and the male germ cell niche. *Nat Rev Cancer*. 2011 Apr;11(4):278-88. doi: 10.1038/nrc3021

10. Бурова ЕА, Буланов АА, Трякин АА, Федянин МЮ, Матвеев ВБ, Тюляндин СА. Лечение несеминомных герминогенных опухолей яичка I стадии. *Онкоурология*. 2011;(1):10-15. <https://cyberleninka.ru/article/n/lechenie-neseminomnyh-germinogennyh-opuholey-yaichka-i-stadii>

11. Maizlin II, Dellinger M, Gow KW, Goldin AB, Goldfarb M, Nuchtern JG, Langer M, Vasudevan SA, Doski JJ, Raval MV, Beierle EA. Testicular tumors in prepubescent patients. *J Pediatr Surg*. 2018 Sep;53(9):1748-52. doi: 10.1016/j.jpedsurg.2017.09.020

12. Chung JM, Lee SD. Overview of pediatric testicular tumors in Korea. *Korean J Urol*. 2014 Dec;55(12):789-96. doi: 10.4111/kju.2014.55.12.789

REFERENCES

1. Davidov MI, Malkov AD. Dermoid cyst of the testis. *Urologiia*. 2003;(2):52-55. (In Russ.)

2. Nemtsova MV, Andreeva YuYu. Testicular germ cell tumors: Molecular genetic and clinicomorphological aspects *Onkourologiia*. 2015;11(1):12-19. doi: 10.17650/1726-9776-2015-1-12-19 (In Russ.)

3. Singh AP, Tanager R, Mishra D, Ansari M, Gupta AK, Shukla AK. Testicular mixed germ cell tumor in

a newborn child: a rare case. *J Indian Assoc Pediatr Surg*. 2019 Apr-Jun;24(2):144-46. doi: 10.4103/jiaps.JIAPS_87_18

4. Vasilijeva IG, Strelnikov AI, Bogdanov GP, Alekseyev PV, Semenova EV. Testicle dermoid cyst in a child with indifferntiated connective tissue dysplasia. *Vest IvGMA*. 2011;16(1):71-72. <https://cyberleninka.ru/article/n/sluchay-dermoidnoy-kisty-yaichka-u-rebenka-s-sindromom-nedifferentsirovannoy-soedinitelnotkannoy-displazii> (In Russ.)

5. Nosov AK, Mamizhev EM, Reva SA, Novikov RV, Vorobyev AV, Gafton GI, Petrov SB. Impact of delayed prehospital diagnosis on the results of treatment in patients with germinogenic testicular tumors in Saint-Petersburg. *Onkourologiia*. 2013;9(2):63-68. <https://doi.org/10.17650/1726-9776-2013-9-2-63-68> (In Russ.)

6. Shen J, Bi Y, Wang X, Lu L, Tang L, Liu Y, Chen H, Zhang B. Epidemiologic study of 230 cases of testicular/paratesticular tumors or masses: 15-year experience of a single center. *J Pediatr Surg*. 2017 Dec;52(12):2056-60. doi: 10.1016/j.jpedsurg.2017.08.027

7. Akiyama S, Ito K, Kim WJ, Tanaka Y, Yamazaki Y. Prepubertal testicular tumors: a single-center experience of 44 years. *J Pediatr Surg*. 2016 Aug;51(8):1351-54. doi: 10.1016/j.jpedsurg.2016.02.042

8. Kuleva SA, Faseeva ND, Ivanova SV, Nomogram for the determination of primary-resistant forms of germ cell tumors in children. *Russian Journal of Pediatric Hematology and Oncology*. 2019;6(3):26-30. <https://doi.org/10.21682/2311-1267-2019-6-3-26-30> (In Russ.)

9. Gilbert D, Rapley E, Shipley J. Testicular germ cell tumours: predisposition genes and the male germ cell niche. *Nat Rev Cancer*. 2011 Apr;11(4):278-88. doi: 10.1038/nrc3021

10. Бурова ЕА, Буланов АА, Трякин АА, Федянин МЮ, Матвеев ВБ, Тюляндин СА. Treatment for stage I nonseminomatous testicular germ cell tumors. *Onkourologiia*. 2011;(1):10-15. <https://cyberleninka.ru/article/n/lechenie-neseminomnyh-germinogennyh-opuholey-yaichka-i-stadii> (In Russ.)

11. Maizlin II, Dellinger M, Gow KW, Goldin AB, Goldfarb M, Nuchtern JG, Langer M, Vasudevan SA, Doski JJ, Raval MV, Beierle EA. Testicular tumors in prepubescent patients. *J Pediatr Surg*. 2018 Sep;53(9):1748-52. doi: 10.1016/j.jpedsurg.2017.09.020

12. Chung JM, Lee SD. Overview of pediatric testicular tumors in Korea. *Korean J Urol*. 2014 Dec;55(12):789-96. doi: 10.4111/kju.2014.55.12.789

Адрес для корреспонденции

430032, Российская Федерация,
г. Саранск, ул. Ульянова, 26 А,
Национальный исследовательский Мордовский
государственный университет им. Н.П. Огарёва,
Медицинский институт,
кафедра факультетской хирургии
с курсами топографической анатомии
и оперативной хирургии, урологии
и детской хирургии,
тел. моб.: +79176990604,
e-mail: markosyansa@mail.ru,
Маркосьян Сергей Анатольевич

Address for correspondence

430032, Russian Federation,
Saransk, Ulyanov str., 26 a,
National Research Ogarev
Mordovia State University,
Institute of Medicine,
the Department of the Faculty Surgery
with Courses of Topographic Anatomy
and Operative Surgery, Urology
and Pediatric Surgery,
tel.mobile: +7 917 699 06 04,
e-mail: markosyansa@mail.ru,
Markosyan Sergey A.

Сведения об авторах

Маркосьян Сергей Анатольевич, доктор медицинских наук, доцент (ученое звание), профессор кафедры факультетской хирургии с курсами топографической анатомии и оперативной хирургии, урологии и детской хирургии, Национальный исследовательский Мордовский государственный университет им. Н.П. Огарёва, Медицинский институт, г. Саранск, Российская Федерация.
<http://orcid.org/0000-0002-9876-4433>

Информация о статье

*Поступила 29 декабря 2019 г.
Принята в печать 22 июня 2020 г.
Доступна на сайте 7 июля 2020 г.*

Information about the authors

Markosyan Sergey A., MD, Associate Professor, Professor, the Department of the Faculty Surgery with Courses of Topographic Anatomy and Operative Surgery, Urology and Pediatric Surgery, National Research Ogarev Mordovia State University, Institute of Medicine, Saransk, Russian Federation.
<http://orcid.org/0000-0002-9876-4433>

Article history

*Arrived: 29 December 2019
Accepted for publication: 22 June 2020
Available online: 7 July 2020*
