

CASE REPORT

Open Access

Prenatal management and perinatal outcome in giant placental chorioangioma complicated with hydrops fetalis, fetal anemia and maternal mirror syndrome

Lutgado García-Díaz¹, Práxedes Carreto², Susana Costa-Pereira¹ and Guillermo Antiñolo^{1,3,4*}**Abstract**

Background: Giant placental chorioangiomas have been associated with a number of severe fetal complications and high perinatal mortality.

Case presentation: We report a case of giant chorioangioma with fetal hydrops, additionally complicated by severe anemia, mild cardiomegaly with hyperdynamic heart circulation and maternal mirror syndrome. Intrauterine blood transfusion and amniocentesis was performed at 29 weeks. Worsening of the fetal and maternal condition prompted us to proceed with delivery at 29 + 5 weeks. The newborn died 3 hours later due to pulmonary hypoplasia and hemodynamic failure. Maternal course was favourable, mirror syndrome resolved in the second day and the patient was discharged four days following delivery.

Conclusions: In the case described here, fetal condition got worse despite of the anemia correction and amniocentesis. Our outcome raises the issue whether additional intrauterine clinical intervention, as interstitial laser, should have been performed to stop further deterioration of the fetal condition when progressive severe hydrops develops.

Keywords: Fetal chorioangioma, Hydrops fetalis, Fetal anemia, Fetal therapy, Mirror syndrome

Background

Chorioangiomas are benign placenta tumors histologically corresponding either to hamartomas derived from primitive chorionic mesenchyma or placental hemangiomas arising from chorionic plate [1]. Large or giant chorioangiomas, defined as measuring more than 4–5 cm in diameter, have an estimated prevalence varying from one in 9000 to one in 50 000 pregnancies [1], and have been associated with a number of fetal complications including anemia, polyhydramnios, hyperdynamic circulation and cardiomegaly, hydrops, and growth restriction [2–6]. In view of these complications and the associated

high perinatal death rate (30–40%), a number of therapeutic interventions have been attempted with limited success in most cases [5,7,8].

Here we report a case of giant chorioangioma, fetal hydrops, additionally complicated by severe anemia, mild cardiomegaly with hyperdynamic heart circulation and maternal mirror syndrome.

Case presentation

A 34-year-old woman, gravida 1, was referred to our Department at 29 weeks' gestation because of placental chorioangioma, severe hydrops fetalis, suspected fetal anemia and maternal mirror syndrome (Ballantine's syndrome), previously not detected. Ultrasound examination confirmed fetal hydrops with hydrothorax and ascitis, fetal anemia (middle cerebral artery peak systolic velocity: 74.3 cm/sg with an estimated haemoglobin of 7.14 g/dl), polyhydramnios (maximum pocket 14),

* Correspondence: guillermo.antinolo.sspa@juntadeandalucia.es

¹Unidad de Gestión Clínica de Genética, Reproducción y Medicina Fetal. Instituto de Biomedicina de Sevilla (IBIS), Hospital Universitario Virgen del Rocío/CSIC/Universidad de Sevilla, Sevilla, Spain

³Centro de Investigación Biomédica en Red de Enfermedades Raras (CIBERER), Sevilla, Spain

Full list of author information is available at the end of the article

estimated fetal weight of 2460 g and mild cardiomegaly (cardiac area more than 1/3 of thoracic area) with hyperdynamic heart circulation. In addition, ultrasound examination showed the presence of a heterogenous hypoechoic area of 70x56 mm, with color Doppler showing a specific blood supply, both consistent with diagnosis of chorioangioma (Figure 1). Maternal examination was consistent with mirror syndrome (edema, oliguria, anemia, elevated liver enzymes, hypoproteinemia and hypokalemia). Blood pressure was normal. At 29 + 1 weeks, treatment with 12 mg betamethasone injections (two doses separated in 24hours) was given; intrauterine transfusion (IUT) of 80 ml of packed red blood cell suspension with a 70% hematocrit was performed, and followed by amniocentesis. Initial fetal hematocrit was 7 g/dL and final one was 12 g/dL. 1800 ml of amniotic fluid were drained, reducing maximum pocket to 5 cm. Within the next hour preterm labor developed, therapy with atosiban and nifedipine was initiated and the contractions subsided. At 29 + 5 weeks' gestation, fetal ultrasound showed worsening of the fetal hydrothorax as well as pulsatility index of the umbilical artery over 95th centile. In addition, worsening of the maternal mirror syndrome (pleural effusion and increasing levels of liver enzymes) was noted. Worsening of the fetal and maternal condition prompted us to proceed with delivery at 29 + 5 weeks'. A thoracocentesis to optimise the neonatal resuscitation was performed in the operating room, and was immediately followed by the caesarean section. The newborn weighed 2503 g and apgar score was 1 and 4 at 1 and 5 min. The newborn died 3 hours later due to pulmonary hypoplasia and hemodynamic failure. Maternal course was favourable, mirror syndrome resolved in the second day and the patient was discharged four days following delivery. Histological analysis confirmed the diagnosis of placental chorioangioma (Figure 2). Microscopic examination showed that the chorioangioma

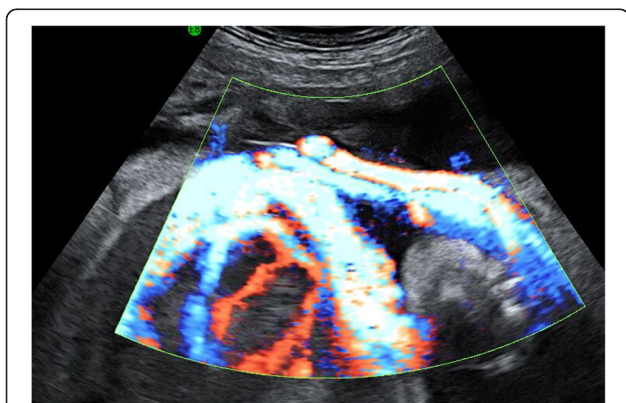


Figure 1 Color Doppler of giant placental chorioangioma.

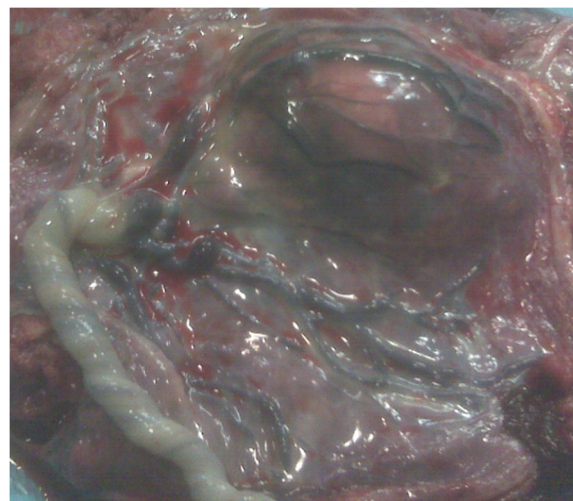

Figure 2 Macroscopic view of giant placental chorioangioma.

was composed of predominantly capillary vascular areas in the fibroid matrix.

Discussion

Around 50% of large chorioangiomas cases develop fetal and maternal complications that required either elective delivery or intervention for tumor-related effects [9].

Chorioangiomas may act as peripheral arteriovenous shunts, leading to increased cardiac output, cardiomegaly and finally heart failure and hydrops, additionally complicated by fetal anemia in some cases [2-6]. When complications appear late in pregnancy, the best option is delivery. However, complications may appear earlier and delivery may be a problem due to fetal prematurity. Thus, different interventions have been proposed to prevent fetal loss related to large fetal chorioangioma complications. Amniocentesis for alleviating polyhydramnios [3,5,7] and intrauterine transfusions in the presence of fetal anemia are two of the most common therapeutic procedures [7,10-12], although results are favorable, the problem that causes increased peripheral flow through the chorioangioma, it is not solved with amniocentesis or fetal transfusion. For that reason, other approaches have been used to stop vascular supply to the tumor and consequent heart failure. In addition to amniocentesis or fetal transfusion, different techniques have been used as injection of absolute alcohol [13-15], endoscopic laser coagulation [16,17], and interstitial laser therapy [4,7], endoscopic suture with bipolar electrocautery [18], and microcoil and embucrilate embolization, the last two procedures without survivors [9,13,18]. Table 1 summarize a literature review of therapy (excluding amniocentesis alone) and the presence/absence of hydrops as well as other complications in chorioangioma cases. When analysing the overall results of intraterrine

Table 1 Literature review of therapy (excluding amniodrainage alone), presence/absence of hydrops, and other complications in giant chorioangioma cases

Reference	Case #	Greatest tumor diameter (mm)	Hydrops	Other complications	Intrauterine therapy	Delivery (weeks)	Pregnancy outcome
This report	1	78	Yes	Polyhydramnios, hydrothorax, mild cardiomegaly, fetal anemia, mirror syndrome	Intrauterine transfusion + amniodrainage (29 weeks)	29+6	Neonatal death
Zanardini (2010)	2	42	No	Polyhydramnios and cardiomegaly	Fetoscopic laser (24+3 weeks)	36+3	Live birth
Zanardini (2010)	3	45	No	Moderate cardiomegaly	Interstitial laser (25+4 and 26+4 weeks)	32+3	Live birth
Zanardini (2010)	4	35	No	Mild cardiomegaly and fetal anemia	Interstitial laser (32+3 weeks)	39+1	Live birth
Zanardini (2010)	5	54	No	Mild cardiomegaly and fetal anemia	Amniodrainage (28+6 weeks) Intrauterine blood transfusion (29 weeks) Interstitial laser (29 and 30+4 weeks)	37+3	Live birth
Sisvali (2009)	1	70	Yes	Fetal anemia	Intrauterine blood transfusion at 26	27	Live birth
Mendez-Figueroa (2009)	1	43	Yes	Fetal anemia	Amniodrainage Intrauterine blood transfusion Fetoscopy: bipolar and laser coagulation	26	Fetal demise
Bermúdez (2007)	1	61	Yes	Fetal anemia	Intrauterine blood transfusion. Fetoscopic laser coagulation Amniodrainage	27	Fetal demise
Deren (2007)	1	83	Yes	Fetal anemia	Intrauterine blood transfusion. Alcohol injection into the tumor (25 and 26 weeks)	28	Live birth
Quarello (2005)	1	44	Yes	No	Fetoscopic laser coagulation Amniodrainage	39	Live birth
Escribano D (2005)	1	81	No	Fetal anemia	Intrauterine blood transfusion (25 weeks, 60 ml)	39	Live birth
Lau (2005)	1	90	Yes	Polyhydramnios	Ultrasound guided transcuteaneous embolisation with enbucrilate (24+2 weeks)	26	Neonatal death
Lau (2003)	1	74	No	Fetal anemia	Intrauterine blood transfusion (24 th weeks, 50 ml) Ultrasound-guided transcuteaneous embolisation with microcoil (24+2th weeks, 8 pieces) Intrauterine blood transfusion (25 th weeks, 60 ml) Ultrasound-guided transcuteaneous embolisation with microcoil (25th weeks, 9 pieces) Intrauterine blood transfusion (27 th 28 th 29th weeks)	29 +6	Neonatal death
Sepúlveda (2003)	1	75	Yes	Severe polyhydramnios and cardiac faillure	Alcohol ablation (26 weeks)	26	Fetal demise (26 weeks)
Nicolini (1999)	1	60	No	Polyhydramnios	Amniodrainage	N/A	Live birth

Table 1 Literature review of therapy (excluding amniodrainage alone), presence/absence of hydrops, and other complications in giant chorioangioma cases (Continued)

Nicolini (1999)	2	50	No	Polyhidramnios	Alcohol ablation (27 weeks)		
					Alcohol ablation (24 and 25 weeks)	N/A	Live birth
Haak (1999)	1	68	No	Fetal anemia Polyhidramnios	Intrauterine blood transfusion (30 weeks, 100 ml)	32	Live birth
Quintero (1996)	1	85	Yes	Fetal anemia	Fetoscopy and devascularisation by suture ligation and bipolar cautery (24 th weeks)	24+3	Fetal demise

interventions, it is also remarkable that mortality in cases without fetal hydrops is 10%, while mortality in cases with fetal hydrops raises to 67%. In fact, all successful interstitial laser procedures [4,7] were performed to prevent the development of fetal hydrops.

Mirror syndrome (Ballantyne's syndrome) is usually defined as maternal edema associated to fetal hydrops [19]. Different fetal conditions have been related to mirror syndrome, although pathogenesis and pathophysiology of Ballantyne's syndrome is currently unknown [19]. Mirror syndrome associated to large placental chorioangiomas has been described only a few times [20-23] and maternal edema has been always present, as was in our case. In addition, other clinical markers also been reported as oliguria, anemia, elevated liver enzymes, hypoproteinemia and hypokalemia were also present in our patient. Additional clinical signs and symptoms described in Mirror syndrome related to large chorioangiomas such as elevated blood pressure, proteinuria, elevated uric acid and creatinine, headache and visual disturbances, and low platelets were absent in our case, which made easier differential diagnosis with preeclampsia. As described elsewhere [19] mirror syndrome disappears shortly after fetal hydrops successful treatment, pregnancy termination or delivery, as in the patient presented here.

Conclusions

In the case described here, which presented with fetal anemia and severe hydrops, additionally complicated by maternal mirror syndrome, intrauterine transfusion and amniodrainage were performed. However, fetal condition got worse despite of the anemia correction. Finally, an emergency cesarean section, after thoracocentesis to optimise the neonatal resuscitation, was performed due to worsening of maternal and fetal condition and to prevent fetal demise. Current data and experience from clinical practice are still scanty to support the effectiveness of intrauterine therapy procedures in chorioangioma complicated cases, specially in cases with fetal hydrops, which led us to attempt a more conservative approach. However, our outcome raises the issue

whether additional intrauterine clinical intervention, as interstitial laser, should have been performed to stop further deterioration of the fetal condition when progressive severe hydrops develops.

Consent

Written informed consent was obtained from the patient for publication of this report and any accompanying images, as it is our usual publication policy according to our Internal Review Board instructions.

Competing interests

The authors declare that they have no competing interests.

Authors' contributions

GA and LG-D drafted the manuscript, and PC and SC-P collaborated with valuable contributions to the manuscript. All authors have read and approved the final manuscript.

Author details

¹Unidad de Gestión Clínica de Genética, Reproducción y Medicina Fetal. Instituto de Biomedicina de Sevilla (IBIS), Hospital Universitario Virgen del Rocío/CSIC/Universidad de Sevilla, Sevilla, Spain. ²Servicio de Obstetricia y Ginecología, Hospital Juan Ramón Jiménez, Huelva, Spain. ³Centro de Investigación Biomédica en Red de Enfermedades Raras (CIBERER), Sevilla, Spain. ⁴Director de la Unidad de Gestión Clínica de Genética, Reproducción y Medicina Fetal, Hospital de la Mujer, Hospital Universitario Virgen del Rocío, Avda. Manuel Siurot s/n, 41013, Sevilla, Spain.

Received: 23 November 2011 Accepted: 20 July 2012

Published: 28 July 2012

References

1. Fox H, Sebire NJ: **Non-trophoblastic tumors of the placenta.** In *Pathology of the Placenta*. 3rd edition. Edited by Fox H, Sebire N. Philadelphia: Saunders Elsevier; 2007:401-430.
2. Sepulveda W, Aviles G, Carstens E, Corral E, Perz N: **Prenatal diagnosis of solid placental masses; the value of color flow imaging.** *Ultrasound Obstet Gynecol* 2000, **16**:554-558.
3. Sepulveda W, Alcalde JL, Schnapp C, Bravo M: **Perinatal outcome after prenatal diagnosis of placental chorioangioma.** *Obstet Gynecol* 2003, **102**:1028-1033.
4. Bhide A, Prefumo F, Sairam S, Carvalho JS, Thilaganathan BT: **Ultrasound-guided interstitial laser therapy for the treatment of placental chorioangioma.** *Obstet Gynecol* 2003, **102**:1189-1191.
5. Nicolini U, Zuliani G, Caravelli E, Fogliani R, Poblete A, Roberts A: **Alcohol injection: a new method of treating placental chorioangiomas.** *Lancet* 1999, **353**:1674-1675.
6. Jauniaux E, Kadri R, Donner C, Rodesch F: **Not all chorioangiomas are associated with elevated maternal serum alpha-fetoprotein.** *Prenat Diagn* 1991, **11**:73-74.

7. Zanardini C, Papageorgiou A, Bhide A, Thilaganathan B: **Giant placental chorioangioma: natural history and pregnancy outcome.** *Ultrasound Obstet Gynecol* 2010, **35**:332–336.
8. Quintero RA, Reich H, Romero R, Johnson MP, Goncalves L, Evans MI: **In utero endoscopic devascularization of a large chorioangioma.** *Ultrasound Obstet Gynecol* 1996, **8**:48–52.
9. Wehrens X, Offermans JPM, Snijders M, Peeters L: **Fetal cardiovascular response to large placental Chorioangiomas.** *J. Perinat Med* 2004, **32**:107–112.
10. Sivasli E, Tekşam Ö, Haliloğlu M, Güçer S, Orhan D, Gürgey A, Tekinalp G: **Hydrops fetalis associated with chorioangioma and thrombosis of umbilical vein.** *Turk J Pediatr* 2009, **51**:515–518.
11. Haak MC, Oosterhof H, Mouw RJ, Oepkes D, Vandenbussche FPHA: **Pathophysiology and treatment of fetal anemia due to placental chorioangioma.** *Ultrasound Obstet Gynecol* 1999, **14**:68–70.
12. Escribano D, Galindo A, Arbués J, Puente JM, De la Fuente P: **Prenatal management of placental chorioangioma: value of the middle cerebral artery peak systolic velocity.** *Fetal Diagn Ther* 2006, **21**:489–493.
13. Lau TK, Yu SCH, Leung TY, To KF, Fung TY, Leung TN: **Prenatal embolisation of a large chorioangioma using enbucrilate.** *BJOG* 2005, **112**:1002–1004.
14. Wanapirak C, Tongsong T, Sirichotiyakul S, Chanprapapah P: **Alcoholization: the choice of intrauterine treatment for chorioangioma.** *J Obstet Gynaecol Res* 2002, **28**:71–75.
15. Deren O, Ozyuncu O, Onderoglu LS, Durukan T: **Alcohol injection for the intrauterine treatment of chorioangioma in a pregnancy with transfusion resistant fetal anemia: a se report.** *Fetal Diagn Ther* 2007, **22**:203–205.
16. Bermudez C, Luengas O, Perez-Wulff J, Genatios U, Garcia V, Guevara-Zuloaga F, Quintero RA: **Management of a placental chorioangioma with endoscopic devascularization and intrauterine transfusions.** *Ultrasound Obstet Gynecol* 2007, **29**:97–98.
17. Quarello E, Bernard JP, Leroy B, Ville Y: **Prenatal laser treatment of a placental chorioangioma.** *Ultrasound Obstet Gynecol* 2005, **25**:299–301.
18. Mendez-Figueroa H, Papanna R, Popek EJ, Byrd RH, Goldaber K, Moise KJ, Jonson A: **Endoscopic laser coagulation following amnioreduction for the management of a large placental chorioangioma.** *Prenat Diagn* 2009, **29**:1277–1278.
19. Braun T, Brauer M, Fuchs I, Czernik C, Dudenhausen J, Henrich W, Sarioglu N: **Mirror Syndrome: A Systematic Review of Fetal Associated Conditions, Maternal Presentation and Perinatal Outcome.** *Fetal Diagn Ther* 2010, **27**:191–203.
20. Dorman SL, Cardwell MS: **Ballantyne syndrome caused by a large placental chorioangioma.** *Am J Obstet Gynecol* 1995, **173**:1632–1633.
21. Gherman RB, Incerpi MH, Wing DA, Goodwin TM: **Ballantyne syndrome: is placental ischemia the etiology?** *J Matern Fetal Med* 1998, **7**:227–229.
22. Galimberti A, Jain S: **Placental chorioangioma as a cause of maternal hydrops syndrome.** *J Obstet Gynaecol* 2000, **20**:91.
23. Zoppini C, Acaia B, Lucci G, Pugni L, Tassis B, Nicolini U: **Varying Clinical Course of large Placental Chorioangiomas. Report of 3 cases.** *Fetal Diagn Ther* 1997, **12**:61–64.

doi:10.1186/1471-2393-12-72

Cite this article as: García-Díaz et al.: Prenatal management and perinatal outcome in giant placental chorioangioma complicated with hydrops fetalis, fetal anemia and maternal mirror syndrome. *BMC Pregnancy and Childbirth* 2012 **12**:72.

Submit your next manuscript to BioMed Central and take full advantage of:

- Convenient online submission
- Thorough peer review
- No space constraints or color figure charges
- Immediate publication on acceptance
- Inclusion in PubMed, CAS, Scopus and Google Scholar
- Research which is freely available for redistribution

Submit your manuscript at
www.biomedcentral.com/submit

