



promising TMS features that could account for STN-DBS. TBS-TMS is supposed to modulate expression of brain-derived neurotrophic factor or cFOS, increase GABAergic activity,¹⁵ and modulate N-methyl-D-aspartate receptor activity¹⁴; however, the transfer of these mechanisms to STN-DBS remains hypothetical at this time.

Findings from a previous study indicate that DBS pattern variations might result in similar clinical results within interburst time ranges of 0.1 to 0.5 seconds.¹⁶ LF-TBS with low intraburst frequencies might have dropped outside the efficacious window, resulting in higher required dosages.

In summary, this short-term, randomized, double-blind, clinical trial represents the first step in the development of new, patterned DBS stimulation forms by demonstrating safety, efficiency, and partial enhancement of therapeutic window width depending on TBS intraburst frequency. ■

Acknowledgment: This work has been supported by the DFG SFB 936, project C8.

References

1. Deuschl G, Schade-Brittinger C, Krack P, et al. A randomized trial of deep-brain stimulation for Parkinson's disease. *N Engl J Med* 2006;355:896–908.
2. Schuepbach WM, Rau J, Knudsen K, et al. Neurostimulation for Parkinson's disease with early motor complications. *N Engl J Med* 2013;368:610–622.
3. Herzog J, Volkmann J, Krack P, et al. Two-year follow-up of subthalamic deep brain stimulation in Parkinson's disease. *Mov Disord* 2003;18:1332–1337.
4. Kleiner-Fisman G, Herzog J, Fisman DN, et al. Subthalamic nucleus deep brain stimulation: summary and meta-analysis of outcomes. *Mov Disord* 2006;21(Suppl. 14):S290–S304.
5. Deuschl G, Herzog J, Kleiner-Fisman G, et al. Deep brain stimulation: postoperative issues. *Mov Disord* 2006;21(Suppl. 14):S219–S237.
6. Pötter-Nerger M, Volkmann J. Deep brain stimulation for gait and postural symptoms in Parkinson's disease. *Mov Disord* 2013;28:1609–1615.
7. Koss AM, Alterman RL, Tagliati M, Shils JL. Calculating total electrical energy delivered by deep brain stimulation systems. *Ann Neurol* 2005;58:168; author reply, 168–169.
8. Defer GL, Widner H, Marie RM, Remy P, Levivier M. Core Assessment program for surgical interventional therapies in Parkinson's disease (CAPSIT-PD). *Mov Disord* 1999;14:572–584.
9. Tass PA, Qin L, Hauptmann C, et al. Coordinated reset has sustained aftereffects in Parkinsonian monkeys. *Ann Neurol* 2012;72:816–820.
10. Adamchic I, Hauptmann C, Barnikol UB, et al. Coordinated reset neuromodulation for Parkinson's disease: proof-of-concept study. *Mov Disord* 2014;29:1679–1684.
11. Milosevic L, Kalia SK, Hodaie M, et al. Neuronal inhibition and synaptic plasticity of basal ganglia neurons in Parkinson's disease. *Brain* 2018;141:177–190.
12. Siebner HR, Rothwell J. Transcranial magnetic stimulation: new insights into representational cortical plasticity. *Exp Brain Res* 2003;148:1–16.
13. Cirillo G, Di Pino G, Capone F, et al. Neurobiological after-effects of non-invasive brain stimulation. *Brain Stimul* 2017;10:1–18.
14. Huang YZ, Edwards MJ, Rounis E, Bhatia KP, Rothwell JC. Theta burst stimulation of the human motor cortex. *Neuron* 2005;45:201–206.
15. Cardenas-Morales L, Nowak DA, Kammer T, Wolf RC, Schonfeldt-Lecuona C. Mechanisms and applications of theta-burst rTMS on the human motor cortex. *Brain Topogr* 2010;22:294–306.
16. Montgomery EB, Jr. Effect of subthalamic nucleus stimulation patterns on motor performance in Parkinson's disease. *Parkinsonism Relat Disord* 2005;11:167–171.

Changes in Regional Cerebral Perfusion Over Time in Idiopathic REM Sleep Behavior Disorder

Andrée-Ann Baril, PhD,^{1,2} Jean-François Gagnon, PhD,^{3,4} Amélie Pelletier, PhD,^{3,5} Jean-Paul Soucy, MD, MSc,⁶ Nadia Gosselin, PhD,^{3,7} Ronald B. Postuma, MD, MSc,^{3,5,8} and Jacques Montplaisir, MD, PhD^{3,9*}

¹The Framingham Heart Study, Framingham, Massachusetts, USA

²Department of Neurology, Boston University School of Medicine, Boston, Massachusetts, USA

³Center for Advanced Research in Sleep Medicine, Hôpital du Sacré-Coeur de Montréal, Centre

intégré universitaire de santé et de services sociaux du Nord de

l'île-de-Montréal, Montreal, Canada

⁴Department of Psychology, Université du Québec à Montréal, Montreal, Canada

⁵Research Institute of the McGill University Health Centre, Montreal, Canada

⁶Montreal Neurological Institute, McGill University, Montreal, Canada

⁷Department of Psychology, Université de Montréal, Montreal, Canada

⁸Department of Neurology, McGill University, Montreal General Hospital, Montreal, Canada

⁹Department of Psychiatry, Université de Montréal, Montreal, Canada

ABSTRACT: Background: Idiopathic rapid eye movement sleep behavior disorder is associated with increased risk of neurodegeneration, but the temporal evolution of regional perfusion, a marker of cerebral activity, has not been characterized. The objective of

***Correspondence to:** Dr. Jacques Montplaisir, Centre for Advanced Research in Sleep Medicine, Hôpital du Sacré-Coeur de Montréal, CIUSSS-du-Nord-de-l'île-de-Montréal, 5400 boulevard Gouin Ouest, Montreal, Quebec, H4J 1C5, Canada; E-mail: jy.montplaisir@umontreal.ca

Relevant conflicts of interest/financial disclosures: A.A.B., J.F.G., and N.G. report salary or fellowship from the Canadian Institutes of Health Research and the Fonds de recherche du Québec – Santé. R.B.P. reports grants and personal fees from Roche, Michael J. Fox Foundation, and the Webster Foundation. J.F.G. holds a Canada Research Chair in Cognitive Decline in Pathological Aging. J.M. holds a Canada Research Chair in Cognitive Decline in Pathological Aging.

Funding agencies: This study was funded by the Canadian Institutes of Health Research, the Fonds de recherche du Québec – Santé, and W. Garfield Weston Foundation.

Received: 25 January 2020; **Revised:** 9 April 2020; **Accepted:** 13 April 2020

Published online 27 May 2020 in Wiley Online Library (wileyonlinelibrary.com). DOI: 10.1002/mds.28092

the current study was to study longitudinal regional perfusion in patients with idiopathic rapid eye movement sleep behavior disorder.

Methods: Thirty-seven patients and 23 controls underwent high-resolution single-photon emission computed tomography. After 17 months on average, scans were repeated for idiopathic rapid eye movement sleep behavior disorder patients. We compared regional cerebral blood flow between groups and over time.

Results: At baseline, patients showed lower relative regional perfusion in the anterior frontal and lateral parietotemporal cortex compared with controls. However, over time, patients showed an increase in relative regional perfusion in the anterior frontal, lateral parietal, and occipitotemporal cortex, reverting toward normal control levels.

Conclusions: Patients with idiopathic rapid eye movement sleep behavior disorder showed significant areas of relative regional hypoperfusion, which disappeared over time to finally return to average levels, suggesting possible developing compensation in areas affected by neurodegeneration. © 2020 International Parkinson and Movement Disorder Society

Key Words: regional cerebral blood flow; REM sleep behavior disorder; single-photon emission computed tomography; synucleinopathy

Idiopathic rapid-eye-movement (REM) sleep behavior disorder (iRBD) is characterized by a loss of muscle atonia during REM sleep, leading to dream enactment behaviors.^{1,2} Most iRBD patients convert to a neurodegenerative synucleinopathy, including Parkinson's disease (PD) or dementia with Lewy bodies (DLB).³ iRBD patients present subtle motor, cognitive, olfactory, color vision, and autonomic dysfunctions, all of which are symptoms of α -synucleinopathies.^{1,3}

One neuroimaging biomarker that shows promise in iRBD is regional cerebral blood flow (rCBF).^{4,5} Compared with controls, iRBD patients have lower relative cortical rCBF, as well as increased relative perfusion in the brain stem, basal ganglia, and hippocampus.⁵⁻¹¹ These rCBF distribution anomalies in subcortical areas have been shown to predict phenoconversion.^{6,10} However, the temporal evolution of cerebral perfusion distribution in iRBD patients is unclear. One study in 9 patients found a relative posterior cortical decrease over 23 months,¹² suggesting that longitudinal rCBF mapping could show the progression of neurodegeneration.

Evaluating cerebral activity changes in iRBD may contribute to our understanding of how prodromal synucleinopathies evolve and lead to possible disease-modifying therapies to prevent phenoconversion.¹³ The aim of this study was to evaluate how regional

cerebral perfusion patterns change over time in iRBD patients.

Methods

Participants and Protocol

This study is part of a longitudinal research program that follows patients with polysomnography-confirmed iRBD.^{14,15} Briefly, we included a subset of 37 iRBD patients who had undergone at least 2 single-photon emission computed tomography (SPECT) examinations. Patients were evaluated at each visit for potential phenoconversion to parkinsonism or dementia according to standard criteria during an assessment by a movement disorder specialist and a neuropsychologist.^{16,17} Twenty-three healthy controls were also recruited through newspaper advertisements or word of mouth and evaluated with a single SPECT acquisition. The neurological and neuropsychological examinations included the assessment of motor, sensory, and autonomic functions, as well as global cognition and individual cognitive domains.¹⁸ Mild cognitive impairment (MCI) status was determined according to published criteria.¹⁸

The polysomnography protocol was published previously.¹⁹ At the participant's first visit, polysomnography to confirm the presence of REM without atonia to diagnose RBD was performed. iRBD patients met the diagnosis criteria of the International Classification of Sleep Disorders-III.^{19,20}

Exclusion criteria for all participants at any visit were the presence of parkinsonism or dementia, major psychiatric disorders, other neurological disorders, and other sleep disorders. In controls, participants with RBD or MCI were excluded. The protocol was approved by the Ethics Committee of the centre intégré universitaire de santé et de services sociaux du Nord-de-l'Île-de-Montréal. All participants gave their written informed consent.

SPECT Acquisitions and Image Processing

iRBD patients underwent 2 ^{99m}Tc-HMPAO SPECT sessions with a high-resolution brain-dedicated scanner (NeuroFOCUS, NeuroPhysics, Shirley, MA), whereas healthy controls underwent 1 session. All participants were injected with a dose of 750 MBq of ^{99m}Tc-HMPAO followed by a 30-cc saline flush while lying awake with their eyes closed. HMPAO is distributed in the brain proportionally to local blood flow, and thus, SPECT scanning with this tracer estimates CBF distribution.²¹ This scanner does not record the whole cerebellum and brain stem, which were excluded from analyses. Details of the acquisition procedure and preprocessing of SPECT images were published previously.^{22,23} Briefly, individual SPECT images were registered and spatially normalized to the standard SPECT template in Statistical Parametric Mapping 8. Normalized images were smoothed using a 14-mm full-width

half-maximum filter and proportionally scaled for individual global mean signal, a method limiting intersubject variability in radiotracer uptake previously used by others in iRBD populations.^{6,8,10} Therefore, rCBF results do not represent absolute perfusion but rather show regional variations relative to global cerebral perfusion. Note that the average global signal did not change over time in patients, with an average of 0.27% difference between scans. To confirm our findings, analyses were performed again using the mean white matter signal for proportional scaling as an alternative measure of global mean signal.^{24,25}

Statistical Analysis

Three different designs were used in SPM12 to compare rCBF distribution between: patients and controls at baseline (independent), patients at baseline and follow-up (paired), and patients at follow-up and controls at baseline (independent). A mask covering the gray matter was applied. Findings were considered significant at $P < 0.05$ for clusters corrected for multiple comparisons using a false discovery rate. When significant findings were observed, clusters' values expressed as a percentage of global signal were extracted, and the average difference between groups and/or scans was computed.

Results

Characteristics of participants are outlined in Table 1, and the cohort has been extensively described elsewhere.^{3,14,15} In patients, the average time between SPECT acquisitions was 16.6 months (median, 12 months; 9–32 months). Of the 36 patients still in active follow-up, 5 developed parkinsonian symptoms, and 4 developed DLB 1 to 5 years after the second SPECT study.

Areas With Lower Relative rCBF in iRBD Patients at Baseline

Compared with controls, patients at baseline had lower relative rCBF in the orbitofrontal cortex extending to the parietal and temporal cortices (Fig. 1A; -5.7% and -4.5% of the global mean for all and frontal clusters, respectively). No regions of higher relative rCBF in patients were observed. When analyses were scaled to white-matter signal instead of the global mean, results remained significant in the exact same areas, although cluster sizes decreased slightly (4062 voxels).

Perfusion Renormalization: Areas With Relative rCBF Increasing Over Time in iRBD Patients

Over time, patients showed increasing relative rCBF, especially in the orbitofrontal cortex as well as in the parietal, temporal, and occipital cortices (Fig. 1B; $+3.3\%$ and $+3.5\%$ over time of the global mean for all and frontal clusters, respectively). Adjusting for follow-up duration did

not affect the results. No regions of diminishing relative rCBF were observed. When comparing patients at follow-up with controls, no significant difference was observed, suggesting normalization of the rCBF pattern over time. When scaling with white-matter signal instead of global signal, results remained significant in the frontal cortex bilaterally as well as in the right postcentral and fusiform gyri (3556 voxels).

Secondary Analyses: iRBD Subgroups

We split patients into 2 subgroups: patients with increasing relative rCBF resulting in perfusion pattern normalization over time in most significant clusters ($n = 19$, $+4.6\%$ over time of the global mean, ≥ 3 clusters with clear increasing rCBF, ≤ 1 cluster with decreasing rCBF); and the remaining patients who showed areas of a mostly stable rCBF pattern in most clusters ($n = 18$, $+1.9\%$ over time of the global mean, not meeting criteria described above). Patients with rCBF pattern normalization over time had shorter iRBD duration and a higher proportion of MCI at baseline compared with those without pattern normalization (8.9 ± 7.3 vs 15.1 ± 10.3 years; 43.8% vs. 8.3% of MCI; $P < 0.05$). At both baseline and follow-up, patients with an rCBF pattern showing normalization had poorer verbal memory performance than those without (immediate and delayed recall, recognition, $P < 0.005$). No difference between subgroups in the phenoconversion rate was observed.

Compared with controls, patients with rCBF pattern normalization over time showed initial widespread relative hypoperfusion in the frontal, temporal, parietal, and occipital lobes at baseline. Interestingly, they also displayed higher relative rCBF at baseline in the medial temporal cortex, hippocampus, and thalamus bilaterally. Conversely, patients without observable rCBF pattern normalization over time had only localized relative hypoperfusion at baseline in the orbitofrontal cortex compared with controls. When we directly compared patients with and without normalizing rCBF patterns at baseline, those with normalizing rCBF patterns had relative hypoperfusion in the parietal, temporal, and occipital cortex.

Discussion

We evaluated longitudinal regional cerebral perfusion patterns in iRBD patients and found that, over 17 months, patients showed increasing relative rCBF in several cortical regions, especially the orbitofrontal cortex. Interestingly, most of these regions were relatively hypoperfused compared with controls at baseline, and those regional hypoperfusions disappeared at follow-up. This renormalization of their rCBF pattern over time could suggest compensatory mechanisms in iRBD patients. Patients with rCBF pattern normalization over

TABLE 1. Sleep, clinical, and neuropsychological characteristics of participants at baseline and follow-up

	Controls (A)	iRBD (baseline) (B)	iRBD (follow-up) (C)	(A) vs (B)	(A) vs (C)	(B) vs (C)
n	23	37	37			
Age (years)	67.5 ± 7.0	65.8 ± 8.6	67.1 ± 8.6			
Sex, n (% male)	18 (78.3)	28 (75.7)	—			
Tonic REM sleep EMG (%)	5.3 ± 3.8	58.4 ± 32.1	—	c		
Phasic REM sleep EMG (%)	14.7 ± 5.3	41.9 ± 19.7	—	c		
iRBD symptom duration (years)	—	11.8 ± 9.3	—			
iRBD diagnostic (years)	—	2.5 ± 4.4	—			
Motor, sensory, and autonomic functions						
MDS-UPDRS I	0.4 ± 0.7	1.6 ± 2.0	1.5 ± 2.0	a	a	
MDS-UPDRS II	0.5 ± 0.8	1.3 ± 1.5	2.3 ± 2.8	a	b	
MDS-UPDRS III	2.3 ± 1.9	5.0 ± 4.4	7.4 ± 6.2	a	c	
MDS-UPDRS III-action tremor	1.9 ± 1.6	4.3 ± 4.0	6.2 ± 5.6	a	c	
Alternate-Tap Test	195.2 ± 23.4	181.7 ± 26.3	172.1 ± 37.7		a	
Purdue PegBoard	11.4 ± 1.9	11.4 ± 2.2	10.9 ± 2.1			
Brief Smell Identification Test	10.8 ± 1.1	7.2 ± 2.7	6.6 ± 2.6	c	c	
Farnsworth-Munsell 100-Hue Test	138.1 ± 75.4	165.7 ± 87.5	168.9 ± 137.4			
Systolic blood pressure drop (mm Hg)	3.1 ± 5.1	10.9 ± 11.1	13.7 ± 14.0	a	b	
Orthostatic symptoms, n (%)	3 (14.0)	6 (19.4)	13 (44.8)		a	a
Urinary dysfunction, n (%)	5 (23.8)	11 (35.5)	10 (34.5)			
Erectile dysfunction in men, n (%)	5 (33.3)	14 (60.9)	11 (57.9)			
Constipation, n (%)	2 (10.0)	10 (32.3)	7 (24.1)			
Neuropsychological performance						
MoCA	27.7 ± 1.8	25.1 ± 3.5	25.4 ± 4.4	c	a	
Forward Digit Span	6.3 ± 1.1	5.4 ± 0.9	5.8 ± 1.1	c		
Backward Digit Span	4.6 ± 1.4	4.2 ± 1.1	4.0 ± 1.2			
Trail Making Test Part B (s)	75.0 ± 32.7	95.5 ± 50.6	98.0 ± 40.1		a	
Stroop III (errors)	4.1 ± 11.4	2.6 ± 3.7	3.6 ± 10.4			
Stroop III-I (s)	0.0 ± 1.9	-0.04 ± 2.9	-0.1 ± 2.1			
Semantic verbal fluency	39.5 ± 6.2	35.2 ± 8.4	36.1 ± 7.4	a		
Phonetic verbal fluency	42.1 ± 12.5	35.3 ± 11.4	34.7 ± 10.6		a	
RAVLT – total 1 to 5	48.7 ± 6.1	41.1 ± 10.7	42.1 ± 12.1	b	a	
RAVLT – list B	4.7 ± 1.7	4.1 ± 1.6	4.4 ± 1.9			
RAVLT – immediate recall	11.1 ± 2.5	7.8 ± 2.6	8.5 ± 3.5	c	b	
RAVLT – delayed recall	10.7 ± 2.3	7.6 ± 2.9	8.0 ± 3.6	c	b	
RAVLT – recognition	14.4 ± 0.7	13.5 ± 1.5	13.7 ± 1.5	b	a	
ROCF – copy	30.7 ± 3.7	30.1 ± 6.3	30.6 ± 5.5			
Bells Test – omissions	2.2 ± 2.2	2.9 ± 3.0	2.3 ± 2.9			
Block design	35.3 ± 12.3	34.2 ± 12.7	33.5 ± 12.7			
Mild cognitive impairment, n (%)	0 (0.0)	8 (28.6)	8 (27.7)	a	a	

RBD, idiopathic rapid eye movement sleep behavior disorder; EMG, electromyogram; REM, rapid eye movement; MDS-UPDRS, Movement Disorder Society Unified Parkinson's Disease Rating Scale; MoCA, Montreal Cognitive Assessment; RAVLT, Rey Auditory Verbal Learning Test; ROCF, Rey-Osterrieth Complex Figure.

Results are mean ± standard deviation.

^aP < 0.05.

^bP < 0.01.

^cP < 0.005.

time showed widespread relative hypoperfusion and localized relative hyperperfusion at baseline, as well as more cognitive impairment, suggesting heterogeneity among patients. In fact, rCBF variations over time might be especially present in patients with more markers of phenoconversion. Our findings suggest that longitudinally mapping cerebral perfusion distribution in iRBD to evaluate relative rCBF allocations of different regions could contribute to understanding how the brain copes with α -synuclein pathology.

Consistent with our findings, cross-sectional studies have reported lower relative perfusion over several

frontal, parietal, and temporal regions in iRBD patients compared with controls.^{6-8,11,12} Because rCBF is closely related to neuronal and astroglial activity, lower relative perfusion might reflect either cellular dysfunction secondary to α -synuclein pathology or loss of excitatory inputs in these cerebral structures compared with others.^{26,27} In PD and DLB, hypoperfusion is observed in the frontal, parietal, and temporal cortices,²⁸⁻³⁵ somewhat similar to our findings in iRBD.

Over time, we found widespread relative regional increases in cerebral perfusion that renormalized

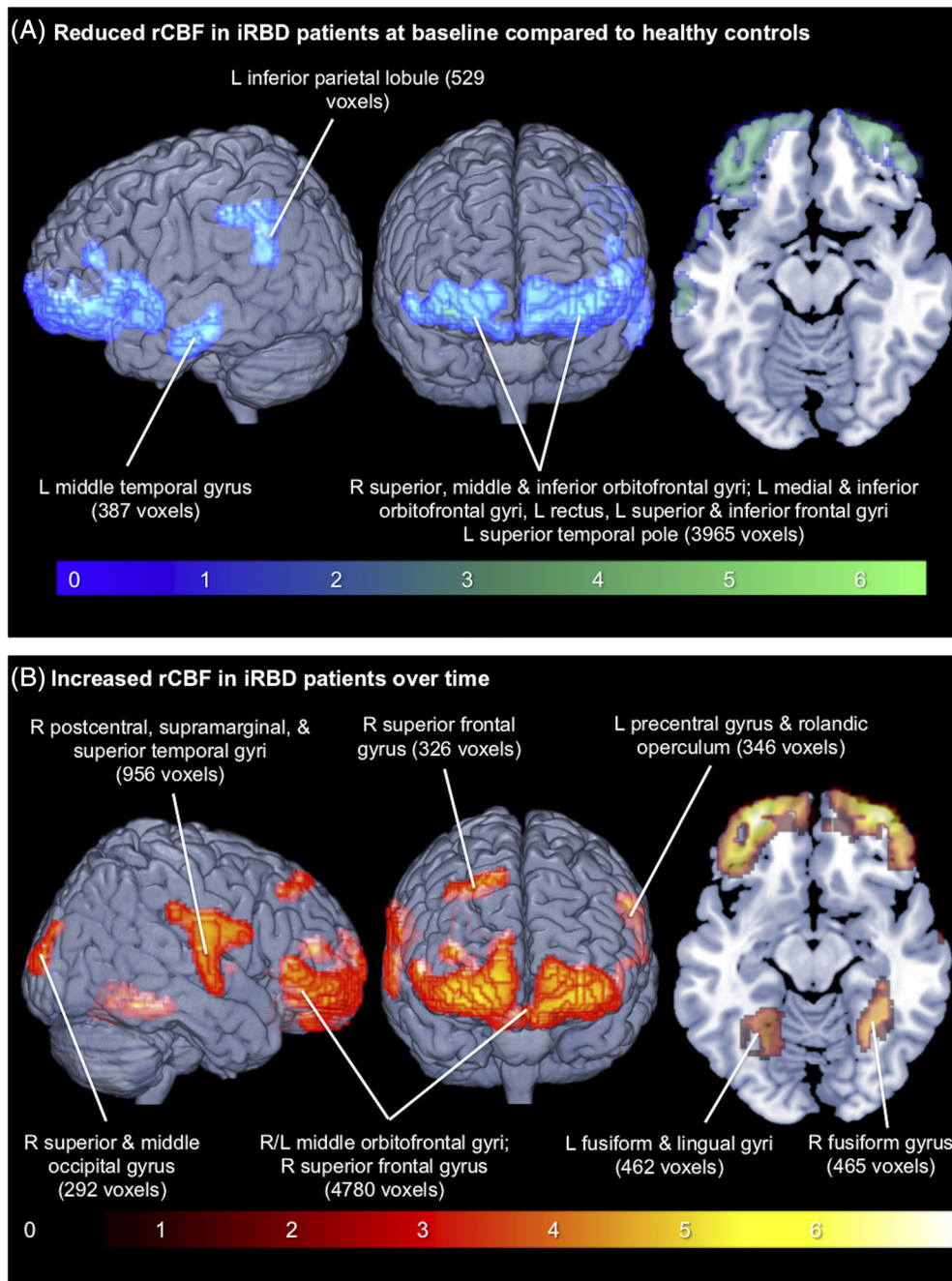


FIG. 1. Relative rCBF changes in iRBD patients **(A)** compared with controls and **(B)** over 17 months. Blue-green, lower rCBF; red-yellow, increased rCBF. Scales show t values in significant regions ($P < 0.05$ false-discovery rate-corrected for multiple comparisons). rCBF, regional cerebral blood flow; iRBD, idiopathic rapid eye movement sleep behavior disorder; L, left; R, right.

rCBF patterns in patients. Only 1 previous study evaluated longitudinal perfusion changes in 9 iRBD patients, and it found lower perfusion over the medial parietal and cingulate cortices.¹² Regional relative hyperperfusion was previously reported over subcortical regions in iRBD patients compared with controls, and this also predicted phenotypic conversion.^{6-8,10,11} Similarly, in our sample, patients

with normalization of a regional perfusion pattern over time had higher relative rCBF at baseline in the medial temporal cortex, hippocampus, and thalamus. As hypothesized before,⁵ cerebral activity in iRBD patients seems to undergo complex modifications with areas of relative hypoperfusion and hyperperfusion varying over time, which could explain discrepancies between studies.

Our findings show that the rCBF pattern normalizes over time in iRBD patients. Higher relative rCBF is hypothesized to be an attempt at functional compensation in cerebral regions potentially affected by α -synuclein pathology in iRBD,^{11,36} DLB, and PD dementia.^{33,37} iRBD patients with rCBF pattern normalization had corresponding widespread hypoperfusions at baseline and more cognitive impairment, suggesting more severe underlying pathology. In patients with amnesic MCI, regional transient hypermetabolism was predictive of conversion to Alzheimer's disease,³⁸ suggesting that areas affected by pathology might attempt functional compensation to prevent clinical expression. Further studies should evaluate whether rCBF pattern normalization over time is similar between RBD patients with MCI compared with MCI alone. Moreover, the link between rCBF pattern normalization over time and phenoconversion should be clarified.

The limits of this study include few phenoconversion cases ($n = 9$) precluding adequately-powered stratification analyses, short interscan time, lack of magnetic resonance imaging-based partial volume correction, and limited axial coverage of our high-resolution SPECT system that precluded assessment of the brain stem. The latter prevented us from fully evaluating the Parkinson's disease-related pattern previously described in iRBD,^{10,39,40} although our findings are partially consistent with this pattern (ie, lower relative parietal rCBF, higher relative thalamic and precentral rCBF).

In this study with a large iRBD sample investigated prospectively with perfusion SPECT, we found interplay of relative cerebral hypoperfusion at baseline and normalization over time, which was especially marked in the orbitofrontal cortex. Relative perfusion normalization in affected brain regions of iRBD patients with a higher risk of phenoconversion may represent attempted functional compensation. ■

References

- Hogl B, Stefani A, Videnovic A. Idiopathic REM sleep behaviour disorder and neurodegeneration - an update. *Nat Rev Neurol* 2018;14(1):40–55.
- Schenck CH, Mahowald MW. REM sleep behavior disorder: clinical, developmental, and neuroscience perspectives 16 years after its formal identification in SLEEP. *Sleep* 2002;25(2):120–138.
- Postuma RB, Iranzo A, Hu M, et al. Risk and predictors of dementia and parkinsonism in idiopathic REM sleep behaviour disorder: a multicentre study. *Brain* 2019;142(3):744–759.
- Bourgouin PA, Rahayel S, Gaubert M, et al. Neuroimaging of rapid eye movement sleep behavior disorder. *Int Rev Neurobiol* 2019;144:185–210.
- Heller J, Brcina N, Dogan I, et al. Brain imaging findings in idiopathic REM sleep behavior disorder (RBD) - a systematic review on potential biomarkers for neurodegeneration. *Sleep Med Rev* 2017;34:23–33.
- Dang-Vu TT, Gagnon JF, Vendette M, Soucy JP, Postuma RB, Montplaisir J. Hippocampal perfusion predicts impending neurodegeneration in REM sleep behavior disorder. *Neurology* 2012;79(24):2302–2306.
- Vendette M, Gagnon JF, Soucy JP, et al. Brain perfusion and markers of neurodegeneration in rapid eye movement sleep behavior disorder. *Mov Disord* 2011;26(9):1717–1724.
- Vendette M, Montplaisir J, Gosselin N, et al. Brain perfusion anomalies in rapid eye movement sleep behavior disorder with mild cognitive impairment. *Mov Disord* 2012;27(10):1255–1261.
- Hanyu H, Inoue Y, Sakurai H, et al. Regional cerebral blood flow changes in patients with idiopathic REM sleep behavior disorder. *Eur J Neurol* 2011;18(5):784–788.
- Holtbernd F, Gagnon JF, Postuma RB, et al. Abnormal metabolic network activity in REM sleep behavior disorder. *Neurology* 2014;82(7):620–627.
- Mazza S, Soucy JP, Gravel P, et al. Assessing whole brain perfusion changes in patients with REM sleep behavior disorder. *Neurology* 2006;67(9):1618–1622.
- Sakurai H, Hanyu H, Inoue Y, et al. Longitudinal study of regional cerebral blood flow in elderly patients with idiopathic rapid eye movement sleep behavior disorder. *Geriatr Gerontol Int* 2014;14(1):115–120.
- Postuma RB, Gagnon JF, Montplaisir J. Rapid eye movement sleep behavior disorder as a biomarker for neurodegeneration: the past 10 years. *Sleep Med* 2013;14(8):763–767.
- Genier Marchand D, Postuma RB, Escudier F, et al. How does dementia with Lewy bodies start? Prodromal cognitive changes in REM sleep behavior disorder. *Ann Neurol* 2018;83(5):1016–1026.
- Postuma RB, Gagnon JF, Bertrand JA, Genier Marchand D, Montplaisir JY. Parkinson risk in idiopathic REM sleep behavior disorder: preparing for neuroprotective trials. *Neurology* 2015;84(11):1104–1113.
- McKeith IG, Boeve BF, Dickson DW, et al. Diagnosis and management of dementia with Lewy bodies: fourth consensus report of the DLB consortium. *Neurology* 2017;89(1):88–100.
- Postuma RB, Berg D, Stern M, et al. MDS clinical diagnostic criteria for Parkinson's disease. *Mov Disord* 2015;30(12):1591–1601.
- Genier Marchand D, Montplaisir J, Postuma RB, Rahayel S, Gagnon JF. Detecting the cognitive prodrome of dementia with Lewy bodies: a prospective study of REM sleep behavior disorder. *Sleep* 2017;40(1).
- Montplaisir J, Gagnon JF, Fantini ML, et al. Polysomnographic diagnosis of idiopathic REM sleep behavior disorder. *Mov Disord* 2010;25(13):2044–2051.
- American Academy of Sleep Medicine. *International Classification of Sleep Disorders*. 3rd ed. Westchester, IL: American Academy of Sleep Medicine; 2014.
- Duncan R, Patterson J, Macrae IM. HMPAO as a regional cerebral blood flow tracer at high flow levels. *J Nucl Med* 1996;37(4):661–664.

22. Baril AA, Gagnon K, Arbour C, et al. Regional cerebral blood flow during wakeful rest in older subjects with mild to severe obstructive sleep apnea. *Sleep* 2015;38(9):1439–1449.
23. Baril AA, Gagnon K, Brayer P, et al. Obstructive sleep apnea during REM sleep and daytime cerebral functioning: a regional cerebral blood flow study using high-resolution SPECT. *J Cereb Blood Flow Metab* 2018;271678X18814106.
24. Spence JS, Carmack PS, Gunst RF, Schucany WR, Woodward WA, Haley RW. Using a white matter reference to remove the dependency of global signal on experimental conditions in SPECT analyses. *Neuroimage* 2006;32(1):49–53.
25. Borghammer P. Perfusion and metabolism imaging studies in Parkinson's disease. *Dan Med J* 2012;59(6):B4466.
26. Derejko M, Slawek J, Lass P, Nyka WM. Cerebral blood flow changes in Parkinson's disease associated with dementia. *Nucl Med Rev Cent East Eur* 2001;4(2):123–127.
27. Morbelli S, Chincarini A, Brendel M, et al. Metabolic patterns across core features in dementia with lewy bodies. *Ann Neurol* 2019;85(5):715–725.
28. Colloby SJ, Fenwick JD, Williams ED, et al. A comparison of (99m)Tc-HMPAO SPET changes in dementia with Lewy bodies and Alzheimer's disease using statistical parametric mapping. *Eur J Nucl Med Mol Imaging* 2002;29(5):615–622.
29. Fong TG, Inouye SK, Dai W, Press DZ, Alsup DC. Association cortex hypoperfusion in mild dementia with Lewy bodies: a potential indicator of cholinergic dysfunction? *Brain Imaging Behav* 2011;5(1):25–35.
30. Jeong HS, Chung YA, Park JS, Song IU, Yang Y. Long-term efficacy of memantine in Parkinson's disease dementia: an 18-month prospective perfusion single photon emission computed tomography preliminary study. *Dement Neurocogn Disord* 2016;15(2):43–48.
31. Mito Y, Yoshida K, Yabe I, et al. Brain 3D-SSP SPECT analysis in dementia with Lewy bodies, Parkinson's disease with and without dementia, and Alzheimer's disease. *Clin Neurol Neurosurg* 2005;107(5):396–403.
32. Paschali A, Messinis L, Kargiotis O, et al. SPECT neuroimaging and neuropsychological functions in different stages of Parkinson's disease. *Eur J Nucl Med Mol Imaging* 2010;37(6):1128–1140.
33. Roquet D, Sourty M, Botzung A, Armspach JP, Blanc F. Brain perfusion in dementia with Lewy bodies and Alzheimer's disease: an arterial spin labeling MRI study on prodromal and mild dementia stages. *Alzheimers Res Ther* 2016;8:29.
34. Song IU, Yoo I, Chung YA, Jeong J. The value of brain perfusion SPECT for differentiation between mildly symptomatic idiopathic Parkinson's disease and the Parkinson variant of multiple system atrophy. *Nucl Med Commun* 2015;36(10):1049–1054.
35. Van Laere K, Santens P, Bosman T, De Reuck J, Mortelmans L, Dierckx R. Statistical parametric mapping of (99m)Tc-ECD SPECT in idiopathic Parkinson's disease and multiple system atrophy with predominant parkinsonian features: correlation with clinical parameters. *J Nucl Med* 2004;45(6):933–942.
36. Bedard MA, Aghourian M, Legault-Denis C, et al. Brain cholinergic alterations in idiopathic REM sleep behaviour disorder: a PET imaging study with (18)F-FE0BV. *Sleep Med* 2019;58:35–41.
37. Firbank MJ, Burn DJ, McKeith IG, O'Brien JT. Longitudinal study of cerebral blood flow SPECT in Parkinson's disease with dementia, and dementia with Lewy bodies. *Int J Geriatr Psychiatry* 2005;20(8):776–782.
38. Fouquet M, Desgranges B, Landeau B, et al. Longitudinal brain metabolic changes from amnesic mild cognitive impairment to Alzheimer's disease. *Brain* 2009;132(Pt 8):2058–2067.
39. Meles SK, Vadasz D, Renken RJ, et al. FDG PET, dopamine transporter SPECT, and olfaction: combining biomarkers in REM sleep behavior disorder. *Mov Disord* 2017;32(10):1482–1486.
40. Wu P, Yu H, Peng S, et al. Consistent abnormalities in metabolic network activity in idiopathic rapid eye movement sleep behaviour disorder. *Brain* 2014;137(Pt 12):3122–3128

A Pooled Analysis From Phase 2b and 3 Studies in Japan of Istradefylline in Parkinson's Disease

Nobutaka Hattori, MD,^{1*} Hiroki Kitabayashi, MSc,² Tomoyuki Kanda, PhD,² Takanobu Nomura, PhD,² Keizo Toyama, MSc,³ and Akihisa Mori, PhD²

¹Department of Neurology, Juntendo University School of Medicine, Tokyo, Japan ²Medical Affairs Department, Kyowa Kirin Co., Ltd., Tokyo, Japan ³R&D Division, Kyowa Kirin Co., Ltd., Tokyo, Japan

ABSTRACT: Background: Characterization of patient factors associated with istradefylline efficacy may facilitate personally optimized treatment.

Objectives: We aimed to examine which patient factors are associated with favorable istradefylline treatment outcomes in PD patients with motor complications.

Methods: We performed a pooled analysis of data from two identical phase 2b and 3 Japanese studies of istradefylline. Logistic regression models were used to assess the association of 12 patient characteristics with favorable outcomes.

Results: *Off* time reduction and increased good *on* time with istradefylline provided a significantly favorable response in patients aged ≥65 years. *Off* time reduction was more favorable in patients with ≥8-hour daily *off* time at baseline. Improvement in UPDRS Part III was favorable in patients with UPDRS Part III baseline score ≥ 20.

This is an open access article under the terms of the Creative Commons Attribution License, which permits use, distribution and reproduction in any medium, provided the original work is properly cited.

*Correspondence to: Prof. Nobutaka Hattori, Department of Neurology, Juntendo University School of Medicine, 2-1-1, Hongo, Bunkyo-ku, Tokyo 113-8421, Japan; E-mail: nhattori@juntendo.ac.jp

Relevant conflicts of interest/financial disclosures: Nobutaka Hattori has received honoraria for manuscript writing and advisory board fees from Kyowa Kirin Co., Ltd. and has a patent pending for an anti-parkinsonian agent. Hiroki Kitabayashi is an employee of Kyowa Kirin Co., Ltd. and has a patent pending for an antiparkinsonian agent. Takanobu Nomura is an employee of Kyowa Kirin Co., Ltd. and has a patent pending for an antiparkinsonian agent. Tomoyuki Kanda is an employee of Kyowa Kirin Co., Ltd. and has a patent pending for an anti-parkinsonian agent. Keizo Toyama is an employee of Kyowa Kirin Co., Ltd. Akihisa Mori is an employee of Kyowa Kirin Co., Ltd. and has a patent pending for an antiparkinsonian agent.

Full financial disclosures and author roles may be found in the online version of this article.

Funding agencies: Kyowa Kirin, Co., Ltd. funded data collection, data analysis, and medical writing by the contract research organization.

Received: 3 November 2019; **Revised:** 17 April 2020; **Accepted:** 19 April 2020

Published online 5 June 2020 in Wiley Online Library (wileyonlinelibrary.com). DOI: 10.1002/mds.28095