



A large deletion in the adRP gene *PRPF31*: evidence that haploinsufficiency is the cause of disease

Leen Abu-Safieh,¹ Eranga N. Vithana,² Irmela Mantel,³ Graham E. Holder,³ Lucia Pelosini,³ Alan C. Bird,³ Shomi S. Bhattacharya¹

(The first two authors contributed equally to this publication)

¹Institute of Ophthalmology, University College London, London, UK; ²Singapore Eye Research Institute, Singapore; ³Moorfields Eye Hospital, London, UK

Purpose: To report a large deletion that encompasses more than 90% of *PRPF31* gene and two other neighboring genes in their entirety in an adRP pedigree that appears to show only the typical clinical features of retinitis pigmentosa.

Methods: To identify *PRPF31* mutation in a dominant RP family (ADRP2) previously linked to the RP11 locus, the 14 exons of *PRPF31* were screened for mutations by direct sequencing. To investigate the possibility of a large deletion, microsatellite markers near *PRPF31* gene were analyzed by non-denaturing PAGE.

Results: Initial screening of *PRPF31* gene in the ADRP2 family did not reveal an obvious mutation. A large deletion was however suspected due to lack of heterozygosity for nearly all *PRPF31* intragenic single nucleotide polymorphism (SNPs). In order to estimate the size of the deletion, SNPs and microsatellite markers spanning and flanking *PRPF31* were analyzed in the entire ADRP2 family. Haplotype analysis with the above markers suggested a deletion of approximately 30 kb that included the putative promoter region of a novel gene *OSCAR*, the entire genomic content of genes *NDUFA3*, *TFPT* and more than 90% of *PRPF31* gene. Sequence analysis of the region flanking the potential deletion showed a high presence of *Alu* elements implicating *Alu* mediated recombination as the mechanism responsible for this event.

Conclusions: This mutation provides evidence that haploinsufficiency rather than aberrant function of mutated proteins is the cause of disease in these adRP patients with mutations in *PRPF31* gene.

Retinitis pigmentosa (RP) is a heterogeneous group of retinal dystrophies, characterized by photoreceptor cell degeneration leading to night blindness and visual field loss. Clinical manifestations include pigment deposition in the retina and attenuation of retinal blood vessels, with later de-pigmentation or atrophy of the retinal pigment epithelium. Electroretinogram (ERG) changes are present with abnormalities of both rod and cone ERGs but with the rod ERGs more affected than the cone ERGs (rod-cone dystrophy). In advanced RP both rod and cone ERG responses are undetectable [1]. With an incidence of around 1 in 3500, RP can be inherited as an X-linked, autosomal dominant or autosomal recessive condition. Autosomal dominant RP (adRP) can be caused by mutations in at least 13 genes (RetNet; Retina Disease Database), one of which is the gene *PRPF31* localized on chromosome 19q13.4 (*RP11*) [2]. The gene is comprised of 14 exons spanning approximately 16 kb of genomic DNA and encodes a ubiquitously expressed 61K splicing factor protein PRPF31, also referred to as splicing factor 61K.

In order to determine the mutation spectrum of *PRPF31* in adRP we and others have screened the coding exons and their flanking splice sites in families linked to this locus and

in large patient cohorts [2]. Over 30 different mutations have been reported that include missense, deletion, insertion and splice site alterations. It has been speculated that haploinsufficiency may be the cause of disease [2] but to date there has been no evidence to prove that this mechanism rather than aberrant function of mutated protein is responsible for disease. In this study we report the largest deletion identified in the *PRPF31* gene thus providing evidence that haploinsufficiency is the cause of disease in adRP patients with mutations in the *PRPF31* gene.

METHODS

Patients: We previously mapped the adRP locus on chromosome 19q13.4 and identified several adRP families linked to this locus [3,4]. After subsequent cloning of the *PRPF31* gene mutations were identified in all but one family referred to as ADRP2. Patients from this family were the subjects of this study. The study protocol was approved by the hospital ethics committee and was in accordance with the tenets of the Declaration of Helsinki (June 1964); informed consent was obtained from all members after explanation of the nature and possible consequences of the study. Although DNA of more than 17 members (disease status known) of this three-generation British family is available, only seven members were available for ophthalmic reexamination. The youngest patient examined was 11 years of age and the oldest 47. A detailed history was taken, focussing on the typical signs of RP and their

Correspondence to: Shomi S. Bhattacharya, Department of Molecular Genetics, Institute of Ophthalmology, University College London, 11-43 Bath Street, London, EC1V 9EL, UK; Phone: 44-207-608-6826; FAX: 44-207-608-6863; email: smbcssb@ucl.ac.uk

onset. All patients had electrophysiological testing performed with gold foil recording electrodes and Ganzfeld stimulation according to the ISCEV Standard responses, including the higher intensity flash “suggested” in the recent version of the ISCEV Standard for ERG [5].

Mutation analysis and genotyping: The 14 exons of *PRPF31* were screened for mutations by systematic sequencing of PCR products as described previously [2].

To assess the possibility of a large intragenic deletion, nine *PRPF31* intragenic single nucleotide polymorphisms (SNPs) were typed in ADRP2 (420+81T >C, 420+82G >C, 528-31C >T, 564G >A, 735C >T, 855+40G >A, 946-70T >C, 1148-9T >C, and 1468C >T). In addition several SNPs and microsatellite markers flanking *PRPF31* were also analyzed in the family. The location of the analyzed markers, sequence of each set of primers and conditions are described in Table 1. PCR products harboring SNPs were analyzed by direct sequencing using an ABI 3100 (Applied Biosystems, Foster city, CA) while PCR products of microsatellite markers were separated by non-denaturing PAGE (Protogel; National Diagnostics USA, Atlanta, GA) and visualized under UV illumination after being stained with ethidium bromide.

RESULTS

Patient clinical data: All examined members of this three-generation British family were affected thus displaying a high

degree of disease penetrance. Four out of the seven members examined are shown in the pedigree (III.3, III.9, IV.1, and IV.2 in Figure 1A); younger affected members for whom genotype data are not available are not shown. The onset of night blindness was reported between the age of 3 and 16 years. Visual field loss was first noticed between the age of 6 and 30 years. Photoaversion and visual loss if present-was noticed in most cases about 15 years after the onset of visual field loss. By the age of 40 most patients had severely reduced visual fields with a central island of 2-5°. However, visual acuity (VA) was relatively well preserved (6/9-6/18) with one exception (III.9) whose VA was counting fingers. The more advanced cases all had a small posterior subcapsular opacity or had been operated for cataract.

Fundus examination revealed advanced disease with heavy bone spicule pigmentation and severe atrophy by the age of 30 to 40 years. The youngest patient examined, despite being asymptomatic at that stage showed at age 11 some mild atrophy in the midperiphery associated with some inferior bone spicule pigmentation. The most severely affected patient (III.9) had severe maculopathy with a bull’s eye appearance in addition to the peripheral retinopathy.

The majority of patients had undetectable full-field ERGs under all standard stimulus and recording conditions. Only one patient, aged 19 years showed some residual ERG activity but was severely abnormal.

TABLE 1. MARKERS AND PRIMERS USED FOR DELETION ANALYSIS

Marker/SNPs	Location of marker/SNP	Sense primer (5'-3')	Antisense primer (5'-3')	Tm
JST060265 JST060264	Proximal to OSCAR	TGGGGTAGAAAGAGTATG	TCTATTTTCTCAAAGACGG	56
JST114222	5' UTR of OSCAR	GAAAGGGGTGACTCACAGAG	TTCCACAGTGCCATAGGGCT	60
(GATA) _n	about 1.5 kb 5' of NDUFA3 start ATG	TTTGCACCTATTATGTGCCA	TCACAGCAAGGGCTGGCAC	58
420+81T>C 420+82G>C	PRPF31 IVS5	GAGTCTCCTTCCATCTCACC	CAGAGCAGACCACTGAGCC	59
528-31C>T 564G>A	PRPF31 IVS6	GGAGATCCAGGAGGCTGG	GGTCACAGTGTGAGCAGACC	61
735C>T 855+40G>A	PRPF31 exon8 PRPF31 IVS8	CTCTCTGCTTTCTTCTGACC	TGAGTGCTACCGTCAGCT	60
946-70T>C	PRPF31 IVS9	TAAGGCACGTGGATACTCG	CATCTTGCGGTACCTGGG	61
1148-9T>C	PRPF31 IVS11	CTGGTCGCTGAACTGCAG	CCTTGCCAAGGTCTCAGG	64
1468C>T	PRPF31 exon 14	CTCACCTAACCCATCATCC	GCTCTGATTCTTCTAGTTGCC	55
(TGTT) _n	about 1.4 kb 3' of PRPF31 STOP	GGATGATCCTGGCTCATG	GAGAATCACTTCAACCTGG	57
(CA) _n	0.5 kb 5' of CNOT3 start ATG	CCCCCAATCTTTCTTCTCTCT	AGCTGATGACTGGGATGGAG	59

Markers, listed in descending order from centromere, and primers used for deletion analysis. Sequence information is based on NCBI Homo sapiens chromosome 19 genomic sequence NT_011109. The nucleotide positions of single nucleotide polymorphism (SNPs) within PRPF31 gene are based on the start codon in the PRPF31 gene (NM_015629).

All the affected members of this family that were examined therefore showed the typical features of retinitis pigmentosa. The ocular phenotype was severe. General history revealed some chronic asthma or chronic bronchitis in two of the patients (IV.2 and younger sister). One patient (IV.1) had some facial dysmorphism with telecanthus. However, this was not seen in other patients and there was no clear evidence

of any obvious systemic association linked with the gene defect.

Mutation analysis: Initial screening of *PRPF31* in the ADRP2 family did not reveal any obvious mutation. However, close scrutiny of the data revealed that all affected individuals are “homozygous” for several SNPs within *PRPF31*. Moreover, the homozygous alleles differed among the affected

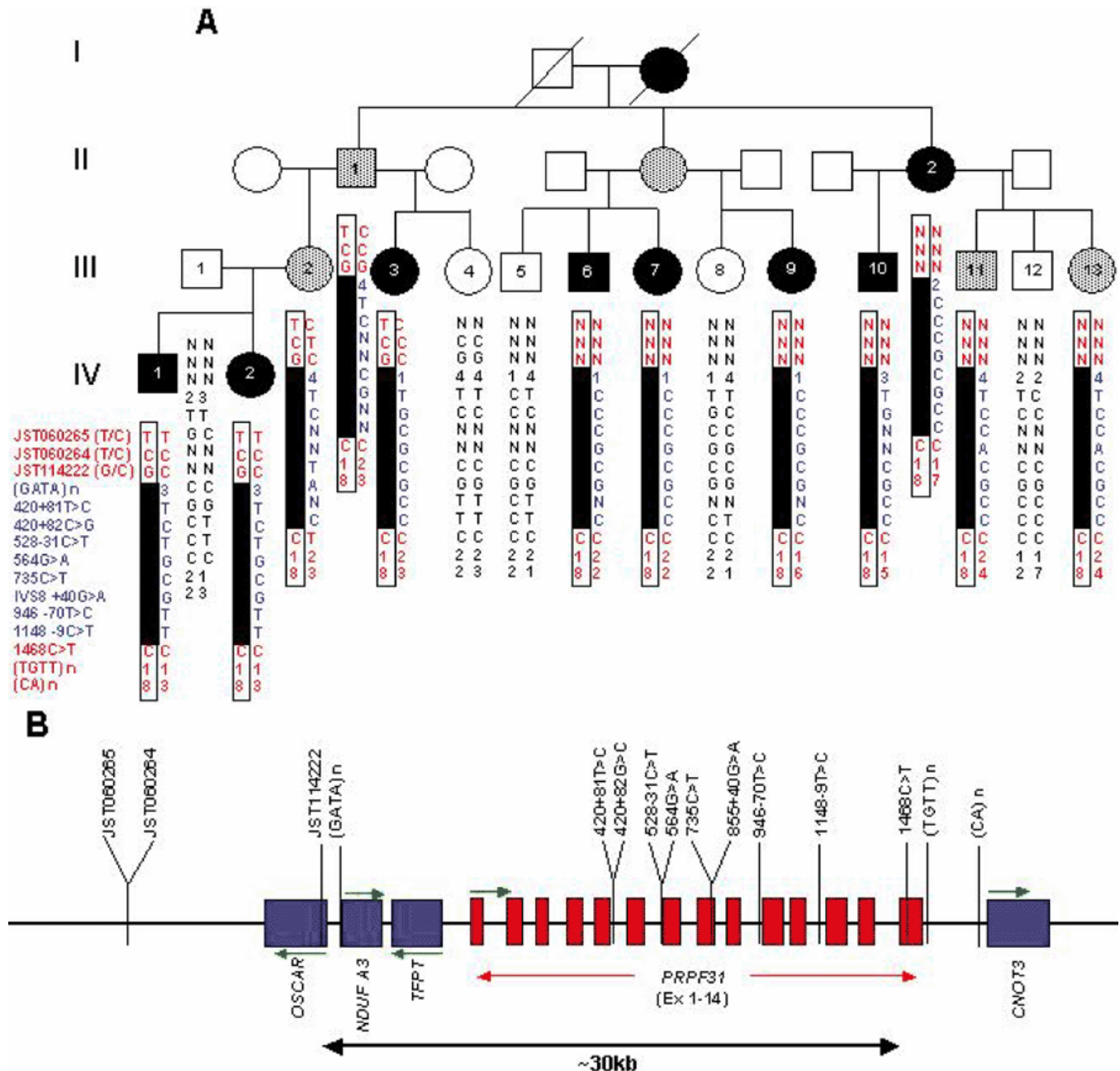


Figure 1. The ADRP2 pedigree with a deletion in *PRPF31*. Subjects were genotyped for 15 markers within and surrounding the *PRPF31* gene and haplotypes assembled. **A:** Filled symbols denote affecteds, open symbols unaffecteds and grey symbols asymptomatic disease haplotype carriers. The extent of the deletion is indicated as a solid bar within the boxed affected haplotype. N denotes untyped markers or where markers failed to amplify. **B:** The schematic diagram showing the location of markers and the genes involved in the deletion. Distances between markers are not drawn to scale. For clarity genomic organization of only *PRPF31* is shown to indicate positions of single nucleotide polymorphisms. The transcriptional direction for each gene is shown by a horizontal arrow.

subjects suggesting that affected individuals were in fact monoallelic at these loci. An intragenic deletion was suspected for this apparent "homozygosity" rather than non-paternity as several microsatellite markers within the 19q13.4 region showed perfect segregation within the family [4]. In order to estimate the size of the deletion, SNPs and microsatellite markers spanning and flanking *PRPF31* were analyzed in the entire ADRP2 family. This showed that a GATA repeat marker located 1.5 kb upstream of the *NDUFA3* gene and majority of *PRPF31* intragenic SNP markers except the ones within exon 14 were monoallelic in all affected family members (Figure 1). Close analysis of the relevant genomic sequence suggested a deletion of approximately 30 kb that included the putative promoter region of a novel gene *OSCAR*, the entire genomic content of genes *NDUFA3*, *TFPT* and most of the *PRPF31* gene except for its terminal exon (exon 14).

DISCUSSION

The deletion of several genes adjacent to *PRPF31* in this family raised the possibility of a contiguous gene syndrome; however examination of the family members showed no obvious indication for any other disorder besides RP.

NDUFA3 is a subunit of the NADH: ubiquinone oxidoreductase (complex I), the first enzyme complex in the electron transport chain of mitochondria [6]. Complex 1 is a multimeric assembly of 7 mitochondrial-encoded subunits (ND subunits) and at least 36 nuclear-encoded subunits. Mutations in several nuclear genes that encode subunits of complex I have been associated with isolated complex I deficiency with an autosomal recessive pattern of inheritance. The clinical symptoms of complex I deficiency range from lethal neonatal forms to neurodegenerative disorders in adult life, including Leber hereditary optic neuropathy (LHON) and Parkinson disease. The fact that members of ADRP2 family do not show symptoms of complex I deficiency may be attributed to the fact that one copy of *NDUFA3* gene is sufficient for electron transport within complex 1. The second gene involved in the deletion, *TFPT* has a promoter responsive to hematopoietic transcriptional factors important for the early stages of B cell differentiation and is involved in leukemia [7,8]. Therefore *TFPT* may have a role in the development and/or progression of leukemogenesis. Only the promoter is deleted in the third gene involved in the deletion, *OSCAR*, which nevertheless is likely to affect the expression of this gene. The osteoclast-associated receptor (*OSCAR*) plays a critical role in osteoclast differentiation and is important for the maintenance of bone homeostasis [9]. A recent study identified a promoter variant in *OSCAR* that might be one of the genetic determinants of Bone Mass Density (BMD) in post-menopausal women [10]. BMD is the major factor for determining bone strength and osteoporotic fracture risk and is determined by both environmental and multiple genetic factors. It is possible that females of ADRP2 with the deletion could be prone to osteoporotic fractures with age. This however was not evident as the oldest female examined in the family was 47 years of age. The lack of an apparent extra ocular phenotype in the ADRP2 family suggests that one functional copy of *NDUFA3*,

TFPT and *OSCAR* is sufficient for normality. Although, a subtle extra ocular phenotype may have been missed that could be revealed in a more thorough clinical assessment.

The precise mechanism behind the potential deletion could not be determined. Attempts made at amplifying across the deletion were hindered by mis-priming of primers. However, it is noteworthy that the *PRPF31* gene has a high density of *Alu* repeats. The presence of SINE/*Alu* repeats at both 5' and 3' ends of the deleted region suggests that an *Alu*-mediated homologous recombination is responsible for this deletion. In humans *Alu* sequences have repeatedly been found to be associated with genomic deletions, such as those identified in *FAA* and *BRCA1* genes that cause Fanconi Anemia and breast/ovarian cancer, respectively [11-14].

In conclusion we have provided strong evidence for the presence of a large deletion mutation in *PRPF31* that effectively results in the loss of one copy of the gene, and provide further evidence that haploinsufficiency rather than aberrant function of mutated proteins may be the cause of disease in adRP patients with mutations in the *PRPF31* gene.

ACKNOWLEDGEMENTS

The authors wish to thank all of the participants in this study. This work was supported in part by MRC grants G0000011 and G9301094, The Foundation Fighting Blindness, USA, The British Retinitis Pigmentosa Society, Fight For Sight and the Special Trusties of Moorfields Eye Hospital.

REFERENCES

1. Heckenlively JR, Daiger SP. Hereditary retinal and choroidal degenerations. In: Rimoin DL, Connor JM, Pyeritz RE, editors. Emery and Rimoin's principles and practice of medical genetics. Vol 1. 4th ed. New York: Churchill Livingstone; 2002. p. 2255-576.
2. Vithana EN, Abu-Safieh L, Allen MJ, Carey A, Papaioannou M, Chakarova C, Al-Magtheth M, Ebenezer ND, Willis C, Moore AT, Bird AC, Hunt DM, Bhattacharya SS. A human homolog of yeast pre-mRNA splicing gene, PRP31, underlies autosomal dominant retinitis pigmentosa on chromosome 19q13.4 (RP11). *Mol Cell* 2001; 8:375-81.
3. al-Magtheth M, Inglehearn CF, Keen TJ, Evans K, Moore AT, Jay M, Bird AC, Bhattacharya SS. Identification of a sixth locus for autosomal dominant retinitis pigmentosa on chromosome 19. *Hum Mol Genet* 1994; 3:351-4.
4. Al-Magtheth M, Vithana E, Tarttelin E, Jay M, Evans K, Moore T, Bhattacharya S, Inglehearn CF. Evidence for a major retinitis pigmentosa locus on 19q13.4 (RP11) and association with a unique bimodal expressivity phenotype. *Am J Hum Genet* 1996; 59:864-71.
5. Marmor MF, Holder GE, Seeliger MW, Yamamoto S, International Society for Clinical Electrophysiology of Vision. Standard for clinical electroretinography (2004 update). *Doc Ophthalmol* 2004; 108:107-14.
6. Loeffen JL, Triepels RH, van den Heuvel LP, Schuelke M, Buskens CA, Smeets RJ, Trijbels JM, Smeitink JA. cDNA of eight nuclear encoded subunits of NADH:ubiquinone oxidoreductase: human complex I cDNA characterization completed. *Biochem Biophys Res Commun* 1998; 253:415-22.
7. Brambillasca F, Mosna G, Colombo M, Rivolta A, Caslini C, Minuzzo M, Giudici G, Mizzi L, Biondi A, Privitera E. Identifi-

- cation of a novel molecular partner of the E2A gene in childhood leukemia. *Leukemia* 1999; 13:369-75.
8. Brambillasca F, Mosna G, Ballabio E, Biondi A, Boulukos KE, Privitera E. Promoter analysis of TFPT (FB1), a molecular partner of TCF3 (E2A) in childhood acute lymphoblastic leukemia. *Biochem Biophys Res Commun* 2001; 288:1250-7.
 9. Ishikawa S, Arase N, Suenaga T, Saita Y, Noda M, Kuriyama T, Arase H, Saito T. Involvement of FeRgamma in signal transduction of osteoclast-associated receptor (OSCAR). *Int Immunol* 2004; 16:1019-25.
 10. Kim GS, Koh JM, Chang JS, Park BL, Kim LH, Park EK, Kim SY, Shin HD. Association of the OSCAR promoter polymorphism with BMD in postmenopausal women. *J Bone Miner Res* 2005; 20:1342-8.
 11. Petrij-Bosch A, Peelen T, van Vliet M, van Eijk R, Olmer R, Drusedau M, Hogervorst FB, Hageman S, Arts PJ, Ligtenberg MJ, Meijers-Heijboer H, Klijn JG, Vasen HF, Cornelisse CJ, van't Veer LJ, Bakker E, van Ommen GJ, Devilee P. BRCA1 genomic deletions are major founder mutations in Dutch breast cancer patients. *Nat Genet* 1997; 17:341-5. Erratum in: *Nat Genet* 1997; 17:503.
 12. Puget N, Sinilnikova OM, Stoppa-Lyonnet D, Audoynaude C, Pages S, Lynch HT, Goldgar D, Lenoir GM, Mazoyer S. An Alu-mediated 6-kb duplication in the BRCA1 gene: a new founder mutation? *Am J Hum Genet* 1999; 64:300-2.
 13. Montagna M, Santacatterina M, Torri A, Menin C, Zullato D, Chieco-Bianchi L, D'Andrea E. Identification of a 3 kb Alu-mediated BRCA1 gene rearrangement in two breast/ovarian cancer families. *Oncogene* 1999; 18:4160-5.
 14. Levran O, Doggett NA, Auerbach AD. Identification of Alu-mediated deletions in the Fanconi anemia gene FAA. *Hum Mutat* 1998; 12:145-52.