



Exopolysaccharide-peptide complex from oyster mushroom (*Pleurotus ostreatus*) protects against hepatotoxicity in rats

Nihad M. Abdel-Monem^a, Mohammad A. El-Saadani^a, Ayman S. Daba^b, Samar R. Saleh^a, Eiman Aleem^{c,*}

^a Department of Biochemistry, Faculty of Science, Alexandria University, Alexandria, Egypt

^b RUSH University Medical Center, Chicago, USA

^c Division of Human Sciences, Cancer Biology and Therapy Laboratory, School of Applied Sciences, London South Bank University, London, United Kingdom

ARTICLE INFO

Keywords:

Pleurotus ostreatus
Liver
Antioxidants
Diethylnitrosamine

ABSTRACT

Liver damage involves oxidative stress and a progression from chronic hepatitis to hepatocellular carcinoma (HCC). The increased incidence of liver disease in Egypt and other countries in the last decade, coupled with poor prognosis, justify the critical need to introduce alternative chemopreventive agents that may protect against liver damage. The aim of this study was to evaluate the efficacy of exopolysaccharide-peptide (PSP) complex extracted from *Pleurotus ostreatus* as a hepatoprotective agent against diethylnitrosamine (DEN)/carbon tetrachloride (CCl₄)-induced hepatocellular damage in rats. The levels of liver injury markers (ALT, AST and ALP) were substantially increased following DEN/CCl₄ treatment. DEN/CCl₄ - induced oxidative stress was confirmed by elevated levels of lipid peroxidation and decreased levels of superoxide dismutase, glutathione-S-transferase, and reduced glutathione. PSP reversed these alterations in the liver and serum, and provided protection evidenced by reversal of histopathological changes in the liver. The present study demonstrated that PSP extract from *P. ostreatus* exhibited hepatoprotective and antioxidant effects against DEN/CCl₄-induced hepatocellular damage in rats. Given the high prevalence of HCV-related liver damage in Egypt, our results suggest further clinical evaluation of *P. ostreatus* extracts and their potential hepatoprotective effects in patients with liver disease.

1. Introduction

Medicinal mushrooms have been shown to stimulate immune function, contribute to glucose homeostasis and to modulate detoxification, as well as exert anti-inflammatory, and anticancer activities (reviewed in Ref. [1]). They are rich sources of antioxidants such as thiamine (vitamin B1), riboflavin (vitamin B2), nicotinic acid (vitamin B3), biotin and ascorbic acid (vitamin C) [2], as well as carotenoids, polyphenolic compounds and flavonoids, which prevent free radical damage and reduce the risk of chronic diseases [3]. The genus *Pleurotus* comprises about 40 species, that are commonly referred to as “oyster mushrooms”. *Pleurotus ostreatus* extracts have been shown to exhibit hypolipidemic [3, 4], immunostimulant, antiproliferative and antitumor activities [5,6], as well as anti-inflammatory, antioxidant [7–9], and antifungal activities [10].

Extracts from *P. ostreatus*, such as polysaccharide-peptide complex (PSP), possess hepatoprotective properties against liver damage caused by toxic chemicals. Aqueous extracts contain high concentrations of

cysteine, methionine and aspartic acid. They improve the antioxidant status and were shown to revert hepatic damage [7,9]. Treatment of rats with polysaccharides from the *P. ostreatus* mycelium are reported to protect against carbon tetrachloride (CCl₄)-induced hepatic damage [11].

Liver damage involves oxidative stress and generally a progression from steatosis to chronic hepatitis, fibrosis, cirrhosis and hepatocellular carcinoma (HCC) [12]. Egypt has one of the highest global burdens of hepatitis C virus (HCV) infection, with an estimated 10% in people between 15 and 59 years of age, and thousands die every year of the consequences of HCV, such as liver cirrhosis and HCC [13].

The antioxidant enzymes catalase (CAT), superoxide dismutase (SOD) and glutathione peroxidase (Gpx) act in concert to protect cellular components from damage by free radicals [14,15]. The reduction of their activity is associated with the accumulation of oxidants, leading to loss of integrity and function of cell membranes, contributing to cell injury. GSH is an important non-enzymatic antioxidant which promotes the detoxification of several toxic metabolites. The depletion of GSH

* Corresponding author. 103 Borough Rd, London, SE1 0AA, United Kingdom.
E-mail address: aleeme2@lsbu.ac.uk (E. Aleem).

promotes generation of reactive oxygen species (ROS) and oxidative stress with a cascade of effects thereby affecting functional as well as structural integrity of cell and organelle membranes [16]. The GSTs are a multigene family of isozymes that catalyse the conjugation of GSH to a variety of electrophilic compounds, and thereby exert a critical role in cellular protection against ROS [17].

Liver injury results in an increase in serum concentrations of alanine aminotransferase (ALT) and aspartate aminotransferase (AST). Both aminotransferases are highly concentrated in the liver. Alkaline phosphatase (ALP), another indicator of liver damage, is mainly derived from the liver and bones in healthy adults [18]. An increase in serum ALP levels is frequently associated with a variety of diseases, such as extrahepatic bile obstruction, intrahepatic cholestasis, infiltrative liver disease and hepatitis [19].

The increased incidence of liver disease in Egypt in the last decade, coupled with the poor prognosis, justify the critical need to introduce alternative chemopreventive agents that may protect against liver damage. We have previously shown that β -glucans extracted in our labs from the inedible mushroom *Schizophyllum commune* reduced the incidence of HCC in dimethyl-benz [a]anthracene (DMBA)-treated mice and this effect was coupled with an increase in apoptosis [20]. Using a similar approach, the aims of the present study were (1) to extract crude polysaccharo peptide complex (PSP) from *P. ostreatus*, and (2) to study its potential hepatoprotective and antioxidant effects in an experimental model of DEN/CCL₄-induced hepatotoxicity in rats.

2. Materials and methods

2.1. Preparation of the mushroom extract by fermentation

Pure mycelia of *Pleurotus ostreatus* were obtained from the Agricultural Research Center (Giza, Egypt). The culture was maintained on potato-dextrose agar (PDA) and sub-cultured every month. The mushroom extract was prepared according to [21] (supplementary data). Total protein and total sugar contents were determined by Lowry method [22] using BSA as standard and by phenol sulfuric acid method [23] using glucose as standard, respectively.

2.2. Spectroscopy and nuclear magnetic resonance

Ultraviolet and infrared absorptions were determined as described in [20]. The ¹H and ¹³C nuclear magnetic resonance (NMR) spectroscopy was performed according to the method described by [24]. NMR spectra were obtained using a 500 MHz JEOL spectrometer (Japan).

2.3. Animals

Male albino Wistar rats were purchased from the National Research Center for biological products (Cairo, Egypt). Animal care and the experimental protocols were in accordance with the guidelines of the National Institutes of Health guide for the care and use of Laboratory animals (NIH Publications No. 8023, revised 1978). Five animals were housed per cage and kept on standard diet (mouse chow) and water *ad libitum*, 22 °C room temperature (RT), 50 ± 10% humidity and 12-h light/dark cycle. The food was withdrawn 18–24 h before the experiment.

2.4. Induction of hepatotoxicity and experimental animal groups

Forty-Eight male albino Wistar rats weighing 100–150 g were randomly divided into six groups of eight rats each (Fig. 1). Group I received only saline solution intraperitoneal (i.p). Groups II, III and IV each received one dose of 200 mg/kg body weight of DEN. After 2 weeks of DEN administration, hepatotoxicity was promoted through subcutaneous (Sc) injections of CCL₄ (3 ml/kg/week) for 6 weeks [25]. Group II served as positive (toxin) control. In order to study whether early administration of PSP would have a protective effect against DEN/CCL₄ hepatotoxicity, Group III received PSP extract at a dose of 30 mg/kg body weight, 3 times/week, i.p for 2 weeks before DEN administration and for the remaining 12 weeks of the experiment. The PSP dose was selected based on a preliminary acute toxicity test (Table S1). **Group IV** received 30 mg/kg body weight of PSP, 3 times/week, i.p for the last 4 weeks of the experiment after DEN/CCL₄ treatment. **Group V**: Served as a control group for group III and received the same PSP dose for 14 weeks. **Group VI**: Served as a control group for group IV and received the same PSP dose for the last 4 weeks of the experiment.

2.5. Cell culture and cell viability

HepG2 cell line (DSMZ, Braunschweig, Germany) was cultured in RPMI 1640 (Gibco, Paisley, UK) with 10% fetal bovine serum, penicillin (100 units/ml), streptomycin (50 µg/ml) (Hyclone, Logan, UT) at 37 °C in a humidified atmosphere containing 5% CO₂ and confirmed authentic using Short Tandem Repeat kit AmpFSTR identifier (Applied Biosystems, Foster City, CA). HepG2 cells were plated in 96-well plates at 10⁴ cells/well and treated after 24 h with serial dilutions of the crude partially soluble PSP in DMSO. Cell viability was assessed after 48 h PSP exposure using Sulforhodamine B (SRB) stain.

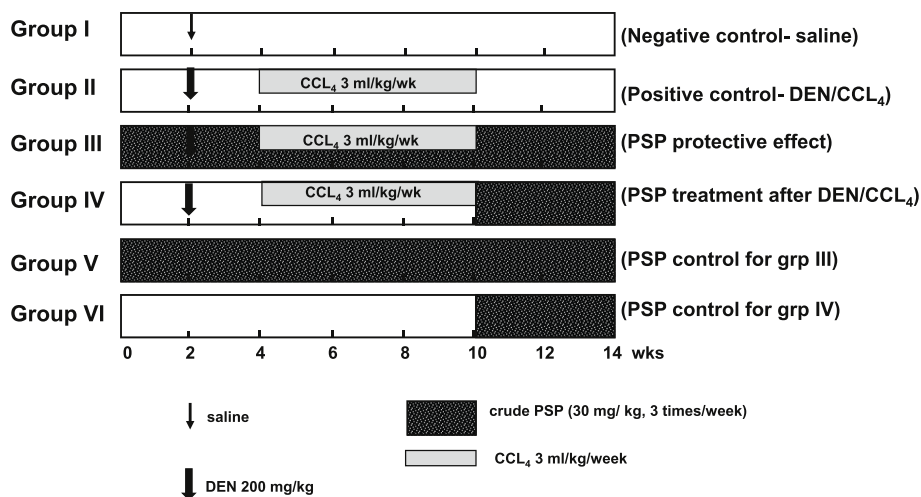


Fig. 1. Experimental groups: Group 1 was treated with saline, group II with DEN/CCL₄ at the doses shown, group III received PSP at the dose shown for 14 weeks, group IV received the same dose of PSP for 4 weeks after administration of DEN/CCL₄. Groups V and VI served as PSP controls for groups III and IV, respectively.

2.6. Tissue sampling and biochemical assays

Animals were subjected to mild ether anesthesia following overnight fast, blood was collected from the abdominal aorta and the serum was separated by centrifugation and stored at $-80\text{ }^{\circ}\text{C}$ for evaluation of the following parameters using commercially available kits (Biosystem S.A., Spain): ALT, AST and ALP. Whole blood was collected in EDTA-coated tubes and used for the determination of WBCs, RBCs and Hb. Cells were analyzed using a flow cytometry-based Advia 2120 Hematology system. The liver was washed twice with ice-cold saline. A portion of the liver was homogenized (10%, w/v) in ice-cold sodium potassium phosphate buffer (0.01 M, pH 7.4) containing 1.15% KCl. The homogenate was centrifuged at $10,000\times g$ for 20 min at $4\text{ }^{\circ}\text{C}$, and the supernatant was used for the determination of: LPO [26]; SOD [27]; GSH [28]; and GST activity [29].

2.7. Histopathology

Liver sections were cut immediately, fixed in 10% neutral buffered formalin, processed, and embedded in paraffin. Sections (4–5 μm) were prepared and mounted on glass slides and stained with hematoxylin and eosin (H&E) for histopathological evaluation.

2.8. Statistical analyses

Data were expressed as mean \pm SD for 8 rats per group. Comparison between the means of various treatment groups was analyzed using least significant difference (LSD) test. A value of $p < 0.05$ was considered significant. Statistical analysis was performed using the SPSS statistical package version 16.00 (SPSS Inc, Chicago, Illinois, USA).

3. Results

3.1. Extraction and structural analysis of the exopolysaccharide-peptide (PSP) complex from *Pleurotus ostreatus*

Ethanol precipitation of PSP and its elemental analysis, as well as results from IR and ^{13}C NMR are shown in the supplementary data (Figs. S1–7). The partially soluble PSP had a total carbohydrate content of 88.85% and 5.3% of soluble protein.

3.2. PSP extract is cytotoxic to HepG2 liver cancer cell line

The viability of the human liver cancer cell line (HepG2) was measured after the addition of increasing concentrations of PSP (0, 1, 2.5, 5 and 10 $\mu\text{g/ml}$ DMSO) for 48 h (Fig. 2). The IC_{50} was inferred from the graph to be 0.5 $\mu\text{g/ml}$.

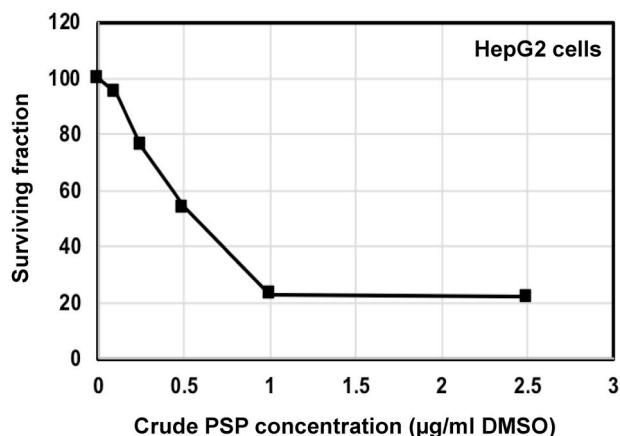


Fig. 2. Cytotoxicity of PSP extract from *P. ostreatus* in HepG2 cell line.

3.3. Effect of PSP extract on serum biomarkers of liver damage

Administration of DEN/CCL₄ induced liver damage but no liver tumors were observed. Hepatotoxicity was confirmed by histopathology. Treatment with DEN/CCL₄ induced a significant 6-fold increase in serum ALT levels compared to control indicating liver damage (Group II). Administration of PSP to groups III and IV significantly reduced serum ALT levels almost back to normal. A similar pattern of results was obtained for other serum biomarkers; a significant 2- and 1.5-fold increase in AST and ALP levels, respectively, was observed in group II animals, compared to all other experimental groups. This effect was reversed upon treatment with PSP extract (Group III, IV). There was no significant difference in ALT, AST or ALP levels between groups III, IV, V and VI compared to negative control (Group I) or between groups III and V, or IV and VI, respectively (Table 1).

3.4. Effect of PSP extract on oxidative stress biomarkers

Treatment of rats with DEN/CCL₄ resulted in a 1.4-fold significant increase in the level of hepatic lipid peroxidation (LPO) compared to group I. Administration of PSP to groups III and IV resulted in a significant decrease in hepatic LPO levels by 1.6- and 1.5-fold, respectively, compared to group II rats.

A highly significant decrease in hepatic LPO was shown in group V that received only PSP for the 14 weeks of the experiment (control group for group III) compared to groups I, II and III. However, the level of hepatic LPO did not show any significant difference in rats receiving PSP only for 4 weeks (Group VI) when compared to either group IV or to group I rats (Table 2).

Administration of DEN/CCL₄ (Group II) resulted in a significant decrease in both serum and hepatic SOD, as well as in hepatic GST activity compared to their corresponding values in the negative control group I rats. Administration of PSP reversed this effect in groups III and IV (Table 3).

The activity of both serum SOD and hepatic GST in groups III and IV, which received PSP either before or after the hepatotoxins, did not show any significant change compared to the corresponding values in group I rats. Serum SOD in group V rats that served as control for group III and received PSP for 14 weeks, showed highly significant increase compared to rats of both group I and group III (Table 3).

DEN/CCL₄ treated group (Group II) showed a significant 2.7-fold decrease in the level of hepatic GSH compared to the hepatic GSH in the control group I. Administration of PSP in groups III and IV reversed this effect resulting in hepatic GSH concentrations approaching that in the control group I (Table 3).

3.5. PSP extract increases WBCs, RBCs and haemoglobin concentration in rats treated with DEN/CCL₄

DEN/CCL₄ caused a significant decrease in WBCs and RBCs count as well as in the hemoglobin (Hb) levels in group II rats compared to all other groups (Table 4). Treatment with PSP significantly alleviated this hematotoxicity, bringing RBCs count and Hb levels to levels approximating those of control group I rats.

3.6. Histopathology

Liver sections from control rats (Group I) showed normal arrangement of hepatocytes (Fig. 3A). Rats treated with DEN/CCL₄ (Group II) showed mild portal mononuclear inflammatory infiltrate, fibrosis, lytic necrosis, frequent apoptotic bodies and distended portal veins. Steatosis manifest by marked accumulation of lipids (Fig. 3B), as well as dysplastic hepatocytes with karyomegaly and prominent macronucleoli (Fig. 3C) were also evident. Group III rats showed more or less normal liver architecture (Fig. 3D), however, rats post-treated with PSP (Group IV), showed minimal portal inflammatory infiltrate (Fig. 3E). Groups V

Table 1
PSP extract reverses the hepatotoxic effect of DEN/CCL₄ on ALT, AST and ALP levels.

Experimental Groups	Group I	Group II	Group III	Group IV	Group V	Group VI
ALT (U/L) (mean ± SD)	39.57 ± 2.60	243.20 ± 84.73	45.83 ± 2.63	34.90 ± 4.68	36.15 ± 3.80	30.09 ± 3.74
F (p)	35.254* (<0.001)					
P ₁		<0.001*	0.757	0.818	0.866	0.640
P ₂			<0.001*	<0.001*	<0.001*	<0.001*
P ₃					0.633	
P ₄						0.812
AST (U/L) (mean ± SD)	158.67 ± 18.75	338.67 ± 103.56	190.17 ± 21.85	139.00 ± 19.96	177.17 ± 29.46	145.50 ± 11.24
F (p)	15.469* (<0.001)					
P ₁		<0.001*	0.249	0.469	0.496	0.627
P ₂			<0.001*	<0.001*	<0.001*	<0.001*
P ₃					0.631	
P ₄						0.810
ALP (U/L) (mean ± SD)	168.33 ± 48.14	268.83 ± 26.41	186.17 ± 62.37	198.00 ± 20.79	192.50 ± 19.09	179.83 ± 57.65
F (p)	4.174* (0.005)					
P ₁		<0.001*	0.477	0.240	0.337	0.646
P ₂			0.002*	0.008*	0.004*	0.001*
P ₃					0.800	
P ₄						0.469

F: F test (ANOVA), p₁: p value of LSD test between negative control and other groups, p₂: p value of LSD test between group II and group III, IV, V and VI, p₃: p value of LSD test between group III and group V, p₄: p value of LSD test between group IV and group VI, *: Statistically significant at $p \leq 0.05$.

Table 2
PSP extract reduces hepatic lipid peroxidation in rats treated with DEN/CCL₄.

Experimental Groups	Group I	Group II	Group III	Group IV	Group V	Group VI
LPO (nmol/g liver) (mean ± SD)	153.02 ± 27.58	217.03 ± 18.81	134.28 ± 20.72	147.19 ± 18.04	105.39 ± 20.38	144.43 ± 8.25
F (p)	20.746* (<0.001)					
P ₁		<0.001*	<0.112	0.614	<0.001*	<0.458
P ₂			<0.001*	<0.001*	<0.001*	<0.001*
P ₃					0.002*	
P ₄						0.268

F: F test (ANOVA), p₁: p value of LSD test between negative control and other groups, p₂: p value of LSD test between group II and group III, IV, V and VI, p₃: p value of LSD test between group III and group V, p₄: p value of LSD test between group IV and group VI, *: Statistically significant at $p \leq 0.05$.

and VI treated only with PSP showed minimal changes (Fig. 3F and G).

4. Discussion

Despite significant advances in surgical treatments and locoregional therapies, prognosis is still poor for patients with liver disease, and for those with recurrent hepatocellular carcinoma (HCC). Therefore, chemoprevention, and lifestyle changes are important as a supportive approach for the protection from liver disease. Most cases of HCC in humans develop in the setting of chronic liver disease, characterized by inflammation, cirrhosis, fibrosis and steatosis [30]. In the present study we used the DEN/CCL₄-model to mimic liver damage. This disease model can be used for studying fibrogenesis and HCC [31]. The goal of this study was to characterize the *in vivo* putative hepatoprotective and antioxidant effects of *P. ostreatus* rather than its anticancer activity. The present study demonstrated that the exopolysaccharide peptide complex (PSP), isolated from *P. ostreatus* exhibited hepato-, haemato-protective, and antioxidant activities in DEN/CCL₄-treated rats.

Furthermore, PSP extract was cytotoxic in the human liver cancer cell line HepG2. These results are consistent with those of [32] in human colorectal and leukaemia cell lines, with [33] against gastric cancer *in vitro* and *in vivo*, and with [34] in HepG2, HCT 116 and HeLa cell lines. Additionally, previous reports demonstrated that extracts from *P. ostreatus* suppressed proliferation of breast cancer (MCF-7, MDA-MB-231) and colon cancer (HT-29, HCT-116) cells, without affecting proliferation of epithelial mammary MCF-10A and normal colon FHC cells [5]. In a similar study [35], showed that the normal liver

cell line WRL-68 was more resistant than the liver cancer cell lines (Huh7, HepG2, SMMC-7721 and Hep3B) to the cytotoxic effects of a polysaccharide-protein (PSP) complex isolated from *Pleurotus pulmonarius*. Protein extracts from *P. ostreatus* were found to induce apoptosis in SW480 cells through ROS production, GSH depletion and mitochondrial dysfunction [32].

DEN and CCL₄ generate reactive oxygen species (ROS), which cause cellular injury [15]. In the present study, DEN/CCL₄ increased serum ALT, AST and ALP levels concomitant with histopathological modifications in the liver reflecting the induction of acute hepatotoxicity and hepatic structural damage [25,36]. PSP reduced ALT, AST and ALP activities suggesting a potential reversal of liver injury, accompanied with an improved histomorphology of the liver. This is consistent with previous work by Refs. [7,36] on *P. ostreatus* extracts, by Ref. [37] on silymarin, and by Ref. [38] on silymarin and Anji white tea polyphenols.

Bioactivation of DEN and CCL₄ by cytochrome P450 system in the liver yields highly reactive free radicals that can react with proteins or lipids, or abstract a hydrogen atom from an unsaturated lipid, thus initiating lipid peroxidation [36,37]. Free radical scavenging enzymes such as SOD, CAT, GPx and GST are the first line of defence against oxidative injury. The inhibition of antioxidant system may cause the accumulation of H₂O₂ or products of its decomposition [17]. In the present study, the exposure to DEN/CCL₄ resulted in increased levels of hepatic lipid peroxides and depleted hepatic SOD, GST activity as well as reduced GSH concentration. PSP extract-treated animals showed a significant reduction in the levels of hepatic oxidation markers with concomitant amelioration in the hepatic antioxidant defence system,

Table 3

Effect of PSP extract on serum and hepatic superoxide dismutase (SOD), hepatic glutathione -S- transferase (GST) activities, and GSH concentration.

Experimental Groups	Group I	Group II	Group III	Group IV	Group V	Group VI
Serum SOD (mean ± SD)	7.72 ± 2.33	5.84 ± 0.83	6.62 ± 0.99	6.84 ± 0.98	10.23 ± 1.54	8.47 ± 1.09
F (p)	7.619* (<0.001)					
P ₁		0.026*	0.180	0.285	0.004*	0.357
P ₂			0.342	0.222	<0.001*	0.003*
P ₃					<0.001*	
P ₄						0.052
Hepatic SOD (mean ± SD)	1.16 ± 0.07	0.68 ± 0.05	0.81 ± 0.04	0.89 ± 0.13	0.93 ± 0.15	1.00 ± 0.16
F (p)	13.241* (<0.001)					
P ₁		<0.001*	<0.001*	<0.001*	0.001*	0.017*
P ₂			0.045*	0.003*	<0.001*	<0.001*
P ₃					0.077	
P ₄						0.089
Hepatic GST (mean ± SD)	2.76 ± 0.71	1.44 ± 0.30	2.34 ± 0.68	2.24 ± 0.42	2.86 ± 0.64	3.05 ± 0.36
F (p)	6.890* (<0.001)					
P ₁		<0.001*	0.183	0.107	0.757	0.372
P ₂			0.008*	0.016*	<0.001*	<0.001*
P ₃					0.104	
P ₄						0.016*
GSH (mg/g liver) (mean ± SD)	115.36 ± 51.18	43.01 ± 11.89	100.58 ± 22.26	83.38 ± 11.20	109.85 ± 40.46	89.55 ± 31.43
F (p)	4.077* (0.006)					
P ₁		<0.001*	0.425	0.090	0.765	0.168
P ₂			0.013*	0.035*	0.001*	0.016
P ₃					0.616	
P ₄						0.738

F: F test (ANOVA).

p₁: p value of LSD test between negative control and other groups.p₂: p value of LSD test between group II and group III, IV, V and VI.p₃: p value of LSD test between group III and group V.p₄: p value of LSD test between group IV and group VI.*: Statistically significant at $p \leq 0.05$.**Table 4**PSP extract increases white (WBCs), red (RBCs) cells' counts and hemoglobin (Hb) concentration in rats treated with DEN/CCl₄.

Experimental Groups	Group I	Group II	Group III	Group IV	Group V	Group VI
WBCs count (#*10 ³ /L) (mean ± SD)	11.40 ± 3.54	6.70 ± 1.14	16.65 ± 7.23	11.73 ± 2.63	16.24 ± 3.00	15.98 ± 3.17
F (p)	5.165* (0.003)					
P ₁		0.076	0.062	0.904	0.069	0.084
P ₂			0.001*	0.060	0.001*	0.001*
RBCs count (#*10 ⁶ /L) (mean ± SD)	7.78 ± 0.22	4.88 ± 0.95	7.45 ± 0.42	7.63 ± 0.59	7.51 ± 0.33	7.75 ± 0.55
F (p)	18.600* (<0.001)					
P ₁		<0.001*	0.424	0.696	0.485	0.932
P ₂			<0.001*	<0.001*	<0.001*	<0.001*
Hb (g/dl) (mean ± SD)	12.78 ± 1.44	7.92 ± 1.63	10.93 ± 0.63	11.32 ± 0.83	11.98 ± 0.81	12.25 ± 0.64
F (p)	12.151* (<0.001)					
P ₁		<0.001*	0.025*	0.058	0.286	0.501
P ₂			<0.001*	<0.001*	<0.001*	<0.001*

F: F test (ANOVA).

p₁: p value of LSD test between negative control and other groups.p₂: p value of LSD test between group II and group III, IV, V and VI.*: Statistically significant at $p \leq 0.05$.

which could be related to its ability to scavenge ROS, thus preventing further damage to membrane lipids. Among the antioxidant compounds in the oyster mushroom are polyphenols, which can act as hydrogen donors, to neutralize ROS and inhibit the formation of O₂- and OH-, the main inducers of lipid peroxidation [39]. Our results are in agreement with reports by Refs. [14] showing the antioxidant effects of a PSP complex extracted from *P. abalonus*-fruiting bodies on senescence-accelerated mice. Similar results were reported by Ref. [40] using Paraquat as liver damage inducer.

In the present study, the decrease in haematological parameters (WBCs, RBCs and Hb), in DEN/CCl₄-treated rats, is in agreement with [41]. The destruction of RBCs reflects the abnormality in hepatocellular

functions and potential changes in the membrane cholesterol and phospholipid ratio. One of potential mechanism of DEN/CCl₄-induced hemolysis is oxidative stress induction as reflected in this study by increased lipid peroxidation. This effect is similar to the effect of cadmium-induced haematological toxicity [42]. The administration of PSP caused an amelioration of the haematological parameters (WBCs; RBCs count & Hb level) probably through lowering lipid peroxidation levels in cell membranes; leading to decreased haemolysis of RBCs and/or due to the prevention of free radicals induced damage. Similar results were reported by Ref. [43]. The increase in WBCs counts in the present study may be due to an activation of immune response [44] as reported by Ref. [45] that polysaccharides from *P. ostreatus* induced

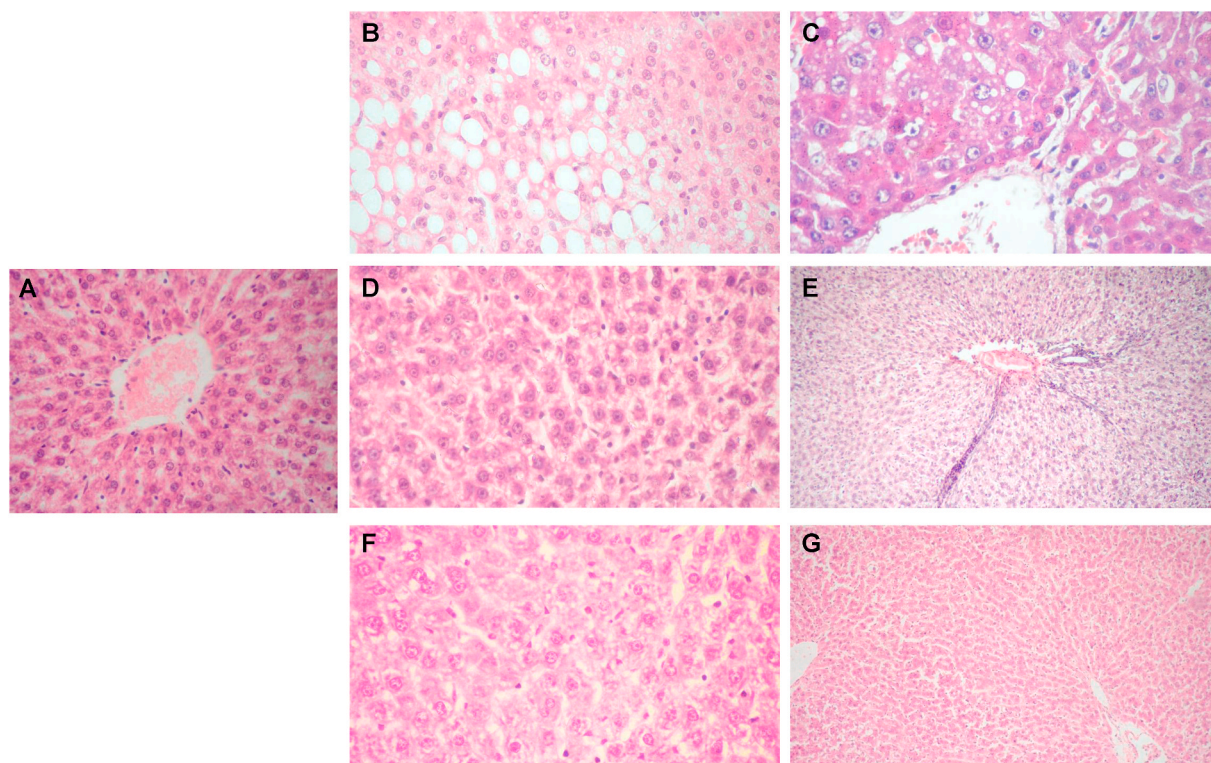


Fig. 3. H&E stained sections of liver from a negative control rat (Group I) showing intact normal hepatic architecture (X100) (A). DEN/CCL₄-treated rats (Group II) showed mild portal mononuclear inflammatory infiltrate and marked macrosteatotic changes of the hepatocytes (X400) (B), markedly dysplastic hepatocytes with karyomegaly and prominent macronucleoli (X400) (C). Group III rats demonstrated almost normal hepatic architecture (X400) (D), while group IV rats showed minimal portal inflammatory infiltrate (X100) (E). Administration of PSP for 14 weeks (Group V) (X400) (F), or for the last 4 weeks of the experiment (Group VI) showed almost normal morphology (X100) (G).

NK-cell mediated cytotoxicity against lung and breast cancer cells mediated by NKG2D and IFN γ upregulation.

The present study has some limitations in the fact that the active component in the polysaccharide-peptide complex (PSP) extract from *P. ostreatus* has not been identified. Extracts contain several compounds, and future research should focus on isolation and characterization of the active therapeutic compound in the PSP extract. Additionally, although our goal, in the present study, was to investigate the hepatoprotective effects of PSP against liver injury, it would have been relevant to investigate its antineoplastic effects on HCC, as well. Future preclinical studies should be directed towards studying the interaction of PSP with conventional chemo- and radiotherapy, as well as with targeted therapy in liver and other types of malignancies.

5. Conclusion

In conclusion, this study confirms that extracts from locally available oyster mushroom (*P. ostreatus*) have hepatoprotective, and antioxidant effects against liver damage induced in rats by DEN/CCL₄. Hence, it is recommended to invest in the commercial cultivation of oyster mushroom in Egypt for nutritional and medicinal purposes. Since Egypt is one of the countries with high prevalence of hepatitis C infection, our results suggest further clinical evaluation of *P. ostreatus* and its potential hepatoprotective effects in patients with liver disease.

Declaration of competing interest

The authors declare that they have no known competing financial interests or personal relationships that could have appeared to influence the work reported in this paper.

CRedit authorship contribution statement

Nihad M. Abdel-Monem: Conceptualization, Project administration, Supervision, Validation, Writing - review & editing. **Mohammad A. El-Saadani:** Conceptualization, Project administration, Supervision, Validation, Writing - review & editing. **Ayman S. Daba:** Conceptualization, Data curation, Formal analysis, Investigation, Methodology, Resources, Validation, Writing - review & editing. **Samar R. Saleh:** Data curation, Formal analysis, Investigation, Methodology, Resources, Writing - original draft, Roles/Writing - original draft, Writing - review & editing. **Eiman Aleem:** Conceptualization, Formal analysis, Investigation, Methodology, Project administration, Supervision, Validation, Writing - original draft, Roles/Writing - original draft, Writing - review & editing.

Appendix A. Supplementary data

Supplementary data to this article can be found online at <https://doi.org/10.1016/j.bbrep.2020.100852>.

References

- [1] E. Aleem, β -Glucans and their applications in cancer therapy: focus on human studies, *Anticancer Agents Med Chem* 13 (2013) 709–719.
- [2] U.V. Mallavadhani, A.V.S. Sudhakar, K.V.S. Satyanarayana, A. Mahapatra, W. Li, R. B. vanBreenen, Chemical and analytical screening of some edible mushrooms, *Food Chem.* 95 (2006) 58–64.
- [3] N. Alam, K.N. Yoon, T.S. Lee, U.Y. Lee, Hypolipidemic activities of dietary *Pleurotus ostreatus* in hypercholesterolemic rats, *MYCOBIOLOGY* 39 (2011) 45–51.
- [4] P. Bobek, L. Ozdin, S. Galbavy, Dose- and time-dependent hypocholesterolemic effect of oyster mushroom (*Pleurotus ostreatus*) in rats, *Nutrition* 14 (1998) 282–286.

- [5] A. Jedinak, D. Sliva, Pleurotus ostreatus inhibits proliferation of human breast and colon cancer cells through p53-dependent as well as p53-independent pathway, *Int. J. Oncol.* 33 (2008) 1307–1313.
- [6] H. Tong, F. Xia, K. Feng, G. Sun, X. Gao, L. Sun, R. Jiang, D. Tian, X. Sun, Structural characterization and in vitro antitumor activity of a novel polysaccharide isolated from the fruiting bodies of *Pleurotus ostreatus*, *Bioresour. Technol.* 100 (2009) 1682–1686.
- [7] T. Jayakumar, E. Ramesh, P. Geraldine, Antioxidant activity of the oyster mushroom, *Pleurotus ostreatus*, on CCl₄-induced liver injury in rats, *Food Chem. Toxicol.* 44 (2006) 1989–1996.
- [8] T. Jayakumar, M. Sakthivel, P.A. Thomas, P. Geraldine, *Pleurotus ostreatus*, an oyster mushroom, decreases the oxidative stress induced by carbon tetrachloride in rat kidneys, heart and brain, *Chem. Biol. Interact.* 176 (2008) 108–120.
- [9] T. Jayakumar, P.A. Thomas, P. Geraldine, Protective effect of an extract of the oyster mushroom, *Pleurotus ostreatus*, on antioxidants of major organs of aged rats, *Exp. Gerontol.* 42 (2007) 183–191.
- [10] K.T. Chu, L. Xia, T.B. Ng, Pleurostrin, an antifungal peptide from the oyster mushroom, *Peptides* 26 (2005) 2098–2103.
- [11] B. Zhu, Y. Li, T. Hu, Y. Zhang, The hepatoprotective effect of polysaccharides from *Pleurotus ostreatus* on carbon tetrachloride-induced acute liver injury rats, *Int. J. Biol. Macromol.* 131 (2019) 1–9.
- [12] P.R. Kodavanti, U.M. Joshi, R.A. Young, E.F. Meydrech, H.M. Mehendale, Protection of hepatotoxic and lethal effects of CCl₄ by partial hepatectomy, *Toxicol. Pathol.* 17 (1989) 494–505.
- [13] M.o.H.a. Population, in: H.a. Population (Ed.), *Plan of Action for the Prevention, Care & Treatment of Viral Hepatitis, 2018*, pp. 1–61. Egypt 2014-2018, http://www.emro.who.int/images/stories/egypt/VH_Plan_of_Action_FINAL_P_RINT1.pdf. Egypt.
- [14] L. Li, T.B. Ng, M. Song, F. Yuan, Z.K. Liu, C.L. Wang, Y. Jiang, M. Fu, F. Liu, A polysaccharide-peptide complex from abalone mushroom (*Pleurotus abalonus*) fruiting bodies increases activities and gene expression of antioxidant enzymes and reduces lipid peroxidation in senescence-accelerated mice, *Appl. Microbiol. Biotechnol.* 75 (2007) 863–869.
- [15] Q. Liu, B. Kong, G. Li, N. Liu, X. Xia, Hepatoprotective and antioxidant effects of porcine plasma protein hydrolysates on carbon tetrachloride-induced liver damage in rats, *Food Chem. Toxicol.* 49 (2011) 1316–1321.
- [16] M. Sreepriya, G. Bali, Effects of administration of Embelin and Curcumin on lipid peroxidation, hepatic glutathione antioxidant defense and hematopoietic system during N-nitrosodiethylamine/Phenobarbital-induced hepatocarcinogenesis in Wistar rats, *Mol. Cell. Biochem.* 284 (2006) 49–55.
- [17] L. Pari, A. Suresh, Effect of grape (*Vitis vinifera* L.) leaf extract on alcohol induced oxidative stress in rats, *Food Chem. Toxicol.* 46 (2008) 1627–1634.
- [18] F.L.M.P.M. Sj, Liver Function tests and the objective evaluation of the patient with liver disease, in: a.B.T. Zakim D (Ed.), *Hepatology: A Textbook of Liver Disease*, WB Saunders, Philadelphia, USA, 1996, pp. 791–833.
- [19] V. Wiwanitkit, High serum alkaline phosphatase levels, a study in 181 Thai adult hospitalized patients, *BMC Fam. Pract.* 2 (2001) 2.
- [20] A. Mansour, A. Daba, N. Baddour, M. El-Saadani, E. Aleem, Schizophyllan inhibits the development of mammary and hepatic carcinomas induced by 7,12 dimethylbenz(alpha)anthracene and decreases cell proliferation: comparison with tamoxifen, *J. Canc. Res. Clin. Oncol.* 138 (2012) 1579–1596.
- [21] I. Sarangi, D. Ghosh, S.K. Bhutia, S.K. Mallick, T.K. Maiti, Anti-tumor and immunomodulating effects of *Pleurotus ostreatus* mycelia-derived proteoglycans, *Int. Immunopharm.* 6 (2006) 1287–1297.
- [22] O.H. Lowry, N.J. Rosebrough, A.L. Farr, R.J. Randall, Protein measurement with the Folin phenol reagent, *J. Biol. Chem.* 193 (1951) 265–275.
- [23] M.G. Dubois, K.A. Hamilton, K. J. P.A. Rebers, F. Smith, Colorimetric method for determination of sugars and related substances, *Anal. Chem.* 28 (1956) 350–356.
- [24] R.J.L. Abraham P, Proton and Carbon-13 NMR Spectroscopy:an Integrated Approach, Heyden, London, 1978.
- [25] S.M. Shaarawy, A.A. Tohamy, S.M. Elgandy, Z.Y. Elmageed, A. Bahnasy, M. S. Mohamed, E. Kandil, K. Matrougui, Protective effects of garlic and silymarin on NDEA-induced rats hepatotoxicity, *Int. J. Biol. Sci.* 5 (2009) 549–557.
- [26] H. Ohkawa, N. Ohishi, K. Yagi, Assay for lipid peroxides in animal tissues by thiobarbituric acid reaction, *Anal. Biochem.* 95 (1979) 351–358.
- [27] S. Marklund, G. Marklund, Involvement of the superoxide anion radical in the autoxidation of pyrogallol and a convenient assay for superoxide dismutase, *J. Biochem.* 47 (1974) 469–474.
- [28] G.L. Ellman, Tissue sulfhydryl groups, *Arch. Biochem. Biophys.* 82 (1959) 70–77.
- [29] W.H. Habig, M.J. Pabst, W.B. Jakoby, Glutathione S-transferases. The first enzymatic step in mercapturic acid formation, *J. Biol. Chem.* 249 (1974) 7130–7139.
- [30] R.C. Shankaraiah, L. Gramantieri, F. Fornari, S. Sabbioni, E. Callegari, M. Negrini, Animal models of hepatocellular carcinoma prevention, *Cancers* (2019) 11.
- [31] T. Uehara, I.P. Pogribny, I. Rusyn, The DEN and CCl₄-induced mouse model of fibrosis and inflammation-associated hepatocellular carcinoma, *Curr Protoc Pharmacol* 66 (2014) 14 30 11–10.
- [32] J.Y. Wu, C.H. Chen, W.H. Chang, K.T. Chung, Y.W. Liu, F.J. Lu, C.H. Chen, Anti-cancer effects of protein extracts from calvatia lilacina, *Pleurotus ostreatus* and *Volvariella volvacea*, *Evid Based Complement Alternat Med* 2011 (2011) 982368.
- [33] X.Y. Cao, J.L. Liu, W. Yang, X. Hou, Q.J. Li, Antitumor activity of polysaccharide extracted from *Pleurotus ostreatus* mycelia against gastric cancer in vitro and in vivo, *Mol. Med. Rep.* 12 (2015) 2383–2389.
- [34] A.S. Younis, J. Wu, S. F. H. El Shikh, F. Hassan, M. Elaasser, Effectiveness of different solvents extracts from edible mushrooms in inhibiting the growth of tumor cells, *Cancer Biology* 4 (2014) 1–15.
- [35] W. Xu, J.J. Huang, P.C. Cheung, Extract of *Pleurotus pulmonarius* suppresses liver cancer development and progression through inhibition of VEGF-induced PI3K/AKT signaling pathway, *PLoS One* 7 (2012), e34406.
- [36] S.A. Nada, E.A. Omara, O.M. Abdel-Salam, H.G. Zahran, Mushroom insoluble polysaccharides prevent carbon tetrachloride-induced hepatotoxicity in rat, *Food Chem. Toxicol.* 48 (2010) 3184–3188.
- [37] K. Pradeep, C.V. Mohan, K. Gobianand, S. Karthikeyan, Silymarin modulates the oxidant-antioxidant imbalance during diethylnitrosamine induced oxidative stress in rats, *Eur. J. Pharmacol.* 560 (2007) 110–116.
- [38] R. Wang, Z. Yang, J. Zhang, J. Mu, X. Zhou, X. Zhao, Liver injury induced by carbon tetrachloride in mice is prevented by the antioxidant capacity of Anji white tea polyphenols, *Antioxidants (Basel)* 8 (3) (2019 Mar) 64, <https://doi.org/10.3390/antiox8030064>.
- [39] C. Sanchez, Reactive oxygen species and antioxidant properties from mushrooms, *Synth Syst Biotechnol* 2 (2017) 13–22.
- [40] E.S. Sutyarso, Taurine and oyster mushroom (*Pleurotus ostreatus*) prevents oxidative damage in liver of mice induced by Paraquat, *Biomedical and Pharmacology Journal* 10 (2017) 1993–2000.
- [41] N.M. El-Sheikh, F.A. Khalil, L-arginine and L-glutamine as immunonutrients and modulating agents for oxidative stress and toxicity induced by sodium nitrite in rats, *Food Chem. Toxicol.* 49 (2011) 758–762.
- [42] M. Andjelkovic, A. Buha Djordjevic, E. Antonijevic, B. Antonijevic, M. Stanic, J. Kotur-Stevuljevic, V. Spasojevic-Kalimanovska, M. Jovanovic, N. Borcic, D. Wallace, Z. Bulat, Toxic effect of acute cadmium and lead exposure in rat blood, liver, and kidney, *Int. J. Environ. Res. Publ. Health* 16 (2019).
- [43] A.N. Ubhenin, C. C. E.J. Dingwoke, Protective effects of *Pleurotus ostreatus* in ameliorating carbon tetrachloride (ccl₄) induced liver injury in Wistar rats, *Med. Plant Res.* 13 (2019) 104–111.
- [44] K.A. Oluyemi, I.O. Omotuyi, O.R. Jimoh, O.A. Adesanya, C.L. Saalu, S.J. Josiah, Erythropoietic and anti-obesity effects of *Garcinia cambogia* (bitter kola) in Wistar rats, *Biotechnol. Appl. Biochem.* 46 (2007) 69–72.
- [45] N.M. El-Deeb, H.I. El-Adawi, A.E.A. El-Wahab, A.M. Haddad, H.A. El Enshasy, Y. W. He, K.R. Davis, Modulation of NKG2D, KIR2DL and cytokine production by *Pleurotus ostreatus* glucan enhances natural killer cell cytotoxicity toward cancer cells, *Front Cell Dev Biol* 7 (2019) 165.