



TITLE:

# Adult-onset Repeat Rhabdomyolysis with a Very Long-chain Acyl-CoA Dehydrogenase Deficiency Due to Compound Heterozygous *ACADVL* Mutations

AUTHOR(S):

Fuseya, Yasuhiro; Sakurai, Takeyo; Miyahara, Jun-ichi; Sato, Kei; Kaji, Seiji; Saito, Yoshihiko; Takahashi, Makio; ... Fukuda, Tokiko; Sugie, Hideo; Yamashita, Hirofumi

---

CITATION:

Fuseya, Yasuhiro ...[et al]. Adult-onset Repeat Rhabdomyolysis with a Very Long-chain Acyl-CoA Dehydrogenase Deficiency Due to Compound Heterozygous *ACADVL* Mutations. *Internal Medicine* 2020, 59(21): 2729-2732

ISSUE DATE:

2020

URL:

<http://hdl.handle.net/2433/259213>

RIGHT:

© 2020 by The Japanese Society of Internal Medicine. The *Internal Medicine* is an Open Access journal distributed under the Creative Commons Attribution-NonCommercial-NoDerivatives 4.0 International License. To view the details of this license, please visit (<https://creativecommons.org/licenses/by-nc-nd/4.0/>).

[ CASE REPORT ]

# Adult-onset Repeat Rhabdomyolysis with a Very Long-chain Acyl-CoA Dehydrogenase Deficiency Due to Compound Heterozygous *ACADVL* Mutations

Yasuhiro Fuseya<sup>1,2</sup>, Takeyo Sakurai<sup>3</sup>, Jun-ichi Miyahara<sup>4</sup>, Kei Sato<sup>5</sup>, Seiji Kaji<sup>2,6</sup>,  
Yoshihiko Saito<sup>7</sup>, Makio Takahashi<sup>8</sup>, Ichizo Nishino<sup>7</sup>, Tokiko Fukuda<sup>9</sup>,  
Hideo Sugie<sup>10</sup> and Hirofumi Yamashita<sup>6</sup>

## Abstract:

Very long-chain acyl-CoA dehydrogenase (VLCAD) deficiency is a genetic disorder of fatty acid beta oxidation that is caused by a defect in *ACADVL*, which encodes VLCAD. The clinical presentation of VLCAD deficiency is heterogeneous, and either a delayed diagnosis or a misdiagnosis may sometimes occur. We herein describe a difficult-to-diagnose case of the muscle form of adult-onset VLCAD deficiency with compound heterozygous *ACADVL* mutations including c.790A>G (p.K264E) and c.1246G>A (p.A416T).

**Key words:** very long-chain acyl-CoA dehydrogenase deficiency, *ACADVL*, rhabdomyolysis

(Intern Med 59: 2729-2732, 2020)

(DOI: 10.2169/internalmedicine.4604-20)

## Introduction

Patients with repeat rhabdomyolysis precipitated by prolonged periods of low-intensity exercise are sometimes left undiagnosed. Clinicians need a high level of suspicion to recognize this condition, and they should diagnose the condition correctly and treat it properly. We herein describe the suggestive features of this condition, and also present an educational case.

Very long-chain acyl-CoA dehydrogenase (VLCAD) deficiency is an autosomal recessive rare metabolic disorder of mitochondrial fatty acid oxidation (1), which is essential for energy production during prolonged fasting or long-time exercise (2, 3). In those conditions, the body switches from using carbohydrates to fatty acids for energy production. In VLCAD deficiency, because of the inability to use long-

chain fatty acids, prolonged fasting and exertion predispose the patient to develop acute metabolic decompensation, hypoketotic hypoglycemia, cardiomyopathy, and rhabdomyolysis (3-5).

The clinical presentation of VLCAD deficiency is heterogeneous. Three clinical groups have been recognized: (a) a severe form in newborns with high mortality and a high incidence of cardiomyopathy; (b) an intermediate form in childhood with episodes of hypoketotic hypoglycemia and liver dysfunction; and (c) a muscle form in adolescents or adults with exercise intolerance, recurrent myoglobinemia, and rhabdomyolysis.

Newborn screening for VLCAD deficiency began in 2014 in Japan, thereby increasing the recognition of this disease. However, making an accurate diagnosis of VLCAD deficiency, especially the adult-onset muscle form, still remains challenging (6-10).

<sup>1</sup>Department of Molecular and Cellular Physiology, Graduate School of Medicine, Kyoto University, Japan, <sup>2</sup>Department of Neurology, Graduate School of Medicine, Kyoto University Hospital, Japan, <sup>3</sup>Sakurai Clinic, Japan, <sup>4</sup>Department of Neurology, Tominaga Hospital, Japan, <sup>5</sup>Department of Neurology, Uji Hospital, Japan, <sup>6</sup>Department of Neurology, Japanese Red Cross Wakayama Medical Center, Japan, <sup>7</sup>Department of Neuromuscular Research, National Institute of Neuroscience, National Center of Neurology and Psychiatry, Japan, <sup>8</sup>Department of Neurology, Japanese Red Cross Osaka Hospital, Japan, <sup>9</sup>Department of Pediatrics, Hamamatsu University School of Medicine, Japan and <sup>10</sup>Faculty of Health and Medical Sciences, Tokoha University, Japan

Received: February 6, 2020; Accepted: June 3, 2020; Advance Publication by J-STAGE: July 14, 2020

Correspondence to Dr. Hirofumi Yamashita, [hirofumi@kuhp.kyoto-u.ac.jp](mailto:hirofumi@kuhp.kyoto-u.ac.jp)

We herein report a difficult-to-diagnose case of VLCAD deficiency with compound heterozygous *ACADVL* mutations.

## Case Report

A 25-year-old Japanese man came to our hospital for severe myalgia, muscle weakness, and dark brown urine after overnight work in a food factory. We found a marked elevation of his serum creatine kinase (CK) level to 58,400 IU/L (normal range; 59-248 IU/L). These symptoms resolved and the serum CK level improved to 68 IU/L with rest and an intravenous saline drip.

Nine months before visiting our hospital, he had experienced severe myalgia with a walking disturbance after walking for about 50 minutes, but these symptoms spontaneously disappeared within a few days. The patient was the first child of non-consanguineous healthy parents, and his family history was negative for neuromuscular disorders. He attained normal psychomotor and growth developmental milestones. He had no episodes of muscle weakness, myoglobinuria, or excessive myalgia after hard exercise before 25 years of age, even though he enjoyed intensive leisure physical activities such as swimming, baseball, judo, and badminton from kindergarten to college. Infections did not induce these symptoms. He had episodes of myalgia that lasted several days after fishing while hungry, which he regarded as normal.

Three months after his severe attack, he was admitted to our hospital for a muscle biopsy. Physical examinations showed no abnormalities, and he had no myalgia. Neurological examinations also revealed no muscle weakness or atrophy, and his deep tendon reflexes were normal. Electrocardiography, chest radiography, and echocardiography showed no significant findings. The serum level of CK at rest was 74 IU/L, but needle electromyography revealed myogenic changes in the muscles of the biceps brachii, first dorsal interosseous, and tibialis anterior, and therefore, we performed a biopsy of the biceps brachii muscle. Hematoxylin and Eosin (H&E) staining of the muscle biopsy specimen revealed no specific findings (Figure A).

Oil Red O staining revealed no lipid accumulation (Figure B), excluding a multiple acyl-CoA dehydrogenase deficiency, which is a treatable disorder, or other conditions that caused the accumulation of intramuscular lipid droplets. At this time, carnitine palmitoyl transferase II deficiency and VLCAD deficiency were considered in the major differential diagnoses.

As expected, VLCAD immunostaining in muscle samples showed an apparent reduction of VLCAD (Figure C). An enzymatic assay for the VLCAD activity in the patient's muscle showed a decreased dehydrogenase activity of long-chain acyl-CoA (Figure D), which indicated the diagnosis of VLCAD deficiency. The sequencing of *ACADVL* showed compound heterozygous mutations in *ACADVL* including c.790A>G (p.K264E) and c.1246G>A (p.A416T) (Fig-

ure E).

Based on this definitive diagnosis, we advised him to avoid hard labor, long-time exercise, and fasting, as well as to consume a diet rich in carbohydrates and low in long-chain fatty acids. He is currently 34 years old without any symptoms, and his serum total carnitine, free carnitine, and acylcarnitine are all within the normal range, thus suggesting that these recommendations are effective.

## Discussion

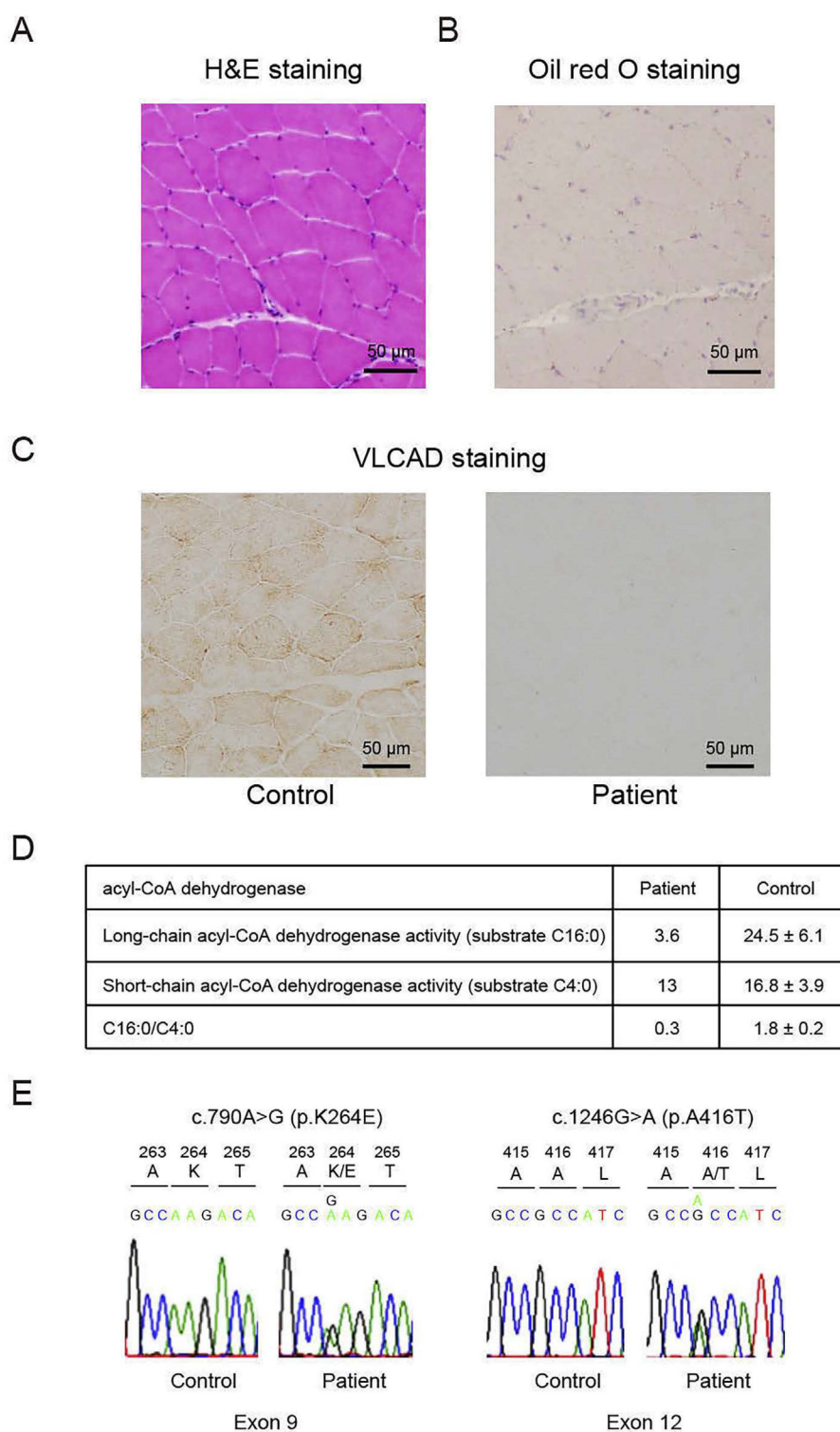
In most patients, the first episode of rhabdomyolysis is provoked by an acquired cause. However, when rhabdomyolysis recurs, suspicion of an underlying genetic cause arises. The recurrent rhabdomyolysis in this patient made us suspect adult-onset metabolic myopathies, which are conditions involving a defective glycogen metabolism or fatty acid metabolism. In particular, conditions involving the fatty acid metabolism were strongly suspected in this patient for two reasons. First, his symptoms were precipitated by prolonged periods of low-intensity exercise, and second, the serum CK level was normal between the episodes of such symptoms.

VLCAD immunostaining is very useful for the diagnosis of VLCAD deficiency (11). VLCAD immunostaining in our patient's muscle samples showed an apparent reduction, leading to a rapid and accurate diagnosis, via measurement of the acyl-CoA dehydrogenase activity and a genetic analysis of *ACADVL*.

On the other hand, an analysis of the blood acylcarnitine profile is also very practical for the diagnosis of VLCAD deficiency (4, 10, 12). Notably, blood examinations can screen for fatty acid metabolism disorders such as VLCAD deficiency, carnitine palmitoyl transferase II deficiency, and multiple acyl-CoA dehydrogenase deficiency, although our patient did not undergo that test. Different methods for diagnosing VLCAD deficiency, including the assessment of organic acids in the urine, another practical method, has been summarized by Voermans et al. (13).

To date, more than two hundred pathogenic mutations have been reported in *ACADVL* (The Human Gene Mutation Database; <http://www.hgmd.cf.ac.uk/ac/index.php>), and a correlation between genotype and phenotype has been suggested in VLCAD deficiency. A severe childhood phenotype is caused by mutations that produce no residual enzyme activity, whereas milder childhood or adult phenotypes are caused by mutations that result in some residual enzyme activity (14). Our patient had compound heterozygous missense mutations, p.K264E and p.A416D, both of which have been individually reported previously (15, 16) and which retain some residual activity (16). Therefore, our case had an adult-onset mild phenotype, displaying severe myalgia, muscle weakness, and dark brown urine as the first attack at 25 years of age.

In conclusion, life-threatening consequences can occur even in adults with milder forms of VLCAD deficiency,



**Figure.** Immunohistology and genetic analysis. (A) Representative images of Hematoxylin and Eosin staining of biceps brachii muscle. (B) Oil Red O staining of biceps brachii muscle. (C) The tissue of the biceps brachii muscle was stained with VLCAD antibody. The left image is from a control, and the right image is from our patient. (D) Acyl-CoA dehydrogenase activities in muscle. Activities are expressed as nmol/min/mg. Long-chain acyl-CoA dehydrogenase activity in our patient was strongly decreased. (E) DNA sequence analysis of exon 9 and exon 12 in *ACADVL* in our patient showed compound heterozygous mutations of c.790A>G (p.K264E) (left) and c.1246 G>A (p.A416T) (right).

such as acute renal failure requiring dialysis (17) and acute postpartum cardiomyopathy in a woman with primi-gravida (18). Therefore, physicians should be aware of this

unusual cause of rhabdomyolysis in adults, because recurrent rhabdomyolysis can be prevented with lifestyle changes.

**The authors state that they have no Conflict of Interest (COI).**

### Financial Support

This study was supported partly by an Intramural Research Grant (29-4) for Neurological and Psychiatric Disorders of NCNP, and partly by the Japan Agency for Medical Research and Development (AMED) under Grant Numbers JP19ek0109285h0003 and 18kk0205001s0203.

### References

1. Aoyama T, Uchida Y, Kelley RI, et al. A novel disease with deficiency of mitochondrial very-long-chain acyl-CoA dehydrogenase. *Biochem Biophys Res Commun* **191**: 1369-1372, 1993.
2. Arnold GL, Van Hove J, Freedberg D, et al. A Delphi clinical practice protocol for the management of very long chain acyl-CoA dehydrogenase deficiency. *Mol Genet Metab* **96**: 85-90, 2009.
3. Knottnerus SJG, Bleeker JC, Wust RCI, et al. Disorders of mitochondrial long-chain fatty acid oxidation and the carnitine shuttle. *Rev Endocr Metab Disord* **19**: 93-106, 2018.
4. Laforet P, Acquaviva-Bourdain C, Rigal O, et al. Diagnostic assessment and long-term follow-up of 13 patients with Very Long-Chain Acyl-Coenzyme A dehydrogenase (VLCAD) deficiency. *Neuromuscul Disord* **19**: 324-329, 2009.
5. Lilleker JB, Keh YS, Roncaroli F, Sharma R, Roberts M. Metabolic myopathies: a practical approach. *Pract Neurol* **18**: 14-26, 2018.
6. Ogilvie I, Pourfarzam M, Jackson S, Stockdale C, Bartlett K, Turnbull DM. Very long-chain acyl coenzyme A dehydrogenase deficiency presenting with exercise-induced myoglobinuria. *Neurology* **44**: 467-473, 1994.
7. Smelt AH, Poorthuis BJ, Onkenhout W, et al. Very long chain acyl-coenzyme A dehydrogenase deficiency with adult onset. *Ann Neurol* **43**: 540-544, 1998.
8. Merinero B, Pascual Pascual SI, Perez-Cerda C, et al. Adolescent myopathic presentation in two sisters with very long-chain acyl-CoA dehydrogenase deficiency. *J Inherit Metab Dis* **22**: 802-810, 1999.
9. Voermans NC, Poels PJ, Kluijtmans LA, van Engelen BG. The effect of dantrolene sodium in Very Long Chain Acyl-CoA dehydrogenase deficiency. *Neuromuscul Disord* **15**: 844-846, 2005.
10. Yamamoto F, Nakamagoe K, Yamada K, et al. A case of very-long-chain acyl-coenzyme A dehydrogenase deficiency with novel compound heterozygous mutations. *J Neurol Sci* **368**: 165-167, 2016.
11. Ohashi Y, Hasegawa Y, Murayama K, et al. A new diagnostic test for VLCAD deficiency using immunohistochemistry. *Neurology* **62**: 2209-2213, 2004.
12. Antunes AP, Nogueira C, Rocha H, Vilarinho L, Evangelista T. Intermittent rhabdomyolysis with adult onset associated with a mutation in the ACADVL gene. *J Clin Neuromuscul Dis* **15**: 69-72, 2013.
13. Voermans NC, van Engelen BG, Kluijtmans LA, Stikkelbroeck NM, Hermus AR. Rhabdomyolysis caused by an inherited metabolic disease: very long-chain acyl-CoA dehydrogenase deficiency. *Am J Med* **119**: 176-179, 2006.
14. Andresen BS, Olpin S, Poorthuis BJ, et al. Clear correlation of genotype with disease phenotype in very-long-chain acyl-CoA dehydrogenase deficiency. *Am J Hum Genet* **64**: 479-494, 1999.
15. Fukao T, Watanabe H, Orii K, et al. Myopathic form of very-long chain acyl-coa dehydrogenase deficiency: evidence for temperature-sensitive mild mutations in both mutant alleles in a Japanese girl. *Pediatr Res* **49**: 227-231, 2001.
16. Takusa Y, Fukao T, Kimura M, et al. Identification and characterization of temperature-sensitive mild mutations in three Japanese patients with nonsevere forms of very-long-chain acyl-CoA dehydrogenase deficiency. *Mol Genet Metab* **75**: 227-234, 2002.
17. Cairns AP, O'Donoghue PM, Patterson VH, Brown JH. Very-long-chain acyl-coenzyme A dehydrogenase deficiency-a new cause of myoglobinuric acute renal failure. *Nephrol Dial Transplant* **15**: 1232-1234, 2000.
18. Murata KY, Sugie H, Nishino I, Kondo T, Ito H. A primigravida with very-long-chain acyl-CoA dehydrogenase deficiency. *Muscle Nerve* **49**: 295-296, 2014.

The Internal Medicine is an Open Access journal distributed under the Creative Commons Attribution-NonCommercial-NoDerivatives 4.0 International License. To view the details of this license, please visit (<https://creativecommons.org/licenses/by-nc-nd/4.0/>).