Scanning Microscopy

Volume 9 | Number 4 Article 27

10-13-1995

Vascular Architecture of the Lactating and Non-Lactating Teat of the Bitch: A Scanning Electron- and Light Microscope Study

F. J. Pérez-Aparicio
Autonomous University of Barcelona

V. Dantzer
Royal Veterinary and Agricultural University

M. Navarro
Autonomous University of Barcelona

A. Carretero
Autonomous University of Barcelona

J. Ruberte
Autonomous University of Barcelona

Recommended Citation

Pérez-Aparicio, F. J.; Dantzer, V.; Navarro, M.; Carretero, A.; and Ruberte, J. (1995) "Vascular Architecture of the Lactating and Non-Lactating Teat of the Bitch: A Scanning Electron- and Light Microscope Study," *Scanning Microscopy*: Vol. 9 : No. 4 , Article 27.
Available at: https://digitalcommons.usu.edu/microscopy/vol9/iss4/27

Scanning Microscopy, Vol. 9, No. 4, 1995 (Pages 1255-1266) 0891-7035/95$5.00+.25
Scanning Microscopy International, Chicago (AMF O'Hare), IL 60666 USA

VASCULAR ARCHITECTURE OF THE LACTATING AND NON-LACTATING TEAT OF THE BITCH: A SCANNING ELECTRON- AND LIGHT MICROSCOPE STUDY

F.J. Pérez-Aparicio[1], V. Dantzer[2], M. Navarro[1], A. Carretero[1] and J. Ruberte[1,*]

[1]Dept. Anatomy and Embryology, Veterinary Faculty, Autonomous Univ. of Barcelona, 08193 Bellaterra, Spain
[2]Dept. Anatomy and Physiol., Royal Veter. and Agric. Univ., Bülowsvej 13, DK-1870 Frederiksberg-C, Denmark

(Received for publication April 7, 1995 and in revised form October 13, 1995)

Abstract

Tissues from fourteen mammary glands of eight bitches were prepared for scanning electron microscopy of vascular corrosion casts and for histology to study the vasculature of the lactating and non-lactating teats. The densely-meshed mammary dermal capillary network formed ridges and troughs. The teat ducts were vascularized by a relatively densely-meshed capillary network which drained into veins longitudinally oriented to the ducts. Between eight and fifteen teat duct openings were seen on the tip of the teat, that were sometimes divided by a septum. The inner vascularization of the teat showed that the main papillary arteries divided into undulating secondary papillary arteries which presented numerous semi-constrictions and loops. Their structure may help during erection of the teat. Arteriovenous anastomoses found at different points may participate in blood flow maintenance during suckling, heat regulation and teat erection. Veins freely anastomosed and ran longitudinally to the axis of the teat. They exhibited numerous bicuspid valves. In non-lactating teats, vessels showed the same main architecture and characteristics mentioned above, although these were considerably less marked. The structure of the vascular elements in the teat of the bitch could favor blood flow during suckling and suggest that vessels adapt to the physiological situation.

Key Words: Microcirculation, corrosion casting, nipples, lactation, dogs, scanning electron microscopy.

[*]Address for correspondence:
Jesús Ruberte,
Department of Anatomy and Embryology,
Veterinary Faculty,
Autonomous University of Barcelona,
08193-Bellaterra,
Spain
Telephone number: (34) 3 5811846
FAX number: (34) 3 5812006

Introduction

The mammary gland undergoes marked morphological and functional changes during the reproductive cycle (Griffith and Turner, 1961; Desjardins *et al.*, 1968; Murad, 1970; Grahame and Bertalanffy, 1972; Hollman, 1974; Knight and Peaker, 1982). The vascularization of the mammary gland changes as well, according to the physiological variations occurring during virgin, pregnancy, lactation and involution (Wahl, 1915; Soemarwoto and Bern, 1958; Nishinakagawa, 1970; Matsumoto *et al.*, 1988, 1992). Moussa (1982) also noticed differences in the structure of the blood vessels that supply the teat of the buffalo under different physiological conditions.

The mammary gland of the bitch consists most commonly of five pairs of mammary complexes (*Mammae*) on each body side. The usual pairs of glands are two thoracic, two abdominal and one inguinal (Silver, 1966). Each mammary complex has two component parts: the glandular body (*Corpus mammae*) and the teat (*Papilla mammae*) (Schummer *et al.*, 1981). The distal third of the teat is occupied by eight to twenty-two teat ducts (*Ductus papillaris*) in the dog (Turner, 1939) which open in a roughly circular pattern on the end of the teat (*Ostium papillare*). Proximally, each teat duct connects with a teat sinus (*Pars papillaris sinus lactifer*) which continues into a lobule of the gland (Silver, 1966).

The different pairs of mammary gland complexes are not supplied by the same blood vessels and vary considerably in number and importance (Silver, 1966; Habel, 1978; Schummer *et al.*, 1981; Evans, 1993). The main arteries are as follows: (1) for the thoracic complexes, the internal thoracic artery (*A. thoracica interna*), intercostal arteries (*Aa. intercostales*) and the lateral thoracic artery (*A. thoracica lateralis*); (2) for the abdominal and inguinal complexes, the cranial and caudal superficial epigastric arteries (*A. epigastrica cranialis superficialis* et *A. epigastrica caudalis superficialis*), intercostal arteries, the caudal phrenic artery (*A. phrenica caudalis*), the cranial abdominal artery (*A. abdominalis cranialis*) and the deep circumflex iliac artery (*A.*

Figure 1. Vascular cast of a non-lactating teat sectioned longitudinally with the teat tip oriented to top. Note some low-density vascular areas (*) typical for the non-lactating state. The dermal capillary network is densely-meshed and forms ridges and troughs (arrows). This network upon the teat tip is closely connected to the inner vascularization than elsewhere. Inner vessels tend to ran longitudinally without undulations (compare Fig. 8). Bar = 0.7 mm.

Figure 2. Magnified view of the dermal capillary network around the base of a non-lactating teat, forming ridges and troughs. Note the central arteriolar-venular system (stars) supplying the capillary network with capillary loops (arrows) projecting towards the epidermis. Bar = 0.2 mm.

Figure 3. Histological overview of a transversal section of a non-lactating teat. Most teat ducts, with their occasional belt of accessory glands, are collapsed (arrowheads). Inner and subdermal vessels (stars) are dilated from perfusion fixation of the sample. Bar = 0.9 mm. **Inset** shows a magnified view of a teat duct with its corrugated epithelium and some accessory glands (a) surrounded by, in part, densely aggregated capillaries (stars). L: lumen of the teat duct. Bar = 0.1 mm.

Figure 4. Vascular aspect of the tip of a non-lactating teat from a ventral view showing the teat duct openings (*). Bar = 0.5 mm. **Inset** shows the magnified view of a teat duct opening divided by a septum (arrow) which consists of a moderately-meshed, almost flat capillary network. Bar = 0.1 mm.

circumflexa ilium profunda). The venous drainage is parallel to the arterial supply (Silver, 1966).

The vascularization of the teat in the bitch has not been studied yet, although some articles deal with that of other species like the cow (Fürstenberg, 1868; Riederer, 1903; Rubeli, 1916; Foust, 1941; Turner, 1952; Habel, 1978; Schummer *et al.*, 1981), small ruminants (Schummer *et al.*, 1981), the buffalo (Moussa, 1982; Badawi *et al.*, 1985), the rabbit (Wahl, 1915), the weddell seal (Tedman and Bryden, 1981), and the woman (Vorherr, 1974).

The aim of the present work is to study the vascular architecture of both lactating and non-lactating teats of the bitch by means of scanning electron microscopy (SEM) of Araldite corrosion casts and light microscopy (LM) of serial sections. The morphology of the vascular organization is compared between the two physiological activities, lactating and non-lactating.

Material and Methods

For the SEM study of vascular corrosion casts, eleven teats of the abdominal and inguinal gland complexes were obtained from five lactating and two non-lactating bitches.

All animals, apart from one German Shepherd, were ordinary crossbreed bitches, obtained from a Municipal kennel. The age averaged 39 months ranging from one to ten years. The age of the animals was estimated by Boenisch's Table (1913), based on wear of the teeth.

The animals were sedated with propenyl-promazine (Combelen®; Bayer) and injected with heparin. Euthanasia was carried out intravenously with sodium pentobarbital at a dosage of 40 mg per kg of body weight. The mammary glands were perfused through the caudal superficial epigastric artery with physiological saline (30°C) and phosphate buffered 5% glutaraldehyde and, according to the method of Hanstede and Gerrits (1982), followed by 10 to 30 ml (depending on the size and lactational state of the bitch) of a mixture of Araldite CY 223, hardener HY 2967 and color DW (all from Ciba-Geigy, Barcelona, Spain). According to Hanstede and Gerrits (1982), the density of plastic was 1.11 ± 0.01 g/cm^3 and the viscosity of the mixture was similar to that of the blood at the time of injection. The flow was kept constant at 2 ml per minute, by means of a syringe infusion pump (Harvard Apparatus, South Natick, MA, USA), until the complete filling of the mammary vascular system. This was considered to happen when the filling of the dermal vessels colored the skin around the teats. The injected resin hardened in approximately 12 hours at room temperature.

Subsequently, the mammary complexes were cut out from the body and soaked overnight or longer in a corrosion medium of 10% KOH at room temperature. After several rinses in running water for hours alternating with corrosion and a final wash in distilled water, the casts of the mammary complexes were clean and ready for dissection in water with a sharpened forceps under a stereo microscope (SMZ-U, Nikon). Part of these dissected samples were embedded in a 10% gelatine solution and freeze-cut with razor blades (Leiser, 1985). Gelatine was digested in 40% KOH and the resulting smaller casts were rinsed several times in distilled water.

The vascular casts of mammary glands, thus prepared, were air-dried, mounted on stubs, coated with gold in a sputter coater (E-5400, Polaron), and observed with either a Hitachi S-570 SEM or a JEOL JSM-840A SEM operated at an accelerating voltage of 7-10 kV.

For the LM study, three teats of the abdominal and inguinal mammary complexes were obtained from one non-lactating female German Shepherd, shortly after euthanasia. The animal was obtained from the Royal Veterinary and Agricultural University of Copenhagen.

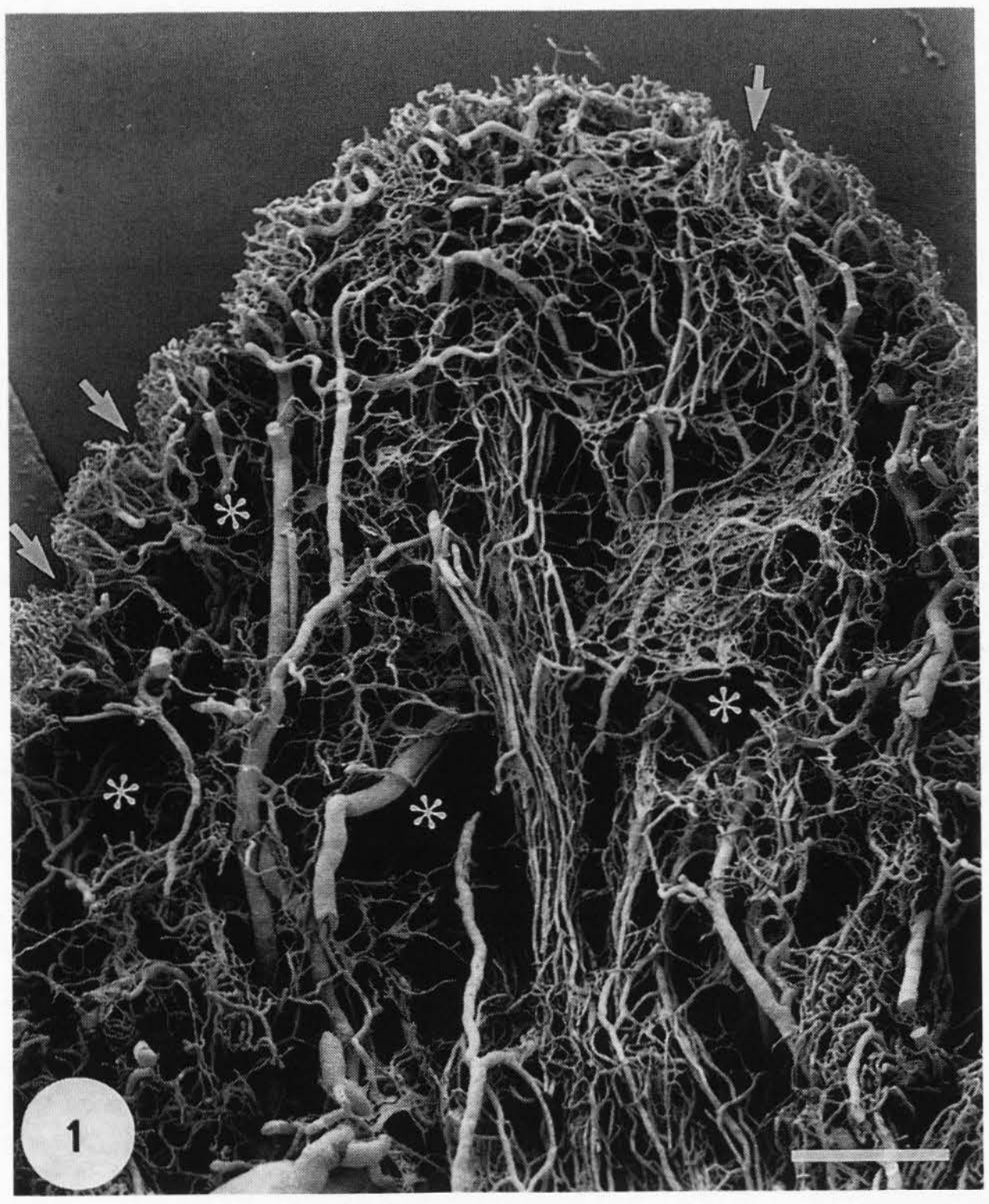
1

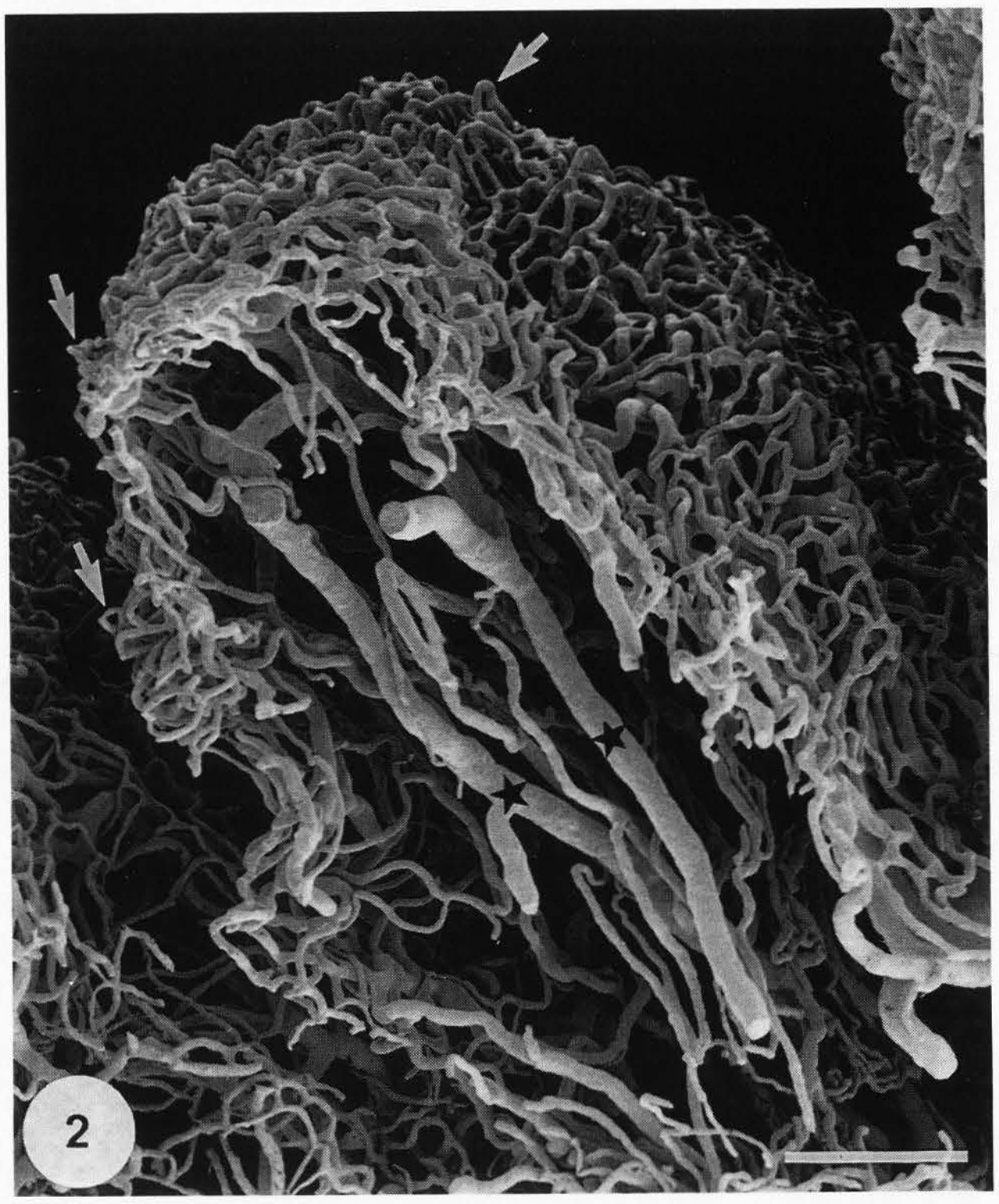
2

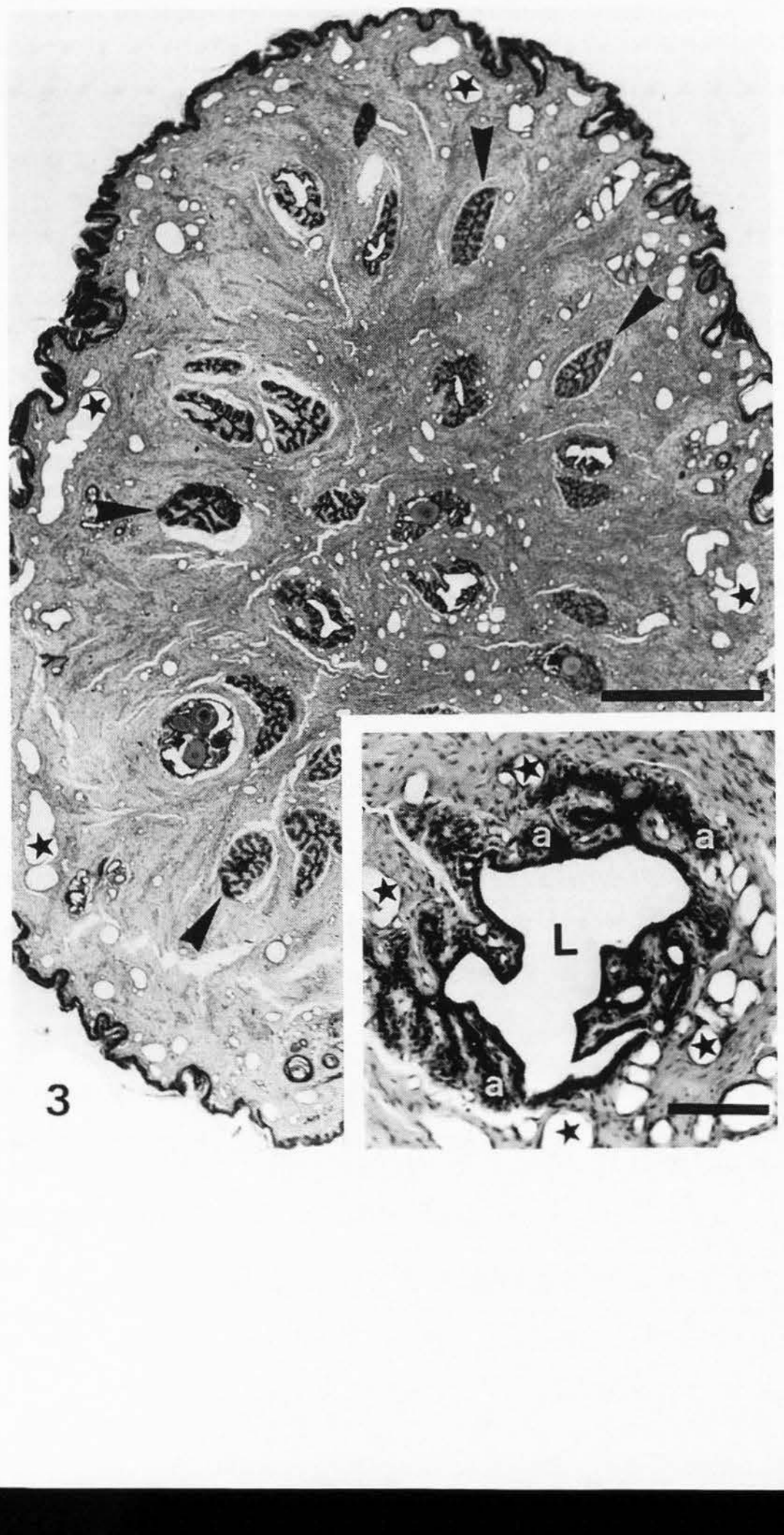
3

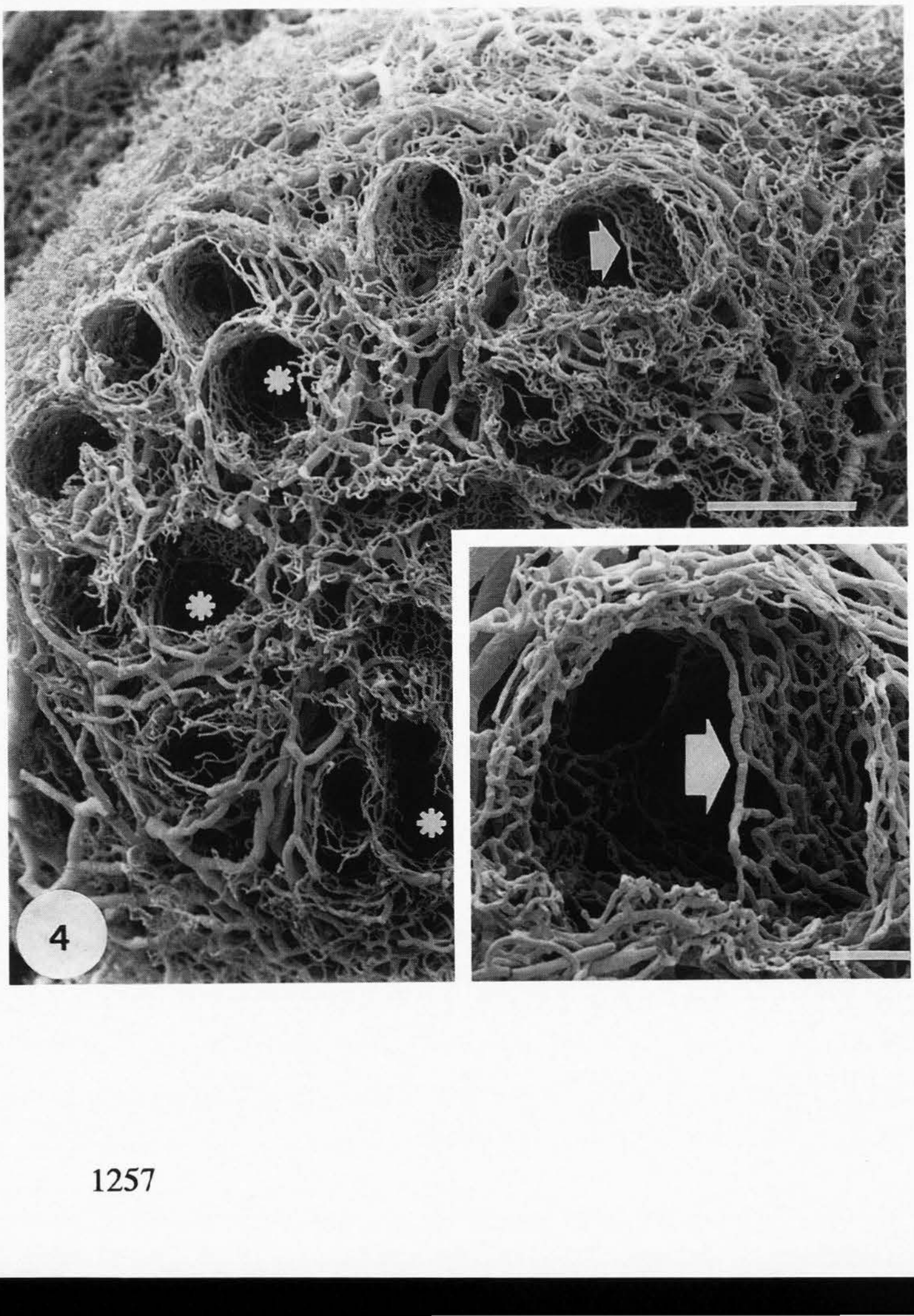
4

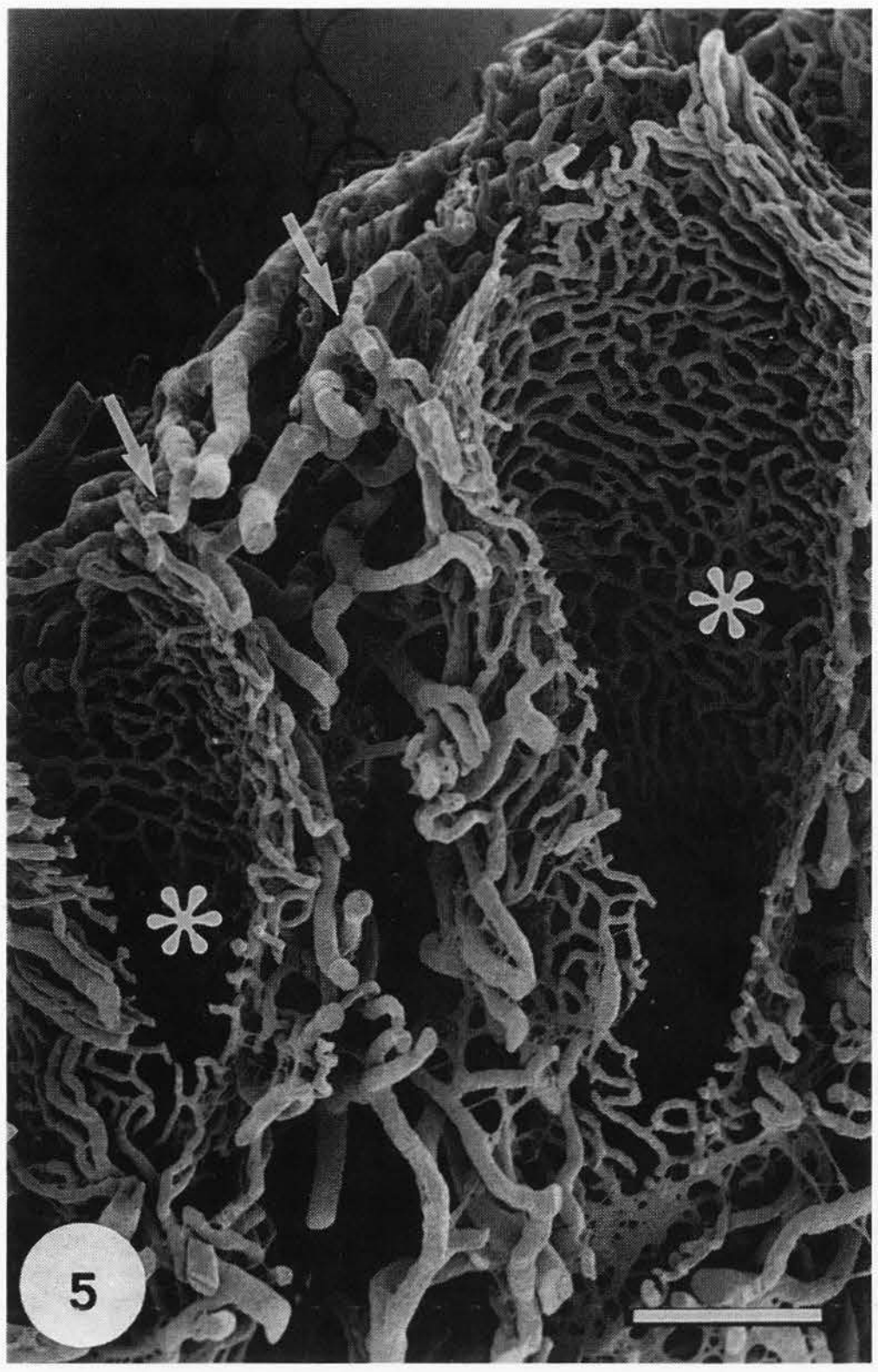

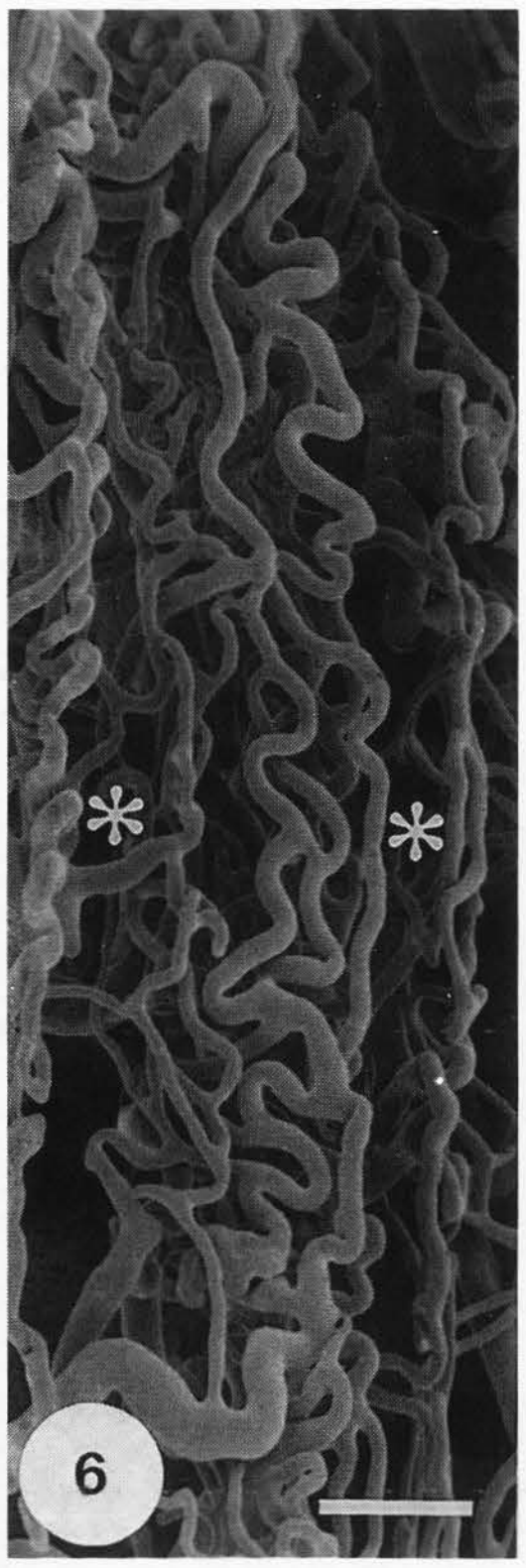

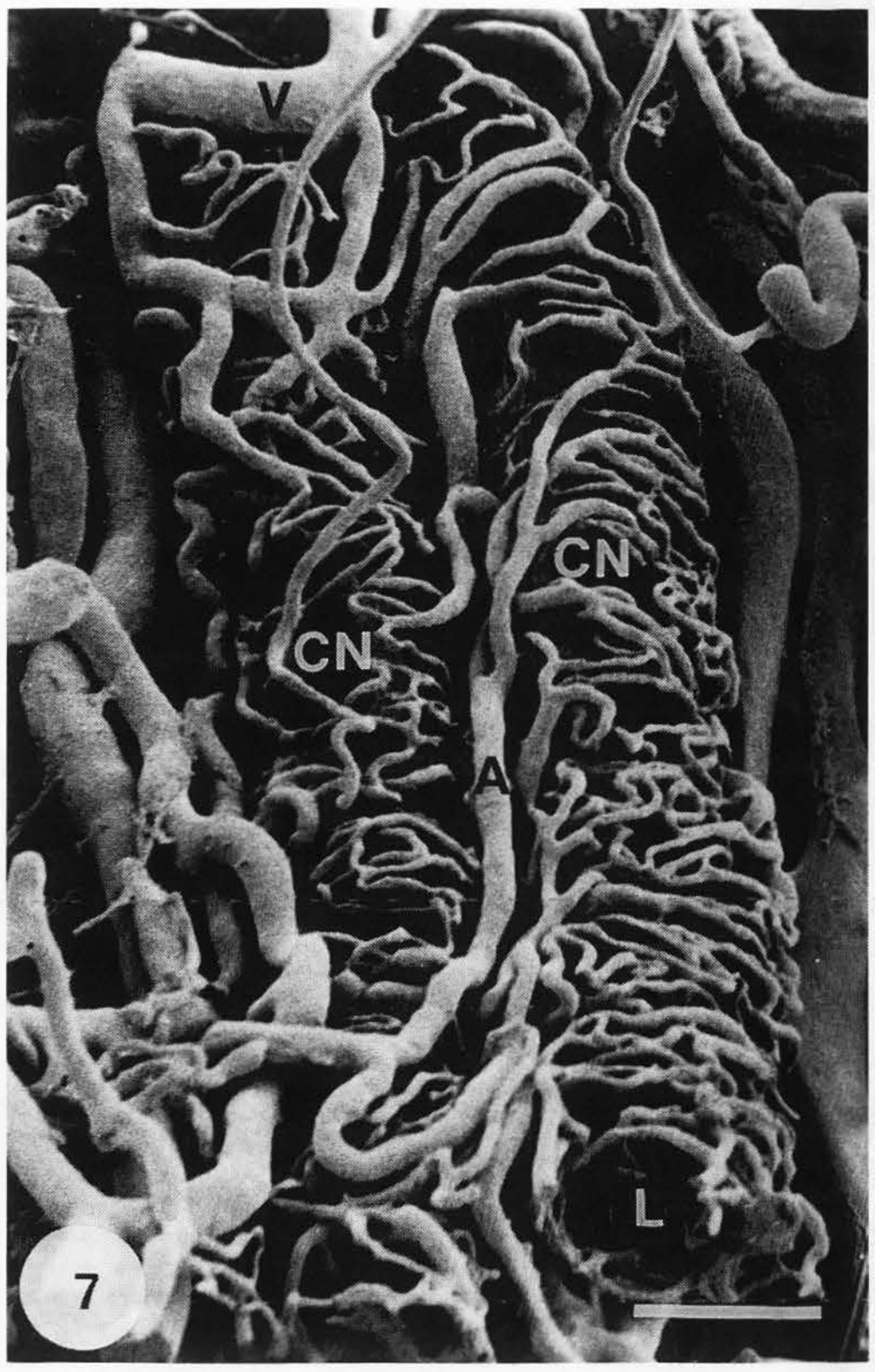

Figure 5. Detail of the tip of a lactating teat sectioned longitudinally. The vascular cast shows the lumen of two teat ducts (*) surrounded by a relatively densely-meshed capillary network which continues into the dermal arteriolar-venular system of the tip of the teat (arrows). Bar = 0.2 mm.

Figure 6. View into a longitudinally opened lactating teat duct. Folds projecting into the lumen of the duct are bordered by meandering capillaries. Asterisks show troughs between folds. Bar = 70 μm.

Figure 7. Vascular cast of two lactating teat ducts from the middle part of the teat. A small longitudinal artery (A) runs along the ducts giving off arteriolar branches to the capillary network (CN), which drains into venules and a vein (V). L: lumen. Bar = 100 μm.

Figures 8-11 on the facing page

Figure 8. Dissected vessel cast of a lactating teat viewed from the lateral side showing the inner vascularization. The main papillary arteries (MA) form big arches (*) and divide into secondary papillary arteries (SA), which present loops (arrowhead) and constrictions (arrows). Veins (V) converge and run longitudinally towards the base of the teat to a collecting venous ring (VR, bottom). Tip of the teat (top). Bar = 0.6 mm.

Figure 9. Arterial constrictions in secondary papillary arteries. **(a)** Vessel cast of a lactating teat showing a constriction (arrow) in a secondary papillary artery after being branched from a main papillary artery. Note that on one side of the artery the vessel diameter diminishes to about half, creating a semi-constriction. Bar = 100 μm **(b)** Histological detail of a secondary papillary artery of a non-lactating teat with a luminally-oriented, wedge-shaped constriction (arrow). Bar = 32 μm.

Figure 10. Constriction (arrow) in a small artery of a lactating teat. Note that this constriction is not related to sudden bending of the artery. Bar = 40 μm.

Figure 11. Vascular cast of a lactating teat showing an arteriovenous shunt. The short and spiral connection (*) joins an arteriole (At) and a venule (Vn). Bar = 13 μm.

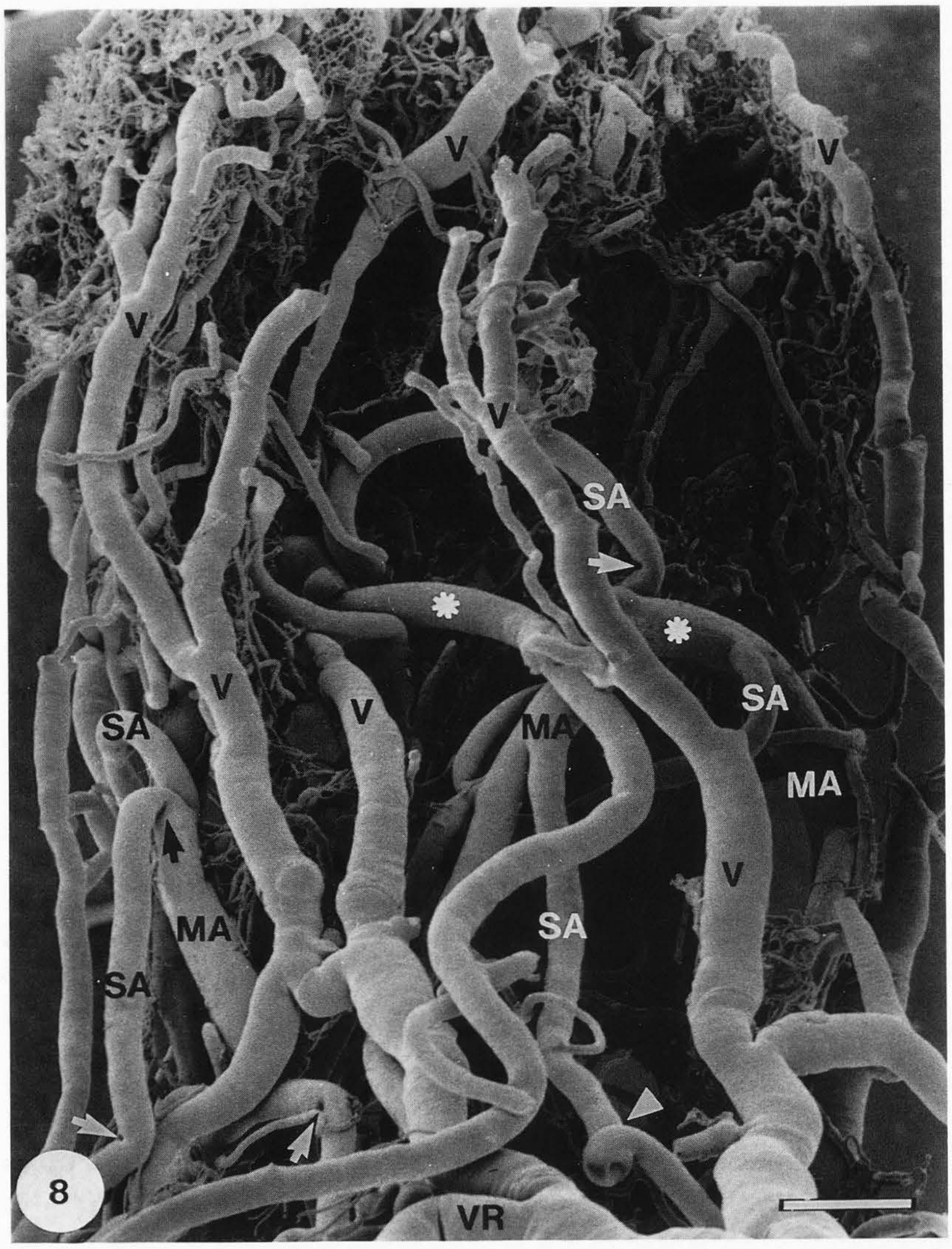
8
V
V
V
V
SA
V
V
SA
SA
MA
MA
MA
V
SA
SA
VR

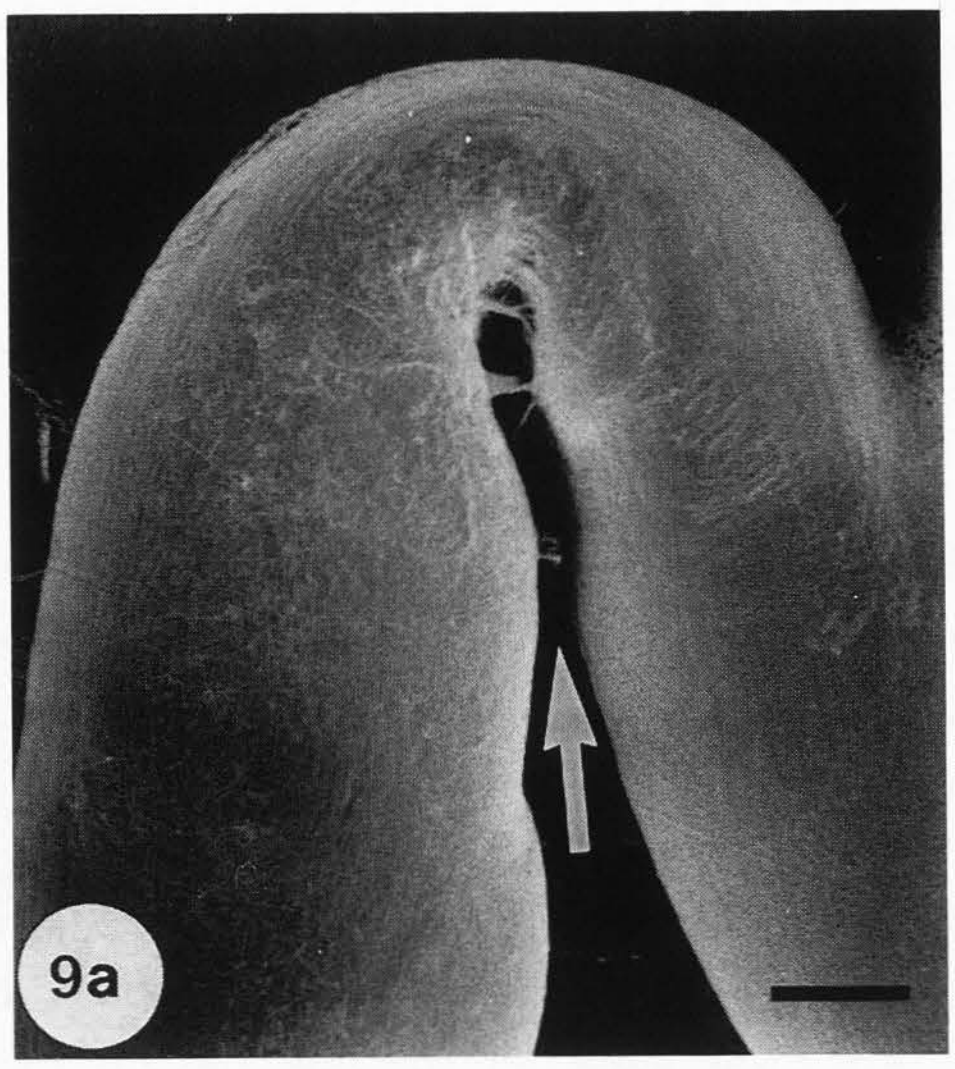
9a

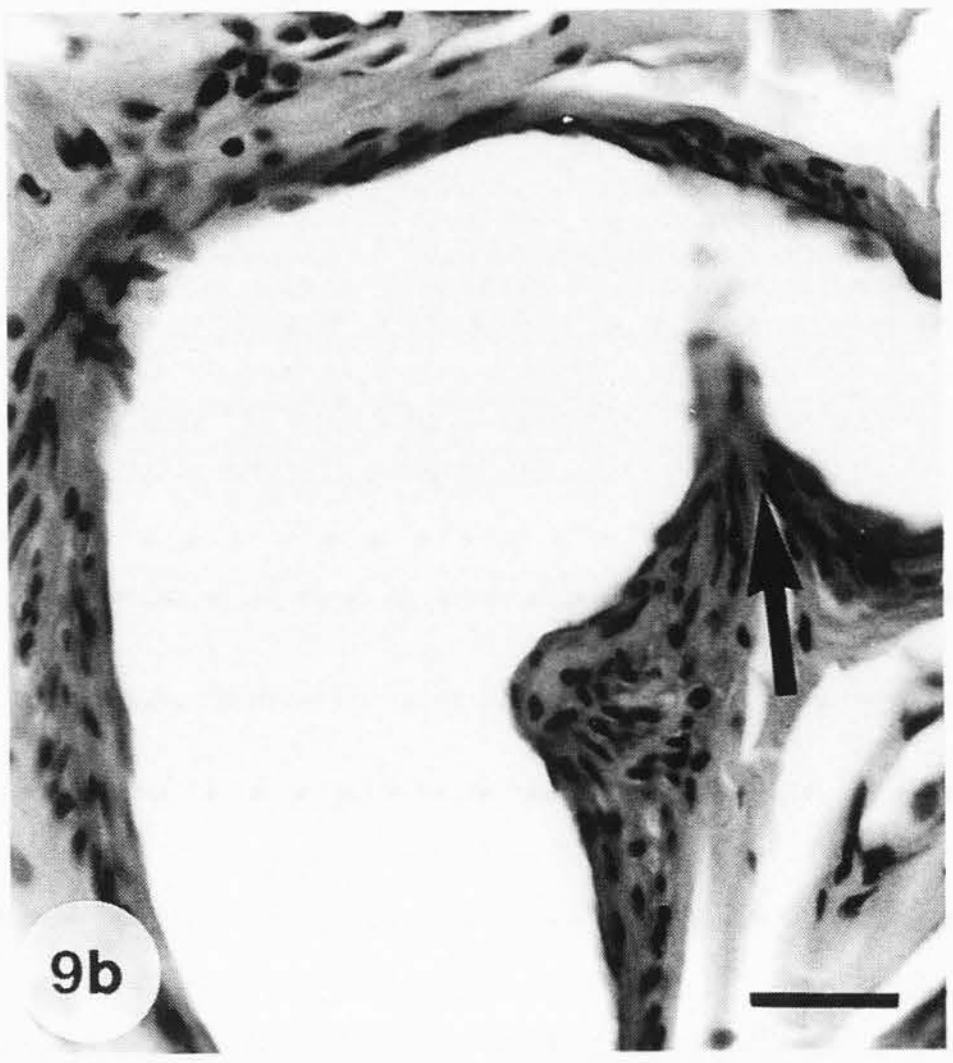
9b

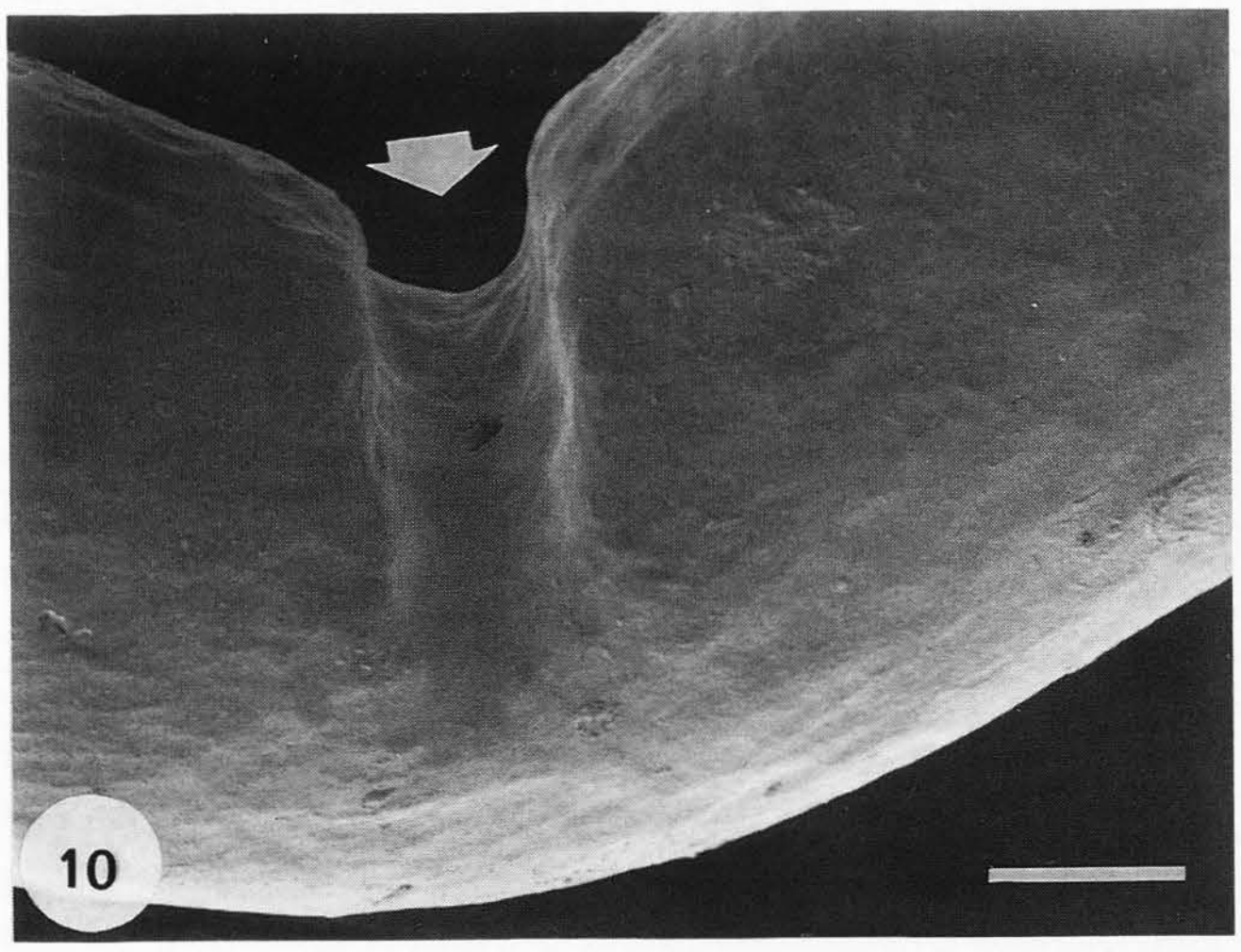
10

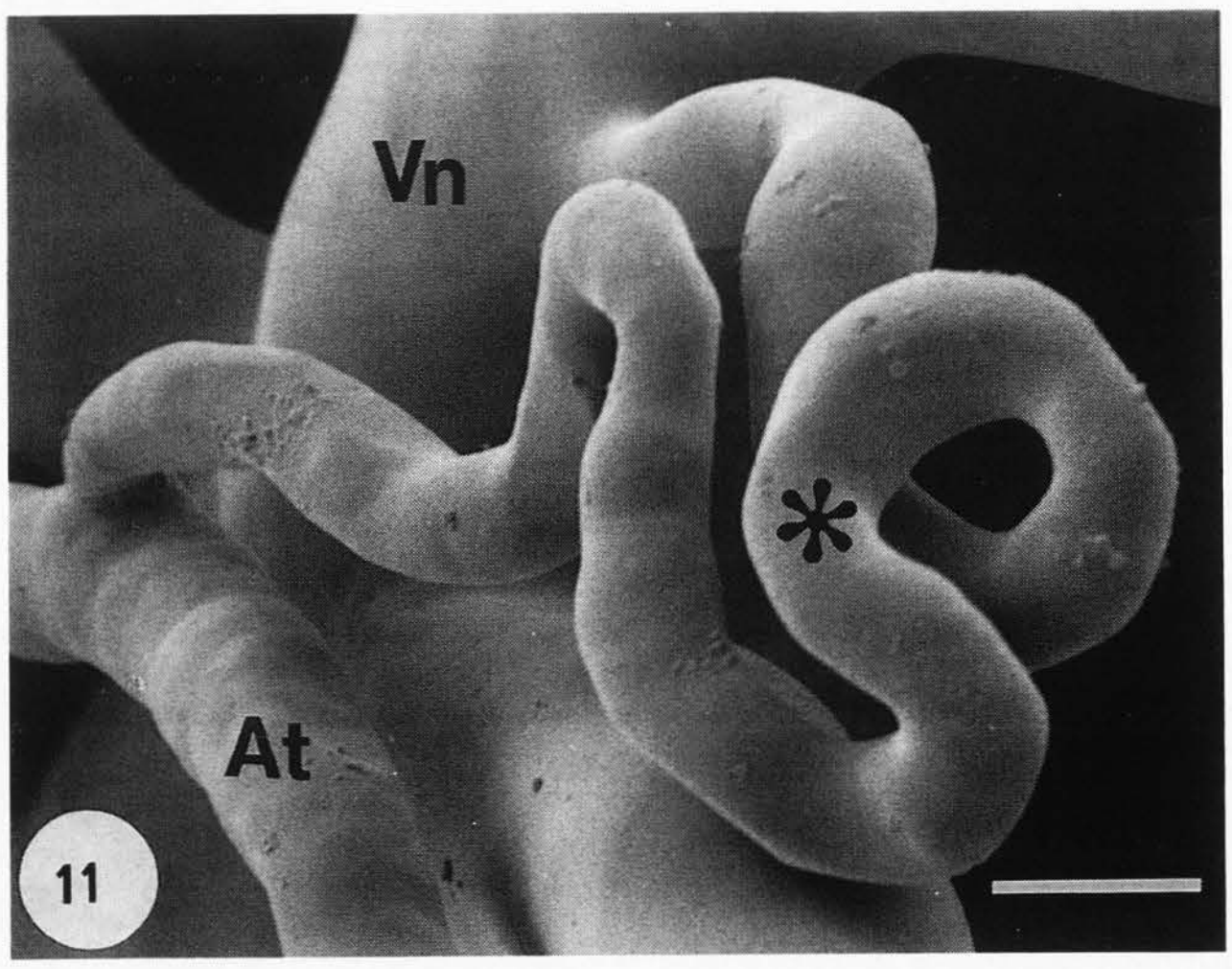
Vn
*
At
11

The teats were fixed by perfusion with a solution of phosphate buffered (pH 7.2) 4% formaldehyde and 3% PVP (polyvinyl pyrrolidon), immersed in 4% buffered formaldehyde, dehydrated in graded ethyl-alcohols, and embedded in paraffin. Finally, the samples were sectioned serially for light microscopy by routine methods and stained with hematoxylin-eosin.

Nomenclature used in descriptive anatomy conforms to Nomina Anatomica Veterinaria (NAV, 1994).

Results

The description has been based on SEM observations from lactating teats and SEM and LM observations from non-lactating teats.

The dermal vascularization of the teat was easily distinguished from the bulk of the inner vascular network in longitudinal sections of vascular corrosion casts of the whole teat (Fig. 1). The vascular network of the dermis on casts was densely-meshed, forming ridges and troughs that were deeper around the base of the teat and were supplied by a central arteriolar-venular system (Fig. 2). The dermal capillaries tended to form loops towards the surface of the skin (Fig. 2). The capillary bed of the dermis was closely related to and connected with the underlying vessels upon the tip of the teat, whereas towards the base of the teat, this connection loosened (Fig. 1).

About 30 teat ducts, most of them with their lumens almost closed, were found in the transverse histological sections of non-lactating teats (Fig. 3). Their capillary network was arranged beneath a highly corrugated epithelium (Fig. 3, Inset). The duct openings, clearly seen on the casts (Figs. 4 and 5), were unevenly distributed on the tip of the teat (Fig. 4) and were fewer (8-15) than the teat ducts. Hence, some of these openings were divided by a septum that consisted of a moderately-meshed, two-dimensional capillary network (Fig. 4, inset). The capillary network of the openings continued into the dermal capillary and arteriolar-venular system of the tip of the teat (Fig. 5). As seen better on casts of lactating teat ducts, their capillary network was densely-meshed (Figs. 5 and 7) and sometimes presented meandering capillaries and folds projecting into the duct lumen (Fig. 6). Longitudinal arteries ran along the ducts giving off arteriolar branches to the capillary network which, at numerous points, drained into venules and veins arranged parallel to the ducts (Fig. 7).

The inner vascularization showed the papillary arteries which supplying the teat, arose at the base of the teat either directly from the superficial epigastric arteries or indirectly from their branches (Fig. 8). Cutaneous branches contributed, less importantly, to the arterial supply of the teat.

The main papillary arteries (about 400-500 μm in diameter) ran internally along the teat until about a third the distance to the tip, where they curved and formed big arches (Fig. 8). These branches sent smaller secondary papillary arteries (about 200-300 μm in diameter), which undulated and sometimes looped (Fig. 8). The secondary papillary arteries were directed both, distally towards the teat tip, and backwards to the base of the teat (Fig. 8). These branches divided into smaller collateral arteries which supplied the dense capillary bed of both the dermis and the teat ducts. Many of the secondary arteries presented semi-constrictions, usually at points of looping and branching (Figs. 8 and 9a). In histological sections, constrictions were seen as wedge-shaped thickenings of the wall that protruded into the lumen of the artery (Fig. 9b). Similar constrictions were found in smaller arteries (about 50-150 μm in diameter), but they did not have the sharp bendings (Fig. 10).

Connections between small arterioles and venules were found at different points of the teat. These connections were short, spiraling or undulating, and resembled the structure of arteriovenous anastomoses (Fig. 11).

From the dermal and ductal capillary network, venules converged to larger veins that freely anastomosed and drained into veins running longitudinally to the axis of the teat (Fig. 8). These longitudinal veins (about 300-350 μm in diameter) were usually larger than the secondary papillary arteries and had bicuspid valves along their main trunk, seen both in casts (Fig. 12a) and in serial histological sections (Fig. 12b). Bicuspid valves were typically near the junction of the longitudinal veins and the collecting venous ring at the base of the teat (about 500-600 μm in diameter; Fig. 12c). From the venous ring, several branches with many valves converged to the superficial epigastric vein. Valves were also observed in venules as small as 45-60 μm in diameter. In general, veins were found more frequently than arteries.

Comparisons of lactating and non-lactating teats showed that their vascular architecture was similar but the density and size of the vessels were smaller in the non-lactating teats, except for the main vessels at the base of the teat which had a similar size (Fig. 1). The arteries of the non-lactating teats had less undulation than the lactating teats, and constrictions of their wall were less frequently found. The lumen of the teat ducts was narrow, and their capillary network was less densely-meshed and did not show meandering capillaries. The dermal capillary network was looser and flatter than in lactating teats. Finally, venous valves were scarcely found in non-lactating teats, apart from the main veins at the base of the teat.

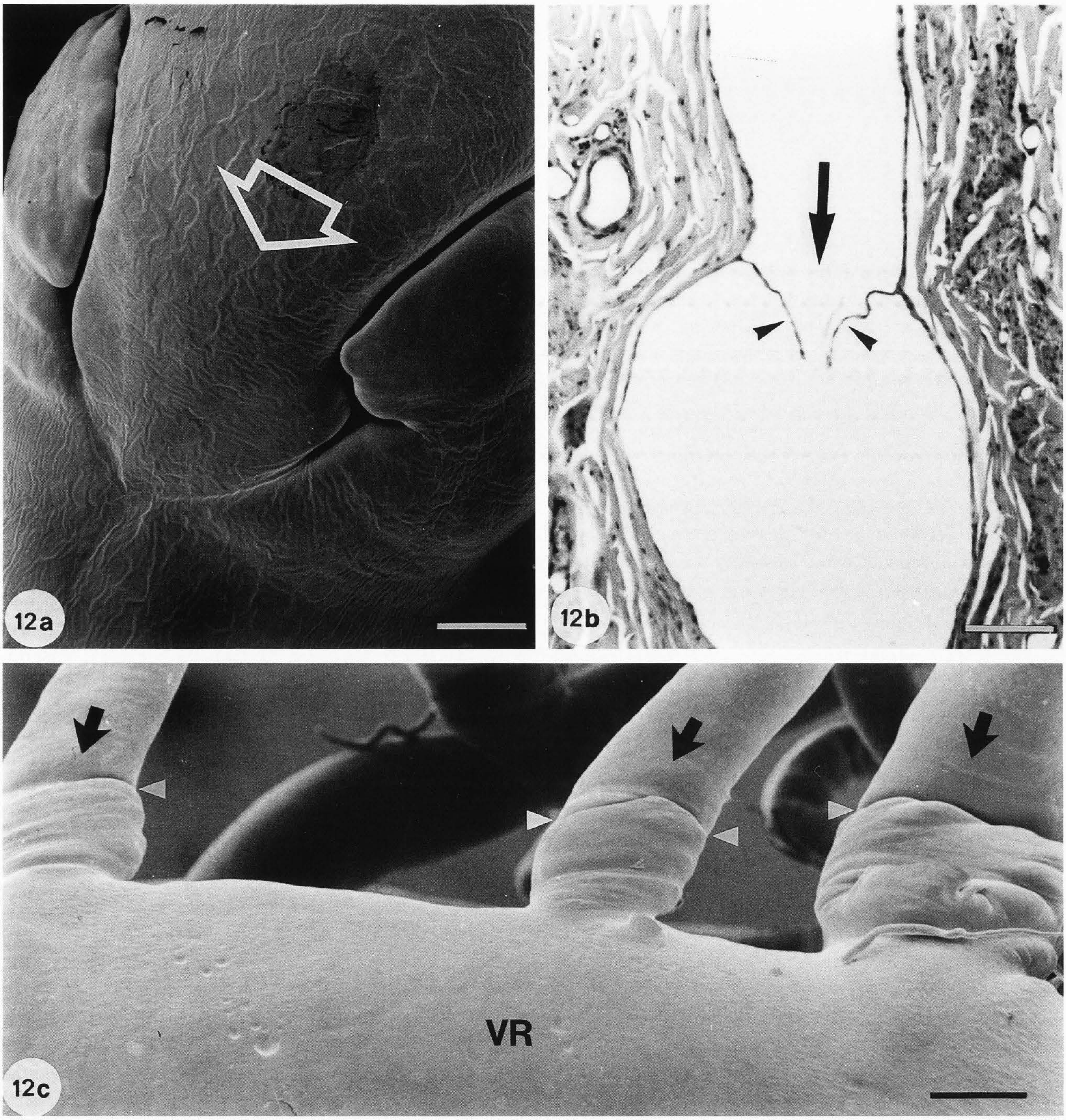

Figure 12. Vascular casts and histological section of venous valves encountered in the teat. The arrows show direction of blood flow. (**a**) Cast of a bicuspid valve in a "longitudinal" vein of a lactating teat. Bar = 47 μm. (**b**) Histological section of a bicuspid valve in a corresponding vein from a non-lactating teat. Note the valve leaflets (arrowheads) in the lumen of the vein which is dilated due to perfusion fixation. Bar = 0.1 mm. (**c**) Cast of three bicuspid valves (white arrowheads) in each longitudinal veins joining the venous ring (VR) at the base of a lactating teat. Bar = 0.2 mm.

Discussion

Vascular system of the teat ducts

The number of teat ducts on LM cross-sections of the teat was much higher than the number of teat duct openings seen on SEM samples. This indicates that several ducts join to empty into the same opening, which is supported by our observations of a vascularized septum in some openings.

The present observations of longitudinally oriented arteries and veins giving or receiving branches from the teat duct wall is similar to that in the rabbit (Wahl, 1915). However, we found that arterioles and venules did not always enter the capillary network on opposite sides of a given segment of the duct as in the rabbit. The folds of the wall in the teat ducts and meandering capillaries may reflect the possibility of increasing duct area during lactation, which is supported by the differences in luminal opening size in non-lactating and lactating animals.

At the teat openings, the capillary network of the teat ducts continued into the surrounding dermis, thus possibly being connected to and part of the vascular mechanism for teat erection.

Vascular phenomena influencing erection of the teat

The dermal capillary network of the teat is arranged in ridges and troughs reflecting deep dermal papillae as earlier described by Foust (1941) in the cow. He also found that the dermis was attached to the underlying tissue of the teat without subcutis. Our light and scanning electron microscopic observations of the connective tissue and dermal capillary network also showed them closely connected with the underlying vessels, especially seen at the tip of the teat. The lack of a subcutis layer in the teat may result in a higher pumping effect on blood flow during suckling than if a subcutis layer were present.

The existence of thick and undulating or looped secondary papillary arteries in the teat results from the amount of fibromuscular tissue around these vessels according to Moussa (1982). The structure of these secondary papillary arteries may, to some extent, favor a higher blood flow, allowing elongation of the teat and, thus, its erection.

Arteriovenous anastomoses may also participate in teat erection, being constricted during erection and otherwise relaxed if not participating in other regulatory mechanisms.

Vascular structures securing a continuous blood circulation

The vascular supply to the teat of the bitch was not limited to the branches arising from the superficial epigastric arteries as cutaneous branches also contributed in order to guarantee a continuous blood supply. The teat of the bitch had fewer arteries than veins, which is similar to other species (Linzell, 1974; Moussa, 1982; Badawi *et al.*, 1985).

The veins of the teat of the bitch tended to be larger than arteries which was also observed in different species (Nishinakagawa, 1970; Moussa, 1982). The present description of the venous drainage of the teat, including the existence of a venous ring at the base of the teat, follows the same main pattern as observed in cows (Turner, 1952; Habel, 1978; Schummer *et al.*, 1981), small ruminants (Schummer *et al.*, 1981), and buffalo (Badawi *et al.*, 1985). This architecture, as well as the many anastomoses with superficial veins, may represent alternative routes for blood drainage in order to maintain blood flow during venous compression, as for example, when the animal is lying down, a theory suggested by Schummer *et al.* (1981).

We observed arteriovenous anastomoses in the teat of the bitch as has been reported for other species (Nisbet, 1956; Linzell, 1971, 1974; Vorherr, 1974; Moussa, 1982). In the present study, they were seen between precapillary arterioles and postcapillary venules; this may be the reason for them being smaller in diameter than those of 60-100 μm diameter reported by Linzell (1974) in the teat of several other species. Arteriovenous anastomoses may participate in several regulatory mechanisms: (1) Linzell (1974) and Moussa (1982) suggested that they participate in maintaining blood flow in the teat during suckling and milking when there is a mechanical pressure on the surface of the teat, thus, regulating blood pressure and improving venous return; (2) the same authors also proposed arteriovenous anastomoses as heat regulators, since they would allow warm blood to bypass the capillary bed and enter the teat quickly to maintain its temperature above freezing point; and (3) it is suggested in the present study that they may participate in teat erection.

The blood flow to the teat may, furthermore, be regulated by the formation of constrictions in the secondary papillary arteries observed by SEM and LM in the present study. These constrictions are comparable to the polypoid or stalked structures, called valve-like arterial bolsters, found in the teat of the buffalo (Moussa, 1982). However, we observed them as wedge-shaped thickenings of the wall protruding into the arterial lumen on histological sections. This difference may be due to perfusion fixation performed in the teats of the bitch which causes vessels to appear dilated with a smooth lumen. The wedge-shaped thickenings in the arterial wall of the teat of the bitch may act as arterial bolsters and participate in blood flow regulation to the capillary network of the teat, a function also suggested for arterial bolsters in other organs (Nawar *et al.*, 1975; Taher, 1976). The preferential location of these arterial constrictions at points of looping or branching would not interfere with this function, but might avoid turbulence at those points.

In the veins of the lactating teat of the bitch, many valves were encountered. Valves have been classified as axial (placed along the main trunk of a vein) and juxtaostial (located on a small venous tributary where it joins a main trunk) (Maros, 1981). In the present study, both types of valves were observed. Axial valves were found in veins of various diameters at different levels in the teat, whereas juxtaostial valves were only located on veins draining into the venous ring at the base of the teat and on those draining into the superficial epigastric veins. These locations would contribute to maintaining blood drainage during suckling when the teat is subjected to large positive and negative pressures.

Vascular changes from non-lactating to lactating teat

The non-lactating teat showed the same main architecture as that of the lactating teat, except the number of vascular elements are less and smaller than in lactating teats, which has also been observed in teats of buffaloes (Moussa, 1982).

The increase in blood flow to the mammary gland during lactation was found to be correlated to an increase in vascularity and size of the vessels (Nishinakagawa, 1970), which is also reflected in our observations.

The differences in vasculature reflect the quiescent state of the non-lactating teat and its lower demand for blood flow regulatory elements. The undulating arteries were less frequent, as well as the occurrence of arterial constrictions or arterial bolsters, which was also noticed in the teat of the buffalo (Moussa, 1982). The lumen of the teat ducts was narrow with a looser capillary network than in lactating teat ducts, as seen in the rabbit (Wahl, 1915). The venous valves were less frequently found in non-lactating teats, reflecting a reduced blood flow in the teat during this period, as well as a non-exposure to suckling with its oscillating pressures. Such venous changes between non-lactating and lactating teats are in agreement with earlier observations of the venous system from various regions, where the number, form and location of venous valves changed with age and with alterations in hemodynamics occurring during maturation (Kampmeier and Birch, 1927; Franklin, 1937; Kugelgen and Greinemann, 1958).

It can be concluded that the vascular organization in the teat of the bitch is comparable to that of other species. It adapts to physiological changes during lactation by: (1) increasing the size of its blood vessels; (2) expanding the capillary network, and (3) further developing blood flow regulatory elements such as arterial bolsters, arteriovenous anastomoses and venous valves.

Acknowledgements

This study was supported by a grant FI (DOGC number 1854/2-4-94) from the Catalan Government. The authors wish to express their deep gratitude to Mr. Josep Maria Giné for his valuable collaboration. Thanks are also due to Mrs. Inge Bjerring, Mrs. Gunnel Holten and Mrs. Dolors Fontdevila for their helpful assistance, and to Mr. José Ygoa of the "Servei d'Idiomes" of the U.A.B for examining the English text.

References

Badawi H, Ahmed AK, Misk NA, Makady FM (1985) The arterial blood supply and venous drainage of the udder in buffaloes (*Bos bubalis* L.) Assiut Vet Med J **14**: 19-23.

Boenisch F (1913) Beitrag zur Altersbestimmung des Hundes nach den Schneidezähnen (Contribution to the age determination in dog according to the incisors). Schweiz Arch Tierheilkd **39**: 289-327.

Desjardins CM, Paape MJ, Tucker HA (1968) Contribution of pregnancy, fetuses, fetal placentas and deciduomas to mammary gland and uterine development. Endocrinology **83**: 907-910.

Evans HE (1993) The mammae. In: Miller´s Anatomy of the Dog. 3rd edn. Evans HE (ed.). W.B. Saunders Company, Philadelphia. pp. 549-555.

Foust HL (1941) The surgical anatomy of the teat of the cow. J Am Vet Med Assoc **98**: 143-150.

Franklin JF (1937) A Monograph on Veins. C.C. Thomas, Springfield, IL. pp. 64-75.

Fürstenberg MHF (1868) Die Milchdrüsen der Kuh (The Mammary Glands of the Cow). Wilhelm Engelgam, Leipzig.

Grahame RE, Bertalanffy FD (1972) Cell division in normal and neoplastic mammary gland tissue in the rat. Anat Rec **174**: 1-7.

Griffith DR, Turner CW (1961) Normal growth of rat mammary glands during pregnancy and early lactation. Proc Soc Exp Biol Med **106**: 448-450.

Habel RE (1978) Mammary gland. In: Applied Veterinary Anatomy. 2nd edn. Habel RE (ed.). Ithaca, NY. pp. 271-276.

Hanstede JG, Gerrits PO (1982) A new plastic for morphometric investigation of blood vessels, especially in large organs such as the human liver. Anat Rec **203**: 307-315.

Hollman KH (1974) Cytology and fine structure of the mammary gland. In: Lactation. A Comprehensive Treatise, Vol 2. Larson BL, Smith VR (eds.). Academic Press, New York. pp. 3-95.

Kampmeier OF, Birch CF (1927) The origin and development of venous valves with particular reference to the saphenous district. Am J Anat **38**: 451-499.

Knight CH, Peaker M (1982) Development of the mammary gland. J Reprod Fertil **65**: 521-536.

Kugelgen AV, Greinemann H (1958) Die Klappen der menschlichen Nierenvenen besonders um die Mündung der Nierenbeckenvenen (The valves of the human renal veins in particular around the openings of the renal pelvic veins). Z Zellforsch Mikr Anat **47**: 648-673.

Leiser R (1985) Fetal vasculature of the human placenta: scanning electron microscopy of microvascular casts. Contrib Gynecol Obstet **13**: 27-31.

Linzell JL (1971) Mammary blood vessels, lymphatics and nerves. In: Lactation. Falconer IR (ed.). Butterworths, London, U.K. pp. 41-50.

Linzell JL (1974) Mammary blood flow and substrate uptake. In: Lactation. A Comprehensive Treatise. Vol 1. Larson BL, Smith VR (eds.). Academic Press, New York. pp. 155-165.

Maros T (1981) Data regarding the typology and functional significance of the venous valves. Morphol Embryol **27**: 195-214.

Matsumoto M, Kuratani Y, Nishinakagawa H, Otsuka J (1988) A scanning electron microscopic observation on the mammary tissue and microvasculature of the mouse mammary gland from virgin through pregnancy, lactation and involution. Bull Fac Agr Kagoshima Univ **38**: 69-78.

Matsumoto M, Nishinakagawa H, Kurohmaru M, Hayashi Y, Otsuka J (1992) Pregnancy and lactation affect the microvasculature of the mammary gland in mice. J Vet Med Sci **54**: 937-943.

Moussa MHG (1982) Micromorphological study of the blood vessels of the teat of buffaloes in Egypt (*Bos bubalis* L.). Anat Anz **152**: 129-140.

Murad TM (1970) Ultrastructural study of rat mammary gland during pregnancy. Anat Rec **167**: 17-36.

NAV (1994) Nomina Anatomica Veterinaria. 4th edn. The World Association of Veterinary Anatomists. Zürich, Ithaca, NY.

Nawar SMA, El-Ayat MA, Ibrahim IS (1975) Some anatomical and histological studies on the arterial supply of the nasal cavity of the buffalo in Egypt (*Bos bubalis* L.). Anat Anz **138**: 203-221.

Nisbet AM (1956) Arterio-venous anastomoses in the teat of a cow. Nature **178**: 1477.

Nishinakagawa H (1970) Anatomical studies on the vascular system of the mammary glands of the mammals. Bull Fac Agr Kagoshima Univ **20**: 1-55.

Riederer TH (1903) Über den Bau der papilla mammae des Rindes (On the structure of the bovine papilla mammae). Schweiz Arch Tierh **29**: 593-625.

Rubeli O (1916) Über einige anatomische Verhältnisse des Rindseuters und deren Bedeutung für die Physiologie und Pathologie (On some anatomical relationships of the cow's udder and their physiological and pathological significance). Schweiz Arch Tierheilkd **58**: 357-369.

Schummer A, Wilkens H, Vollmerhaus B (1981) Skin and cutaneous organs. In: The Anatomy of the Domestic Animals. Vol. 3. Nickel R, Schummer A, Seiferle E (eds.). Verlag Paul Parey, Berlin, Germany. pp. 491-492, 514-524.

Silver IA (1966) The anatomy of the mammary gland of the dog and cat. J Small Anim Pract **7**: 689-696.

Soemarwoto IN, Bern HA (1958) The effect of hormones on the vascular pattern of the mouse mammary gland. Am J Anat **103**: 403-435.

Taher El-S (1976) Micromorphological studies of the vasculature of the nasal septum of the albino rat. Acta Anat (Basel) **96**: 366-385.

Tedman RA, Bryden MM (1981) The mammary gland of the Weddell Seal, Leptonychotes weddelli (Pinnipedia). I. Gross and microscopic anatomy. Anat Rec **199**: 519-529.

Turner CW (1939) The Comparative Anatomy of the Mammary Glands. Doctoral thesis. University of Missouri, Columbia, MO.

Turner CW (1952) The Mammary Gland, Vol. 1. The Anatomy of the Udder of Cattle and Domestic Animals. Lucas Brothers Publishers. Columbia, MO, pp. 54-55, 63-64.

Vorherr H (1974) Development of the female breast. Morphology of the mature female breast. In: The Breast: Morphology, Physiology, and Lactation. Academic Press, New York. pp 1-19, 20-70.

Wahl HM (1915) Development of the blood vessels of the mammary gland in the rabbit. Am J Anat **18**: 515-524.

Discussion with Reviewers

Y. Ohta: Why are there many venous valves? Usually, venous valves are not found in such thin (45-60 μm) venous vessels.

Authors: The existence of many valves in the veins of the teat is probably due to the large suction pressures that are applied to the teats during suckling. Although valves were encountered in veins of any size, the number of valves found in small venules (45-60 μm) was much lower than that found in large veins.

Y. Ohta: Is "septum" composed of a connective tissue or is it really in the proper layer of the stratified squamous epithelium?

Authors: Histologically, septa of the teat duct openings consist of stratified squamous epithelium and a lamina propia where the vessels seen in the casts are located.

Y. Ohta: How do you think that these peculiar constrictions, existing on one side of the arteriolar wall, are built? By lactating?

Authors: Constrictions of secondary papillary arteries could be found in both lactating and non-lactating teats, although they were less numerous in the latter. In **Discussion**, we compare these structures with the valve-like arterial bolsters described by Moussa (1982) in the teat of the buffalo and suggest that their function may be to participate in blood flow regulation to the capillary network of the teat. On the other hand, these constrictions located at points of looping and branching would help to maintain the configuration of these arteries under high pressure conditions by two possible mechanisms: (1) they may represent a reinforcement of the arterial walls and, (2) they decrease the arterial diameter that, according to Bernouilli's law, increases the velocity and diminishes the pressure of the circulating blood at those points.

A. Lametschwandtner: In **Discussion**, you suggest that the perfusion fixation you have used may have led to dilated vessels and to smoothen vessel lumina. Could you give some data on volume, flow rate, and pressure of rinsing solution, fixative and resin used?

Authors: The volume of both rinsing solution and fixative used in each injection was of approximately 100-150 ml, depending on the size of the bitch. Perfusion of these solutions was performed manually until the color of the skin switched to white due to rinsing out of the blood. This was more evident in animals with light skin. The volume of the mixture of resin was of 10-30 ml, depending on the size and lactational state of the bitch. The resin was injected by means of a syringe infusion pump (Harvard apparatus) and the flow was kept at 2 ml per minute.

A. Lametschwandtner: In the text, you point out that in the teats of the lactating bitch, beside changes in the vessel diameters and the development of blood flow regulating elements (arterial bolsters, arteriovenous anastomoses, venous valves), an increase of the capillary network is also found. This increase obviously is due to angiogenesis. Could you find signs in the vascular casts indicating this process? If so, what kind of angiogenesis is prevailing (sprouting, non-sprouting angiogenesis)?

Authors: Two different angiogenic structures could be mainly found in lactating teats at both the dermal and ductal capillary levels, thus, capillary sprouts and angiogenic holes. Capillary sprouts have been previously described in vascular casts of mammary glands of mice (Matsumoto *et al.*, 1988, 1992). On the other hand, angiogenic holes represent a model of intussusceptive microvascular growth which involves expansion of the capillary network by insertion of slender trans-capillary tissue pillars (Caduff *et al.*, 1986; Burri and Tarek, 1990; Patan *et al.*, 1992, 1993). No data could be found on angiogenic holes in vascular casts of mammary glands. However, Patan *et al.* (1992) described angiogenic holes in the capillary network of the ducts in casts of a glandular structure, the submandibular gland in rats.

M. Nishinakagawa and M. Matsumoto: How old was the non-lactating bitch from which sample were obtained for LM?

Authors: Legal identification of this bitch was not available when we collected the samples. However, using Boenisch's table (1913), we estimate that it was an old bitch (age ranging 8-10 years).

M. Nishinakagawa and M. Matsumoto: Why was only a non-lactating bitch used for LM?

Authors: The total number of teats used for SEM of vascular casts was eleven (obtained from five lactating and two non-lactating bitches) and that of teats used for LM was three (obtained from one animal). The present work was mainly focused on the morphology of the casts of lactating and non-lactating teats in the bitch. Therefore, histology was used only as a complementary method in order to support some of the results found in our vascular corrosion casts.

M. Nishinakagawa and M. Matsumoto: What method did you use for the measurement of vascular diameters?

Authors: Measurements were made directly on the micrographs by means of a measuring magnifier, x10 (Peak). This is an approximate method to measure vascular diameters which was simply used to categorize the vessels of the teat.

M. Nishinakagawa and M. Matsumoto: The inset of Figure 3 showed a highly corrugated epithelium of a non-lactating teat. Did you observe folds projecting into the duct lumen in lactating teats?

Authors: Yes, we observed folds of the teat duct projecting into the lumen in vascular casts of lactating teats as shown in Figure 6.

G.J. Burton: You do not make any statement regarding the parity of the animals you studied. Do you think you would observe differences between nulliparous and multiparous females?

Authors: Yes, although we did not consider these conditions, other authors have extensively studied the variations in the vascularization of the mouse mammary gland from virgin through pregnancy, lactation and postweaning (Soemarwoto and Bern, 1958; Iwamatsu *et al.*, 1988; Matsumoto *et al.*, 1988, 1992). Soemarwoto and Bern (1958) studied the vascular pattern of the mouse mammary gland and stated that regression of the vascularity could be observed after weaning although the vascular system returned to a condition intermediate between that of virgin and of early pregnant females. This was supported by the findings of Iwamatsu *et al.* (1988), who measured the size of the large veins draining the mouse mammary glands. Finally, from an ultrastructural point of view, Matsumoto *et al.* (1988) measured the changes in density of pinocytic vesicles and in number and length of microvillous processes of endothelial cells in the mouse mammary gland. They found that all of these characteristics decreased after weaning, although did not reach the same situation than in the virgin period.

G.J. Burton: Equally, are there differences between pre-pubertal and post-pubertal females?

Authors: We did not study these conditions. However, Soemarwoto and Bern (1958) and Moussa (1982) found no significant changes in the vascularity of, respectively, the mammary gland of the mouse and the teat of the buffalo throughout both the pre-pubertal and the post-pubertal periods, except for a gradual increase in their vasculature. This increase in richness of the vascularity of the mammary gland and teat may be related to the age according to Moussa (1982). On the other hand, it is well known that during the oestrus (post-pubertal period) changes in the vasculature take place in the mammary gland. For instance, the blood flow to the gland increases in the luteal phase (Vorherr, 1974).

G.J. Burton: Do you think, from their morphology, that the venous valves ever become incompetent due to engorgement during lactation?

Authors: Linzell and Mount (1955) and Linzell (1960) demonstrated that during pregnancy and lactation valves of the mammary veins in ruminants became incompetent, and that this fact implied a variation in blood flow direction. However, Linzell (1960) also examined pigs and horses and could not notice valvular incompetence. No data could be found on valvular competence/incompetence in the mammary gland of the bitch. We think that it is difficult to determine if venous valves ever become incompetent in the teat of the bitch due to engorgement during lactation only from a morphological point of view. Further studies on the venous flow in the mammary gland of the bitch during lactation have to be done in order to increase our knowledge on this subject.

Additional References

Burri PH, Tarek MR (1990) A novel mechanism of capillary growth in the rat pulmonary microcirculation. Anat Rec **228**: 35-45.

Caduff JH, Fischer LC, Burri PH (1986) Scanning electron microscope study of the developing microvasculature in the postnatal rat lung. Anat Rec **216**: 154-164.

Iwamatsu S, Nishinakagawa H, Otsuka J (1988) Changes of venous size in mouse mammary glands from virgin through pregnancy, lactation, and post-weaning. Jpn J Vet Sci **50**: 1262-1263.

Linzell JL, Mount LE (1955) Variations in the direction of venous blood-flow in the mammary region of the sheep and goat. Nature **176**: 37-38.

Linzell JL (1960) Valvular incompetence in the venous drainage of the udder. J Physiol **153**: 481-491.

Patan S, Alvarez MJ, Schittny JC, Burri PH (1992) Intussusceptive microvascular growth: a common alternative to capillary sprouting. Arch Histol Cytol **55** Suppl: 65-75.

Patan S, Haenni B, Burri PH (1993) Evidence for intussusceptive capillary growth in the chicken chorioallantoic membrane (CAM). Anat Embryol **187**: 121-130.