

CASE REPORT

Rapid identification of *Nocardia cyriacigeorgica* from a brain abscess patient using MALDI-TOF-MS

Mohammed AlMogbel¹, Mohammed AlBolbol², Noura Elkhizzi³, Hisham AlAjlan³, John Philip Hays⁴ and Mushtaq Ahmad Khan^{5,*},†

¹Molecular Diagnostic and Personalized Therapeutics unit, College of Applied Medical Sciences, University of Ha'il, Ha'il, Kingdom of Saudi Arabia, ²Department of Neurosurgery, Prince Sultan Military Medical City, Riyadh, Kingdom of Saudi Arabia, ³Medical Microbiology Division, Central Military Laboratory and Blood Bank, Prince Sultan Military Medical City, Riyadh, Kingdom of Saudi Arabia, ⁴Department of Medical Microbiology and Infectious Diseases, Erasmus University Medical Centre Rotterdam (Erasmus MC), Rotterdam, the Netherlands, ⁵Department of Medical Microbiology and Immunology, College of Medicine and Health Sciences, United Arab Emirates University, Al Ain, United Arab Emirates

*Correspondence address. Department of Medical Microbiology and Immunology, College of Medicine and Health Sciences, United Arab Emirates University, Al Ain, United Arab Emirates. Tel: +971-3 7137180; E-mail: mushtaq.khan@uaeu.ac.ae

Abstract

Nocardia cyriacigeorgica (*N. cyriacigeorgica*) is most frequently associated with human infections, including chronic bronchitis, pulmonary disease and brain abscesses. In general, *N. cyriacigeorgica* causes infections in immunocompromised individuals and has been reported in clinical samples worldwide. However, the isolation and speciation of *N. cyriacigeorgica* in the routine diagnostic microbiology laboratory are complicated and time consuming. Recent mass spectrometry techniques such as matrix-assisted laser desorption/ionization time-of-flight-mass spectrometry (MALDI-TOF-MS) have been successfully integrated into many routine diagnostic microbiology laboratories, allowing for the rapid, accurate and simple identification and speciation of many different microorganisms, including difficult-to-identify bacterial species. Here, we present a case report of a 65-year-old female patient from the neurology ward of Prince Sultan Military Medical City in Riyadh, Saudi Arabia, who was infected with *N. cyriacigeorgica*. The bacterium was successfully identified by MALDI-TOF-MS, with species identification subsequently confirmed by sequence analysis of the 16S ribosomal RNA.

INTRODUCTION

In humans, *Nocardia* spp. predominantly causes pulmonary nocardiosis [1]. However, *Nocardia* species are also capable of disseminating from the primary site of infection, such as the lungs, to other organs, including the central nervous system. As such, *Nocardia* are capable of generating disease at different body sites, including abscesses in the brain [2]. Although *Nocardia* infections are primarily seen in patients with immunodeficiency, AIDS,

cancer and diabetes [3], cases have been reported in individuals with fully functioning immune systems [4].

Among the *Nocardia* species, *Nocardia cyriacigeorgica* (*N. cyriacigeorgica*) is an emerging pathogen that appears to be adapting from environmental to human host [5]. The bacterium is primarily found in soil, but can also live in stagnant water and enter the human body through dust respiration and traumatic inoculation. Unfortunately however, the microbiological

†Mushtaq Ahmad Khan, <http://orcid.org/0000-0002-2434-1411>

Received: June 11, 2020; Revised: August 10, 2020; Accepted: August 18, 2020

© The Author(s) 2020. Published by Oxford University Press. All rights reserved. For Permissions, please email: journals.permissions@oup.com

This is an Open Access article distributed under the terms of the Creative Commons Attribution Non-Commercial License (<http://creativecommons.org/licenses/by-nc/4.0/>), which permits non-commercial re-use, distribution, and reproduction in any medium, provided the original work is properly cited. For commercial re-use, please contact journals.permissions@oup.com

isolation and identification of *Nocardia* species from clinical samples within typical hospital laboratories is difficult and time consuming when using conventional diagnostic methods [6]. One potential candidate method that allows for rapid and accurate

identification of bacterial species is matrix-assisted laser desorption/ionization time-of-flight (MALDI-TOF). In this case report, we describe the use of MALDI-TOF for identifying the bacterial species *N. cyriacigeorgica*, isolated from a brain abscess. Species confirmation was obtained via subsequent 16S ribosomal RNA (16S rRNA) gene sequencing.

CASE REPORT

A 65-year-old female was admitted to the emergency department of Prince Sultan Military Medical City in Riyadh, Saudi Arabia, complaining of headache, vomiting, dysarthria and right-sided weakness. She had end-stage renal disease, relied on hemodialysis, and suffered from ischemic heart disease, idiopathic thrombocytopenia and hypothyroidism. The patient subsequently underwent a magnetic resonance imaging (MRI) scan, which showed a left-sided parietal lesion measuring 5 cm × 4.5 cm × 5 cm, with a midline shift (Fig. 1). The patient was immediately admitted to the hospital, and surgery was performed to aspirate material from the brain abscess. Gram staining and acid fast staining of the brain abscess aspirate did not show any bacteria, however, several white blood cells were observed. The aspirate was grown on enrichment medium (RCM) and also on solid media (nutrient agar) and after 72 hours, bacterial growth was found on both media. Conventional methods using biochemical testing and Gram-staining failed to identify the bacterium present within the bacterial colonies, therefore samples were prepared for MALDI-TOF (Bruker MALDI Biotyper System) analysis. MALDI-TOF identified the abscess bacterium as *N. cyriacigeorgica*, with a score value of 2.11, indicating a 'High Confidence Identification' of the bacterial species [7]. Species identification was subsequently confirmed by sequencing of the 16S rRNA gene of the bacterial isolate by an external reference laboratory (Mayo Clinic, AZ, USA). Antibiotic susceptibility testing—using disc diffusion and E-testing according to CLSI guidelines—showed that the isolated *N. cyriacigeorgica* species was resistant to penicillin, teicoplanin and vancomycin (intermediate), but susceptible to cotrimoxazole, imipenem, fucidin and ceftriaxone [8]. The patient received empirical antibiotic treatment with vancomycin and ceftriaxone for 3 weeks. After 3 weeks, a follow-up MRI showed the remaining presence of the lesion, which was excised by craniotomy. An MRI taken following surgery showed no abscess. Postoperatively the patient was found to be well and discharged.

DISCUSSION

Nocardia species are Gram-positive, aerobic, branching and filamentous bacteria belonging to the actinomycetes group of bacteria, which are ubiquitously found in soil and water. However, infections due to *Nocardia* are difficult and cumbersome to diagnose because they lack specific clinical signs and do not exhibit pathognomonic features [3]. In addition, the bacteria do not grow efficiently in culture media, leading to slow or sometimes no growth, which may specifically be because of the presence of other commensals. Because of these issues, the identification of *Nocardia* at the species level in the

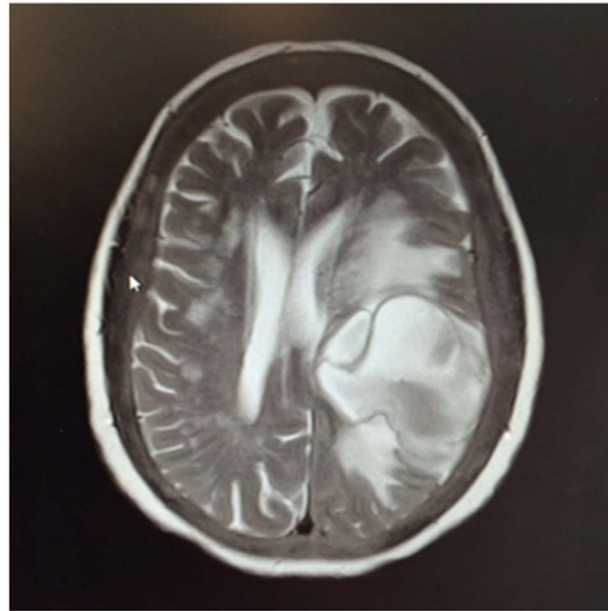


Figure 1: MRI showing a left parietal lesion measuring 5 cm × 4.5 cm × 5 cm, with a midline shift.

routine diagnostic microbiology laboratory is very time consuming, and accurate species identification is often not possible using conventional techniques. Currently, the species identification of *Nocardia* is based on gene sequencing, specifically sequencing of the 16S rRNA gene, which has become the 'gold standard' [9]. The use of genetic-based species identification methods such as 16S rRNA gene sequencing plays a vital role in *Nocardia* species determination. Accordingly, these techniques aid epidemiological investigations and provide a better understanding of the management and treatment of nocardiosis infections because different *Nocardia* species may exhibit different antimicrobial susceptibility patterns [8]. However, genetic-based methods of identification are time consuming and not always available in smaller diagnostic microbiology laboratories; thus, accurate and rapid identification techniques such as MALDI-TOF are showing their value in the current diagnostic clinical microbiology laboratory. For example, in this case report, initial pathogen identification was achieved using MALDI-TOF, which has the potential to rapidly and accurately identify *Nocardia* species in clinical samples [7]. However, given the rarity of nocardial brain abscesses, the confirmation of the genus/species identification using methods such as 16S rRNA gene sequencing is still recommended.

The prolonged use of corticosteroids, organ transplantation, the presence of cancer and human immunodeficiency virus infection are considered to be the most common predisposing factors for nocardial infections (nocardiosis) [2]. When nocardial infection occurs, species such as *N. farcinica*, *N. paucivorans*, *N. asteroides*, *N. arthritidis* and *N. cerradoensis* have been reported. Among the *Nocardia* group, *N. cyriacigeorgica* is one of the most often implicated species in human nocardiosis, including septicemia, endophthalmitis, after liver transplantation, as secondary infections in patients with cancer, in pulmonary infections, cellulitis, spinal abscess, empyema and brain abscess [10].

In conclusion, brain abscesses associated with *Nocardia* species are rare and this is the first case report of the identification of *N. cyriacigeorgica* isolated from a cerebral abscess in Saudi Arabia. The success of MALDI-TOF in the identification and speciation of difficult to identify bacterial isolates such

as *N. cyriacigeorgica* will help clinicians make effective clinical decisions, particularly in the treatment of life-threatening critical infections such as brain abscesses.

ETHICAL APPROVAL

None required.

CONSENT

None required as patient deceased.

GUARANTOR

Mohammad AlMogbel.

ACKNOWLEDGMENT

None. No funding was received for this article.

CONFLICT OF INTEREST STATEMENT

None declared.

REFERENCES

1. Manoharan H, Selvarajan S, Sridharan KS, Sekar U. Pulmonary infections caused by emerging pathogenic species of *Nocardia*. *Case Rep Infect Dis* 2019;2019:5184386. doi: <https://doi.org/10.1155/2019/5184386>.
2. Aliaga L, Fatoul G, Guirao E, Peña A, Rodríguez-Granger J, Cobo F. *Nocardia paucivorans* brain abscess. Clinical and microbiological characteristics. *ID Cases* 2018;3:e00422. doi: [10.1016/j.idcr.2018.e00422](https://doi.org/10.1016/j.idcr.2018.e00422).
3. Barnaud G, Deschamps C, Manceron V, Mortier E, Laurent F, Bert F et al. Brain abscess caused by *Nocardia cyriacigeorgica* in a patient with human immunodeficiency virus infection. *J Clin Microbiol* 2005;43:4895–7. doi: [10.1128/JCM.43.9.4895-4897.2005](https://doi.org/10.1128/JCM.43.9.4895-4897.2005).
4. Riviere F, Billhot M, Soler C, Vaylet F, Margery J. Pulmonary nocardiosis in immunocompetent patients: can COPD be the only risk factor? *Eur Respir Rev* 2011;20:210–2. doi: [10.1183/09059180.00002211](https://doi.org/10.1183/09059180.00002211).
5. Zoropogui A, Pujic P, Normand P, Barbe V, Belli P, Graindorge A et al. The *Nocardia cyriacigeorgica* GUH-2 genome shows ongoing adaptation of an environmental Actinobacteria to a pathogen's lifestyle. *BMC Genomics* 2013;14:286. doi: <https://doi.org/10.1186/1471-2164-14-286>.
6. Mehta HH, Shamoo Y. Pathogenic *Nocardia*: a diverse genus of emerging pathogens or just poorly recognized? *PLoS Pathog* 2020;16:e1008280. doi: <https://doi.org/10.1371/journal.ppat.1008280>.
7. MALDI Biotyper CA System - Online Brochure. Bruker. https://www.bruker.com/fileadmin/user_upload/8-PDF-Docs/Separations_MassSpectrometry/Literature/Brochures/1857366_MALDI_Biotyper_CA_brochure_01-2018_ebook.pdf. (9 August 2020, date last accessed).
8. Larruskain J, Idigoras P, Marimón JM, Pérez-Trallero E. Susceptibility of 186 *Nocardia* sp. isolates to 20 antimicrobial agents. *Antimicrob Agents Chemother* 2011;55:2995–8. doi: [10.1128/AAC.01279-10](https://doi.org/10.1128/AAC.01279-10).
9. Conville PS, Brown-Elliott BA, Smith T, Zelazny AM. The complexities of *Nocardia* taxonomy and identification. *J Clin Microbiol* 2018;56:e01419–7. doi: [10.1128/JCM.01419-17](https://doi.org/10.1128/JCM.01419-17).
10. Khorshidi M, Navid S, Azadi D, Shokri D, Shojaei H. A case report of brain abscess caused by *Nocardia cyriacigeorgica* in a diabetic patient. *JMM Case Rep* 2018;5:e005133. doi: [10.1099/jmmcr.0.005133](https://doi.org/10.1099/jmmcr.0.005133).