

EXPERIMENTAL INFECTION OF PREGNANT PYRENEAN CHAMOIS (*RUPICAPRA PYRENAICA*) WITH BORDER DISEASE VIRUS SUBTYPE 4

Claire Martin,¹ Véronique Duquesne,¹ Jean-Michel Guibert,¹ Coralie Pulido,¹ Emmanuelle Gilot-Fromont,^{2,3} Philippe Gibert,⁴ Roser Velarde,⁵ Richard Thiéry,¹ Ignasi Marco,⁵ and Eric Dubois^{1,6}

¹ ANSES, Laboratoire de Sophia-Antipolis, Unité Pathologie des Ruminants, 105 Route des Chappes B.P.111, 06902 Sophia-Antipolis Cedex, France

² Université de Lyon, VetAgro Sup Campus Vétérinaire, MIPIE, Santé Publique Vétérinaire, 1 Avenue Bourgelat, F-69280 Marcy-l'Etoile, France

³ Université de Lyon, Université Lyon 1, UMR 5558 Laboratoire de Biométrie et Biologie Evolutive, Bâtiment Mendel, 43 Bd du 11 Novembre 1918, 69622 Villeurbanne cedex, France

⁴ Office National de la Chasse et de la Faune Sauvage, Unité Sanitaire de la Faune, Rue de la Champagne, 73250 Saint-Pierre-d'Albigny, France

⁵ Servei d'Ecopatologia de Fauna Salvatge, Facultat de Veterinària, Campus de la Universitat Autònoma de Barcelona, Bellaterra, Barcelona, Spain

⁶ Corresponding author (email: eric.dubois@ANSES.fr)

ABSTRACT: Border disease virus (BDV) causes high mortality in Pyrenean chamois (*Rupicapra pyrenaica*) on the French and Spanish sides of the Pyrenees Mountains. We investigated the pathology induced by BDV in pregnant chamois via experimental infection. Three females were inoculated during the second third of pregnancy with a BDV-4 subgroup strain isolated from a wild Pyrenean chamois during an acute epizootic. A fourth pregnant chamois and one nonpregnant ewe were kept as negative controls. Animals were monitored to assess clinical signs, hematology, viremia, and serology. Postmortem examinations included necropsy, histopathology, and quantification of viral RNA in organs. Pregnancy was unsuccessful in all inoculated animals. One died 24 days postinoculation (dpi) without showing any precursory clinical signs. The second animal had profuse diarrhea from 13 dpi to its death at 51 dpi. The third aborted at 46 dpi and was euthanized at 51 dpi. All animals were viremic from 4 dpi until death. Neutralizing antibodies against BDV-4 were detected from 12 dpi. Necropsies showed generalized lymphadenomegaly, associated in one case with disseminated petechial hemorrhages in the digestive tract. Seventy-eight of 79 organs from inoculated adults and their fetuses had detectable viral RNA. The main histologic lesions in adults were mild lymphohistiocytic encephalitis associated with moderate or moderately severe lymphoid depletion. Control animals remained negative for virus (in blood and organs), antibody, and lesions upon postmortem examination. BDV infection during pregnancy in Pyrenean chamois causes severe disease leading to abortion, then death. Despite 100% fetal death following inoculation, viral RNA was recovered from all organs of infected fetuses, suggesting that persistently infected offspring could be born. Our results may help explain the reported decrease in chamois populations in several areas and suggest that great care must be taken when interpreting infection status for wildlife.

Key words: Border disease virus, experimental infection, pathogenicity, pestivirus, pregnancy, Pyrenean chamois, *Rupicapra pyrenaica*.

INTRODUCTION

Pestiviruses (family *Flaviviridae*) are single-stranded RNA viruses classified into four species by the International Committee on Taxonomy of Viruses. Bovine viral diarrhea virus type 1 (BVDV-1) and BVDV-2 mainly affect bovines; border disease virus (BDV) is commonly isolated from sheep and classical swine fever virus (CSFV) from pigs. Eleven subgroups or subspecies have been

described for the BVDV-1 (Vilček et al., 2001), two subgroups for BVDV-2 (Vilček et al., 2005), and at least seven subgroups for BDV (Giammarioli et al., 2011). In Europe, BDV-1 was isolated from sheep in the UK (Vilček et al., 1997), BDV-2 in Germany (Becher et al., 2003), BDV-3 in Switzerland (Stalder et al., 2005) and Austria (Krametter-Froetscher et al., 2007), BDV-4 in Spain (Arnal et al., 2004; Valdazo-Gonzalez et al., 2007), and BDV-5, BDV-6, and BDV-Tunisian in

France (Dubois et al., 2008). Three distinct genotypes, isolated from a giraffe (giraffe-1 strain), a deer (reindeer-1 strain) (Avalos-Ramirez et al., 2001; Becher et al., 2003), and from fetal calf serum (Hobi strain; Schirrmeier et al., 2004), have been proposed as novel pestivirus species. Pestivirus infections have been found in many wild ungulate species (Vilček and Nettleton, 2006) and cross-infection between species has been widely described (Passler et al., 2009). In domestic flocks, the main clinical signs associated with border disease are reproductive failure including abortion, stillbirth, and lower fertility. The immunosuppressive effects of infection increase the severity of opportunistic infections. The birth of persistently infected (PI) animals is an important consideration in infection epidemiology (Letellier and Kerkhofs, 2003). In wild ruminants, pestivirus pathology is poorly known. Experimental infection with BVDV has been carried out in white-tailed deer (*Odocoileus virginianus*; Passler et al., 2007; Ridpath et al., 2007; Duncan et al., 2008; Raizman et al., 2009), elk (*Cervus elaphus*; Tessaro et al., 1999), and mule deer (*Odocoileus hemionus*; Van Campen et al., 1997). In most of these studies, no clinical signs were reported while abortion, fever, and lymphocyte depletion were described in others (Duncan et al., 2008; Raizman et al., 2009).

Pestivirus infection in Pyrenean chamois (*Rupicapra pyrenaica*) has been described in Spain (Marco et al., 2007, 2009) and France (Pioz et al., 2007). In France, the virus (classified BDV-4) seems to have become endemic at least as early as 1995 (Pioz et al., 2007). In Spain, outbreaks were associated with high mortality (42–86%) and clinical signs such as behavioral changes and alopecia with skin hyperpigmentation. Histologic changes were found in the brain with mainly edema, gliosis, spongiosis, and neuronal multifocal necrosis. Moderate hyperplasia with orthokeratotic hyperkeratosis was also observed in skin (Marco et al., 2007). The strains

isolated during these outbreaks were BDV-4 (Arnal et al., 2004; Frölich et al., 2005). A retrospective study of archived sera and spleen showed that the populations studied had been infected by BDV-4 strains at least as early as 1990. The emergence of border disease in 2001 may, thus, be due to other factors such as viral mutation (Marco et al., 2011). Experimental infections with BDV-4 from chamois (CADI-6 strain) have already been carried out in sheep (Cabezón et al., 2010c) and pigs (Cabezón et al., 2010a). Although these species developed brief viremia and seroconversion within 15 days postinoculation (dpi), no clinical signs were observed. To understand the infection and pathogenicity in chamois, it was thus important to perform an experimental infection in the target species and to assess its consequences on pregnancy. We investigated 1) the pathology of a BDV-4 strain isolated from a naturally infected Pyrenean chamois during an acute epizootic, and 2) the consequences of infection on pregnancy (whether fetuses may be persistently infected) in semidomesticated Pyrenean chamois.

MATERIALS AND METHODS

Animals

Four Pyrenean chamois were obtained from a game park in the French Pyrenees Mountains (43°00'N, 0°06'W). While animals were under sedation with 0.2 mg/kg of xylazine, pregnancy was confirmed by transabdominal ultrasound. All animals were apparently healthy, presenting no signs of cough or apparent health disorders. They were also negative for BDV and BVDV, both by antigen and antibody detection tests (ELISA BVD Ag Mix®, Pourquier, Eragny, France; and ELISA BVD/MD/BD P80®, Pourquier, respectively). Ages ranged from 4–14 yr. Chamois were transferred to the experimental station (ANSES Sophia-Antipolis laboratory) in level-2 confinement facilities under negative pressure. Animals were acclimatized for 10 days and randomly separated into two groups. Three individuals were assigned to the inoculated group (chamois A, B, and C), and the last one (chamois D) was placed with a ewe to form the control group. The ewe

originated from a specific-pathogen-free herd (pre-Alp breed).

Cells and virus

The CADI-6 viral strain (GenBank accession number AM905923) was isolated from a Pyrenean chamois (Marco et al., 2009). Three virus subcultures were produced to obtain inocula. The final viral suspension was titrated before inoculation, and ETM52 cells were grown in minimum essential medium (MEM-Gibco®, Invitrogen, Carlsbad, California, USA) as described by Thabti et al. (2002) and used for both virus production and virus neutralization (VN) tests. Fetal calf serum used for cell cultures was confirmed to be free of pestivirus.

Experimental design

Animals were inoculated under sedation by intratracheal injection (Thabti et al., 2002) of 5 ml of cell culture medium containing 1.0×10^6 50% tissue culture infectious doses (TCID₅₀) per milliliter of the CADI-6 strain. They were inoculated during the second third of gestation, as estimated by ultrasound.

Clinical monitoring was realized daily by visual inspection and recorded throughout the experiment. To standardize clinical monitoring, we used a clinical score taking into account the presence or absence of clinical signs specific to pestivirus infection (Table 1). Assessments consistent with good health were assigned a score of 0 and abnormalities a score of 1. A score of 10 was attributed to death. Some procedures, including temperature and weight measurements, were excluded to avoid excessive stress. Euthanization criteria were the occurrence of hemorrhagic diarrhea for more than 24 hr, signs of apathy or prostration, or signs of suffering such as groans. All surviving animals were euthanized at the end of the experiment period.

Sample collection

Samples of blood and swabs were performed 10 and 5 days before inoculation, on the day of inoculation (day 0), and on days 1, 2, 4, 6, 8, 10, 12, 14, 17, 21, 28, 35, 42, and 49 postinoculation. Blood samples were taken from the jugular vein and collected in silicone-coated and spray-coated Vacutainer K₂EDTA® (potassium ethylene diamine tetraacetic acid) blood sampling tubes (BD, Franklin Lakes, New Jersey, USA). For each blood sample, a complete hemogram was performed manually (Veterinary Diagnostic Laboratory, Sophia-Antipolis, France). To consider individual

variations, values obtained for each hematologic parameter during the acclimatization period were normalized to 100 (Martinelle et al., 2011). Nasal, rectal, vaginal, and oral swabs were taken using sterile swabsticks (single plastic swab, Copan, Brescia, Italy). Swabs were resuspended in 1 ml of sterile phosphate buffered saline (PBS) and frozen at -80 C until use. Samples of nine organs (brain, cotyledon, kidney, liver, lung, mesenteric node, myocardium, skin, and spleen) were collected from animals that died or were euthanized (adults and fetuses when available) and frozen until use.

Viral RNA extraction

Total RNA was extracted from 100 μ l of whole EDTA blood and from 100 μ l of PBS (for swab) using the NucleoSpin 8 Virus® (Macherey Nagel, Düren, Germany) and an automated extractor (Tecan Evo® 75, Tecan, Männedorf, Switzerland). For organs, total RNA was extracted from 100 μ l of 10% homogenate (w/v) of tissue in PBS using the RNeasy mini kit (Qiagen, Courtaboeuf, France) according to the manufacturer's instructions. RNA was suspended in 30 μ l (blood) or 100 μ l (organs and swab) of RNase-free water and kept at -80 C until use.

Virus detection

Conventional and quantitative real-time reverse transcriptase–polymerase chain reactions (respectively RT-PCR and real-time RTq-PCR) were performed on each whole blood sample. For swabs and organs, only real-time RTq-PCR was performed. For conventional PCR, the 5' untranslated region (5'UTR) was amplified using primers 324 and 326 to amplify a 249 base-pair fragment and sequenced using a previously described method (Dubois et al., 2008).

A one step real-time RTq-PCR on the 5'UTR region was performed as follows. The primer pair R-BD4-237 (5'-GCCCTCG-TCCACGTAGCAT-3') and F-Orlu-171 (5'-AGTACAGGGCAGTCGTCAGTAGTTC-3'), and the FAM-Orlu 200 probe (FAM-CTAA-CTCGGTTTAGTCTCG-MGB) (Applera, Villebon sur Yvette, France) were designed in silico specifically for the detection and quantification of CADI-6. The ABI 7500 Real-Time PCR system (Applied Biosystems, Courtaboeuf, France) was used. Each PCR reaction was run in 25 μ l containing 12.5 μ l $2 \times$ QuantiFast Probe RT-PCR Master Mix (w/o ROX), 10 μ M of both primers, 10 μ M of fluorescent probe, 0.25 μ l of QuantiFast RT Mix and 50 \times ROX Dye Solution (QuantiFast

TABLE 1. Clinical signs and associated scores associated with experimental inoculation of Pyrenean chamois (*Rupicapra pyrenaica*) with border disease virus.

System	Clinical sign	Score ^a	
General	Healthy	0-1	
	Weakness	0-1	
	Apathy	0-1	
	Prostration	0-1	
	Decubitus	0-1	
	Lymph node hypertrophy	0-1	
	Weight loss	0-1	
	Dehydration	0-1	
	Death	0-10	
	Dermatology	Alopecia	0-1
Ulcer on: Mouth		0-1	
Lips		0-1	
Nostril		0-1	
Vulva		0-1	
Skin		0-1	
Hyperkeratosis		0-1	
Conjunctivitis		0-1	
Reproductive system		Premature birth	0-1
		Blood discharge	0-1
	Stillbirth: Normal	0-1	
	Mummified	0-1	
	Generalized congestion	0-1	
	Undeveloped	0-1	
	Newborn: Malformations	0-1	
Weakness	0-1		
Digestive system	Anorexia	0-1	
	Excessive salivation	0-1	
	Diarrhea	0-1	
	Hemorrhagic diarrhea	0-1	
	Respiratory system	Cough	0-1
Nasal discharge		0-1	
Lachrymal discharge		0-1	
Dyspnea		0-1	
Locomotive system		Limping	0-1
	Nervous system	Tremor	0-1
Ataxia		0-1	
Paresis		0-1	
Paralysis		0-1	

^a Assessments consistent with good health were assigned a score of 0 and abnormalities a score of 1; a score of 10 was attributed to death.

kit, Qiagen), and 2 µl of purified RNA. PCR conditions were a starting period of 10 min at 55 C and 5 min at 95 C, followed by 45 cycles of 10 sec at 95 C and of 30 sec at 60 C. Fluorescent measurements were carried out during the elongation step.

The 5'UTR PCR amplicon was cloned into the pGEM®T Easy Vector (Promega, Charbonnières-les-Bains, France). After in vitro transcription with the Promega ribomax large-scale RNA production system (Promega), RNAs were purified and quantified in order to obtain a standard dilution of synthetic RNA

(2×10^6 to 2×10^{-1} copies of RNA per microliter). Standard curves were used to estimate the quantity of RNA detected in blood or swabs.

Virus titration

Ten microliters of each sample were diluted in 90 µl of MEM-Gibco, and twofold serial dilutions were inoculated onto five wells on 96-well microtiter plates containing ETM52 cells. After 1 hr of incubation at 37 C in 5% CO₂, the wells were drained and a growth

medium supplemented with antibiotics (penicillin 100,000 UI/L, streptomycin 50 mg/L) was added. Cultures were incubated for 5 days at 37 C in 5% CO₂. After cell fixation with cold acetone, the virus was detected by immunofluorescence assay using a poly pestivirus monoclonal antibody (Synbiotics, Lyon, France). Titers were expressed as the reciprocal of the highest blood dilution yielding 50% virus growth and were calculated with the Spearman-Kärber method (Thrusfield, 1986).

Serologic analyses

Pestivirus-specific antibodies against the p80 protein (also known as NS3) were detected using a blocking enzyme-linked immunosorbent assay (ELISA; Synbiotics) according to the manufacturer's recommendations.

For the VN test, strain CADI-6 was used to perform specific neutralizations. A previously described method was used (Martin et al., 2011) with minor modifications concerning incubation (1 hr at 37 C). The virus was detected as in the titration method, and titers were expressed as the reciprocal of the highest serum dilution yielding 50% virus growth neutralization.

Necropsy and postmortem examinations

A necropsy was performed within 24 hr of the animals' death (carcasses were stored at 5 C) or immediately after euthanasia. Adult and fetal brains, cotyledon, kidney, liver, lung, mesenteric node, myocardium, skin, and spleen were collected whenever possible. One-hundred and eighty milligrams of tissue were sampled and ground in 600 µl of PBS. Of these 600 µl, 100 µl were used for extraction and subsequently analyzed by real-time RTq-PCR, as described above. Tissue samples collected during necropsy for histopathologic analyses were fixed in a 10% buffered formalin and then trimmed, paraffin-embedded, sectioned at 3–4 µm, and stained with hematoxylin and eosin.

RESULTS

Clinical signs and scores

Chamois A did not show any clinical signs before its sudden death at 24 dpi. During necropsy, signs of hemorrhagic diarrhea were found and the fetus was mummified. Chamois B showed clinical diarrhea from 14 dpi and weakness from

35 dpi until its death on 51 dpi, but did not display other severe clinical signs. Although the animal was not weighed, clinical examination suggested weight loss during the experiment period. The third animal (C) aborted at 46 dpi. Except for abortion and apparent weight loss, it did not present clinical signs related to the pestivirus infection. Although this animal did not display several clinical signs, it was decided to proceed to euthanasia at 51 dpi because 1) it had already aborted, 2) we did not want to keep it alone in experimental conditions, and 3) we wanted to obtain necropsy samples that could be compared to those from animal B. The two control animals were also euthanized at 52 dpi. They did not show any clinical signs throughout the experimentation. The fetus of the control chamois had nearly reached full term by the end of the experiment.

The cumulated clinical scores were 10 for chamois A (corresponding to its death score), 63 for chamois B (the sum of 10 points for death, 37 points for 37 days of diarrhea, and 16 points for 16 days of weakness), 7 for chamois C (the sum of 3 points for 1 day of apathy, dehydration, and anorexia, 3 points for 3 days of apathy, and 1 point for 1 day of nasal discharge), and 0 for the two control animals.

Hematology

No significant variation was observed in red blood cell count, hematocrit, mean corpuscular volume, or mean corpuscular hemoglobin concentration in any individual (data not shown). Figure 1 shows the evolution of total leukocyte counts. All Pyrenean chamois (including controls) first showed a decrease in the total leukocyte count, reflected in both lymphocyte and neutrophil counts from the inoculation day to 5 dpi (data not shown). After 5 dpi, the total leukocyte count decreased again only for inoculated animals. Chamois A died 3 days after its total leukocyte count dropped to 1,200 cells/mm³, and chamois B died 5 days after its

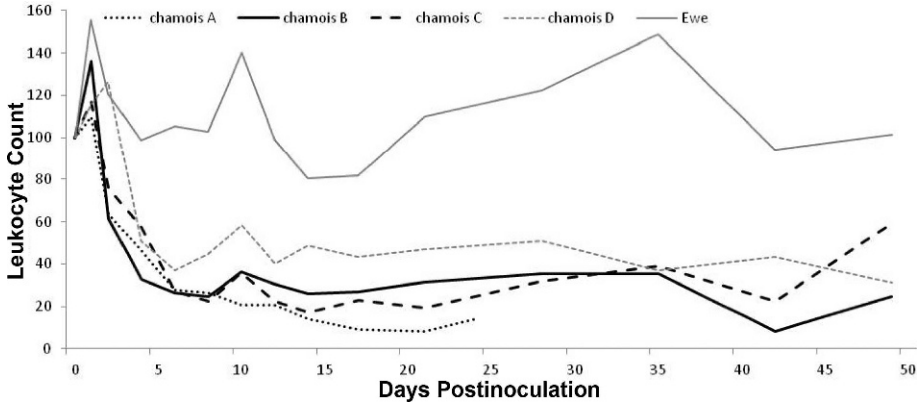


FIGURE 1. Evolution of total leukocyte count after experimental inoculation of Pyrenean chamois (*Rupicapra pyrenaica*) with border disease virus. Chamois A, B, and C were inoculated with virus; chamois D and the “ewe” form the control group. To compare individual variations, the mean of values obtained 10, 5, and 0 days prior to inoculation was calculated and scaled to 100 for each animal, constituting the value at the time of inoculation.

total leukocyte count was $1,500 \text{ cells/mm}^3$. In contrast, the leukocyte count of chamois C, which did not die, stayed above $2,000 \text{ cells/mm}^3$.

Viremia

Pestivirus RNA and viruses were detected in all inoculated animals at 4 dpi. Control individuals remained negative throughout the experiment. Figure 2 shows viremia kinetics by both viral titration and real-time RTq-PCR. Viremia remained positive for chamois C until it was euthanized at 51 dpi, with the highest titers at 17 dpi ($2.2 \times 10^6 \text{ TCID}_{50}/\text{ml}$). For animal B, maximum values increased to $3.0 \times 10^6 \text{ TCID}_{50}/\text{ml}$ during a 23-day period between 28 and 51 dpi. In contrast, chamois A had a very low viremia from 4 to 17 dpi, reaching only $2.0 \times 10^5 \text{ TCID}_{50}/\text{ml}$. RNA was detected by real time RTq-PCR in blood at 2 dpi for animals A and B and at 4 dpi for C. For chamois A, the total RNA count reached $1.1 \times 10^6 \text{ RNA copies/ml}$ on 12 dpi and decreased thereafter. For the other two inoculated animals, maximum values were obtained at 35 dpi with values higher than 2.5×10^7 copies of RNA/ml and remained stable until their death at 51 dpi. Control animals remained negative throughout the experiment.

Viral excretion

All animals were tested by oral, vaginal, nasal, and rectal routes. Viral detection was positive from 12 dpi in all vaginal, rectal, and nasal samples. Animal A

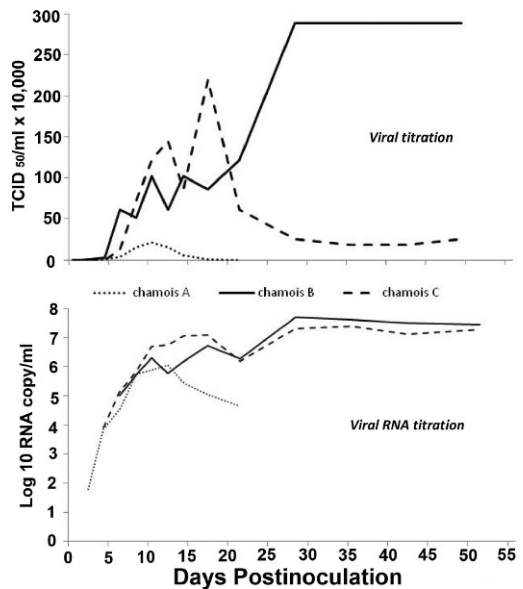


FIGURE 2. Kinetics of infectious virus (50% tissue culture infectious dose per milliliter; $\text{TCID}_{50}/\text{ml}$) and viral RNA titer per milliliter (\log_{10} RNA copies/ml) in the blood of the three Pyrenean chamois (*Rupicapra pyrenaica*) experimentally inoculated with border disease virus.

showed only a significant rectal excretion whereas the other two inoculated chamois had high excretion rates for nasal, rectal, and vaginal routes (Fig. 3). Two increases of viral excretion were observed for chamois C: one around 12 dpi and the other around 25 dpi. For chamois B, the nasal and rectal viral excretions increased strongly at 12 dpi and at 17 dpi for the vaginal route. Oral viral excretion was very low for all inoculated animals. No viral excretion was observed for control animals.

Antibody response

Seroconversion was observed by VN test at 12 dpi for animals A and B and at 14 dpi for animal C. No seroconversion was detected in control animals throughout the experiment. The three animals showed three different kinetics of neutralizing antibody titers (Fig. 4). Chamois B had a low antibody titer, reaching 4.4×10^2 50% neutralizing dose per milliliter (ND_{50}/ml)

on 21 dpi. VN titers were higher for animal C between 28 and 35 dpi, with the highest value of 3.6×10^3 ND_{50}/ml , and reached 5.1×10^3 ND_{50}/ml at 21 dpi for animal A. No antibodies were detected in the control animals. Only one sample was positive by ELISA (animal B on 17 dpi), corresponding to a neutralizing antibody concentration of 5.1×10^3 ND_{50}/ml .

Postmortem examination

The results of postmortem examinations are summarized in Table 2. Upon necropsy, animal A presented signs of abundant yellowish diarrhea. Multifocal petechial hemorrhages were present in the serosa and mucosa of the digestive tract, mainly on the abomasum and small intestine as well as the epicardium and pericardium. Lungs were highly affected with a sizeable hemorrhage on the right lung apical lobe and petechiae on the pleura. All lymph nodes had increased in volume. Chamois

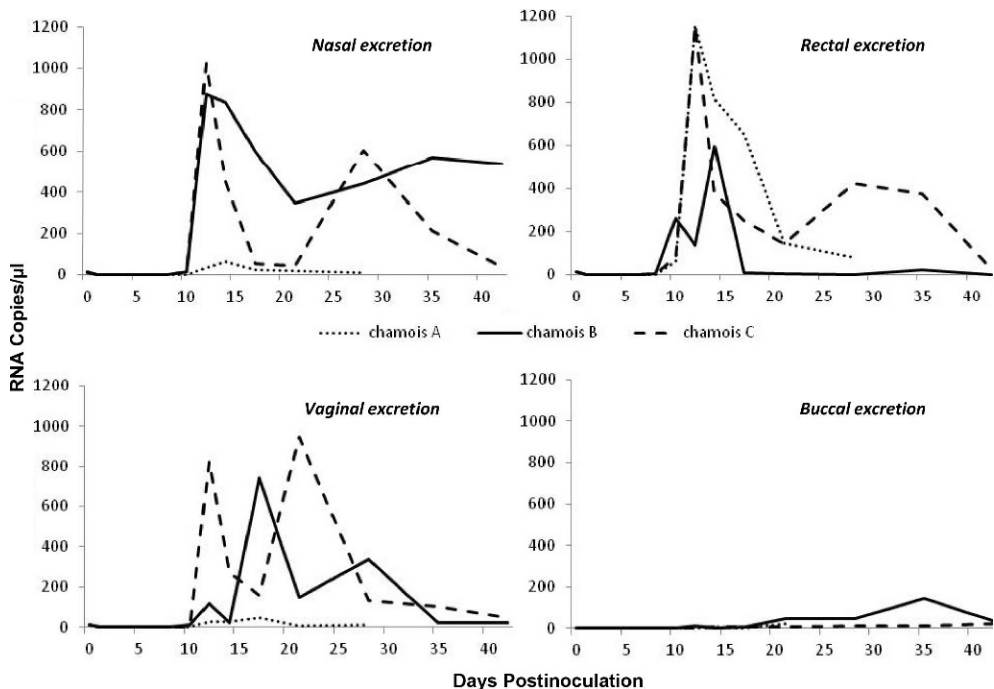


FIGURE 3. Pestivirus excretion expressed in genome copy number per microliter of swab suspension (RNA copies/microliter) as determined by quantitative real-time reverse transcriptase–polymerase chain reaction through nasal, rectal, vaginal, and buccal routes in the three Pyrenean chamois (*Rupicapra pyrenaica*) experimentally inoculated with border disease virus.

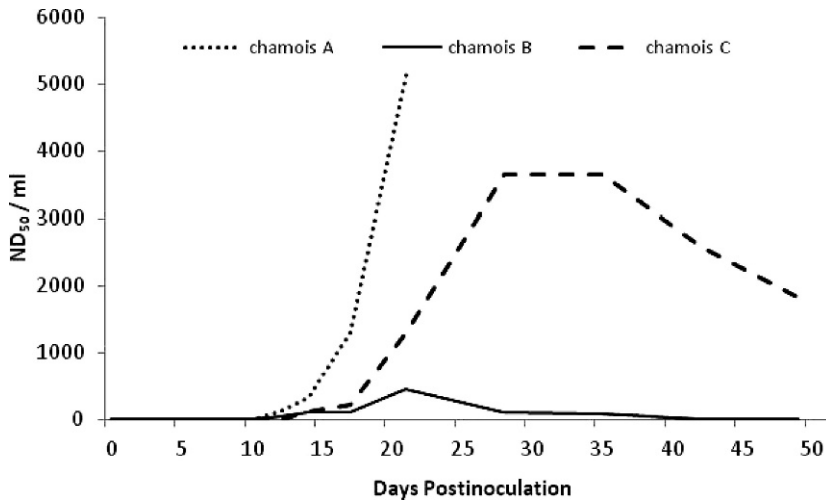


FIGURE 4. Kinetics of pestivirus-neutralizing antibodies (50% neutralizing dose per milliliter: ND₅₀/ml) in three Pyrenean chamois (*Rupicapra pyrenaica*) experimentally inoculated with border disease virus.

B was emaciated and presented severe enteritis in the small intestine with signs of brown diarrhea, severe verminous tracheitis, and verminous bronchopneumonia. Animal C presented chronic pulmonary abscesses, unrelated to the viral infection, and verminous bronchopneumonia. No macroscopic lesions were observed in any of the fetuses, either after infection of the mother (B-fetus and C-fetus) or in control animals (D, D-fetus and the ewe).

Histopathologic examinations of all inoculated animals revealed mild lymphohistiocytic encephalitis associated with moderate (B and C) or moderately severe (A) lymphoid depletion. Concurrent infections reported macroscopically were confirmed and completed. Animal A presented severe bacterial necrotizing pneumonia, animal B enteric coccidiosis, and animal C suppurative bacterial placentitis. The fetus of B had severe autolytic changes precluding a precise histologic evaluation. Nevertheless, it was possible to observe multifocal acute hemorrhages in the brain and a diffuse lymphoid depletion in the spleen. No histologic changes were noticed in control animals.

Real-time RTq-PCR was performed on the total RNA extracted from collected organs (Table 3). Pestivirus RNA was

detected in all the tissues of inoculated animals except one, the skin of animal A. Moreover, all organs of B-fetus, C-fetus, and A-fetus were PCR-positive (Tables 2 and 3). Real-time RTq-PCR was negative for all the organs of the control animals. The viral RNA detected in adults B and C and their fetuses were sequenced and found to be identical to that of the inoculated strain (CADI-6).

DISCUSSION

Three pregnant Pyrenean chamois were inoculated with a BDV-4 strain previously isolated from wild Pyrenean chamois. One died at 24 dpi with a mummified fetus, another died on 51 dpi, and the third aborted on 46 dpi before being euthanized on 51 dpi. Viral RNA was detected in all fetal organs of inoculated females, with high loads of viruses.

Within 5 days of inoculation, the total leukocyte count decreased for all chamois, including the control. However, after 5 dpi, the total leukocyte count decreased only for inoculated animals and remained stable for the control chamois. The stress induced by capture and transport affects hematologic, serum chemistry, and clinical parameters (López-Olvera et al., 2007).

TABLE 2. General characteristics of the experimental animals and postmortem results following experimental inoculation of Pyrenean chamois (*Rupicapra pyrenaica*) with border disease virus.

Animal identification	General information			Postmortem results ^a			
	Status	Age (yr)	Sum of clinical scores	Day of death (dpi)	Gross observations	Histologic findings	Presence of RNA in organs except skin
A	Inoculated	4	10	24	Diarrhea; multifocal petechial hemorrhages in digestive tract, epicardium, and pericardium; pulmonary hemorrhages; generalized lymphadenomegaly	Mild lymphohistiocytic encephalitis; marked lymphoid depletion	All organs tested positive
B	Inoculated	14	63	51	Emaciated; enteritis with yellowish diarrhea; thinness	Mild lymphohistiocytic encephalitis; moderate lymphoid depletion	All organs tested positive
C	Inoculated	7	7	51	Thinness; pulmonary abscess (older lesions)	Mild lymphohistiocytic encephalitis; moderate lymphoid depletion	All organs tested positive
A fetus	Infected	UB	UB	Undetermined	Fetal mummification	ND	All organs tested positive
B fetus	Infected	UB	UB	51	Normal	Multifocal acute hemorrhages in brain	All organs tested positive
C fetus	Infected	UB	UB	46 (abortion date)	Normal	ND	All organs tested positive
D	Control	9	0	63	Normal	No histologic lesions	All organs tested negative
Ewe	Control	1	0	63	Normal	No histologic lesions	All organs tested negative
D fetus	Control	UB	UB	63	Normal	No histologic lesions	All organs tested negative

^a dpi = days post inoculation; UB = unborn; ND = not done.

TABLE 3. Viral RNA titers by real-time reverse transcriptase–polymerase chain reaction for organs of Pyrenean chamois (*Rupicapra pyrenaica*) experimentally inoculated with border disease virus (results expressed in number of RNA copies per gram of tissue).

Animal	Cotyledon	Brain	Kidney	Liver	Lung	Mesenteric node	Myocardium	Skin	Spleen
A	1.5×10^6	3.4×10^4	7.5×10^4	7.5×10^2	3.4×10^5	2.3×10^4	9.4×10^1	0	2.3×10^5
B	1.3×10^7	3.4×10^6	5.9×10^6	3.4×10^6	8.7×10^6	5.0×10^3	8.4×10^5	9.7×10^4	5.6×10^6
C	1.0×10^8	1.2×10^6	4.0×10^5	1.9×10^6	3.7×10^7	2.6×10^6	1.0×10^6	1.9×10^4	3.7×10^6
B-fetus	-	1.5×10^6	2.3×10^6	2.1×10^6	1.1×10^7	-	6.5×10^5	8.7×10^6	5.9×10^6
C-fetus	-	4.1×10^6	2.2×10^6	3.4×10^5	8.7×10^5	-	2.6×10^5	2.2×10^6	4.7×10^5
Ewe	-	0	0	0	0	0	0	0	0
D	0	0	0	0	0	0	0	0	0
D-fetus	-	0	0	0	0	0	0	0	0

Duncan and collaborators (Duncan et al., 1994) showed that the leukocyte response to stress is biphasic: a preliminary lymphocytic leukocytosis is followed by lymphopenia. In this experiment, after capture and transport, an acclimatization period of 10 days preceded inoculation. During this period, animals were sampled only once, 5 days before inoculation. After inoculation, they were sampled daily for 3 days and every 2 days for 1 wk. Both inoculation and sampling procedures may have stressed animals, which can explain the general leukocytosis followed by leukopenia observed between 0 and 5 dpi. After 5 dpi, leukopenia was more severe for inoculated animals than for the control chamois and lasted until the end of the experiment. Leukopenia is commonly associated with pestivirus infection in both domestic (Thabti et al., 2002) and wild species. In Pyrenean chamois, leukopenia has been associated with BDV infection in both natural (Fernández-Sirera et al., 2011) and experimental conditions (Cabezón et al., 2011).

This experiment confirms that a specific course of infection occurs in chamois. Abortion and animal death were observed. Pestivirus was detected in the cotyledons of inoculated animals, which would indicate that the virus caused their abortion. Infections in livestock are usually shorter and milder. In lambs (Cabezón et al., 2010c) and pigs (Cabezón et al., 2010a) inoculated with the same strain, no clinical signs were reported and the associated viremia was short-lived. In nonpregnant Pyrenean chamois inoculated under the same conditions as in this study, two animals were found dead on 18 and 21 dpi, with signs of hemorrhagic diarrhea, and one died at 24 dpi after a coughing attack. The last two inoculated animals were euthanized at 34 dpi without presenting any clinical signs other than weight loss and high body temperature (Cabezón et al., 2011). In the two experiments, secondary infections were the rule, indicating that all inoculated animals had low immune defense.

All inoculated chamois showed positive viremia until at least 17 or 51 dpi. Such long-lasting viremia associated with pestivirus infection has only been described in chamois (Cabezón et al., 2011). In contrast, during transient infection in sheep, viremia is short-lived, lasting no more than 12–15 days (Thabti et al., 2002). In other wild species, such as elk (*Cervus elaphus*), viremia was only detected between 3 dpi and 7 dpi (Tessaró et al., 1999).

Chamois A eliminated the virus at 17 dpi. It did not survive despite high VN titers. Chamois B (the oldest at 14 yr old) had a very long-lasting and severe viremia until death at 51 dpi. Despite a seroconversion on 12 dpi, VN titers remained very low and were negative before death. The third animal (C) seroconverted, with VN titers higher than chamois B but still lower than others described in the field (Marco et al., 2011; Martín et al., 2011). The ELISA for antibody detection was positive only when VN titers reached 5.1×10^3 ND₅₀/ml. These results provide important information for the epidemiologic study of pestivirus infection in natural conditions. Indeed, the usual methods used in the field are a preliminary screening of antibody prevalence by ELISA followed by RT-PCR for viral detection in ELISA-negative samples (Martín et al., 2011). In livestock, to differentiate a PI animal from an animal in transient infection, two PCRs with a 3-wk interval have to be positive. However, the current study results show that chamois in transient infection display this profile if the ELISA is used for antibody detection. Care must, therefore, be taken when interpreting infection status for wildlife studies in the field.

These results also have important implications concerning the epidemiology of border disease. Of three inoculated pregnant females, one had a mummified fetus, one died before parturition, and one aborted. As none of the pregnancies reached term, the usual method of determining a PI animal (serial virus detections)

could not be used. However, a multisystemic and systematic distribution of viruses in all organs of infected fetuses was present, with high virus loads. The virulence of the strain may be the cause of death of the fetuses. In chamois, pestivirus RNA has already been isolated in a fetus (Cabezón et al., 2010b). An experimental infection of one pregnant Pyrenean chamois was conducted in 2008 (Vautrain and Gibert, 2008). RT-PCRs at birth and death (on 92 days) were both positive. In general, the multisystemic distribution of the virus, its excretion by several routes, the long-lasting viremia, and the possible birth of PI offspring revealed in this study suggest that infected chamois may efficiently transmit infection in natural populations.

Our results mostly confirm virologic and histologic observations made in the field. In all inoculated animals, the virus had a multisystemic distribution. Histologic lesions were consistent with those observed in animals infected in both natural and experimental conditions. In chamois naturally infected by BDV type 4, the main lesions were observed in the brain with diffuse moderate spongiosis, occasional glial nodules, neuronal degeneration, and death, and occasionally a nonpurulent perivascular inflammatory infiltrate (Marco et al., 2007). Besides, major lymphoid depletion was present in all infected animals, which is usually observed with pestivirus infection. In an experimentally infected pregnant doe with BVDV, the most significant histologic abnormality was diffuse depletion of B-lymphocytes in fawns (Duncan et al., 2008). Although weight loss was not quantified, two out of three animals were seen to have lost weight during the experimentation, which is in accordance with the cachexia observed in 15 of 23 virus-positive chamois (Marco et al., 2009).

However, clinical signs did not exactly correspond to observations of infections in natural conditions (cutaneous signs or neurologic alterations were not observed).

In both experiments (Cabezón et al., 2011 and the present study), infections lasted at least 18 days and were progressive: no individual remained without any sign or lesion, but duration, signs, and lesions differed. In experimental infections, signs were expected to differ from natural infections because individuals were stressed and had to adapt to an unknown environment. The immunodepression caused by the virus, associated with the stress induced by captivity, favored the expression of secondary infections. Their precise timing and signs were expected to be variable, as they are agent- and individual-dependant.

In the Pyrenees Mountains, pestivirus infections have been shown to be associated with a marked decline in Pyrenean chamois populations (Marco et al., 2011). In contrast, in populations of Alpine chamois (*Rupicapra rupicapra*) in the French Alps, infection was shown to be associated with a decrease in fertility (number of kids/number of females per year; Martin et al., 2011). The results of this experiment confirm both observations in natural populations: BDV-4 infection in Pyrenean chamois led to abortion, fetus mummification, and secondarily to death. Chamois fetuses were shown to be infected by the virus. Their role in the epidemiology of pestivirus in chamois populations needs to be assessed.

ACKNOWLEDGMENTS

The Veterinary Services Directorate of the Alpes-Maritimes Department approved the care and use of chamois in this experiment. The primary author holds chamois farming capacity certificate 2010-2671. The work was conducted in the experimental station of the ANSES Sophia-Antipolis laboratory, under agreement A06-018-2 delivered according to French regulation by veterinary services, which approved the experimental conditions for handling wild ungulates. Special thanks to Serge Mounard (Parc Animalier des Pyrénées, Argelès-Gazost, France) for providing the pregnant Pyrenean chamois. We are most grateful to Joël Appolinaire, Jean-Marc Cugnasse, and the ONCFS French Wildlife and Hunting Agency officers for their

help in handling the chamois. We are also grateful to Rosa Rosell and Oscar Cabezón for their involvement in study design. This study was supported by a doctoral fellowship provided by ANSES and the Provence-Alpes-Côte d'Azur region (France).

LITERATURE CITED

- Arnal MC, Fernandez-De-Luco D, Riba L, Maley M, Gilray J, Willoughby K, Vilček S, Nettleton PF. 2004. A novel pestivirus associated with deaths in Pyrenean chamois (*Rupicapra pyrenaica pyrenaica*). *J Gen Virol* 85:3653–3657.
- Avalos-Ramirez R, Orlich M, Thiel HJ, Becher P. 2001. Evidence for the presence of two novel pestivirus species. *Virology* (New York) 286:456–465.
- Becher P, Avalos Ramirez R, Orlich M, Cedillo Rosales S, König M, Schweizer M, Stalder H, Schirrmeyer H, Thiel HJ. 2003. Genetic and antigenic characterization of novel pestivirus genotypes: Implications for classification. *Virology* 311:96–104.
- Cabezón O, Rosell R, Sibila M, Lavín S, Marco I, Segalés J. 2010a. Experimental infection of pigs with border disease virus isolated from Pyrenean chamois (*Rupicapra pyrenaica*). *J Vet Diagn Invest* 22:360–365.
- Cabezón O, Rosell R, Velarde R, Mentaberre G, Casas-Díaz E, Lavín S, Marco I. 2010b. Border disease virus shedding and detection in naturally-infected Pyrenean chamois (*Rupicapra pyrenaica*). *J Vet Diagn Invest* 22:360–365.
- Cabezón O, Velarde R, Rosell R, Lavín S, Segalés J, Marco I. 2010c. Experimental infection of lambs with border disease virus isolated from a Pyrenean chamois. *Vet Rec* 167:619–621.
- Cabezón O, Velarde R, Mentaberre G, Fernández-Sirera L, Casas-Díaz E, López-Olvera JR, Serrano E, Rosell R, Riquelme C, Lavín S, et al. 2011. Experimental infection with chamois border disease virus causes long-lasting viraemia and disease in Pyrenean chamois (*Rupicapra pyrenaica*). *J Gen Virol* 92:2494–2501.
- Dubois E, Russo P, Prigent M, Thiéry R. 2008. Genetic characterization of ovine pestiviruses isolated in France, between 1985 and 2006. *Vet Microbiol* 130:69–79.
- Duncan C, Ridpath J, Palmer MV, Driskell E, Spraker T. 2008. Histopathologic and immunohistochemical findings in two white-tailed deer fawns persistently infected with bovine viral diarrhea virus. *J Vet Diagn Invest* 20:289–296.
- Duncan JR, Prasse KW, Mahaffey EA. 1994. *Veterinary Laboratory Medicine. Clinical Pathology*. Iowa State University Press, Ames, Iowa, 450 pp.
- Fernández-Sirera L, Mentaberre G, López-Olvera JR, Cuenca R, Lavín S, Marco I. 2011. Haematology

- and serum chemistry of Pyrenean chamois (*Rupicapra pyrenaica*) naturally infected with a border disease virus. *Res Vet Sci* 90:463–467.
- Frölich K, Jung S, Ludwig A, Lieckfeld D, Gibert P, Gauthier D, Hars J. 2005. Detection of a newly described pestivirus of Pyrenean chamois (*Rupicapra pyrenaica pyrenaica*) in France. *J Wildl Dis* 41:606–610.
- Giammarioli M, La Rocca SA, Steinbach F, Casciari C, De Mia GM. 2011. Genetic and antigenic typing of border disease virus (BDV) isolates from Italy reveals the existence of a novel BDV group. *Vet Microbiol* 147:231–236.
- Krametter-Froetscher R, Kohler H, Benetka V, Mostly K, Golja F, Vilček S, Baumgartner W. 2007. Influence of communal alpine pasturing on the spread of pestiviruses among sheep and goats in Austria: First identification of border disease virus in Austria. *Zoonoses Public Hlth* 54:209–213.
- Letellier C, Kerkhofs P. 2003. Real-time PCR for simultaneous detection and genotyping of bovine viral diarrhoea virus. *J Virol Methods* 114:21–27.
- López-Olvera JR, Marco I, Montané J, Casas-Díaz E, Lavín S. 2007. Effects of acepromazine on the stress response in southern chamois (*Rupicapra pyrenaica*) captured by means of drive-nets. *Can J Vet Res* 71:41–51.
- Marco I, López-Olvera JR, Rosell R, Vidal E, Hurtado A, Juste R, Pumarola M, Lavín S. 2007. Severe outbreak of disease in the southern chamois (*Rupicapra pyrenaica*) associated with border disease virus infection. *Vet Microbiol* 120:33–41.
- Marco I, Rosell R, Cabezón O, Mentaberre G, Casas E, Velarde R, Lavín S. 2009. Border disease virus among chamois, Spain. *Emerg Infect Dis* 15:448–451.
- Marco I, Cabezón O, Rosell R, Fernández-Sirera L, Allepuz A, Lavín S. 2011. Retrospective study of pestivirus infection in Pyrenean chamois (*Rupicapra pyrenaica*) and other ungulates in the Pyrenees (NE Spain). *Vet Microbiol* 149:17–22.
- Martin C, Letellier C, Caij B, Gauthier D, Jean N, Shaffii A, Saegerman C. 2011. Epidemiology of pestivirus infection in wild ungulates of the French South Alps. *Vet Microbiol* 3–4:320–328.
- Martinelle L, Dal Pozzo F, Sarradin P, De Leeuw I, De Clerck K, Thys C, Ziant D, Thiry E, Saegerman C. 2011. Two alternative inocula to reproduce bluetongue virus serotype 8 disease in calves. *Vaccine* 29:3600–3609.
- Passler T, Walz PH, Ditchkoff SS, Givens MD, Maxwell HS, Brock KV. 2007. Experimental persistent infection with bovine viral diarrhoea virus in white-tailed deer. *Vet Microbiol* 122:350–356.
- Passler T, Walz PH, Ditchkoff SS, Brock KV, Deyoung RW, Foley AM, Givens MD. 2009. Cohabitation of pregnant white-tailed deer and cattle persistently infected with bovine viral diarrhoea virus results in persistently infected fawns. *Vet Microbiol* 134:362–367.
- Pioz M, Loison A, Gibert P, Dubray D, Menaut P, Le Tallec B, Artois M, Gilot-Fromont E. 2007. Transmission of a pestivirus infection in a population of Pyrenean chamois. *Vet Microbiol* 119:19–30.
- Raizman EA, Pogranichny R, Lévy M, Negron M, Langohr I, Van Alstine W. 2009. Experimental infection of white-tailed deer fawns (*Odocoileus virginianus*) with bovine viral diarrhoea virus type-1 isolated from free-ranging white-tailed deer. *J Wildl Dis* 45:653–660.
- Ridpath JF, Mark CS, Chase CC, Ridpath AC, Neill JD. 2007. Febrile response and decrease in circulating lymphocytes following acute infection of white-tailed deer fawns with either a BVDV1 or a BVDV2 strain. *J Wildl Dis* 43:653–659.
- Schirmmeier H, Strebelow G, Depner K, Hoffmann B, Beer M. 2004. Genetic and antigenic characterization of an atypical pestivirus isolate, a putative member of a novel pestivirus species. *J Gen Virol* 85:3647–3652.
- Stalder HP, Meier P, Pfaffen G, Wageck-Canal C, Rufenacht J, Schaller P, Bachofen C, Marti S, Vogt HR, Peterhans E. 2005. Genetic heterogeneity of pestiviruses of ruminants in Switzerland. *Prev Vet Med* 72:37–41.
- Tessaro SV, Carman PS, Deregt D. 1999. Viremia and virus shedding in elk infected with type 1 and virulent type 2 bovine viral diarrhoea virus. *J Wildl Dis* 35:671–677.
- Thabti F, Fronzaroli L, Dlissi E, Guibert JM, Hammami S, Pepin M, Russo P. 2002. Experimental model of border disease virus infection in lambs: Comparative pathogenicity of pestiviruses isolated in France and Tunisia. *Vet Res* 33:35–45.
- Thrusfield M. 1986. Serological epidemiology. In: *Veterinary epidemiology*, Thrusfield M, editor. Butterworths, London, UK, pp. 175–186.
- Valdazo-Gonzalez B, Alvarez-Martinez M, Sandvik T. 2007. Genetic and antigenic typing of border disease virus isolates in sheep from the Iberian Peninsula. *Vet J* 174:316–324.
- Van Campen H, Williams ES, Edwards J, Cook W, Stout G. 1997. Experimental infection of deer with bovine viral diarrhoea virus. *J Wildl Dis* 33:567–573.
- Vautrain G, Gibert P. 2008. Le pestivirus de l'isard contamine-t-il les ovins? Résultats d'expérimentations. *Faune sauvage* 282:46–49.
- Vilček S, Nettleton PF, Paton DJ, Belak S. 1997. Molecular characterization of ovine pestiviruses. *J Gen Virol* 78:725–735.
- Vilček S, Paton DJ, Durkovic B, Strojny L, Ibata G, Moussa A, Loitsch A, Rossmanith W, Vega S, Scicluna MT, Palfi V. 2001. Bovine viral

- diarrhoea virus genotype 1 can be separated into at least eleven genetic groups. *Arch Virol* 146:99–115.
- Vilček S, Durkovic B, Kolesarova M, Paton DJ. 2005. Genetic diversity of BVDV: Consequences for classification and molecular epidemiology. *Prev Vet Med* 72:31–35.
- Vilček S, Nettleton PF. 2006. Pestiviruses in wild animals. *Vet Microbiol* 116:1–12.
- Submitted for publication 6 September 2011.*
Accepted 13 August 2012.