

Fishhook Lesions in Loggerhead Sea Turtles

Ana Luisa S. Valente,¹ Maria Luz Parga,² Roser Velarde,¹ Ignasi Marco,¹ Santiago Lavin,¹ Ferran Alegre,² and Rafaela Cuenca¹ ¹Servei d'Ecopatologia de Fauna Salvatge, Facultat de Veterinària, Universitat Autònoma de Barcelona, 08193-Bellaterra, Barcelona, Spain; ²Centre de Recuperació d'Animals Marins, Camí Ral 239, 08330—Premià de Mar, Barcelona, Spain; ³Corresponding author (email: schifinoval@hotmail.com)

ABSTRACT: This study describes four cases of loggerhead sea turtles with fishhooks in the gastrointestinal tract. Two dead turtles with a hook in the esophagus had local fibrosis with an invagination of the keratinized stratified squamous epithelium surrounding the hook, isolating it from the subjacent stroma, one had a hook in the cloaca which was expelled spontaneously, and one had plication of the intestine with necrosis caused by the long monofilament line attached to the hook lodged in the esophagus. Lethal injuries were related to the effect of strangulation and traction produced by the line throughout the gastrointestinal tract rather than the presence of the hook in the esophageal mucosa. Hook size, point of attachment to the gastrointestinal tract, the presence or not of a long monofilament line, and the traction applied by it could be crucial for turtle survival.

Key words: *Caretta caretta*, fishhooks, intestinal plication, loggerhead sea turtles.

The loggerhead sea turtle (*Caretta caretta*) is a widespread species of sea turtle greatly threatened by the increase in accidental catches by longline sets. In some areas, such as the Mediterranean sea, fishhook ingestion causes traumatic injuries in the gastrointestinal tract, leading to death in some cases (Pont and Alegre, 2000; Di Bello et al., 2006a). However, other authors have stated that sea turtles are apparently able to sustain considerable injuries and still survive with hooks in the gastrointestinal tract (Tomas et al., 2001; Alegre et al., 2006). Frequently, turtles with multiple hooks lodged in the gastrointestinal tract are able to keep feeding, and in some cases, the hooks are expelled spontaneously (Aguilar et al., 1995; Alegre et al., 2006). Posthooking mortality has been discussed over the last few decades and is assumed to be related to the size and shape of the hook, location in the gastrointestinal tract, and how

a hooked animal is handled and released (Epperly and Boggs, 2004). Most turtles accidentally captured by fishing activities are released with the hook still inside, and scant information about the effect of hook retention in turtle survival is available (Lizana and Barbadillo, 1997). An experiment in 11 juvenile turtles with a hook lodged in the esophagus or stomach revealed that about 50% of them were able to eliminate the hook in 2 yr without distress (Alegre et al., 2006).

In hooked turtles, necropsy findings have shown the presence of an acute inflammatory process with ulcerative and fibrinous esophagitis and traumatic esophageal perforation (Orós et al., 2005). However, damage caused by long-term hooking in tissues has not been evaluated. This short report describes four cases of turtles admitted to the Rescue Center for Marine Animals (CRAM), Premià de Mar, Barcelona, Spain, with fishhooks in the gastrointestinal tract.

Turtles 1 and 2 were juvenile specimens that were dead on arrival at the center due to capture by fishing nets. Turtle 1 had a 3-cm “J” hook, without a line, attached to the midesophagus, surrounded by abundant firm white tissue, which was determined to be fibrosis histologically (Fig. 1A). The fibrous scarring caused displacement of the esophageal lumen. Histologic examination showed an invagination of the keratinized stratified squamous epithelium that normally covers the esophageal papillae surrounding the hook (Fig. 1B) and isolates it from the subjacent stroma. Keratin and detritus were present where the hook was lodged. The subjacent stroma consisted of a mature dense fibrous tissue where groups of striated myofibers from the esophageal wall were present

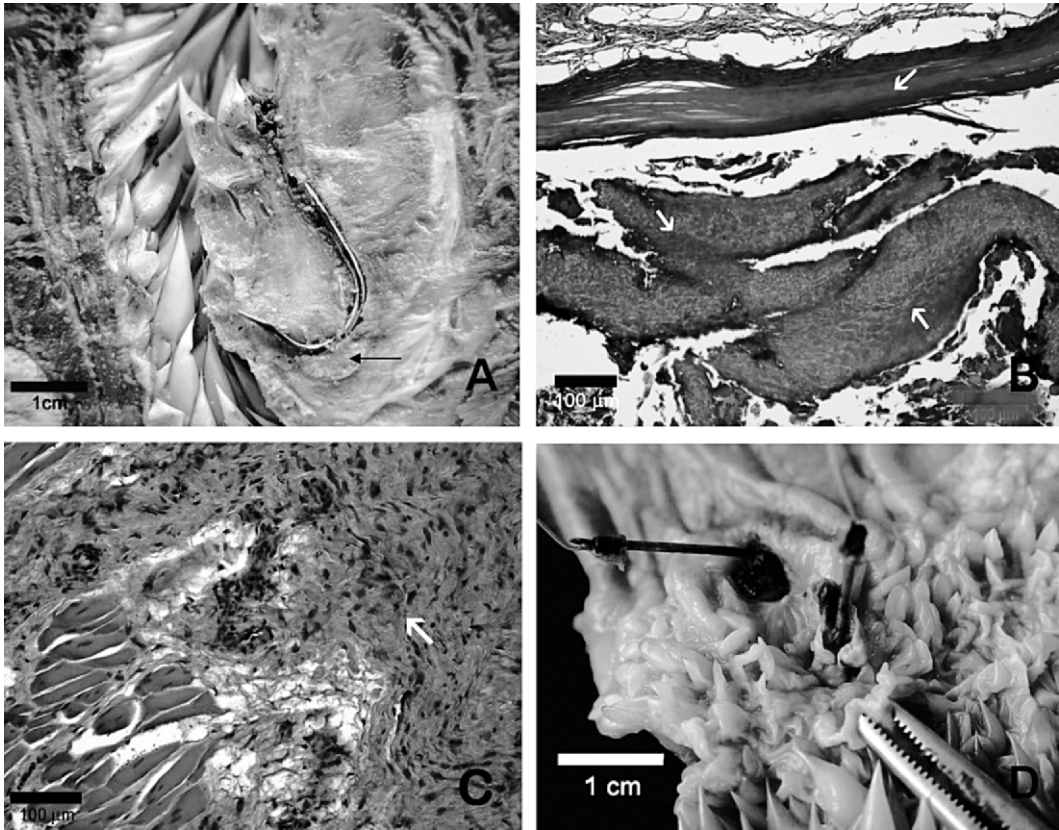


FIGURE 1. A. Photograph of esophagus of a loggerhead sea turtle with attached fishhook (turtle 1). Arrow indicates areas shown in B and C. B. Arrows indicate the keratinized stratified squamous epithelium surrounding and isolating hook. C. Arrow indicates deep, extensive fibrosis within muscle layer. D. Fishhooks found in nonpapillated esophagus of turtle 2.

(Fig. 1C). The diagnosis was hook-induced focal chronic fibrosis.

Turtle 2 had two 2-cm “J” fishhooks lodged in the distal esophagus, in the transition area to the non-papillated esophagus (Pressler et al., 2003). A firm white-yellow mass surrounded each hook (Fig. 1D). Both hooks had an associated monofilament line about 2.5 cm long. Tissue changes around one of the hooks were similar to the previous case, with an invaginated epithelium covered by keratin, cellular detritus and bacteria, and the presence of mature dense fibrous tissue in the subjacent stroma. With the other hook, ulcerated mucosa was observed, together with a deep focus of necrosis in the submucosa with cellular detritus from

inflammatory cells and bacteria surrounded by macrophages and multinucleated giant cells, characteristic of a foreign body reaction or granuloma. The diagnosis was focal esophagitis with chronic fibrosis and foreign body granuloma induced by the hook, respectively.

Turtle 3 was a subadult captured by a fishing net and admitted to the center in August 2004. The turtle readily began voluntary feeding inside the tank and its health status seemed normal during clinical examination. A radiograph taken at admission showed the presence of a single double fishing hook in the descending colon, close to the cloaca (Fig. 2A). One week later, the hook (without monofilament line) was expelled naturally with the

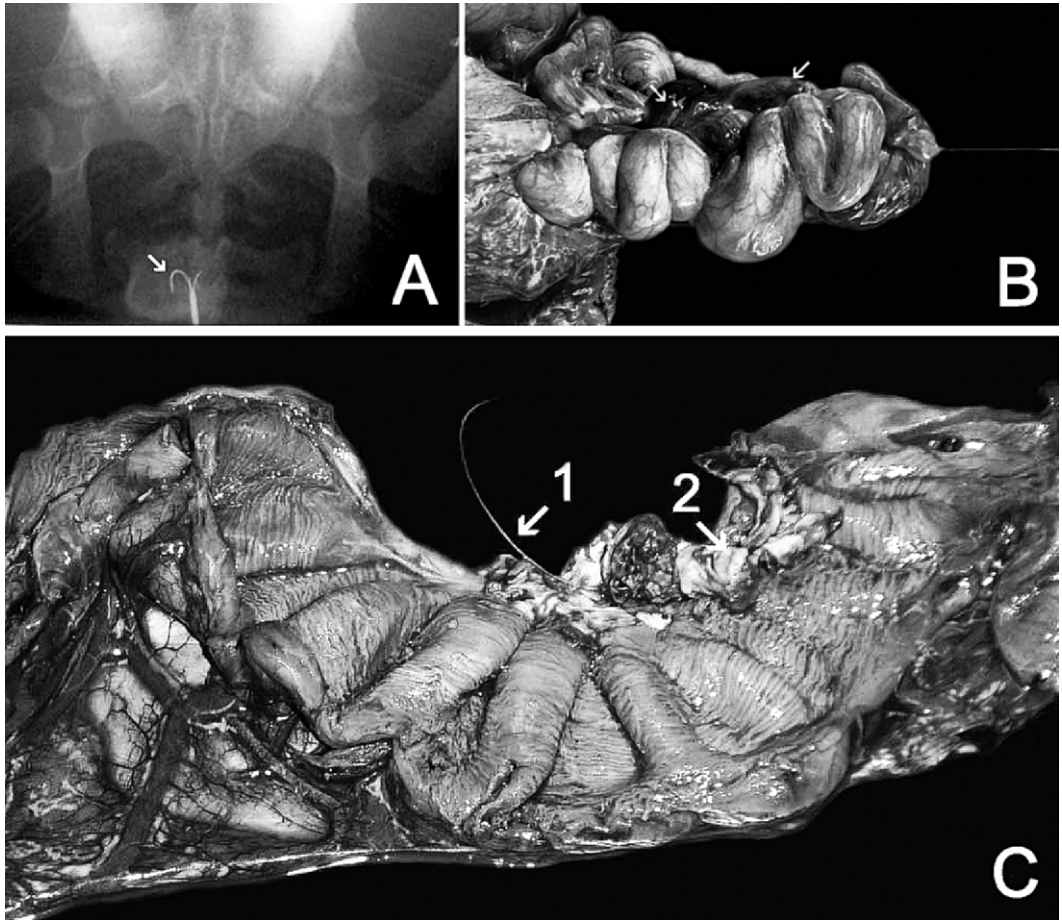


FIGURE 2. A. Dorsoventral radiograph of loggerhead sea turtle (turtle 3) with single double fishhook (arrow) close to cloaca. B. Intestinal plication of turtle 4 caused by peristalsis and line traction along gastrointestinal tract. Arrows indicate congestive areas of intestine. C. Internal view of intestine. 1, monofilament line; 2, areas with fibrin and necrosis.

feces. The turtle was released in October of the same year.

Turtle 4 was a juvenile accidentally captured in a trammel net. The turtle arrived to the center in a state of shock and died 24 hr later. Necropsy findings revealed the presence of a 3-cm “J” fishhook lodged in the distal esophagus and a long monofilament line (>40 cm) that pulled the gastrointestinal tract caudally, causing intestinal plication (Fig. 2B). The intestinal mucosa was ulcerated by the line, and a hemorrhagic focus and intestinal necrosis were present (Fig. 2C). The death of the animal was attributed to damage

caused by the long monofilament line in the intestine.

The hooks extracted from the turtles in this case series were smaller than those usually employed in the long-line sets used in the western Mediterranean, and may have come from recreational or traditional fisheries. Hooks of this kind (about 2 to 3 cm long) lodged in the esophagus do not seem to compromise the survival of the turtle if the line is cut as short as possible. The lesions caused by the hooks seem to begin with transmural esophagitis that can affect the muscle layer, causing extensive localized fibrosis, as observed in turtle 1,

with proliferation of superficial keratinized stratified squamous epithelium to isolate the hook from the subjacent tissue, characterizing a chronic lesion.

Turtle 3, which also had a small hook, showed that the radiographic presence of a hook in the intestines might not necessarily indicate the hook is attached. This finding agrees with the statement of Alegre et al. (2006) from their experimental study. Therefore, before contemplating surgical removal, if the health status of the animal allows, we recommend that at least two dorsoventral radiographs with a 72 hr interval be taken to check whether there is hook displacement.

Turtles with a long monofilament line attached to the hook, which is exiting through the cloaca or mouth (Di Bello et al., 2006b) have a worse prognosis than when the hook alone is present. First, the peristaltic movement displaces the line caudally, producing plication from the point of hook attachment. Plication can also occur when the line-set is taken up in the boat. Depending on the position of the hook inside the turtle, severe damage could ensue because of the turtle's weight and traction. An external line is not always seen in turtles with intestinal plication, such as turtle 4 in this study. In these cases, contrasted radiographs of the gastrointestinal tract using 60% solution of barium sulphate as proposed by Di Bello et al. (2006b) could help in the diagnosis. Surgery is often necessary in these cases.

This short communication helps clarify the effect of long-term hooking in the gastrointestinal tract of loggerhead sea turtles. Lethal injuries are related to strangulations and traction produced by the line throughout the gastrointestinal tract rather than the presence of the hook in the mucosa. The size of the hook, position of attachment in the gastrointestinal tract, the presence or not of a long monofilament line, and the traction applied to it could be decisive to turtle survival. Although traumatic lesions can be a pathway of entry of bacteria and

consequent septicemia (Orós et al., 2004), small fishing hooks with a short monofilament (<5 cm), even deeply attached, do not seem to compromise the life of the turtle. Fishing hooks lodged in the esophagus do not seem to cause great disturbance in the life of the turtle if no long monofilament line is attached. These findings explain why many turtle are found with several different old fishing hooks in their gastrointestinal tract.

LITERATURE CITED

- ALEGRE, F., M. PARGA, C. CASTILLO, AND S. PONT. 2006. Study on the long-term effect of hooks lodged in the mid-esophagus of sea turtles. Twenty-sixth Annual Symposium on Sea Turtle Biology and Conservation, 3–8 April, Creta, Greece, 234 pp. [Abstract].
- AGUILAR, R., J. MAS, AND X. PASTOR. 1995. Impact of Spanish swordfish longline fisheries on the loggerhead sea turtle *Caretta caretta* population in the western Mediterranean. NOAA-NMFS-SEFSC- Technical Memorandum 361: 1–6.
- DI BELLO, A., C. VALASTRO, AND F. STAFFIERI. 2006a. Surgical approach to the coelomic cavity through the axillary and inguinal regions in sea turtles. *Journal of the American Veterinary Medical Association* 228: 922–925.
- , ———, ———, AND A. CROVACE. 2006b. Contrast radiography of the gastrointestinal tract in sea turtles. *Veterinary Radiology and Ultrasound* 47: 351–354.
- EPPERLY, S. P., AND C. BOGGS. 2004. Post-hooking mortality in pelagic longline fisheries using “J” hooks and circle hooks—Application of new draft criteria to data from Northeast distant experiments in the Atlantic. Southeast Fisheries Science Center—Protected Resources and Biodiversity Division. Internal Document no. PRD-03/04-04. http://www.sefsc.noaa.gov/PDFdocs/UPR_Epperly_Boggs_2004.pdf. Accessed 10 July 2006.
- LIZANA, M., AND L. J. BARBADILLO. 1997. Legislación, protección y estado de conservación de los anfibios y reptiles españoles. In *Distribución y biogeografía de los anfibios y reptiles en España y Portugal*, J. M. Pleguezuelos (ed.). Universidad de Granada Editorial, Granada, pp. 477–516.
- ORÓS, J., S. DÉNIZ, AND P. CALABUIG. 2004. Digestive pathology of sea turtles stranded in the Canary Islands between 1993 and 2001. *Veterinary Record* 155: 169–174.
- , A. TORRENT, P. CALABUIG, AND S. DÉNIZ. 2005. Diseases and causes of mortality among sea turtles stranded in the Canary Islands, Spain

- (1998–2001). *Diseases of Aquatic Organisms* 63: 13–24.
- PONT, S. G., AND F. N. ALEGRE. 2000. Work of the Foundation for the Conservation and Recovery of Marine Life. *Marine Turtle Newsletter* 87: 5–7.
- PRESSLER, B. M., R. A. GOODMAN, C. A. HARMS, E. C. HAWKINS, AND G. A. LEWBART. 2003. Endoscopic evaluation of the esophagus and stomach in three loggerhead turtles (*Caretta caretta*) and a Malaysian giant turtle (*Orlitia borneensis*). *Journal of Zoo and Wildlife Medicine* 34: 88–92.
- TOMAS, J., A. DOMINICI, S. NANNARELLI, L. FORNI, F. J. BADILLO, AND J. A. RAGA. 2001. From hook to hook: The odyssey of a Loggerhead Sea Turtle in the Mediterranean. *Marine Turtle Newsletter* 92: 13–14.

Received for publication 26 July 2006.