

# Aggravation by Paroxetine, a Selective Serotonin Reuptake Inhibitor, of Antral Lesions Generated by Nonsteroidal Anti-Inflammatory Drugs in Rats

Koji Takeuchi, Akiko Tanaka, Kazuo Nukui, Azusa Kojo, Melinda Gyenge, and Kikuko Amagase

*Division of Pathological Sciences, Department of Pharmacology and Experimental Therapeutics, Kyoto Pharmaceutical University, Misasagi, Yamashina, Kyoto, Japan*

Received April 24, 2011; accepted June 21, 2011

## ABSTRACT

Recent clinical studies have suggested a risk of adverse gastric reactions from the concomitant use of selective serotonin (5-HT) reuptake inhibitors (SSRIs) with nonsteroidal anti-inflammatory drugs (NSAIDs). We examined the adverse effects of SSRIs on antral lesions produced by indomethacin in rats. Rats fasted for 24 h were refed for 1 h, then administered indomethacin (30 mg/kg s.c.) 1 h after the refeeding and killed 6 h later. Paroxetine (1–10 mg/kg) was given orally 30 min before indomethacin. Indomethacin caused antral lesions in refed rats. Paroxetine dose-dependently aggravated these lesions, despite provoking no damage by itself. Similar results were obtained when other NSAIDs such as diclofenac, flurbiprofen, and loxoprofen were coadministered with paroxetine or when indomethacin was coadministered with other antidepressants such as fluvoxamine and milnacipran, but not imipramine or maprotri-

line. Exogenous 5-HT also worsened the indomethacin-induced antral damage, whereas the aggravating effect of paroxetine was attenuated by ondansetron, a selective 5-HT<sub>3</sub> antagonist, but not antagonists for other 5-HT receptor subtypes. Indomethacin plus paroxetine had no effect on gastric secretion but significantly decreased mucosal superoxide dismutase (SOD) activity as well as GSH content. The antral damage induced by indomethacin plus paroxetine was significantly prevented by antisecretory (acid or pepsin) agents and mucosal protective agents as well as SOD and allopurinol. These results suggest that SSRIs aggravate NSAID-induced antral lesions, probably via the activation of 5HT<sub>3</sub> receptors, and the mechanism of aggravation may involve the corrosive action of acid/pepsin as well as an impaired antioxidative system.

## Introduction

Nonsteroidal anti-inflammatory drugs (NSAIDs), such as indomethacin, cause gastrointestinal lesions, especially in the antrum (Lanza, 1984; Fries et al., 1989). The gastric lesions generated by NSAIDs in experimental animals, however, occur mainly in the corpus, not the antrum, of the stomach under fasting conditions (Takeuchi et al., 1986; Tanaka et al., 2001). These drugs, however, produce lesions in the small intestine but not the stomach under nonfasting conditions (Kunikata et al., 2001; Tanaka et al., 2002). It is

noteworthy that indomethacin caused antral lesions in rats subjected to 24 h of fasting and subsequent 1 h of refeeding (Satoh et al., 1982, 1983). Likewise, high doses of NSAIDs produced antral lesions in hamsters under normal feeding conditions (Kolbasa et al., 1988).

Paroxetine, a selective serotonin (5-HT) reuptake inhibitor (SSRI), is often prescribed for the treatment of depression or mental disorders. Studies have suggested a risk of adverse gastric reactions to SSRIs, showing frequent gastrointestinal bleeding in patients taking SSRIs and a markedly increased risk of bleeding with the coadministration of NSAIDs (Dalton et al., 2003; De Jong et al., 2003; Mort et al., 2006; Lewis et al., 2008; Ahsberg et al., 2010; Dall et al., 2010), although there is controversy about the association (Tata et al., 2005; Itatsu et al., 2011). Consistent with the clinical findings, we found that SSRIs, given as a single injection, markedly aggravated the development of antral lesions in response to

This research was supported in part by the Kyoto Pharmaceutical University's 21st Century Centers of Excellence Program and the Open Research Program from the Ministry of Education, Science, and Culture of Japan.

Article, publication date, and citation information can be found at <http://jpet.aspetjournals.org>.

doi:10.1124/jpet.111.183293.

**ABBREVIATIONS:** NSAID, nonsteroidal anti-inflammatory drug; 5-HT, serotonin; SSRI, selective serotonin reuptake inhibitor; SNRI, serotonin/norepinephrine reuptake inhibitor; PGE, prostaglandin E; COX, cyclooxygenase; SOD, superoxide dismutase; DDC, diethyldithiocarbamate; MPO, myeloperoxidase; SC-560, 5-(4-chloro-phenyl)-1-(4-methoxyphenyl)-3-trifluoromethylpyrazole; SB204070, (1-butyl-4-piperidinyl)methyl-8-amino-7-chloro-1,4-benzodioxane-5-carboxylate.

indomethacin in refed rats (Kojo et al., 2010). Several models of antral lesions have been established with various agents, including NSAIDs, and the pathogenesis of these models is reportedly associated with the impairment of the mucosal antioxidative system, such as a decrease in superoxide dismutase (SOD) activity or an increase in oxyradical production (Oka et al., 1991; Chen et al., 1993; Ohashi et al., 2009). However, the mechanism underlying the aggravation by SSRIs of NSAID-induced antral damage remains unknown.

In the present study, we examined the effect of paroxetine, a SSRI, on the antral mucosa in rat stomachs when administered concomitantly with NSAIDs, in comparison with other antidepressants, such as tricyclic or tetracyclic antidepressants and a 5-HT-norepinephrine reuptake inhibitor (SNRI), and investigated the underlying mechanism of the aggravation by paroxetine of NSAID-induced antral lesions, in relation to endogenous 5-HT and its receptor subtypes. In addition, we examined the effects of various antiulcer drugs, such as antisecretory and mucosal protective drugs as well as antioxidative agents, on the antral lesions produced by indomethacin plus paroxetine.

## Materials and Methods

**Animals.** Male Sprague-Dawley rats (220–260 g; Nippon Charles River, Shizuoka, Japan) were acclimatized to standard laboratory conditions (12-h light-dark cycle, temperature  $22 \pm 1^\circ\text{C}$ ). Experiments were carried out using approximately four to six rats per group under unanesthetized conditions, unless otherwise specified. All experimental procedures involving animals were approved by the Experimental Animal Research Committee of Kyoto Pharmaceutical University.

**Induction of Antral Lesions.** For the induction of antral lesions, the animals were first deprived of food for 24 h, refed for 1 h, given indomethacin (30 mg/kg) subcutaneously 1 h after the refeeding, and killed 6 h later. SSRIs or other antidepressants were given orally 30 min before indomethacin. The SSRIs used were paroxetine (1–10 mg/kg) and fluvoxamine (100 mg/kg), and the other antidepressants were imipramine (a tricyclic antidepressant; 50 mg/kg), maprotiline (a tetracyclic antidepressant; 30 mg/kg), and milnacipran (a SNRI; 30 mg/kg). In some cases, other conventional NSAIDs (diclofenac, 30 mg/kg; flurbiprofen, 30 mg/kg; loxoprofen, 60 mg/kg) or selective cyclooxygenase (COX)-1/COX-2 inhibitors [5-(4-chloro-phenyl)-1-(4-methoxyphenyl)-3-trifluoromethylpyrazole (SC-560), 10 mg/kg; rofecoxib, 10 mg/kg] were given subcutaneously or orally, respectively, together with paroxetine, in place of indomethacin, whereas 5-HT (10 mg/kg) was given subcutaneously together with indomethacin, in place of paroxetine. In addition, the effects of various 5-HT antagonists on the severity of the antral lesions generated by indomethacin (30 mg/kg) plus paroxetine (10 mg/kg) were examined. The 5-HT antagonists used were methysergide (a nonselective 5-HT<sub>1,2,4,5</sub> antagonist; 1 mg/kg), sarpogrelate (a 5-HT<sub>2</sub> antagonist; 100 mg/kg), ondansetron (a 5-HT<sub>3</sub> antagonist; 10 mg/kg), and (1-butyl-4-piperidinyl)methyl-8-amino-7-chloro-1,4-benzodioxane-5-carboxylate (SB204070) (a 5-HT<sub>4</sub> antagonist; 1 mg/kg) (Sanders-Bush and Mayer, 2005), and they were given subcutaneously 30 min before the administration of paroxetine. Furthermore, the effects of various other agents on the antral lesions produced by indomethacin plus paroxetine were examined; antisecretory drugs such as pepstatin (isovaleryl-L-valyl-4-amino-3-hydroxy-5-methyl heptanoyl-L-ananyl-4-amino-3-hydroxy-6-methyl-heptanoic acid, a specific antipeptic agent; 1 mg/kg), atropine (an anticholinergic agent; 3 mg/kg), and omeprazole (a proton pump inhibitor; 30 mg/kg), and mucosal protective drugs such as rebamipide [2-(4-chlorobenzoylamino)-3-[2(1*H*)-quinolinon-4-yl] propionic acid; 10 mg/kg], teprenone (6,10,14,18-tetramethyl-5,9,13,17-nonadecatetraen-2-one; 300 mg/kg), and irsogladine [2,4-diamino-6-(2,5-dichlorophenyl)-

s-triazine malate; 10 mg/kg], as well as antioxidative drugs such as allopurinol (a xanthine oxidase inhibitor; 50 mg/kg) and SOD (30,000 units/kg). In addition, we examined the effect of diethyldithiocarbamate (DDC; 750 mg/kg), a SOD inhibitor, on the antral lesions produced by indomethacin. These agents, except SOD and DDC, were given orally 1 h before indomethacin, whereas SOD or DDC was administered intraperitoneally or subcutaneously, respectively, 1 h before indomethacin.

**Macroscopic Evaluation of Gastric Lesions.** Animals with various treatments were killed for examination of the gastric mucosa by deep ether anesthesia 6 h after the NSAID treatment. The stomach was excised, treated with 2% formalin for fixation of the tissue walls, and then opened along the greater curvature or the antimesenteric attachment, and the mucosa was examined for damage under a dissecting microscope (10 $\times$ ). The area (mm<sup>2</sup>) of macroscopically visible lesions was measured separately for hemorrhagic and non-hemorrhagic damage, summed for each tissue, and used as a lesion score. The person measuring the lesions did not know the treatments given to the animals. In some cases, the gastric mucosa was examined with a light microscope after the administration of indomethacin (30 mg/kg) with or without paroxetine (10 mg/kg). The animals were killed 6 h after the indomethacin treatment, and the stomachs were excised. The tissue samples were then immersed in 10% neutralized formalin, embedded in paraffin, sectioned at 5  $\mu\text{m}$ , and stained with hematoxylin and eosin.

**Measurement of Myeloperoxidase Activity.** Myeloperoxidase (MPO) activity in the antral mucosa was measured as described by Krawisz et al. (1984) with some modifications. The animals were killed 6 h after the administration of indomethacin (30 mg/kg p.o.) with or without paroxetine (10 mg/kg s.c.) given 30 min before. In some cases, ondansetron (10 mg/kg s.c.) was given 1 h before the administration of indomethacin. All blood was withdrawn from the heart by perfusing it with saline, and the stomach was excised and opened along the greater curvature. After the tissue was rinsed with cold saline, the antral mucosa was scraped with glass slides, weighed, and homogenized in a 50-mmol phosphate buffer containing 0.5% hexadecyl-trimethyl-ammonium bromide (pH 6.0; Sigma-Aldrich, St. Louis, MO) and centrifuged at 2000 rpm for 10 min at 4 $^\circ\text{C}$ . MPO activity in the supernatant was determined using *O*-dianisidine dihydrochloride (Sigma-Aldrich). The changes in absorbance at 450 nm were recorded on a microplate reader (VERSAmix; Molecular Devices, Sunnyvale, CA). Sample protein content was estimated by spectrophotometric assay (Pierce Protein Assay Kit; Thermo Fisher Scientific, Rockford, IL). The MPO activity was obtained from the slope of the reaction curve, based on the following equation: specific activity ( $\mu\text{mol H}_2\text{O}_2/\text{min}/\text{mg protein}$ ) = (OD/min)/OD/ $\mu\text{mol H}_2\text{O}_2 \times \text{mg protein}$ .

**Determination of Mucosal PGE<sub>2</sub> Content.** Levels of PGE<sub>2</sub> in the gastric antral mucosa were measured after the oral administration of indomethacin (30 mg/kg) and paroxetine (10 mg/kg), either alone or in combination. The animals were killed under deep ether anesthesia 2 h after the administration of indomethacin or paroxetine, and the antral tissue was isolated, weighed, and placed in a tube containing 100% ethanol plus 0.1 M indomethacin (Futaki et al., 1994). Then, the tissues were homogenized by polytron homogenizer (IKA, Tokyo, Japan) and centrifuged at 10,000 rpm for 10 min at 4 $^\circ\text{C}$ . After the supernatant of each sample had been evaporated with N<sub>2</sub> gas, the residue was resolved in assay buffer and used for the determination of PGE<sub>2</sub>. The concentration of PGE<sub>2</sub> was measured using a PGE<sub>2</sub> enzyme immunoassay kit (GE Healthcare, Chalfont St. Giles, Buckinghamshire, UK).

**Determination of SOD Activity in Gastric Mucosa.** SOD activity was measured in the gastric mucosa, according to the method reported by Ukeda et al. (1997). In brief, the rats were killed under deep ether anesthesia, and the stomachs were removed. After the tissue was rinsed with cold saline, the antral mucosa was scraped with glass slides and kept cold on ice. The mucosal scrapings were weighed, minced, and homogenized in a sucrose buffer solution (0.25

M sucrose, 10 mM Tris-HCl buffer solution, pH 7.4, 1 mM EDTA), the volume of which was approximately six to eight times the tissue weight. After centrifugation at 3500 rpm for 60 min, the supernatant was used for the determination of SOD activity. The absorbance was measured at 450 nm on a Hitachi spectrophotometer (U1100; Hitachi, Ibaraki, Japan), and the results were expressed as units per milliliter per gram of tissue weight. Paroxetine (10 mg/kg) was given orally 30 min before indomethacin (30 mg/kg), whereas ondansetron (10 mg/kg s.c.) or rebamipide (10 mg/kg p.o.) was given 1 h before paroxetine.

**Measurement of Sulfhydryl Content in Gastric Mucosa.** The amount of nonprotein sulfhydryl (GSH) was measured in the antral mucosa of the stomach, according to a modified version of the method originally described by Kaplowitz et al. (1980). After the tissue was rinsed with cold saline, the antral mucosa was scraped with glass slides and kept cold on ice. The mucosal scrapings were weighed, homogenized in 2 ml of phosphate buffer (0.1 M  $\text{NaH}_2\text{PO}_4$  plus 0.25 M sucrose, pH 7.4), and centrifuged at 4000 rpm for 15 min at 4°C. A 0.5-ml aliquot of 25% trichloroacetic acid was added to 1 ml of the supernatant of each sample, and the sample was kept for 30 min at 4°C. After centrifugation at 3000 rpm for 15 min, the supernatant was used to determine GSH content by using 5',5'-dithiobis(2-nitrobenzoic acid). Absorbance was measured at 412 nm on the Hitachi spectrophotometer, and the results were expressed as micromoles per gram of wet tissue. Paroxetine (10 mg/kg) was given orally 30 min before the subcutaneous administration of indomethacin (30 mg/kg), whereas ondansetron (10 mg/kg s.c.) or rebamipide (10 mg/kg p.o.) was given 1 h before paroxetine.

**Determination of Gastric Secretion.** Effects of indomethacin and paroxetine, either alone or in combination, on the secretion of gastric acid and pepsin were examined in pylorus-ligated rats. With the rats under light ether anesthesia, a small incision (5–7 mm) was made along the midline of the abdomen from the xyphoid process, the pyloric portion was exposed, and a silk ligature was applied around the pyloric sphincter (Kolm et al., 1945). The animals were then allowed to recover from the anesthesia. Four hours after the ligation, the animals were killed with an overdose of ether, the stomachs were removed, and the gastric content was collected. After centrifugation for 10 min at 3000 rpm, each sample was measured for volume and titrated with 100 mM NaOH to pH 7.0 for titratable acidity, using an automatic titrator (Commtite 550; Hiranuma, Ibaraki, Japan). The pepsin activity of each sample was measured according to a modified version of the method of Anson (1938) using bovine serum albumin (Wako Pure Chemicals, Osaka, Japan) as a substrate and porcine pepsin (Sigma-Aldrich) as a standard at pH 2.0. The secretion of gastric acid and pepsin was expressed as total acid and pepsin output

per hour ( $\mu\text{Eq/h}$  and  $\text{mg/h}$ ), respectively. Paroxetine (10 mg/kg) was given orally 30 min before pylorus ligation, whereas indomethacin (30 mg/kg) was given subcutaneously 1 h before.

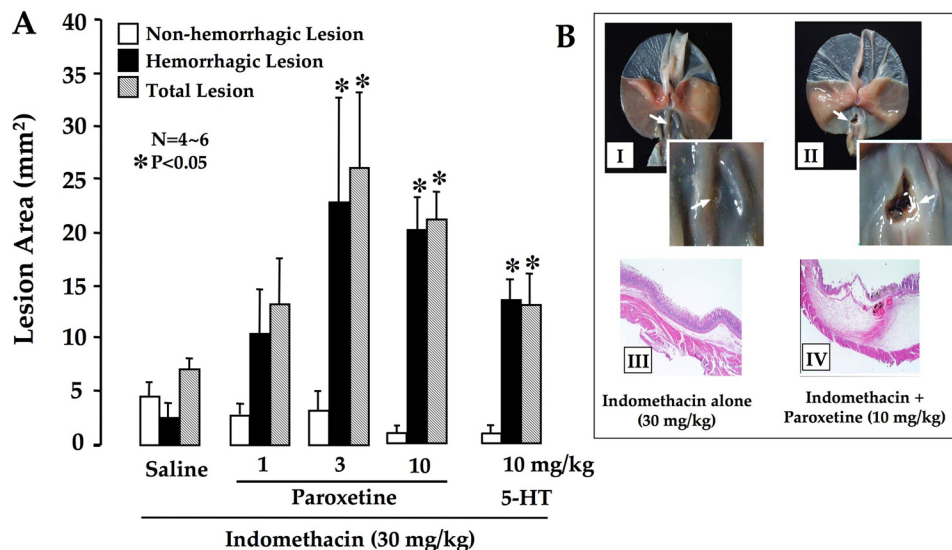
**Preparation of Drugs.** The drugs used were indomethacin, diclofenac, flurbiprofen, loxoprofen, fluvoxamine, maprotiline, SB204070, atropine (Sigma-Aldrich), SC-560 (Cayman Chemical, Ann Arbor, MI), rofecoxib (synthesized in our laboratory), 5-HT, atropine, allopurinol, SOD, DDC (Nacalai Tesque, Kyoto, Japan), sarpogrelate (Mitsubishi Pharm Co., Tokyo, Japan), imipramine, maprotiline (Wako Pure Chemicals), paroxetine (LKT Laboratories, St. Paul, MN), milnacipran (Janssen Pharmaceutica, New Brunswick, NJ), methysergide (Toocris Bioscience, Ellisville, MO), ondansetron (GlaxoSmithKline, Uxbridge, Middlesex, UK), teprenone (Eisai, Tokyo, Japan), irsgladine (Nippon-Shinyaku, Kyoto, Japan), rebamipide (Otsuka, Tokyo, Japan), pepstatin (Banyu Pharm Co., Tokyo, Japan), and omeprazole (Astra Zeneca, Möndal, Sweden). All NSAIDs and COX inhibitors were suspended in a hydroxypropylcellulose solution (Wako Pure Chemicals). Omeprazole was suspended in a 0.5% carboxymethylcellulose solution. Other agents were dissolved in saline. All drugs were prepared immediately before use and administered orally, intraperitoneally, or subcutaneously in a volume of 0.5 ml/100 g body weight. Control animals received the vehicle alone.

**Statistics.** Data are presented as the mean  $\pm$  S.E. for four to six rats per group. Statistical analyses were performed using a two-tailed unpaired *t* test and Dunnett's multiple comparison test, and values of  $P < 0.05$  were regarded as significant.

## Results

### Effect of Paroxetine on Antral Lesions Caused by NSAIDs

Indomethacin (30 mg/kg s.c.) produced nonhemorrhagic antral lesions within 6 h in the refed rats. Pretreatment with paroxetine (1–10 mg/kg p.o.) dose-dependently aggravated the antral lesions generated by indomethacin, the lesion score at 10 mg/kg being significantly greater than the control value (Fig. 1A). In addition, indomethacin alone produced nonhemorrhagic lesions, but additional treatment with paroxetine generated hemorrhagic lesions deep in the mucosa. Paroxetine alone did not cause any injury in the stomach (data not shown). Likewise, 5-HT given subcutaneously at 10 mg/kg also significantly worsened the indomethacin-induced antral damage, the degree of aggravation being equivalent to that caused by paroxetine at 10 mg/kg. Histological examination revealed that indomethacin alone damaged only the



**Fig. 1.** A, effects of paroxetine and 5-HT on the antral lesions produced by indomethacin in rats. Animals fasted for 24 h were refed for 1 h, administered indomethacin at 30 mg/kg s.c. 1 h after the refeeding, and killed 6 h later. Paroxetine (1–10 mg/kg p.o.) or 5-HT (10 mg/kg s.c.) was administered 30 min before indomethacin. Data are presented as the mean  $\pm$  S.E. for four to six rats. \* indicates significant difference from saline,  $P < 0.05$ . B, macroscopic (I and II) and microscopic (III and IV) appearances of the antral lesions generated by indomethacin in rats, in the absence or presence of paroxetine (10 mg/kg). I and III, indomethacin alone; II and IV, indomethacin plus paroxetine. Inserts in I and II show enlargements of the antral lesions. Note that the antral lesions produced by indomethacin were markedly aggravated by the combined administration of paroxetine. Arrows indicate the location of damage.



epithelial cell layer, whereas the combination of indomethacin and paroxetine produced deep damage reaching to the muscularis mucosa, with severe edema in the submucosa (Fig. 1B).

Similar to indomethacin, other NSAIDs such as diclofenac (30 mg/kg), flurbiprofen (30 mg/kg), and loxoprofen (60 mg/kg) given subcutaneously also produced antral lesions in the re-fed rats. Pretreatment of the animals with paroxetine (10 mg/kg p.o.) significantly aggravated the damage, resulting in deep, hemorrhagic lesions (Fig. 2A). The occurrence of antral lesions in re-fed rats was reproduced by the combined oral administration of SC-560 (10 mg/kg) and rofecoxib (10 mg/kg), although neither of these agents alone damaged the antrum (Fig. 2B). In addition, paroxetine did not damage the antral mucosa when given with rofecoxib, but it did provoke a few lesions when given with SC-560, although the damage was mostly nonhemorrhagic. However, the concurrent administration of paroxetine with SC-560 plus rofecoxib produced severe hemorrhagic lesions in the antrum, the lesion

score being equivalent to that produced by paroxetine plus indomethacin.

### Effect of Various Antidepressants on Indomethacin-Induced Antral Lesions

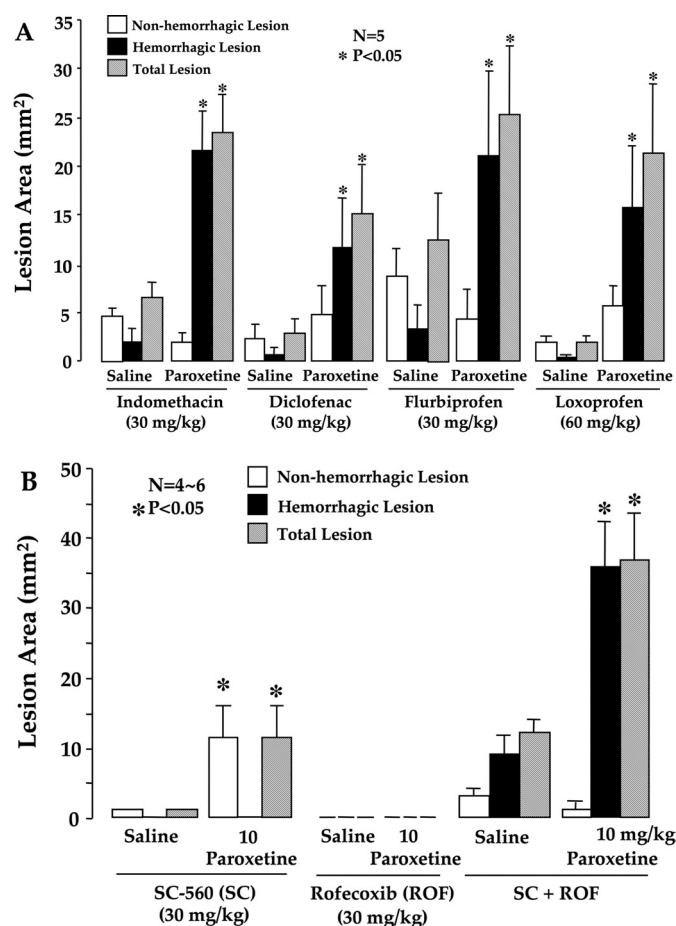
To clarify whether the NSAID-induced antral ulceration is aggravated by other antidepressants, such as tricyclic or tetracyclic drugs, we examined the effects of various antidepressants given orally on the indomethacin-induced antral lesions.

Fulvoxamine (100 mg/kg p.o.), another SSRI, and milnacipran (30 mg/kg), a SNRI, significantly aggravated the antral damage produced by indomethacin (30 mg/kg s.c.) and rendered nonhemorrhagic lesions hemorrhagic, similar to paroxetine (Fig. 3). However, the tricyclic antidepressant imipramine (50 mg/kg) and the tetracyclic antidepressant maprotiline (30 mg/kg) had no effect, with most of the lesions remaining nonhemorrhagic. None of the antidepressants used in this study by itself provoked any injury in the stomach (data not shown).

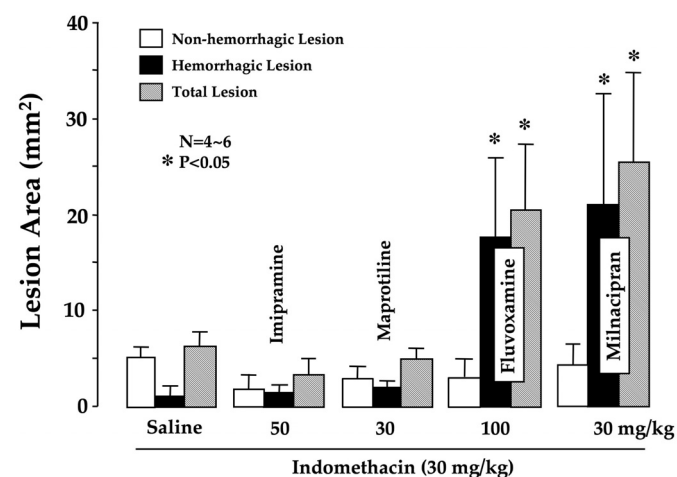
### Effect of 5-HT Receptor Antagonists on the Aggravation of Antral Lesions Produced by Indomethacin Plus Paroxetine

Because the aggravating effect of paroxetine on NSAID-induced antral lesions was mimicked by 5-HT given exogenously, it may be accounted for by endogenous 5-HT accumulated in the tissue caused by the inhibition of neuronal reuptake. Then, to determine which type of 5-HT receptor is associated with the actions of paroxetine, we examined the effects of various 5-HT antagonists on the aggravation by paroxetine of the indomethacin-induced antral lesions.

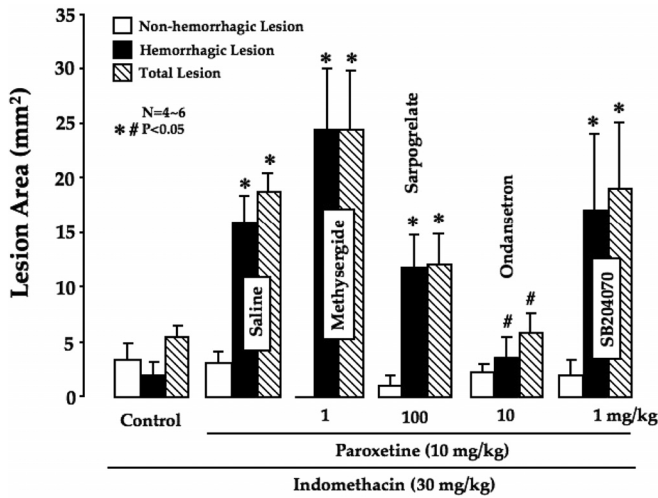
The severity of the antral lesions generated by indomethacin (30 mg/kg s.c.) plus paroxetine (10 mg/kg p.o.) was not significantly affected by prior subcutaneous administration of either the 5-HT<sub>1,2,5,7</sub> receptor antagonist methysergide (1 mg/kg), the 5-HT<sub>2</sub> receptor antagonist sarpgogerate (100 mg/kg), or the 5-HT<sub>4</sub> antagonist SB204070 (1 mg/kg), and the



**Fig. 2.** Effect of paroxetine on the antral lesions produced by conventional NSAIDs (diclofenac, flurbiprofen, and loxoprofen) (A) or selective COX-1 (SC-560) and COX-2 inhibitors (rofecoxib) (B) in rats. A, animals fasted for 24 h were re-fed for 1 h, then administered diclofenac (30 mg/kg), flurbiprofen (30 mg/kg), or loxoprofen (60 mg/kg) subcutaneously 1 h after the refeeding, and killed 6 h later. B, animals fasted for 24 h were re-fed for 1 h, then administered SC-560 (30 mg/kg) and rofecoxib (30 mg/kg) orally, either alone or in combination, 1 h after the refeeding, and killed 6 h later. In both A and B, paroxetine (10 mg/kg p.o.) was administered 30 min before the administration of other materials. Data are presented as the mean  $\pm$  S.E. for four to six rats. \* indicates significant difference from the corresponding saline group,  $P < 0.05$ .



**Fig. 3.** Effects of various antidepressants on the antral lesions produced by the combined administration of indomethacin in rats. Animals fasted for 24 h were re-fed for 1 h, then administered indomethacin (30 mg/kg) subcutaneously 1 h after the refeeding and killed 6 h later. Imipramine (50 mg/kg), maprotiline (30 mg/kg), fulvoxamine (100 mg/kg), or milnacipran (30 mg/kg) was given orally 30 min before indomethacin. Data are presented as the mean  $\pm$  S.E. for four to six rats. \* indicates significant difference from saline,  $P < 0.05$ .



**Fig. 4.** Effects of various 5-HT receptor antagonists on the development of antral lesions induced in rats by the combined administration of indomethacin and paroxetine. Animals fasted for 24 h were refed for 1 h, then administered indomethacin at 30 mg/kg subcutaneously 1 h after the refeeding and killed 6 h later. Paroxetine (10 mg/kg) was given orally 30 min before the administration of indomethacin, whereas various 5-HT antagonists were given subcutaneously 1 h before indomethacin: methysergide (a nonselective 5-HT<sub>1,2,4,5</sub> antagonist; 1 mg/kg), sarpogrelate (a 5-HT<sub>2</sub> antagonist; 100 mg/kg), ondansetron (a 5-HT<sub>3</sub> antagonist; 10 mg/kg), and SB204070 (a 5-HT<sub>4</sub> antagonist; 1 mg/kg). Data are presented as the mean ± S.E. for four to six rats. Significant difference at  $P < 0.05$ , \* from control; # from saline.

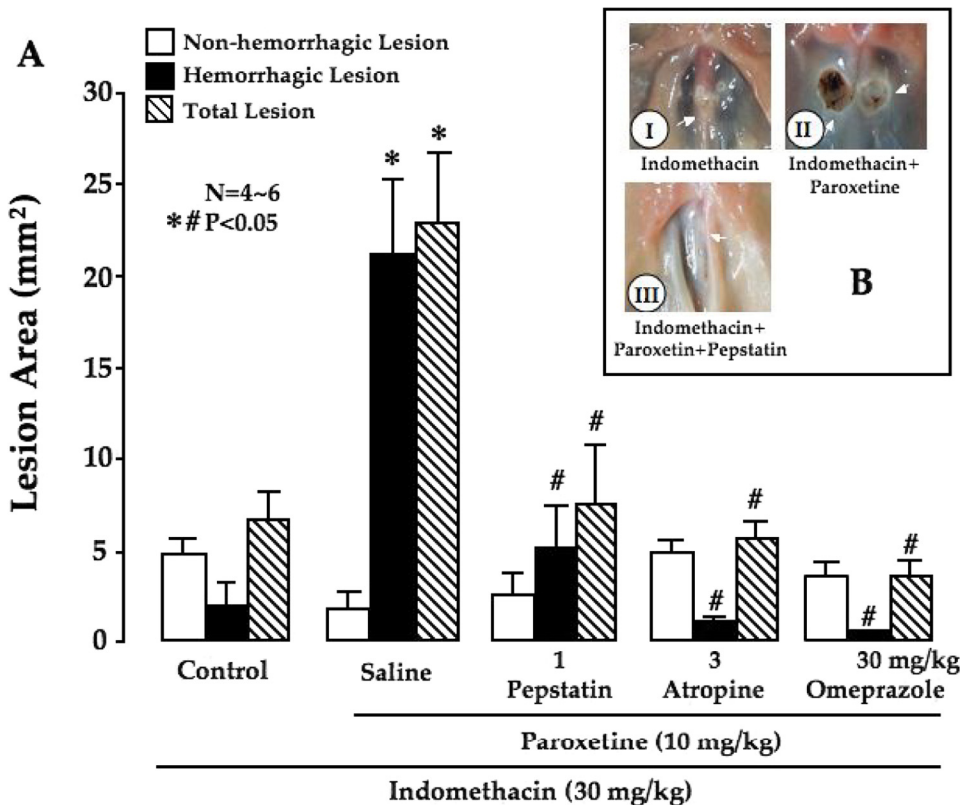
lesion score of hemorrhagic damage as well as total area in these groups were all but equivalent to those in the vehicle-treated group (Fig. 4). However, pretreatment of the animals with ondansetron (10 mg/kg s.c.), the 5-HT<sub>3</sub> receptor antagonist, almost totally abrogated the aggravating effect of proxetine on the indomethacin-induced antral lesions, and the

severity of the lesions was reduced to the level observed in control animals given indomethacin alone. Likewise, the aggravation by milnacipran of the antral lesions was also significantly abrogated by the prior administration of ondansetron (data not shown).

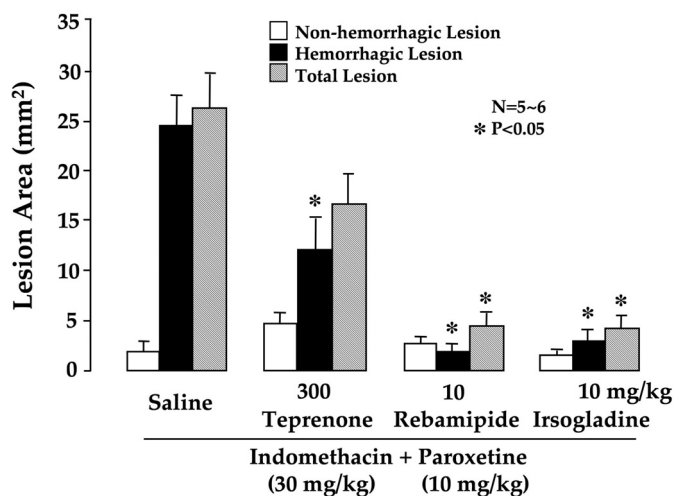
**Effect of Various Agents on Antral Lesions Produced by Indomethacin Plus Paroxetine**

**Antisecretory Drugs.** A proton pump inhibitor, omeprazole (30 mg/kg p.o.), and an anticholinergic agent, atropine (3 mg/kg p.o.), had no effect on the severity of antral damage induced by indomethacin (30 mg/kg s.c.) alone (data not shown), but totally inhibited the aggravation by paroxetine (10 mg/kg p.o.) of these lesions; both hemorrhagic and total lesions were significantly decreased in area compared with those produced by indomethacin plus paroxetine (Fig. 5A). Likewise, the aggravation of indomethacin-induced antral damage was significantly attenuated by pepstatin, a specific pepsin inhibitor (1 mg/kg p.o.). Macroscopically, indomethacin-induced nonhemorrhagic lesions became hemorrhagic on the coadministration of paroxetine, but these changes were apparently inhibited by the prior administration of pepstatin (Fig. 5B). Furthermore, this agent slightly decreased the severity of antral lesions caused by indomethacin alone (data not shown).

**Mucosal Protective Drugs.** Similar to antisecretory drugs, the mucosal protective drugs, such as rebamipide (10 mg/kg p.o.) and irsogladine (10 mg/kg p.o.), significantly inhibited the aggravation by proxetine of indomethacin-induced antral lesions; the areas of hemorrhagic and total lesions were markedly decreased compared with the vehicle-treated group (Fig. 6). Teprenone (300 mg/kg p.o.) also protected against these lesions, although its effect was less than



**Fig. 5. A,** effects of pepstatin, atropine, and omeprazole on the development of antral lesions induced in rats by the combined administration of indomethacin and paroxetine. Animals fasted for 24 h were refed for 1 h, then administered indomethacin at 30 mg/kg subcutaneously 1 h after the refeeding and killed 6 h later. Paroxetine (10 mg/kg) was given orally 30 min before indomethacin. Pepstatin (1 mg/kg), atropine (3 mg/kg), or omeprazole (30 mg/kg) was administered orally 1 h before the administration of indomethacin. Data are presented as the mean ± S.E. for four to six rats. Significant difference at  $P < 0.05$ , \* from control; # from saline. **B,** gross appearances of the antral lesions generated in rats by the combined administration of indomethacin and paroxetine in the absence or presence of pepstatin. I, indomethacin alone; II, indomethacin plus paroxetine; III, indomethacin plus paroxetine plus pepstatin. Note that pepstatin markedly prevented the aggravation by paroxetine of antral lesions induced by indomethacin. Arrows indicate the location of hemorrhagic damage.



**Fig. 6.** Effects of rebamipide, teprenone, and irsogladine on the development of antral lesions induced in rats by the combined administration of indomethacin and paroxetine. Animals fasted for 24 h were refed for 1 h, then administered indomethacin at 30 mg/kg subcutaneously 1 h after the refeeding and killed 6 h later. Paroxetine (10 mg/kg) was given orally 30 min before indomethacin. Rebamipide (10 mg/kg), teprenone (300 mg/kg), or irsogladine (10 mg/kg) was administered orally 1 h before the administration of indomethacin. Data are presented as the mean  $\pm$  S.E. for five to six rats. \* indicates significant difference from saline,  $P < 0.05$ .

that of rebamipide or irsogladine and significant only for the area of hemorrhagic lesions.

**Antioxidative Drugs.** The severity of the antral lesions produced by indomethacin plus paroxetine was significantly reduced when the animals were pretreated with allopurinol (50 mg/kg p.o.), a xanthine-oxidase inhibitor, the inhibition of hemorrhagic and total lesions being 81.0 and 64.3%, respectively (Fig. 7A). Likewise, the area of hemorrhagic lesions was significantly suppressed by pretreatment with SOD (30,000 units/kg i.p.), although the effect on total lesions was not statistically significant. On the other hand, the development of antral lesions in response to indomethacin was significantly exacerbated by cotreatment with DDC (100 mg/kg s.c.), a SOD inhibitor that by itself provoked no damage, and

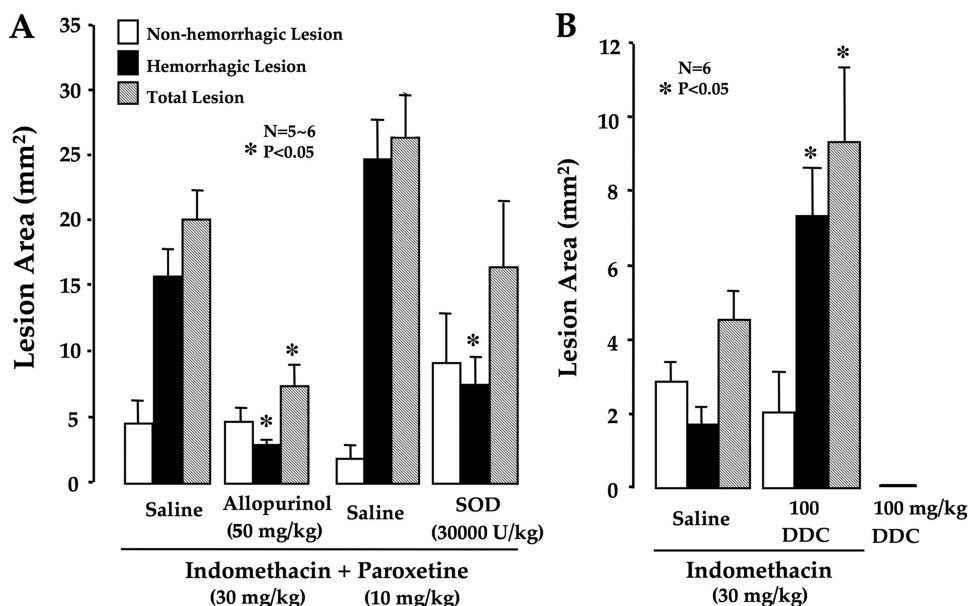
the degree of aggravation was all but equivalent to that by proxetine (Fig. 7B).

### Changes in SOD Activity and GSH Content Induced in Antral Mucosa by Indomethacin Plus Paroxetine

Mucosal SOD activity in the normal rat antrum was  $330 \pm 26$  units/g tissue. In the animals given indomethacin (30 mg/kg s.c.), the SOD activity was low,  $246 \pm 25$  units/g tissue, but not significantly different from that in normal rats (Fig. 8A). However, additional treatment with paroxetine (10 mg/kg p.o.) further decreased the activity to  $223 \pm 19$  units/g tissue, which was significantly lower than the control group. The decreased SOD activity in response to indomethacin plus paroxetine was significantly reverted by pretreatment with ondansetron, a 5-HT<sub>3</sub> antagonist (10 mg/kg s.c.) as well as rebamipide (10 mg/kg p.o.). On the other hand, the amount of GSH in the normal rat antrum was  $2.4 \pm 0.10$   $\mu$ mol/g tissue (Fig. 8B). The mucosal GSH content was slightly but significantly decreased by indomethacin alone. This decrease was further enhanced by additional treatment with paroxetine, the value being  $1.6 \pm 0.08$   $\mu$ mol/g tissue, which is approximately 50% of that in normal rats. The decrease in GSH caused by indomethacin plus paroxetine was almost totally restored by pretreatment with ondansetron and rebamipide, the value being  $2.3 \pm 0.26$  and  $1.9 \pm 0.17$   $\mu$ mol/g tissue, respectively.

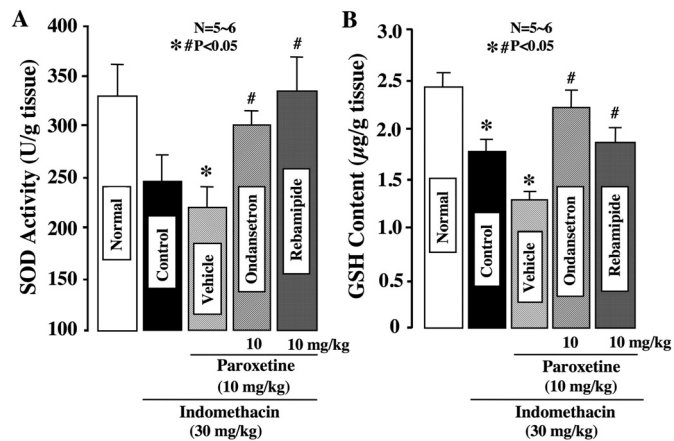
### Effects of Various Agents on Changes in Antral MPO Activity Induced by Indomethacin Plus Paroxetine

The MPO activity in the normal antral mucosa was  $0.096 \pm 0.004$   $\mu$ mol H<sub>2</sub>O<sub>2</sub>/min/mg protein and increased slightly in response to indomethacin (30 mg/kg s.c.), reaching  $0.105 \pm 0.035$   $\mu$ mol H<sub>2</sub>O<sub>2</sub>/min/mg protein (Fig. 9). The activity was further significantly potentiated by additional treatment with paroxetine (10 mg/kg p.o.), the value being  $0.593 \pm 0.062$   $\mu$ mol H<sub>2</sub>O<sub>2</sub>/min/mg protein, which is approximately five times greater than the control level. The increased MPO activity induced by indomethacin plus paroxetine was significantly suppressed by pretreatment with ondansetron (10

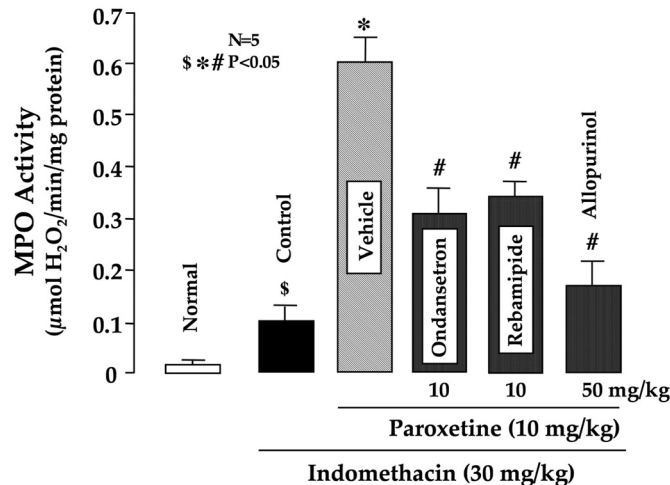


**Fig. 7.** A, effect of allopurinol and SOD on the development of antral lesions induced in rats by the combined administration of indomethacin and paroxetine. Animals fasted for 24 h were refed for 1 h, then administered indomethacin at 30 mg/kg subcutaneously 1 h after the refeeding and killed 6 h later. Paroxetine (10 mg/kg) was given orally 30 min before indomethacin. Allopurinol (50 mg/kg) or SOD (30,000 units/kg) was given orally or intraperitoneally, respectively, 1 h before indomethacin. Data are presented as the mean  $\pm$  S.E. for five to six rats. \* indicates significant difference from the corresponding vehicle,  $P < 0.05$ . B, effect of DDC on the antral lesions produced by indomethacin in rats. Animals fasted for 24 h were refed for 1 h, administered indomethacin at 30 mg/kg subcutaneously 1 h after the refeeding, and killed 6 h later. DDC (100 mg/kg) was given subcutaneously 30 min before indomethacin. Data are presented as the mean  $\pm$  S.E. for six rats. \* indicates significant difference from saline,  $P < 0.05$ .





**Fig. 8.** Effect of indomethacin plus paroxetine on SOD activity (A) and GSH content (B) in the antral mucosa in rats. Animals fasted for 24 h were refed for 1 h, then administered indomethacin at 30 mg/kg subcutaneously 1 h after the refeeding and killed 6 h later. Paroxetine (10 mg/kg) was given orally 30 min before indomethacin, whereas ondansetron (10 mg/kg s.c.) or rebamipide (10 mg/kg p.o.) was given 1 h before indomethacin. Data are presented as the mean  $\pm$  S.E. for five to six rats. Significant difference at  $P < 0.05$ : \*, from normal; #, from vehicle.

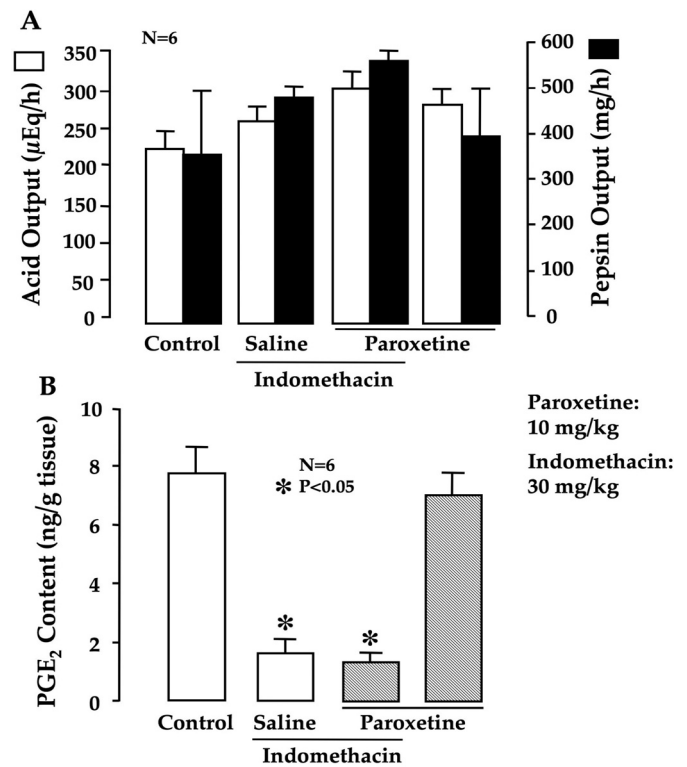


**Fig. 9.** Effects of ondansetron, rebamipide, and allopurinol on changes in antral mucosal MPO activity induced by indomethacin plus paroxetine in rats. Animals fasted for 24 h were refed for 1 h, then administered indomethacin at 30 mg/kg subcutaneously 1 h after the refeeding and killed 6 h later. Paroxetine (10 mg/kg) was given orally 30 min before the administration of indomethacin. Ondansetron (10 mg/kg) was given subcutaneously 1 h before indomethacin, whereas allopurinol (50 mg/kg) or rebamipide (10 mg/kg) was given orally 1 h before. Data are presented as the mean  $\pm$  S.E. for five rats. Significant difference at  $P < 0.05$ : \$, from normal; \*, from control; #, from vehicle.

mg/kg s.c.), rebamipide (10 mg/kg p.o.), and allopurinol (50 mg/kg p.o.). Likewise, the antisecretory agents pepstatin (1 mg/kg p.o.), omeprazole (30 mg/kg p.o.) and atropine (3 mg/kg p.o.) significantly attenuated the increase in MPO activity in response to indomethacin plus paroxetine, and the values in all cases were equivalent to that in the control (data not shown).

#### Effect of Paroxetine on Gastric Secretion and Mucosal PGE<sub>2</sub> Content

Normal rats secreted 5 to 7 ml of gastric juice for 4 h after ligation of the pylorus, the acid and pepsin output being  $235 \pm 30$   $\mu$ Eq/h and  $376 \pm 120$   $\mu$ g/h, respectively. Neither output was significantly affected by the combined adminis-



**Fig. 10.** A, effect of paroxetine on acid/pepsin secretion in pylorus-ligated rats in the absence or presence of indomethacin. The animals were killed 4 h after the pylorus was ligated. Indomethacin (30 mg/kg) was given subcutaneously 1 h before pylorus ligation, whereas paroxetine was given orally 30 min before. Data are presented as the mean  $\pm$  S.E. for six rats. B, effect of paroxetine on PGE<sub>2</sub> content in the rat antral mucosa in the absence or presence of indomethacin. The animals were given indomethacin (30 mg/kg) subcutaneously and killed 2 h later. Paroxetine (10 mg/kg) was given orally 30 min before the administration of indomethacin. Data are presented as the mean  $\pm$  S.E. for six rats. \* indicates significant difference from control,  $P < 0.05$ .

tration of indomethacin (30 mg/kg s.c.) and paroxetine (10 mg/kg intraduodenally) (Fig. 10A). On the other hand, indomethacin significantly decreased PGE<sub>2</sub> content in the antral mucosa in refed animals (Fig. 10B). Paroxetine by itself had no effect on the mucosal PGE<sub>2</sub> content and did not affect the inhibitory effect of indomethacin on PGE<sub>2</sub> production.

## Discussion

The present study showed that paroxetine, a SSRI, markedly aggravated indomethacin-induced antral damage in refed rats, changing superficial/nonhemorrhagic lesions into deep/hemorrhagic lesions. Other NSAIDs similarly produced antral lesions in the refed rats, and this property of NSAIDs was reproduced by the combined administration of selective COX-1 and COX-2 inhibitors. It is noteworthy that the effect of paroxetine was also reproduced by exogenous 5-HT and abrogated by ondansetron, a 5HT<sub>3</sub> antagonist, suggesting the involvement of endogenous 5-HT/5-HT<sub>3</sub> receptors in the pathogenic mechanism. Furthermore, we found that the generation of antral lesions by indomethacin plus paroxetine was suppressed by antisecretory and mucosal protective drugs as well as antioxidative agents. It is assumed that SSRI aggravate NSAID-induced antral damage, probably via the activation of 5-HT<sub>3</sub> receptors, and the mechanism of

aggravation may involve the corrosive action of acid/pepsin as well as a weakening of the antioxidative system.

First, the present study confirmed in experimental animals the clinical findings that the risk of gastric bleeding in patients taking SSRIs was markedly increased by the coadministration of NSAIDs (Dalton et al., 2003; De Jong et al., 2003; Mort et al., 2006; Lewis et al., 2008; Ahsberg et al., 2010; Dall et al., 2010). In this study, we used antral lesions caused by indomethacin in refeed rats (Satoh and Guth, 1981, Satoh et al., 1983), because in patients the incidence of NSAID-induced injury in the antrum is reportedly high (Fries et al., 1989). Satoh and Guth (1981) first showed that indomethacin selectively produced antral lesions in refeed rats without damaging the corpus mucosa. We further showed that this action of indomethacin was mimicked by other conventional NSAIDs such as diclofenac, flurbiprofen, or loxoprofen and was also reproduced by the combined administration of SC-560 and rofecoxib, suggesting the inhibition of both COX-1 and COX-2 as part of the pathogenic mechanism. These results are consistent with the findings that the gastric ulcerogenic properties of NSAIDs are not accounted for solely by the inhibition of COX-1 and requires the inhibition of COX-2 as well (Wallace et al., 2000; Tanaka et al., 2001). As clearly shown in this study, indomethacin produced nonhemorrhagic lesions consisting of mostly superficial damage, but paroxetine aggravated these lesions, causing deep hemorrhagic damage with severe edema in the submucosa. These results support clinical reports suggesting an increased risk of gastric bleeding with the concomitant use of SSRIs and NSAIDs (Dalton et al., 2003; De Jong et al., 2003; Mort et al., 2006; Lewis et al., 2008; Ahsberg et al., 2010; Dall et al., 2010).

Second, we found that the aggravating effect of paroxetine was mimicked by exogenous 5-HT, suggesting the involvement of endogenous 5-HT in this action. In addition, the effect of paroxetine was reproduced by another SSRI, fluvoxamine, and a SNRI, milnacipran, but not by imipramine or maprotiline. It is assumed that the aggravating action on antral lesions is shared by antidepressants showing selective inhibition of the reuptake of 5-HT or 5-HT/norepinephrine. SSRIs may increase the 5-HT concentration in tissue, because of the inhibition of 5-HT reuptake at nerve endings and platelets. As expected, exogenous 5-HT did aggravate antral lesions produced by indomethacin. So far, seven subtypes of 5-HT receptors, 5-HT<sub>1</sub> to 5-HT<sub>7</sub>, have been reported, and some of them show several splicing variants (Sanders-Bush and Mayer, 2005). It would be important to determine which 5-HT receptor subtype is mainly responsible for the aggravating effect of paroxetine. We then examined the influence of various subtype-selective 5-HT antagonists and found that the effect of paroxetine was significantly reversed by ondansetron, a 5-HT<sub>3</sub> antagonist, but not other antagonists, including methysergide (5-HT<sub>1,2,5,7</sub> antagonist), sarpogrelate (5-HT<sub>2</sub> antagonist), and SB204070 (5-HT<sub>4</sub> antagonist). These results suggest that the aggravating effect of paroxetine on NSAID-induced antral lesions is mediated mainly by the activation of 5-HT<sub>3</sub> receptors.

It has been suggested that the gastrointestinal bleeding caused by SSRIs is related to a decrease of 5-HT content in platelet cells (Weinrieb et al., 2005). In the present study, however, exogenous 5-HT exhibited the same effect as paroxetine, and sarpogrelate, an anticoagulant 5-HT<sub>2</sub> antago-

nist, had no influence on the aggravating effect of paroxetine on the antral lesions induced by indomethacin. Thus, it is unlikely that the aggravating action of SSRIs is accounted for by an aberration of platelet aggregation. On the other hand, because it has been reported that 5-HT facilitates the release of acetylcholine via the activation of 5-HT<sub>3</sub> receptors (Cho et al., 1994), it is possible that acetylcholine is involved in the actions of paroxetine. This possibility is supported by the finding that the aggravating effect of paroxetine on antral lesions was markedly inhibited by the anticholinergic agent atropine. In this study, imipramine and maprotiline did not aggravate the indomethacin-induced antral damage in refeed rats. Because these two agents by themselves have anticholinergic effects (Sanders-Bush and Mayer, 2005), the aggravating effect caused by the inhibition of 5-HT reuptake may be negated by these anticholinergic effects. At present, the mechanism underlying this protection remains unknown. Cho et al. (1994) reported that ondansetron suppressed ethanol-induced gastric ulceration via an increase in gastric mucosal blood flow. Kuratani et al. (1994) showed that indomethacin-generated antral lesions were prevented by increasing the mucosal blood flow in the antrum. Thus, it is possible that the protective effect of ondansetron might be brought about, at least partly, by the increase in mucosal blood flow.

Satoh and Guth (1981) reported that indomethacin-induced antral lesions were prevented by supplementation with PGE<sub>2</sub>. They also showed that cimetidine, the histamine H<sub>2</sub> receptor blocker, significantly suppressed the generation of antral lesions at a relatively high dose. Consistent with their results, we found that both omeprazole, atropine, and PGE<sub>2</sub> significantly reduced the severity of antral lesions produced by indomethacin plus paroxetine. Pepstatin, a specific pepsin inhibitor, also markedly suppressed the development of these lesions. Gaw et al. (1995) reported that pepstatin prevented indomethacin-induced antral damage, whereas Nagamachi and Ishihara (1970) reported an important role for pepsin in the pathogenesis of antral lesions in response to cincophen. These results strongly suggest acid/peptic digestion is involved in the aggravating effect of paroxetine on NSAID-induced antral lesions, although the secretion of gastric acid or pepsin was not significantly affected by indomethacin and paroxetine, either alone or in combination. A clinical study also provides evidence that the use of acid-suppressing agents limits the increased risk of upper gastrointestinal tract bleeding associated with coadministration of SSRIs and NSAIDs (de Abajo and García-Rodríguez, 2008).

Several models of antral lesions have been established with agents that affect the mucosal antioxidative system. The pathogenesis of these lesions is reportedly associated with impairment of the mucosal antioxidative system, including a decrease in SOD activity or an increase in oxyradical production (Ogino et al., 1992; Chen et al., 1993). Free radical scavengers such as SOD and GSH attenuate the microvascular damage observed in such models and play a role in maintaining mucosal integrity by counteracting oxygen-derived free radicals (Perry et al., 1986; Loguercio et al., 1993). The increased oxidative stress may be caused not only by an accelerated production of reactive oxygen species but also by a decreased scavenging ability of those molecules. Indeed, the development of DDC-induced antral lesions was prevented by pretreatment with SOD, a radical scavenger,



and worsened by drugs that impair the antioxidative system (Ogino et al., 1992). In the present study, the severity of antral lesions induced by indomethacin plus paroxetine was significantly reduced by pretreatment with allopurinol, an inhibitor of oxyradical production, as well as SOD. Furthermore, a marked reduction in SOD activity and GSH content was observed in the antral mucosa after the administration of indomethacin plus paroxetine, and these responses were significantly reverted by pretreatment with ondansetron at the dose that prevented the aggravating effect of paroxetine. These results suggest that the pathogenesis of the antral lesions is accounted for partly by the impairment of the mucosal antioxidative system. This idea was also supported by the experiment using DDC, an inhibitor of  $\text{Cu}^{2+}$ -dependent SOD activity; this agent further reduced mucosal SOD activity in the presence of indomethacin and markedly increased the severity of antral lesions, although by itself it caused no damage. These findings support the involvement of the impaired antioxidative system in the aggravation by paroxetine of indomethacin-induced antral lesions.

The mucosal protective drugs used in the present study, such as rebamipide, teprenone, and irsogladine, are used to treat gastritis and gastric ulcers in Japan. Among them, rebamipide suppresses inflammatory cell infiltration and the generation of free radicals, exhibits radical-scavenging action, and exerts a potent anti-inflammatory effect (Ogino et al., 1992; Sakurai et al., 2005). Indeed, this agent significantly reduced the severity of antral lesions produced by indomethacin plus paroxetine, together with the suppression of increased MPO activity as well as the restoration of decreased SOD activity and GSH content. These results strongly support the pathogenic importance of the impaired antioxidative system in the development of antral lesions induced by indomethacin plus paroxetine. Irsogladine is also reported to protect the gastric mucosa by enhancing the mucosal integrity of the stomach through the facilitation of gap junctional intracellular communication and increasing the intracellular levels of 3',5'-cAMP (Ueda et al., 1995; Kyojima et al., 2004). On the other hand, teprenone exhibits a protective effect in various models by stimulating the secretion of mucus and the expression of heat shock proteins (Terano et al., 1986; Suemasu et al., 2009). Although the precise mechanisms by which these drugs reduced the severity of the antral lesions in response to indomethacin plus paroxetine remain unknown, it is assumed that these mucosal protective drugs can be used as a prophylactic against gastric bleeding associated with SSRIs.

In conclusion, the present results suggest that paroxetine, a SSRI, aggravated NSAID-induced antral lesions, probably via the activation of  $5\text{HT}_3$  receptors. This action of paroxetine was mimicked by SNRIs but not tricyclic/tetracyclic antidepressants. In addition, the mechanism underlying the aggravation by paroxetine may be attributable, at least partly, to the corrosive action of acid/pepsin as well as the impaired antioxidative system. Finally, antisecretory and mucosal protective drugs may be useful for the prevention of gastric bleeding induced by the concomitant use of SSRIs and NSAIDs.

#### Authorship Contributions

*Participated in research design:* Takeuchi and Tanaka.

*Conducted experiments:* Tanaka, Nukui, Kojo, Gyenge, and Amagase.

*Performed data analysis:* Takeuchi, Tanaka, Nukui, and Amagase.

*Wrote or contributed to the writing of the manuscript:* Takeuchi.

#### References

- Ahsberg K, Höglund P, Kim WH, and von Holstein CS (2010) Impact of aspirin, NSAIDs, warfarin, corticosteroids and SSRIs on the site and outcome of non-variceal upper and lower gastrointestinal bleeding. *Scand J Gastroenterol* **45**: 1404–1415.
- Anson ML (1938) The estimation of pepsin, trypsin, papain and cathepsin with hemoglobin. *J Gen Physiol* **22**:79–89.
- Chen SH, Pan S, Okita K, and Takemoto T (1993) Role of superoxide dismutase in mechanism of diethyldithiocarbamate-induced gastric antral ulcer in rats: protective effect of prostaglandin, cimetidine and pirenzepine. *J Gastroenterol Hepatol* **8**:457–461.
- Cho CH, Koo MW, and Ko JK (1994) Modulatory role of  $5\text{HT}_3$  receptors in gastric function and ethanol-induced mucosal damage in rat stomachs. *Pharmacology* **49**:137–143.
- Dall M, Schaffalitzky de Muckadell OB, Lassen AT, and Hallas J (2010) There is an association between selective serotonin reuptake inhibitor use and uncomplicated peptic ulcers: a population-based case-control study. *Aliment Pharmacol Ther* **32**:1383–1391.
- Dalton SO, Johansen C, Mellekjær L, Nørgård B, Sørensen HT, and Olsen JH (2003) Use of selective serotonin reuptake inhibitors and risk of upper gastrointestinal tract bleeding: a population-based cohort study. *Arch Intern Med* **163**: 59–64.
- de Abajo FJ and García-Rodríguez LA (2008) Risk of upper gastrointestinal tract bleeding associated with selective serotonin reuptake inhibitors and venlafaxine therapy: interaction with nonsteroidal anti-inflammatory drugs and effect of acid-suppressing agents. *Arch Gen Psychiatry* **65**:795–803.
- de Jong JC, van den Berg PB, Tobi H, and de Jong-van den Berg LT (2003) Combined use of SSRIs and NSAIDs increases the risk of gastrointestinal adverse effects. *Br J Clin Pharmacol* **55**:591–595.
- Fries JF, Miller SR, Spitz PW, Williams CA, Hubert HB, and Bloch DA (1989) Toward an epidemiology of gastropathy associated with nonsteroidal anti-inflammatory drug use. *Gastroenterology* **96**:647–655.
- Futaki N, Takahashi S, Yokoyama M, Arai I, Higuchi S, and Otomo S (1994) NS-398, a new anti-inflammatory agent, selectively inhibits prostaglandin G/H synthase cyclooxygenase (COX-2) activity in vitro. *Prostaglandins* **47**:55–59.
- Gaw AJ, Williams LV, Spraggs CF, and Jordan CC (1995) Role of pepsin in the development of indomethacin-induced antral ulceration in the rat. *Aliment Pharmacol Ther* **9**:167–172.
- Itatsu T, Nagahara A, Hojo M, Miyazaki A, Murai T, Nakajima M, and Watanabe S (2011) Use of selective serotonin reuptake inhibitors and upper gastrointestinal disease. *Intern Med* **50**:713–717.
- Kaplowitz N, Kuhlenskamp J, Goldstein L, and Reeve J (1980) Effect of salicylates and phenobarbital on hepatic glutathione in the rats. *J Pharmacol Exp Ther* **212**:240–245.
- Kojo A, Nukui K, Tanaka A, Amagase K, and Takeuchi K (2010) Aggravation by selective serotonin re-uptake inhibitor of antral ulcers induced by indomethacin in rats: Pathogenic importance of impaired anti-oxidative system. *Gastroenterology* **138**(Suppl 1):S497.
- Kolbasa KP, Lancaster C, Olafsson AS, Gilbertson SK, and Robert A (1988) Indomethacin-induced gastric antral ulcers in hamsters. *Gastroenterology* **95**:932–944.
- Kolm R, Komarov SA, and Shay H (1945) Experimental studies on the excretion of neutral red by the stomach. *Gastroenterology* **5**:303–319.
- Krawisz JE, Sharon P, and Stenson WF (1984) Quantitative assay for acute intestinal inflammation based on myeloperoxidase activity. Assessment of inflammation in rat and hamster models. *Gastroenterology* **87**:1344–1350.
- Kunikata T, Araki H, Takeeda M, Kato S, and Takeuchi K (2001) Prostaglandin E prevents indomethacin-induced gastric and intestinal damage though different EP receptor subtypes. *J Physiol Paris* **95**:157–163.
- Kuratani K, Kodama H, and Yamaguchi I (1994) Enhancement of gastric mucosal blood flow by  $\beta$ -3 adrenergic agonists prevents indomethacin-induced antral ulcer in the rat. *J Pharmacol Exp Ther* **270**:559–565.
- Kyojima T, Noda K, Oka M, and Ukai Y (2004) Irsogladine, an anti-ulcer drug, suppresses superoxide production by inhibiting phosphodiesterase type 4 in human neutrophils. *Life Sci* **76**:71–83.
- Lanza FL (1984) Endoscopic studies of gastric and duodenal injury after the use of ibuprofen, aspirin, and other nonsteroidal anti-inflammatory agents. *Am J Med* **77**:19–24.
- Lewis JD, Strom BL, Localio AR, Metz DC, Farrar JT, Weinrieb RM, Nessel L, Brensinger C, and Kimmel SE (2008) Moderate and high affinity serotonin reuptake inhibitors increase the risk of upper gastrointestinal toxicity. *Pharmacoeconomic Drug Saf* **17**:328–335.
- Loguercio C, Taranto D, Beneduce F, del Vecchio Blanco C, de Vincentiis A, Nardi G, and Romano M (1993) Glutathione prevents ethanol induced gastric mucosal damage and depletion of sulfhydryl compounds in humans. *Gut* **34**:161–165.
- Mort JR, Aparasu RR, and Baer RK (2006) Interaction between selective serotonin reuptake inhibitors and nonsteroidal antiinflammatory drugs: review of the literature. *Pharmacotherapy* **26**:1307–1313.
- Nagamachi Y and Ishihara K (1970) Role of the hypothalamus in the pathogenesis of cinchophen-induced gastric ulcers in dogs. *Am J Dig Dis* **15**:1083–1089.
- Ogino K, Hobarata T, Ishiyama H, Yamasaki K, Kobayashi H, Izumi Y, and Oka S (1992) Antiulcer mechanism of action of rebamipide, a novel antiulcer compound, on diethyldithiocarbamate-induced antral gastric ulcers in rats. *Eur J Pharmacol* **212**:9–13.
- Ohashi Y, Aihara E, Takasuka H, Takahashi K, and Takeuchi K (2009) Antral ulcers induced by alendronate, a nitrogen-containing bisphosphonate, in rat stomachs—prophylactic effect of rebamipide. *J Physiol Pharmacol* **60**:85–93.
- Oka S, Ogino K, Hobarata T, Yoshimura S, Okazaki Y, Takemoto T, and Iida Y (1991) Effects of various mucosal protective drugs on diethyl dithiocarbamate-induced antral ulcer in rats. *Eur J Pharmacol* **197**:99–102.
- Perry MA, Wadhwa S, Parks DA, Pickard W, and Granger DN (1986) Role of oxygen

- radicals in ischemia-induced lesions in the cat stomach. *Gastroenterology* **90**:362–367.
- Sakurai K, Osaka T, and Yamasaki K (2005) Rebamipide reduces recurrence of experimental gastric ulcers: role of free radicals and neutrophils. *Dig Dis Sci* **50**:S90–S96.
- Sanders-Bush E and Mayer S (2005) 5-Hydroxytryptamine (serotonin): receptor agonists and antagonists, in *Goodman & Gilman's The Pharmacological Basis of Therapeutics* (Brunton L, Lazo JS and Parker KL, eds), 11th edition, pp 297–315, McGraw-Hill, New York.
- Satoh H and Guth PH (1981) Role of gastric acid and prostaglandins in the formation of gastric antral ulcers produced by indomethacin in the rat. *Prostaglandins* **21**:131–137.
- Satoh H, Guth PH, and Grossman MI (1982) Role of food in gastrointestinal ulceration produced by indomethacin in the rat. *Gastroenterology* **83**:210–215.
- Satoh H, Guth PH, and Grossman MI (1983) Role of bacteria in gastric ulceration produced by indomethacin in the rat: cytoprotective action of antibiotics. *Gastroenterology* **84**:483–489.
- Suemasu S, Tanaka K, Namba T, Ishihara T, Katsu T, Fujimoto M, Adachi H, Sobue G, Takeuchi K, Nakai A, et al. (2009) A role for HSP70 in protecting against indomethacin-induced gastric lesions. *J Biol Chem* **284**:19705–19715.
- Tanaka A, Araki H, Komoike Y, Hase S, and Takeuchi K (2001) Inhibition of both COX-1 and COX-2 is required for development of gastric damage in response to nonsteroidal anti-inflammatory drugs. *J Physiol Paris* **95**:21–27.
- Tanaka A, Hase S, Miyazawa T, and Takeuchi K (2002) Up-regulation of COX-2 by inhibition of COX-1: a key to NSAID-induced intestinal damage. *J Pharmacol Exp Ther* **300**:754–761.
- Takeuchi K, Ueki S, and Okabe S (1986) Importance of gastric motility in the pathogenesis of indomethacin-induced gastric lesions in rats. *Dig Dis Sci* **31**:1114–1122.
- Tata LJ, Fortun PJ, Hubbard RB, Smeeth L, Hawkey CJ, Smith CJ, Whitaker HJ, Farrington CP, Card TR, and West J (2005) Does concurrent prescription of selective serotonin reuptake inhibitors and non-steroidal anti-inflammatory drugs substantially increase the risk of upper gastrointestinal bleeding? *Aliment Pharmacol Ther* **22**:175–181.
- Terano A, Hiraishi H, Ota S, and Sugimoto T (1986) Geranylgeranylacetone, a novel anti-ulcer drug, stimulates mucus synthesis and secretion in rat gastric cultured cells. *Digestion* **33**:206–210.
- Ueda F, Ban K, and Ishima T (1995) Irsogladine activates gap-junctional intercellular communication through M<sub>1</sub> muscarinic acetylcholine receptor. *J Pharmacol Exp Ther* **274**:815–819.
- Ukeda H, Maeda S, Ishii T, and Sawamura M (1997) Spectrophotometric assay for superoxide dismutase based on tetrazolium salt 3'-1-(phenylamino)-carbonyl-3,4-tetrazolium]-bis(4-methoxy-6-nitro) benzenesulfonic acid hydrate reduction by xanthine-xanthine oxidase. *Anal Biochem* **251**:206–209.
- Wallace JL, McKnight W, Reuter BK, and Vergnolle N (2000) NSAID-induced gastric damage in rats: requirement for inhibition of both cyclooxygenase 1 and 2. *Gastroenterology* **119**:706–714.
- Weinrieb RM, Auriacombe M, Lynch KG, and Lewis JD (2005) Selective serotonin re-uptake inhibitors and the risk of bleeding. *Expert Opin Drug Safety* **4**:337–344.

---

**Address correspondence to:** Dr. Koji Takeuchi, Division of Pathological Sciences, Department of Pharmacology and Experimental Therapeutics, Kyoto Pharmaceutical University, Misasagi, Yamashina, Kyoto 607-8414, Japan. E-mail: takeuchi@mb.kyoto-phu.ac.jp

---