

# Morphometric characteristics of the asterion and the posterolateral surface of the skull: relationship with dural venous sinuses and neurosurgical importance

Salvador Galindo-de León,<sup>1</sup> Alejandra Nohemí Hernández-Rodríguez,<sup>1</sup> Rodolfo Morales-Ávalos,<sup>1</sup> María del Carmen Theriot-Girón,<sup>2</sup> Rodrigo Enrique Elizondo-Omaña,<sup>1</sup> Santos Guzmán-López<sup>1</sup>

## Abstract

**Background:** Knowledge of the location and morphometry of the lateral venous sinus (transverse and sigmoid) and their relationship with the asterion and other surface anatomic landmarks is imperative for posterolateral approaches to the posterior cranial fossa to avoid vascular structure injury and surgical complications. We undertook this study to determine a secure anatomic area for drilling that allows entry into the posterior cranial fossa without damaging adjacent structures and study the morphometric characteristics of the asterion, the lateral sinus and bony landmarks of the posterolateral surface of the skull.

**Methods:** Using a 1.3-mm drill, both sides of 88 dry skulls (176 hemispheres) were drilled. The anatomic landmarks studied were the asterion, apex of the mastoid process, suprameatal spine, Frankfurt horizontal plane, posterior root of the zygomatic arch, external occipital protuberance and its relationship with the transverse sinus.

**Results:** Type I asterion is prevalent in 74.4%. In 82.4% of the specimens, the lateral venous sinus can be found lower than the asterion in 12.5% and higher in 5.1%.

**Conclusions:** Using the data from this and other studies, the initial drill must be placed 15 mm below the asterion and 15 mm posterior to it to reduce the risk of injury to the lateral venous sinus.

**Key words:** asterion, posterior cranial fossa, venous sinus, morphometry, skull.

## Introduction

During surgical approaches, consideration should be given to the superficial anatomic reference points of the posterior cranial fossa that allow the topographic location of the intracranial structures to avoid causing injury or accessing them.

The posterior cranial fossa is framed by important venous structures such as the superior, occipital and lateral petrous sinuses and its confluence (Herophilus' press). The lateral venous sinus is large and originates in the confluence of the sinuses. The right lateral venous sinus tends to be the continuation of the superior sagittal sinus and the left the continuation of the straight sinus. Each lateral venous sinus has an inferolateral pathway in the lateral sulcus of the occipital portion that has a small curve with its convexity where the lateral margin of the tentorium is inserted until reaching the base of the petrous pyramid (petromastoideo channel). This channel is in relationship with the mastoid portion where it curves inferiorly and forms an "S", for which reason it is called the sigmoid sinus. It continues its trajectory towards the jugular foramen where it extends with the bulb of the internal jugular vein. This allows us to recognize three parts in the lateral sinus: one horizontal (transverse sinus), an elbow or knee and a descending (sigmoid sinus).<sup>1</sup>

The anatomic points of reference to analyze the topography of the posterolateral surface of the skull are asterion, external occipital protuberance, suprameatal crest, apex of the mastoid process, root of the zygomatic arch, Frankfurt horizontal plane, and the mastoid foramen.<sup>2-4</sup> These reference points are of great importance in surgical procedures

<sup>1</sup> Departamento de Anatomía Humana, Facultad de Medicina y Hospital Universitario Dr. José Eleuterio González, Monterrey, Nuevo León (NL), Mexico

<sup>2</sup> Departamento de Anatomía Humana, Facultad de Odontología, Universidad Autónoma de Nuevo León, Monterrey, Nuevo León, México

### Correspondence:

Dr. Rodrigo E. Elizondo Omaña  
Departamento de Anatomía Humana  
Facultad de Medicina  
Universidad Autónoma de Nuevo León  
Ave. Madero s/n, Col. Mitras Centro  
Monterrey 64460, Nuevo León, México  
Tel: (52) 81-83294171  
E-mail: rod\_omana@yahoo.com

Received: 1-28- 2013

Accepted: 13-15-2013

to locate the site where the initial trepanning will be carried out. The surgical importance of the posterior cranial fossa lies in its dense collection of neurovascular structures housed in a small, rigid space, which makes the invasive approach very delicate and prone to accidents or medical errors in surgery.

The proximity of large venous sinuses, emissary veins that cross the posterior portion of the occipital squama and the large number of noncollapsible veins explain the high incidence of bleeding, air embolism, thrombosis and sepsis in neurosurgical interventions of the posterior cranial fossa. In addition to the possible implications for endovascular procedures, these facts should take into consideration by the surgeon.<sup>5,6</sup>

Knowledge of the location and morphometric characteristics of the lateral venous sinus (transverse and sigmoid) and their relationship with it and other superficial anatomic landmarks is essential during posterolateral approaches to the posterior cranial fossa. This facilitates locating the site in which the initial trepanning will be performed (strategic drilling), as well as to be able to plan the course of surgery. All this gives the neurosurgeon the knowledge necessary to avoid injuring these vascular structures, which is a cause of surgical failure and subsequent surgical complications with severe repercussions.

The aim of this study is to determine a safe anatomic site to carry out a trepanning that would allow entry to the posterior cranial fossa without damaging adjacent structures and to study the morphometric characteristics of the asterion, the lateral sinus and bony landmarks of the posterolateral surface of the skull.

## Materials and Methods

An observational, cross-sectional descriptive study based on the analysis of 176 structurally intact dry hemicraniums without any evident pathology or abnormality belonging to the Department of Human Anatomy of the School of Medicine and Dentistry of the Universidad Autónoma de Nuevo León. Two independent observers analyzed and classified the morphology of the asterion based on the accepted conventional classification.<sup>7</sup>

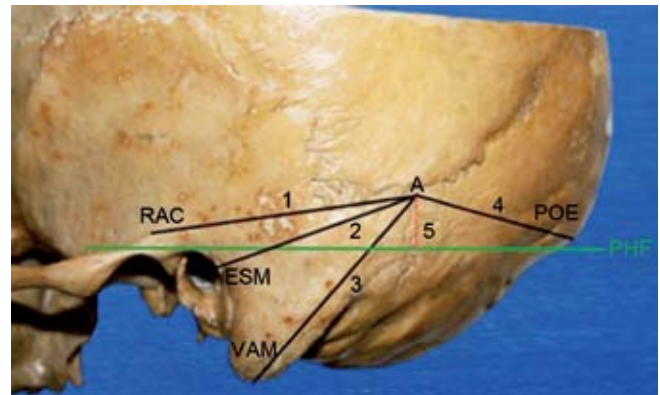
- Asterion type I*: union of the parietomastoid, lambdoid and occipitomastoid sutures
- Asterion type II*: sutural bone (Wormian) located among the other bones that make up the asterion

The morphometric characteristics of the posterolateral surface of the skull were recorded, among them the distance from the asterion towards: *a*) root of the zygomatic arch (A-RZA), *b*) suprameatal spine (A-SMS), *c*) apex of the mastoid process (A-AMP), *d*) external occipital protuber-

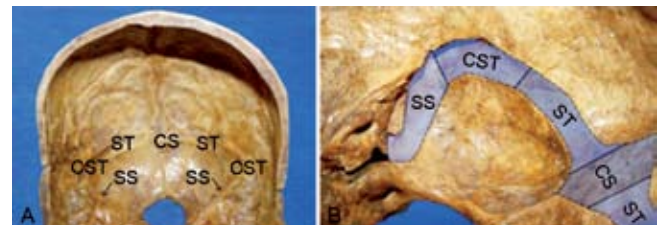
ance (A-EOP) and *e*) horizontal Frankfurt plane (A-HFP) (Figure 1).

Also recorded were the morphometry and morphology of the sulcus of the lateral venous sinus. The most important parameter of the measurement was the width of the lateral venous sinus canal in three sections: transverse sinus, elbow of the sinus and sigmoid sinus (Figure 2). At the end the center of the asterion in each one of the 176 hemicraniums studied was perforated with a drill of 1.3 mm in diameter so that it would perforate the bone perpendicular to its surface. In cases where the asterion was classified as type II, the perforation was carried out in the center of the Wormian bone. The distance of the resulting hole on the internal surface of the skull (endocranium) was recorded in relation with the sulcus of the lateral venous sinus (Figure 3). A Vernier digital millimeter dial caliper with a precision of 0.01 mm data was used for each of the piece studied and all measurements were reported in millimeters.

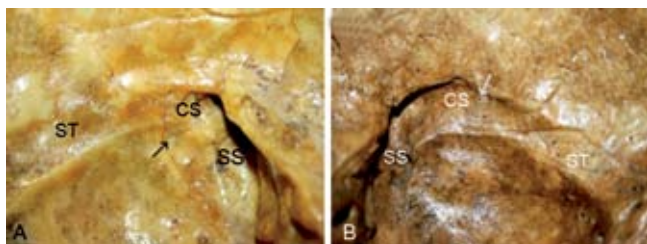
The protocol was approved by the Local Committee for Health Research (registration AH12-001). There was no



**Figure 1.** View of the left side of the posterolateral base of the skull. Measurements from the asterion towards: 1. Root of the zygomatic arch (A-RZA), 2. Suprameatal spine (A-SMS), 3. Apex of the mastoid process (A-AMP), 4. External occipital protuberance (A-EOP) and 5. Frankfurt horizontal plane (A-HFP).



**Figure 2.** *a*) View of bilateral venous sinuses where one can see: confluence of the sinuses (CS), the transverse sinus (TS) and the elbow of the transverse sinus (ETS). *b*) Right unilateral endocranial view of the transverse venous sinus. In this view one can better appreciate the "S" trajectory of the sigmoid sinus (SS).



**Figure 3.** a) Right unilateral endocranial view in which the perforation (arrow) can be seen, which shows the location of the asterion at the level of the transverse venous sinus. b) Left unilateral endocranial view in which a perforation (arrow) can be appreciated that shows the location of the asterion below the transverse venous sinus.

source of external funding; hence, no conflicts of interest are reported.

The measurement parameters were analyzed with the IBM computer program SPSS Statistics 20.0 for Windows XP version. For each measurement parameter, the mean and standard deviation were reported.

## Results

We analyzed the morphometric characteristics of the asterion, the lateral sinus and bony landmarks of the posterolateral surface of the skull for 176 hemispheres. The prevalence of type I asterion was 74.4%, whereas for type II was 25.6%. Ranges and averages for the morphometric characteristics are shown in Table 1.

The mean obtained of the widths for the three portions of the lateral sinus were width of the transverse sinus 7.87 mm ( $\pm 1.67$ ), width of the elbow of the lateral sinus 9.09 mm

**Table 1.** Morphometries of the asterion according to the reference point of the cranium

Morphometric parameters	Total	
	Mean (mm)	SD (mm)
A-RZA	54.74	4.46
A-AMP	51.53	4.97
A-SMS	44.16	5.81
A-HFP	5.49	3.2
A-OEP	61.51	7.44

Mean and standard deviation (SD) of the distances between the asterion and anatomic reference points studied. Distances are expressed in millimeters.

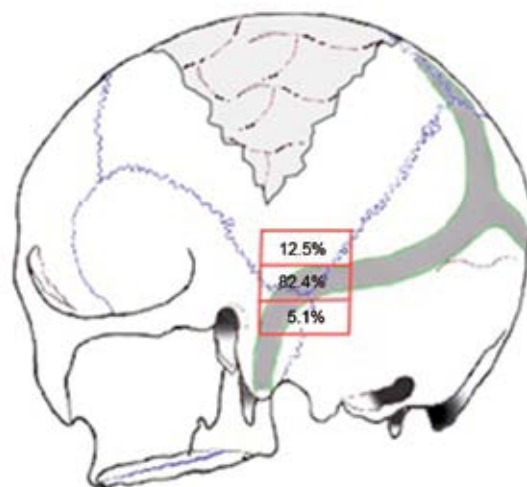
A, asterion; RZA, root of the zygomatic arch; AMP, apex of the mastoid process; SMS, suprameatal spine; HFP, horizontal Frankfurt plane; OEP, occipital external protuberance.

( $\pm 1.66$ ) and width of the sigmoid sinus 8.4 mm ( $\pm 2.03$ ). The distance of the asterion with respect to the lateral venous sinus is shown in Table 2. The transverse sinus is located in the asterion in 82.4% of the cases, above the asterion in 12.5% and below it in 5.1% (Figure 4).

**Table 2.** Location of the TS with respect to different types of asterion in three planes: level with the asterion, higher than the asterion, and below the asterion

Location of the TS	Asterion		Total
	Type I	Type II	
Level	60.2%	22.2%	82.4%
Higher	9.7%	2.8%	12.5%
Below	4.5%	0.6%	5.1%

TS, transverse sinus.



**Figure 4.** Location of the lateral venous sinus in relationship with the asterion (independent of type I and II).

## Discussion

In the posterolateral approaches to the posterior fossa, in order to avoid injury, it is essential to consider the surface topography of the venous sinuses. For the neurosurgeon it is extremely useful to know the exact location of these structures and, in particular, their relationship to bony landmarks used in these approaches. Some authors have looked for and established these topographical landmarks to locate the different portions of the lateral venous sinus.

In our study, distances obtained from the asterion to bony landmarks (root of the zygomatic arch, apex of the mastoid process, suprameatal spine, Frankfurt horizontal plane and external occipital protuberance) are consistent with those found by other researchers (Table 3). The location of bony landmarks in Mexican skulls coincides with those found in other populations.

**Table 3.** Bony relation of the asterion specific to the cranium (different studies carried out in various populations)

Authors	A-RZA	A-AMP	A-SMS	A-HFP	A-OEP
Day et al. (2000) <sup>11</sup>	53.88 (±5.09)	49.20 (±4.68)	43.92 (±4.89)	--	--
Martínez et al. (2005) <sup>1</sup>	55.42 (±4.92)	49.70 (±4.80)	44.80 (±5.61)	--	64.40 (±6.78)
Ucerler and Govsa (2006) <sup>9</sup>	54.60 (±5.12)	51.12 (±5.06)	45.20 (±5.56)	10.30 (±6.5)	--
Galindo-de León et al. (this study) (2012)	54.74 (±4.46)	51.33 (±4.97)	44.16 (±5.81)	6.49 (±3.2)	7.44 (±7.44)

Note: Distances are expressed in millimeters.

A-RZA (asterion-root of the zygomatic arch), A-AMP (asterion-apex of the mastoid proces), A-SMS (asterion-suprmeatal spine), A-HFP (asterion-horizontal Frankfurt plane), A-OEP (asterion-occipital external protuberance).

In general, we agree that the confluence of sinuses is between 5 and 10 mm above the external occipital protuberance. Martínez et al.<sup>1</sup> found that the transverse venous sinus is located on the outer circumference of the tentorium, on a line stretched from the suprmeatal spine to the external occipital protuberance. The sigmoid sinus is located on a line drawn from a vertex of the mastoid and follows its superior axis, subsequently reaching the asterion. At the crossing point of these two lines, the elbow of the lateral sinus is found.

These relationships lose their value in patients with developmental abnormalities of the posterior fossa as in Chiari malformation and Dandy-Walker syndrome. What is typical is that the tentorium will suffer a caudal displacement due to development of the brain and is placed in its definitive position at the third month of intrauterine life. Alterations in this displacement make the final position of the tentorium varied and, therefore, the situation of the sinuses in relation to it.<sup>8</sup> Various anatomic studies in fresh cadavers and dry skulls show that the relationship of the asterion with the

transverse sinus is variable and somewhat different from what is classically described (Table 4).

Martínez et al.<sup>1</sup> and Ucerler et al.<sup>9</sup> reported that the asterion is found in a posterosuperior relationship with the mastoid process and, in depth, corresponds with the inferior border of the transverse portion of the lateral sinus. Therefore, in posterolateral approaches to the posterior fossa, some neurosurgeons suggest that the opening of the trepanning should be located from below and behind the asterion away from the sinus.

Uz et al.<sup>10</sup> found that in 54% of the cases the transverse sinus was located at the level of the asterion and in 44% above it, in the dura of the posterior fossa. For Day et al., in between 55 and 61% of the cases the transverse sinus is located at the level of the asterion.<sup>11-13</sup> For Martínez et al. the percentage of cases where the transverse sinus is found at the level of the asterion are somewhat higher (87.8%).<sup>1</sup>

Our findings are consistent with these studies in regard to the higher percentages of finding the transverse sinus at the level of the asterion (82.4%) and a close similarity with the results by Martínez et al., which suggest a high prevalence of finding the transverse sinus at the level of the asterion in Mexican skulls. Therefore, it is safe to perform initial drilling placed between 15 and 25 mm posteroinferior to the asterion. This prevents injuring some neurovascular structures.

In conclusion, the prevalence of the type I asterion is three times greater than that of type II asterion. Therefore, there is a 60.2% probability that the transverse sinus is found at the level of the asterion. The most relevant bony landmarks for locating the asterion are the root of the zygomatic arch and the apex of the mastoid process. The transverse sinus is located in 82.4% of cases at the level of the

**Table 4.** Relationship of the TS with the asterion (different studies were done in various populations)

Study	Level of TS (%)	Below TS (%)	Above TS (%)
Day et al. (2000) <sup>11</sup>	61.0	39.0	--
Uz A et al. (2001) <sup>10</sup>	54.0	44.0	2.0
Martínez F et al. <sup>1</sup> (2005)	76.2	23.8	--
Galindo-de León et al. (present study) (2012)	82.4	12.5	5.1

TS, transverse sinus.

asterion (independent of the type of asterion) so the initial drilling should be done away from it.

With the results obtained it can be observed that the transverse sinus has an average width of 7.87 mm ( $\pm 1.67$ ) and the elbow of the transverse sinus 9.09 mm ( $\pm 1.66$ ). Initial drilling should be located from 15 to 25 mm in the posteroinferior direction of the asterion to avoid any type of injury to the venous sinus. The zone of maximal safety for initial drilling, which would avoid any type of injury to the anatomic structure, is from 21.42 mm ( $\pm 2.38$ ) following a posterior and inferior trajectory to the asterion.

### References

1. Martínez F, Laxague A, Vida L, Prinzo H, Sgarbi N, Soria VR, et al. Anatomía topográfica del asterion. *Neurocirugía* 2005;16:441-446.
2. Bozbuga M, Boran BO, Sahinoglu K. Surface anatomy of the posterolateral cranium regarding the localization of the initial burr-hole for a retrosigmoid approach. *Neurosurg Rev* 2006;29:61-63.
3. Mwachaka PM, Hassanali J, Odula PO. Anatomic position of the asterion in Kenyans for posterolateral surgical approaches to cranial cavity. *Clin Anat* 2010;23:30-33.
4. Tubbs RS, Elton S, Grabb P, Dockery SE, Bartolucci A, Oakes WJ. Analysis of the posterior fossa in children with the Chiari 0 malformation. *Neurosurgery* 2001;48:1050-1055.
5. Avci E, Kocaogullar Y, Fossett D, Caputy A. Lateral posterior fossa venous sinus relationships to surface landmarks. *Surg Neuro* 2003;59:392-397.
6. Tubbs RS, Loukas M, Shoja MM, Bellew MP, Cohen-Gadol AA. Surface landmarks for the junction between the transverse and sigmoid sinuses: application of the "strategic" burr hole for suboccipital craniotomy. *Neurosurgery* 2009;65:37-41.
7. Morales-Avalos R, Aguilar-Alvarado MV, Elizondo-Omaña RE, Guzmán-López S. Estudio morfológico del pterion y asterion en cráneos adultos mexicanos. *Rev Arg de Anat Clín* 2011;3:77-83.
8. Sarnat HB. Disorders of segmentation of the neural tube: Chiari malformations. *Handb Clin Neurol* 2007;87:89-103.
9. Ucerler H, Govsa F. Asterion as a surgical landmark for lateral cranial base approaches. *J Craniomaxillofac Surg* 2006;34:415-420.
10. Uz A, Ugur HC, Tekdemir I. Is the asterion a reliable landmark for the lateral approach to posterior fossa? *J Clin Neurosci* 2001;8:146-147.
11. Day JD, Kellogg JX, Tschabitscher M, Fukushima T. Surface and superficial surgical anatomy of the posterolateral cranial base: significance for surgical planning and approach. *Neurosurgery* 1996;38:1079-1084.
12. Day JD, Tschabitscher M. Anatomic position of the asterion. *Neurosurgery* 1998;42:198-199.
13. Day JD, Manfred T. Anatomic position of the asterion: anatomical report. *Neurosurgery* 1998;42:198-199.