

# Serum hyaluronan and hyaluronidase: very early markers of toxic liver injury

Joseph George<sup>a</sup>, Robert Stern<sup>b,\*</sup>

<sup>a</sup>Division of Molecular Medicine, Department of Medicine, Columbia University, New York, NY 10032, USA

<sup>b</sup>Department of Pathology, School of Medicine, University of California, San Francisco, S-564, San Francisco, CA 94143-0511, USA

Received 14 February 2003; received in revised form 24 May 2004; accepted 24 May 2004

## Abstract

**Background:** Dimethylnitrosamine (DMN), a potent hepatotoxin, administered to rats, provides a convenient model for toxic liver injury. Indicators of early liver injury are important clinically, for surveillance, for screening new drugs that are potentially hepatotoxic and for identifying drugs that protect against liver injury. Both cirrhosis and wound healing culminate in deposition of fibrous connective tissue and scarring. Increased hyaluronan (HA) occurs in the earliest stage of wound healing. Hyaluronidase, the enzyme that degrades hyaluronan, is also elevated whenever rapid turnover of hyaluronan occurs. We test the hypothesis that elevated levels of circulating hyaluronan and hyaluronidase could provide indicators of very early liver damage. **Methods:** Dimethylnitrosamine was administered to adult male albino rats by intraperitoneal injections for 7 consecutive days. **Results:** Increased serum hyaluronan levels observed on day 2 reached a maximum on day 4. Hyaluronidase was elevated on the first day and reached a maximum on day 2 that was 30-times control levels. Hyaluronan-specific staining in liver sections was maximal on day 7, occurring predominantly in portal triads and in sinusoidal spaces. Individual hepatocytes were slightly enlarged and contained intracellular hyaluronan, which was not evident in control sections. Though circulating hyaluronan levels had decreased after day 4, continued hyaluronan staining persisted in liver sections through day 21. Conventional indicators of liver injury, such as serum aminotransferase enzymes, did not reach a peak until day 7. Conventional gross and histopathological changes, including severe centrilobular congestion and hemorrhagic necrosis, were observed only after day 7. Both hyaluronan and hyaluronidase are indicators of very early liver damage in the dimethylnitrosamine-treated rat, occurring well before conventional indicators appear, or before overt histopathologic changes of liver damage can be seen. However, levels are increased only transiently, indicating that serial assays are necessary. **Conclusions:** Measures of circulating hyaluronidase activity may be used to assess liver damage.

© 2004 Elsevier B.V. All rights reserved.

**Keywords:** Hyaluronan; Hyaluronidase; Toxic liver injury; Cirrhosis; Dimethylnitrosamine

## 1. Introduction

Dimethylnitrosamine (DMN) administered to rats provides a convenient and highly reproducible animal model for acute liver injury. Well known as a carcinogen and a mutagen, it became recognized as a potent

\* Corresponding author. Tel.: +1-415-476-4961; fax: +1-415-476-5669.

E-mail address: [rstern@itsa.ucsf.edu](mailto:rstern@itsa.ucsf.edu) (R. Stern).

hepatotoxin [1] following an industrial accident [2]. Hepatotoxicity is mediated by reactive intermediates rather than by the parent compound. They target primarily the liver which contains the necessary enzymes for this metabolic conversion. The microsomal membrane-bound enzyme, cytochrome P450IIE1, is responsible for activation and degradation of DMN [3–5]. Metabolism of DMN produces formaldehyde, methanol and alkylating intermediates that react with nucleic acids and proteins to form methylated macromolecules. The liver is particularly vulnerable to these compounds.

Hyaluronan (HA) is a straight-chain glycosaminoglycan polymer of the extracellular matrix (ECM) and is increased whenever rapid tissue growth and repair occur. Hyaluronan occurs in many forms, circulating freely in the blood stream and in the lymphatic system, loosely associated with the ECM, tightly intercalated in the ECM where it aggregates with proteoglycans, or bound to cell surfaces by specific receptors [6,7]. Normally, low concentrations of HA circulate in the blood. Increases in tissue-bound and circulating HA occur very early in wound healing and during periods of rapid cell turnover following tissue injury [7–11]. Rapid increases in circulating HA also occur in response to major stress, such as blood loss, shock, septicemia [12,13], following massive trauma, major surgical procedures and extensive burns [14–16]. Hyaluronan takes on a large volume of water of hydration, up to 1000 times the original polymer volume [17]. It is a stress-response-molecule, rapid increases occurring in response to inflammatory cytokines such as IL-1 and TNF $\alpha$  [18,19]. The increased HA functions as an intravascular volume expander that prevents circulatory collapse. Clearly, increased HA provides a rapid response survival mechanism following major injuries, among which is acute liver damage. Measures of serum HA are often used clinically to assess liver function [20–28]. Increased HA is also one of the earliest indicators of rejection following liver transplantation [29–32].

In the liver, HA is synthesized mainly by the stellate cells present in the sinusoidal areas [33,34]. The major portion of circulating HA is removed by sinusoidal endothelial cells of the liver [35,36]. Elevations precede capillarization of sinusoids, the appearance of basement membrane in the space of Disse

and decreased fenestrae of endothelial cells that lead to hepatic fibrosis [26,28].

Hyaluronidases, the catabolic enzymes involved in degradation of HA, are now recognized to be a family of enzymes with high sequence homology. There are six hyaluronidase-like sequences in the human genome [37], Hyal-1 (hyaluronidase-1) being the only such enzyme in the mammalian circulation [38,39]. The turnover of HA is extraordinarily rapid, 2–5 min in the blood stream [40]. Increases in HA production and turnover are often associated with increases in hyaluronidase levels. However, measures of hyaluronidase levels have not been used previously in assessing liver damage. The enzymes that synthesize HA, the synthases [41] do not circulate freely. Activities of the HA synthases presumably precede the peak of their HA product. The assumption is that hyaluronidase also precedes the appearance of HA, and that measure of hyaluronidase activity in serum may provide a very early indicator of liver damage.

In the rat model, DMN administration causes severe necrosis and the deposition of ECM macromolecules, particularly collagen [42–44], the hallmark of the fibrous deposition in the liver associated with cirrhosis. A detailed investigation of the temporal pathophysiological changes in the liver, the glycoprotein metabolism and other biochemical abnormalities have been carried out following the sequential administration of DMN [45–49]. However, a study of HA metabolism in the liver following DMN administration has not been carried out previously.

There are many parallels between cirrhosis and wound healing, both processes culminating in deposition of fibrous connective tissue and scar formation. In wound healing, HA increases early on, and returns to normal levels within the first week [50–52]. The peak of HA reflects an early step in the cascade of events that ends in fibrous deposition. Here, we test the hypothesis that an increased level of HA is one of the earliest events in toxic liver injury. We examined HA and hyaluronidase levels at early time points following DMN administration. These markers have the potential for use clinically for detecting the earliest changes following liver injury, for screening drugs, as well as means of identifying agents that protect against liver injury.

## 2. Materials and methods

### 2.1. Materials

Ethyl alcohol, formaldehyde and *p*-dimethylamino-benzaldehyde were from E. Merck (Darmstadt, Germany), and ethylene glycol monomethyl ether (methyl cellosolve) from Fluka, Switzerland. Trichloroacetic acid, potassium sodium tartarate and Folin-Ciocalteu's phenol reagent were the products of Loba Chemie, Bombay, India. Human umbilical cord HA was from ICN, Costa Mesa, CA. COVALINK-NH microtiter plates were from NUNC (Placerville, NJ). *o*-Phenylenediamine (OPD) was from Calbiochem, La Jolla, CA, and the avidin–biotin complex (ABC kit) from Vector Lab. Burlingame, CA. Dimethylnitrosamine and all other reagents were from Sigma (St. Louis, MO).

### 2.2. Animals and treatment

Three-month-old male albino rats of the Wistar strain weighing between 180 and 200 g were used, bred and maintained in an air-conditioned animal house with commercial diet (Hindustan Lever, Bombay, India) and water available ad libitum. They were housed in polypropylene cages with a wire mesh top and a hygienic bed of husk.

The DMN was injected intraperitoneally in doses of 1  $\mu$ l (diluted 1:100 with 0.15 mol/l sterile NaCl)/100 g body weight for 7 consecutive days. Control animals received the same volume of 0.15% sterile NaCl. Animals were injected without anesthesia. Animals were observed for morphological and behavioral changes. Treated animals were sacrificed each day for the first week, and also on days 14 and 21 from the beginning of exposure. Control animals were sacrificed at the beginning of the experiment, and on days 7, 14 and 21. The controls and the experimental group for each of the first 7 days were comprised of 6 rats each time point, while the 14th and 21st day group consisted of four rats each. All rats were anaesthetized with diethyl ether before sacrifice.

### 2.3. Handling of tissues

The body and liver weights of the animals in each group were measured. Body weight was measured only

after removal of the ascitic fluid. Blood was obtained from the tail vein of rats. Blood was allowed to clot and the overlying serum collected following centrifugation. Immediately after sacrifice, the livers were rapidly removed and rinsed in cold saline. A portion of liver was fixed for histopathology using formalin fixation.

### 2.4. Biochemical analyses

Hyaluronan and hyaluronidase levels in serum were measured using a well described competitive HA ELISA-based microtiter plate procedures [53,54]. The serum alanine aminotransferase (ALT) and aspartate aminotransferase (AST) activities in serum were measured as a measure of hepatic injury. The days on which samples were taken for these determinations are given in the respective tables.

### 2.5. Statistical analysis

Arithmetic mean and standard deviations were calculated for the biochemical data. The results were statistically evaluated using one-way analysis of variance (ANOVA). The control mean values were compared with the treated mean values using the least significant difference method. A  $P < 0.01$  was considered statistically significant.

### 2.6. Procedures for histopathology

Fixed liver samples were embedded in paraffin blocks and sections of 5  $\mu$ m were prepared. The degree of hepatic injury was evaluated histopathologically by both hematoxylin and eosin (H&E) and by Masson's trichrome staining. Staining for HA uses a specific biotinylated HA-binding peptide, prepared as described [55], coupled to an avidin-peroxidase enzyme staining reaction [56,57].

## 3. Results

### 3.1. Observations of animals

There were no morphological or behavioral changes up to the 10th day following the initiation of DMN treatment. Treated animals then began exhibiting behavioral changes. Grooming no longer occurred. Food

and water intake was much decreased. Extreme lethargy and prostration were observed in the later time periods. A significant decrease in the mean body weight of DMN-treated animals was documented on days 14 and 21, with a 36% decrease recorded on day 21.

### 3.2. Observations of tissues

An increase in the liver weight was recorded on days 4, 5 and 6 after the start of DMN administration with a maximum increase on day 5 (45.6 mg/g body weight). On days 14 and 21, liver weight decreased significantly, about 55% (17.7 mg/g body weight) being observed on day 21. The livers of the animals on day 21 were hard and granular with diffuse hyperemia. The lobes were partially fused with strictures and nodulation. The mean liver weight of the control animals was 39.4 mg/g body.

The degree of hepatic fibrosis was assessed by H&E as well as Masson's trichrome staining. On day 3 after the start of DMN administration, several foci of spotty necrosis were present with marked dilatation of central veins. On day 5, extensive necrosis and hemorrhage was noted. There was marked neutrophilic and mononuclear cell infiltrates with severe centrilobular congestion. Mild bile duct hyperplasia was also observed. Massive hepatic necrosis and collapse of the liver parenchyma were observed on day 7. On day 14, there was well-developed fibrosis. Bridging necrosis was present in certain cases. Fibrosis with thick collagen fibers was observed by day 21.

Masson's trichrome staining was performed to study fibrosis, to examine the accumulation of blue collagen fibers with DMN administration. Trichrome staining demonstrated slight pericentral fibrosis by day 3. On day 5, abundant bridging fibrosis was documented with the deposition of collagen fibers. There was a blue circular staining pattern around central veins on day 7. The lobular architecture was distorted. By day 14, focal fibrosis and early cirrhosis occurred, with abundant blue collagen fibers clearly visible. All specimens by day 21 had well-developed fibrosis and early cirrhosis.

### 3.3. Hyaluronan staining

Staining for HA in liver sections using the specific HA-binding peptide was detected on day 4, reaching a

maximum on day 7. Staining occurred predominantly in hepatocytes near the portal triad as well as in sinusoidal lining cells. Intracellular HA was detected, particularly in enlarged hepatocytes (data not shown). No intracellular HA-staining could be detected in control sections.

### 3.4. Serum aspartate and alanine aminotransferase

The AST activities in the serum are shown in Table 1. Levels were significantly increased on days 3–7, with the maximum increase ( $\times 30$ -fold) recorded on day 7. The AST levels decreased to normal values on day 14. Significant increases in serum ALT levels were recorded on days 2–14. The maximum increase was also observed on day 7, 16-fold higher compared to control values. Serum AST levels decreased to normal activities by day 21.

### 3.5. Serum hyaluronan levels

Blood was collected at daily intervals in the first 7 days, and on days 14 and 21. The measure of HA concentrations in rat serum was performed using a competitive ELISA-based microtiter plate procedure, as described under Materials and methods. Serum levels on day 1 were indistinguishable from those observed in control animals. Increases were evident by day 2 and reached a maximum on day 4 that was more than 20-fold higher than controls. Circulating

Table 1  
Serum AST and ALT levels during DMN-induced hepatic injury in rats

Days	Serum ALT (IU/l), mean $\pm$ S.D.	Serum AST (IU/l), mean $\pm$ S.D.
Control	104.00 $\pm$ 14.11	190.62 $\pm$ 24.17
1	127.66 $\pm$ 18.66	180.66 $\pm$ 27.21
2	160.00 $\pm$ 24.32	265.66 $\pm$ 44.66
3	261.66 $\pm$ 32.78*	1347.33 $\pm$ 220.36
4	288.00 $\pm$ 36.34*	1515.66 $\pm$ 315.21
5	362.00 $\pm$ 64.14*	1672.33 $\pm$ 325.66
6	1221.66 $\pm$ 226.90*	3241.33 $\pm$ 514.26
7	1665.00 $\pm$ 315.17*	5523.66 $\pm$ 914.31
14	169.00 $\pm$ 30.21	231.50 $\pm$ 31.21
21	127.00 $\pm$ 19.62	224.50 $\pm$ 28.32

\* $P < 0.001$  by ANOVA when compared with control.

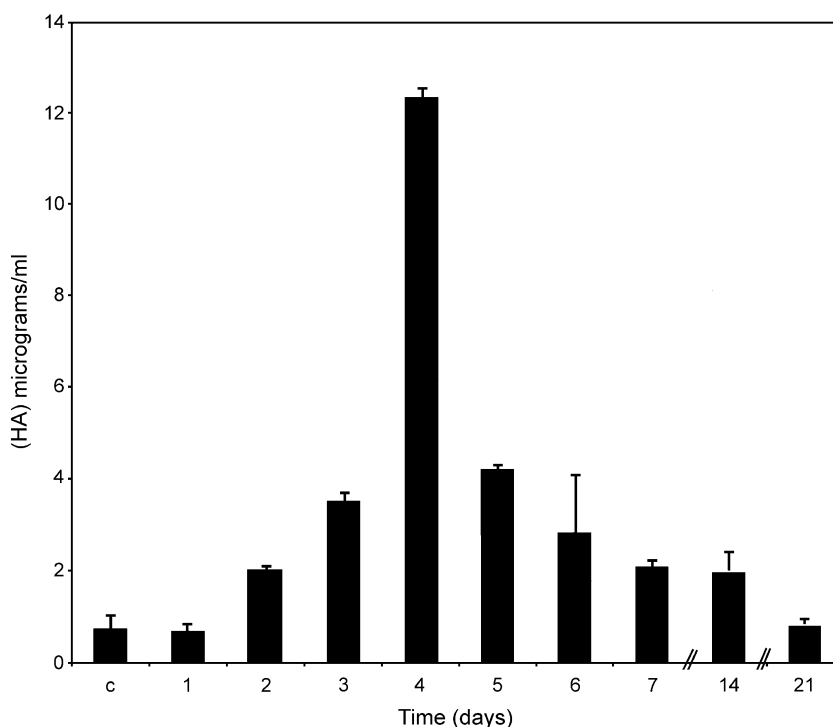


Fig. 1. Levels of HA in the serum of rats following DMN administration. The HA concentrations were assayed using a microtiter-based ELISA assay. The HA levels are shown as a function of the days after the beginning of DMN treatment. Serum levels in control animals were indistinguishable from those observed on day 1. Increases were evident by day 2 and reached a maximum by day 4. Concentrations of HA decreased thereafter. The arithmetic means and standard deviations are shown. Six rats were used for controls and at each time point from days 1 through 7, while the 14- and 21-day time points utilized four rats each in all experiments shown in Tables 1 and 2, and in this figure.

levels decreased thereafter, reaching control levels by day 14 (Fig. 1).

### 3.6. Serum hyaluronidase levels

Blood was collected as described in Section 2 and levels of circulating hyaluronidase activity examined.

Table 2

Levels of circulating serum hyaluronidase activity following initiation of DMN treatment in rats

Hyaluronidase activity	
Days	rTRU/ml, mean ± S.D.
Controls	30 ± 4
1	195 ± 2
2	1060 ± 15
3	1024 ± 8
4	910 ± 10
6	40 ± 5
14	18 ± 3
21	25 ± 2

Control levels of enzyme activity in untreated animals was approximately 30 rTRUs/ml serum, about twice that found in human serum [54]. Activity was increased to 195 rTRUs by the first day, with a peak of 1060 units by day 2 (Table 2). This was 35-times control levels. On day 2, 1024 units of activity were observed. Hyaluronidase then decreased, reaching control levels by day 6.

## 4. Discussion

Hyaluronidase and HA both appear to be very early circulating indicators of acute liver injury in this rat model system. Hyaluronidase levels were elevated in the serum sample obtained on the first day following the start of DMN treatment. A peak of enzyme activity that was 35-times control levels was observed on the second day, with only a slight decrease on the third day. Samples of blood were obtained every 24 h. Very

rapid changes were occurring during those first 2–3 days and, conceivably, an actual peak level may have occurred in an intervening interval. Circulating HA levels peaked on day 4, which was 20-times higher than controls. These parameters of HA metabolism are among the very earliest indicators of acute liver damage, occurring well before more conventional parameters of liver damage, such as aminotransferase activities. The latter activities increased only gradually and had peaks on day 7.

Administration of DMN to rats provides a valuable animal model for the study of toxic liver injury. It is a potent hepatotoxin, with doses as small as 20 mg/kg causing massive liver necrosis and death [58]. Lower doses cause subacute and chronic liver injury with varying degrees of fibrosis [59]. The carcinogenicity of DMN is also well established [59–61]. The histopathological changes observed in rats following DMN administration correlated well with alterations observed in the human following liver injury, particularly alcoholic cirrhosis. An increase in liver weight is observed in the model, reaching a maximum at day 7 [49], the same time point that liver function tests reached their peak levels in the present experiments (Table 1). This also corresponded with the time that the greatest levels of HA deposition in liver tissue occurred (data not shown). But this occurred well after the time that maximum levels of circulating HA were observed.

This increased weight and swelling of the liver may reflect tissue deposition of HA and its associated water of hydration. The swelling within individual hepatocytes can also be attributed to intracellular HA detected by histological localization. Hyaluronan is usually associated within the ECM. However, other reports of intracellular HA are now documented [62–64], including situations of severe stress [65]. Because of its highly charged nature, HA takes on an enormous volume of water of hydration, capable of expanding its solvent domain up to 1000 its actual polymer volume. The edematous swelling associated with organ transplantation is also attributed to the accumulation of HA [29–32]. A significant decrease in liver weight then follows, observed both clinically and experimentally [48,66].

At 21 days, massive centrilobular necrosis was observed with well-developed fibrosis surrounding central veins and occasional bridging. Increased

portal pressure, decreased liver blood flow, ascites and a high mortality rate are also reported following DMN administration in rats [42,49]. Late stage liver weight reduction may occur because of decreased protein synthesis, massive cell necrosis and collapse of the liver parenchyma. Relative starvation may also contribute to the decreased liver weight in these animals.

Endothelial cells are sites of uptake and degradation of HA in the liver, attributed to specific HA receptors [35,67]. The HA deposition occurred in the areas of periportal fibrosis and around the sinusoidal wall, where fibrosis was developing. The HA is localized particularly around Ito and sinusoidal endothelial cells prior to the deposition of fibrous components [68].

A conundrum arises from the results of the present studies. Increasing levels of circulating HA following toxic liver injury can be attributed to failure of the liver to remove HA from the blood. Dysfunction of the sinusoidal endothelial system and its receptors [69,70] can be invoked as the mechanism of increasing levels of circulating HA. However, if this were the case, levels of circulating HA should continue to increase, rather than falling to normal levels, as is observed.

The liver is the major source of degradation of circulating HA, followed by the kidneys. When the hepatic or renal arteries are ligated, there is an immediate increase in circulating HA [71]. The ability of HA to return to normal levels in the present experiments might be explained by the ability of the kidneys to compensate for the liver failure, performing the entire function of HA removal.

The decrease in serum transaminase levels to apparent normal levels is also seen clinically in patients with liver injury. Following rises in enzyme levels, a fall in activity indicates complete absence of liver function. The peak and then decrease in HA and hyaluronidase enzyme activity to baseline levels following liver injury appear to be similar, but the mechanisms for decreasing levels may have an entirely different mechanism.

Much information regarding the somatic hyaluronidases is accumulating rapidly [37,72,73]. Increased hyaluronidase activity often occurs whenever there is rapid in HA deposition, a reflection of the rapid turnover of the polymer. The acid-active hyaluronidase, referred to as Hyal-1, is the only hyaluronidase



present in serum and urine. As expected, increases in circulating HA occurred very early following liver injury, with an even earlier detection of increased hyaluronidase activity. Enzymatic synthesis and degradation, a reflection of increased turnover preceded the actual increased steady state deposition of HA. Increased hyaluronidase activity was detected on the first day after the beginning of DMN administration. The present studies represent the first time that levels of Hyal-1 activity have been used in a study of liver disease. The increased enzyme activity may be the earliest possible indicator of acute liver insults and may become an important clinical tool for assessing hepatic damage.

Circulating levels of HA rise rapidly in response to stress, following infection, in septicemia [12,13], shock and in patients with extensive burns [14–16]. Such increases in HA, together with the ability to take on a vast volume of water of hydration may function as a survival mechanism, providing a naturally occurring volume expander to prevent or delay imminent intravascular collapse. The turnover of circulating HA is remarkably rapid, with a  $t_{1/2}$  of 2–5 min [40].

In conclusion, in the DMN-induced liver injury model, an increase in circulating hyaluronidase can be detected within a day, with a peak of activity occurring on day 2 that was 35-fold greater than controls. Maximum circulating HA was observed on day 4 that was 20-fold increased over controls. Hyaluronidase and HA levels may be the very earliest markers for toxic liver injury, occurring well before the peaks of conventional serum markers.

The mechanism by which HA-associated serum markers become elevated in response to liver damage is not known. Many questions remain regarding HA turnover in somatic tissues. The increased HA may be a function of decreased degradation. Necrosis of liver cells and release of enzymes such as hyaluronidase into the circulation may account for the observations made here. However, a 35-fold increase over control levels makes this unlikely. Much work is required before a comprehensive mechanism can be posited for the present data. Towards this end, a putative catabolic scheme for HA has been formulated recently [74] that provides a framework for further experiments. Correlations with clinical laboratory data may validate such a scheme.

## Acknowledgements

This work was supported by the Indian Council of Medical Research, New Delhi, by grant no. 3/1/23/(9201540)/92-NCD-III) to JG. The authors are grateful to Dr. Gowri Chandrakasan of the Central leather Research Institute, Department of Biochemistry, Chennai, India for support, guidance and many useful discussions.

## References

- [1] Haggerty HG, Holsapple MP. Role of metabolism in dimethylnitrosamine induced immunosuppression: a review. *Toxicology* 1990;63:1–23.
- [2] Barnes JM, Magee PN. Some toxic properties of dimethylnitrosamine. *Br J Ind Med* 1954;11:167–74.
- [3] Yang CS, Tu YY, Koop DR, Coon MJ. Metabolism of nitrosamines by purified liver cytochrome P-450. *Cancer Res* 1985;45:1140–5.
- [4] Yang CS, Yoo JSH, Ishizaki H, Hong J. Cytochrome P450III1: role in nitrosamine metabolism and mechanisms of regulation. *Drug Metab* 1990;22:147–59.
- [5] Yoo JSH, Guengerich FP, Yang CS. Metabolism of *N*-nitrosodialkylamines by human liver microsomes. *Cancer Res* 1988;48:1499–504.
- [6] Laurent TC, Laurent UBG, Fraser JRE. Serum hyaluronan as a disease marker. *Ann Med* 1996;28:241–53.
- [7] Laurent TC, editor. *The Chemistry, Biology, and Medical Applications of Hyaluronan and Its Derivatives*. London: Portland Press; 1998.
- [8] Toole BP. Proteoglycans and hyaluronan in morphogenesis and differentiation. In: Hay ED, editor. *Cell Biology of Extracellular Matrix*. New York: Plenum Press; 1991. p. 305–41.
- [9] Toole BP. Hyaluronan is not just goo! *J Clin Invest* 2000;106:335–7.
- [10] Fraser JR, Laurent TC, Laurent UB. Hyaluronan: its nature, distribution, functions and turnover. *J Intern Med* 1997;242:27–33.
- [11] Lee JY, Spicer AP. Hyaluronan: a multifunctional megaDalton stealth molecule. *Curr Opin Cell Biol* 2000;12:581–6.
- [12] Berg S. Hyaluronan turnover in relation to infection and sepsis. *J Intern Med* 1997;242:73–7.
- [13] Berg S, Brodin B, Hesselvik F, Laurent TC, Maller R. Elevated levels of plasma hyaluronan in septicemia. *Scand J Clin Lab Invest* 1988;48:727–32.
- [14] Ferrara JJ, Reed RK, Dyess DL, Townsley MI, Onarheim H, Laurent TC, et al. Increased hyaluronan flux from skin following burn injury. *J Surg Res* 1991;50:240–4.
- [15] Onarheim H, Missavage AE, Gunther RA, Kramer GC, Reed RK, Laurent TC. Marked increase of plasma hyaluronan after major thermal injury and infusion therapy. *J Surg Res* 1991;50:259–65.
- [16] Onarheim H, Reed RK, Laurent TC. Increased plasma con-

- centrations of hyaluronan after major thermal injury in the rat. *Circ Shock* 1992;37:159–63.
- [17] Granger HJ, Laine GA, Barnes GE, Lewis RE. Dynamics and control of transmicrovascular fluid exchange. In: Staub AE, Taylor AE, editors. *Edema*. New York: Raven Press; 1984. p. 189–228.
- [18] Postlethwaite AE, Smith Jr GN, Lachman LB, Endres RO, Poppleton HM, Hasty KA, et al. Stimulation of glycosaminoglycan synthesis in cultured human dermal fibroblasts by interleukin 1. Induction of hyaluronic acid synthesis by natural and recombinant interleukin 1s and synthetic interleukin 1 beta peptide 163–171. *J Clin Invest* 1989;83:629–36.
- [19] Ohkawa T, Ueki N, Taguchi T, Shindo Y, Adachi M, Amuro Y, et al. Stimulation of hyaluronan synthesis by tumor necrosis factor-alpha is mediated by the p50/p65 NF-kappa B complex in MRC-5 myofibroblasts. *Biochim Biophys Acta* 1999;1448:416–24.
- [20] Engstrom-Laurent A, Loof L, Nyberg A, Schroder T. Increased serum levels of hyaluronate in liver disease. *Hepatology* 1985;5:638–42.
- [21] Nyberg A, Engstrom-Laurent A, Loof L. Serum hyaluronate in primary biliary cirrhosis—a biochemical marker for progressive liver damage. *Hepatology* 1988;8:142–6.
- [22] Mattsson L, Lindqvist U, Weiland O, Aber B. Serum levels of the aminoterminal propeptide of type III procollagen and hyaluronan during resolving and nonresolving posttransfusion non-A, non-B hepatitis. *Scand J Infect Dis* 1990;22:11–7.
- [23] Ramadori G, Zohrens G, Manns M, Rieder H, Dienes HP, Hess G, et al. Serum hyaluronate and type III procollagen aminoterminal propeptide concentration in chronic liver disease. Relationship to cirrhosis and disease activity. *Eur J Clin Invest* 1991;21:323–30.
- [24] Trivedi P, Cheeseman P, Mowat AP. Serum hyaluronic acid in healthy infants and children and its value as a marker of progressive hepatobiliary disease starting in infancy. *Clin Chim Acta* 1993;215:29–33.
- [25] Frebourg T, Delpech B, Bercoff E, Senant J, Bertrand P, Deugnier Y, et al. Serum hyaluronate in liver diseases: study by enzyme-immunological assay. *Hepatology* 1986;6:392–5.
- [26] Kobayashi H, Horikoshi K, Yamataka A, Yamataka T, Okazaki T, Lane GJ, et al. Hyaluronic acid: a specific prognostic indicator of hepatic damage in biliary atresia. *J Pediatr Surg* 1999;34:1791–4.
- [27] Guechot J, Serfaty L, Bonnand AM, Chazouilleres O, Poupon R, Poupon R. Prognostic value of serum hyaluronan in patients with compensated HCV cirrhosis. *J Hepatol* 2000;32:447–52.
- [28] Nanji AA, Tahan R, Khwaja S, Yacoub LK, Sadzadeh SM. Elevated plasma levels of hyaluronic acid indicate endothelial cell dysfunction in the initial stages of alcoholic liver disease in the rat. *J Hepatol* 1996;24:368–74.
- [29] Rao PN, Bronsther OL, Pinna AD, Demetris A, Snyder J, Fung J, et al. Prediction of early graft function by effluent levels of hyaluronic acid in clinical liver transplantation. *Transplant Proc* 1993;25:2141–2.
- [30] Rao PN, Bronsther OL, Pinna AD, Snyder JT, Cowan S, Sankey S, et al. Hyaluronate levels in donor organ washout effluents: a simple and predictive parameter of graft viability. *Liver* 1996;16:48–54.
- [31] Lendoire JC, Duek F, Bianco G, Aziz H, Saul J, Blanco S, et al. Correlation between effluent hyaluronic acid levels and early graft function in orthotopic liver transplantation. *Transplant Proc* 1998;30:2889–90.
- [32] Fabrega E, Castro B, Crespo J, de la Pena J, Gomez-Fleitas M, Garcia-Unzueta MT, et al. Different time course of circulating adhesion molecules and hyaluron during hepatic allograft rejection. *Transplantation* 2000;69:569–73.
- [33] Vrochides D, Papanikolaou V, Pertoft H, Antoniadis AA, Heldin P. Biosynthesis and degradation of hyaluronan by non-parenchymal liver cells during liver regeneration. *Hepatology* 1996;23:1650–5.
- [34] Gressner AM, Haarmann R. Regulation of hyaluronate synthesis in rat liver fat storing cell cultures by Kupffer cells. *J Hepatol* 1988;7:310–8.
- [35] Eriksson S, Fraser JR, Laurent TC, Pertoft H, Smedsrod B. Endothelial cells are sites of uptake and degradation of hyaluronic acid in the liver. *Exp Cell Res* 1983;144:223–8.
- [36] Fraser JR, Alcorn D, Laurent TC, Robinson AD, Ryan GB. Uptake of circulating hyaluronic acid by the rat liver. Cellular localization in situ. *Cell Tissue Res* 1985;242:505–10.
- [37] Csoka AB, Frost GI, Stern R. The six hyaluronidase-like sequences in the human genome. *Matrix* 2001;20:499–508.
- [38] Frost GI, Csoka TB, Wong T, Stern R. Purification, cloning and expression of human plasma hyaluronidase. *Biochem Biophys Res Commun* 1997;236:10–5.
- [39] Csoka TB, Frost GI, Wong T, Stern R. Purification and microsequencing of hyaluronidase isozymes from human urine. *FEBS Lett* 1997;417:307–10.
- [40] Fraser JR, Laurent TC, Pertoft H, Baxter E. Plasma clearance, tissue distribution and metabolism of hyaluronic acid injected intravenously in the rabbit. *Biochem J* 1981;200:415–24.
- [41] Weigel PH, Hascall VC, Tammi M. Hyaluronan synthases. *J Biol Chem* 1997;272:13997–4000.
- [42] Jenkins SA, Grandison A, Baxter JN, Day DW, Taylor I, Shields R. A dimethylnitrosamine induced model of cirrhosis and portal hypertension in the rat. *J Hepatol* 1985;1:489–99.
- [43] Ala-Kokko L, Pihlajaniemi T, Myers JC, Kivirikko KI, Savolainen ER. Gene expression of types I, III, and IV collagens in hepatic fibrosis induced by dimethylnitrosamine in the rat. *Biochem J* 1987;24:75–9.
- [44] Savolainen ER, Brocks D, Ala-Kokko L, Kivirikko KI. Serum concentrations of the N-terminal propeptide of type III procollagen and two type IV collagen fragments and gene expression of the respective collagen types in liver in rats with dimethylnitrosamine-induced hepatic fibrosis. *Biochem J* 1988;249:753–7.
- [45] George J, Chandrakasan G. Glycoprotein metabolism in dimethylnitrosamine induced hepatic fibrosis in rats. *Int J Biochem Cell Biol* 1996;28:353–61.
- [46] George J, Chandrakasan G. Molecular characteristics of dimethylnitrosamine induced fibrotic liver collagen. *Biochim Biophys Acta* 1996;1292:215–22.
- [47] George J, Chandrakasan G. Lactate dehydrogenase isoen-



- zymes in dimethylnitrosamine-induced hepatic fibrosis in rats. *J Clin Biochem Nutr* 1997;22:51–62.
- [48] George J, Chandrakasan G. Biochemical abnormalities during the progression of hepatic fibrosis induced by dimethylnitrosamine. *Clin Biochem* 2000;33:563–70.
- [49] George J, Rao KR, Stern R, Chandrakasan G. Dimethylnitrosamine-induced liver injury in rats: the early deposition of collagen. *Toxicology* 2001;156:129–38.
- [50] Weigel PH, Fuller GM, LeBoeuf RD. A model for the role of hyaluronic acid and fibrin in the early events during the inflammatory response and wound healing. *J Theor Biol* 1986; 119:219–34.
- [51] Weigel PH, Frost SJ, McGary CT, LeBoeuf RD. The role of hyaluronic acid in inflammation and wound healing. *Int J Tissue React* 1988;10:355–65.
- [52] Longaker MT, Chiu ES, Adzick NS, Stern M, Harrison MR, Stern R. Studies in fetal wound healing: V. A prolonged presence of hyaluronic acid characterizes fetal wound fluid. *Ann Surg* 1991;213:292–6.
- [53] Fosang AJ, Hey NJ, Carney SL, Hardingham TE. An ELISA plate based assay for hyaluronan using biotinylated proteoglycan G1 domain (HA-binding region). *Matrix* 1990;10:306–13.
- [54] Frost GI, Stern R. A microtiter-based assay for hyaluronidase activity not requiring specialized reagents. *Anal Biochem* 1997;251:263–9.
- [55] Tengblad A. Affinity chromatography on immobilized hyaluronate and its application to the isolation of hyaluronate binding properties from cartilage. *Biochim Biophys Acta* 1979; 578:281–9.
- [56] Meyer LJ, Russell SB, Russell JD, Trupin JS, Egbert BM, Shuster S, et al. Reduced hyaluronan in keloid tissue and cultured keloid fibroblasts. *J Invest Dermatol* 2000;114:953–9.
- [57] Lin W, Shuster S, Maibach HI, Stern R. Patterns of hyaluronan staining are modified by fixation techniques. *J Histochem Cytochem* 1997;45:1157–63.
- [58] Hashimoto N, Ishikawa Y, Utsunomiya J. Effects of portacaval shunt, transposition, and dimethylnitrosamine-induced chronic liver injury on pancreatic hormones and amino acids in dog. *J Surg Res* 1989;46:35–40.
- [59] Magee PN, Barnes J. Carcinogenic nitroso compounds. *Adv Cancer Res* 1967;10:163–246.
- [60] Magee PN. The experimental basis for the role of nitroso compounds in human cancer. *Cancer Surv* 1989;8:207–39.
- [61] Tsutsumi M, Matsuda Y, Takada A. Role of ethanol-inducible cytochrome P-450E1 in the development of hepatocellular carcinoma by the chemical carcinogen, *N*-nitrosodimethylamine. *Hepatology* 1993;18:1483–9.
- [62] Evanko SP, Wight TN. Intracellular location of hyaluronan in proliferating cells. *J Histochem Cytochem* 1999;47:1331–42.
- [63] Evanko SP, Angello JC, Wight TN. Formation of hyaluronan- and versican-rich pericellular matrix is required for proliferation and migration of vascular smooth muscle cells. *Arterioscler Thromb Vasc Biol* 1999;19:1004–13.
- [64] Tammi R, Rilla K, Pienimäki JP, MacCallum DK, Hogg M, Luukkonen M, et al. Hyaluronan enters keratinocytes by a novel endocytic route for catabolism. *J Biol Chem* 2001;276:35111–22.
- [65] Majors AK, Austin RC, de la Motte CA, Pyeritz RE, Hascall VC, Kessler SP, et al. Endoplasmic reticulum stress induces hyaluronan deposition and leukocyte adhesion. *J Biol Chem* 2003;278:47223–31.
- [66] Chowdhury SA, Taylor R. Insulin sensitivity in experimental cirrhosis. *Mol Cell Biochem* 1989;89:69–72.
- [67] Smedsrod B, Pertoft H, Eriksson S, Fraser JR, Laurent TC. Studies in vitro on the uptake and degradation of sodium hyaluronate in rat liver endothelial cells. *Biochem J* 1984; 223:617–26.
- [68] Satoh T, Ichida T, Matsuda Y, Sugiyama M, Yonekura K, Ishikawa T, et al. Interaction between hyaluronan and CD44 in the development of dimethylnitrosamine-induced liver cirrhosis. *J Gastroenterol Hepatol* 2000;15:402–11.
- [69] Zhou B, Oka JA, Singh A, Weigel PH. Purification and subunit characterization of the rat liver endocytic hyaluronan receptor. *J Biol Chem* 1999;274:33831–4.
- [70] Zhou B, Weigel JA, Fauss L, Weigel PH. Identification of the hyaluronan receptor for endocytosis. *J Biol Chem* 2000; 275:37733–4.
- [71] Engstrom-Laurent A, Hellstrom S. The role of liver and kidneys in the removal of circulating hyaluronan. An experimental study in the rat. *Connect Tissue Res* 1990;24:219–24.
- [72] Csóka TB, Frost GI, Heng HH, Scherer SW, Mohapatra G, Stern R. The hyaluronidase gene *HYAL1* maps to chromosome 3p21.2–p21.3 in human and 9F1-F2 in mouse, a conserved candidate tumor suppressor locus. *Genomics* 1998;48:63–70.
- [73] Lepperdinger G, Mullegger J, Kreil G. Hyal2-less active, but more versatile? *Biology* 2001;20:509–14.
- [74] Stern R. Devising a pathway for hyaluronan catabolism: are we there yet? *Glycobiology* 2003;13:105R–15R.