

Full Length Research Paper

Analysis of predictors of root resorption in the orthodontic treatment (Part II)

**Oliveira, Antônio Geraldo de^{1*}, Consolaro, Alberto², Junqueira, José Luiz Cintra³,
Martins-Ortiz, Maria Fernanda⁴ and Franzolin, Solange de Oliveira Braga⁵**

¹Orthodontics of São Leopoldo Mandic at Ipatinga and Belo Horizonte, MG (Unit II), and Private Orthodontic practice in Varginha, MG, Brazil.

²University of São Paulo at Bauru and Ribeirão Preto, SP, Brazil.

³São Leopoldo Mandic, Campinas, SP, Brazil.

⁴University of Sagrado Coração and Private orthodontic practice in Bauru, SP, Brazil.

⁵University of Sagrado Coração, Bauru, SP, Brazil.

Accepted 18 May, 2011

This study aims to analyze the predictors of root resorption in orthodontic treatment. From 407 records, 377 pretreatment and posttreatment periapical radiographs of permanent maxillary central incisors of 199 patients treated with fixed appliances were divided according to the apical morphologies: pipette-shaped, dilacerated, pointed, rounded and rectangular; crown/root ratio; and presence or absence of partial hypodontia. Changes in root length between the onset and completion of orthodontic treatment were measured in digitized images and statistically compared using T student, one-way ANOVA and Tukey tests. The apical morphology influenced the occurrence of root resorption; teeth with rounded and rectangular apical morphologies were more resistant to root resorption (.001 and .0007, respectively). Short teeth and the presence of partial hypodontia or multiple partial hypodontia did not present greater tendency to root resorption (.1008 and .1544, respectively). The results indicated that abnormal apical morphology is a predictor of external apical root resorption after corrective orthodontic therapy. However, short teeth and partial hypodontia did not increase the prevalence of apical resorption. The susceptibility or individual predisposition to tooth resorptions during orthodontic treatment may be related to the apical morphology.

Key words: Root resorption, orthodontic treatment, tooth movement.

INTRODUCTION

There is a relationship between morphological tooth characteristics such as taurodontism, invagination, root length, root shape (Levander and Malmgren, 1988; Kjaer, 1995; Mirabella and Artun, 1995; Levander et al., 1998a, b; Sameshima and Sinclair, 2001; Consolaro et al., 2001; Velloso et al., 2001; Furquim, 2002; Sameshima and Sinclair, 2004; Consolaro, 2005; Smale et al., 2005) crown/root ratio (Kjaer, 1995; Consolaro et al., 2001; Velloso et al., 2001; Nigul and Jagomagi, 2006) and the

tendency of root resorption during orthodontic treatment. Root resorption occurs initially in the maxillary anterior teeth, primarily affecting the maxillary lateral incisors and teeth with abnormal root morphologies, such as pipette-shaped, pointed or dilacerated roots (Sameshima and Sinclair, 2001; Sameshima and Sinclair, 2004; Nigul and Jagomagi, 2006). The so-called susceptibility or individual predisposition may be related to the tooth morphology of the patient, favoring the greater occurrence of root resorption during orthodontic treatment.

Table 4 demonstrates the association of apical morphology and crown/root ratio with root resorption in several published studies, according to the methodology. In patients with predominantly pointed roots, the bone

*Corresponding author. E-mail: antoniogeraldooliveira@gmail.com Tel/Fax: (55-35)3221-5376.

crests tend to be rectangular. This may be observed in patients with partial hypodontia. The interdental spaces are larger and the alveolar bone crest presents a rectangular shape. In patients with partial hypodontia (Oliveira, 1988; Oliveira et al., 1991; Kjaer, 1995; Peck et al., 1996; Levander et al., 1998a; Mavragani et al., 2000; Consolaro et al., 2001; Velloso et al., 2001), the teeth present a morphological simplification characterized by a conical root shape, besides other features, with predominance of pointed root shape and shorter roots compared to normal patients. According to Peck et al. (1996) partial hypodontia, reduced tooth size and palatal displacement of canines are biological co-variables in a complex of disorders. Some studies have suggested and evidenced that patients with partial hypodontia are more predisposed to root resorption during induced tooth movement, even suggesting a genetic predisposition. In fact, the action of hypodontia genes causes morphological changes in the root and alveolar bone crest, such as pointed root morphology and rectangular bone crests; these changes favor the concentration of forces on the periodontal tissues, increasing the risk of root resorption during orthodontic movement (Consolaro, 2005).

Hypodontia is a genetic condition with autosomal dominant inheritance and is associated with several tooth abnormalities, including small sized maxillary lateral incisors, ectopic canines, taurodontism and rotated premolars (Arte et al., 2001). The rate of external apical root resorption is significantly higher in cases of multiple hypodontia (four to 16 missing teeth) than in individuals with only one to three missing teeth (Levander et al., 1998a). Table 5 presents studies that correlated the partial hypodontia and multiple partial hypodontia with external apical root resorption and the methodology applied. Based on the assumption that local factors are intrinsically related to root resorption in the orthodontic treatment and considering the presence of many such factors, some of which are still scarcely investigated, this study evaluated the predictors of external apical root resorption in patients submitted to orthodontic treatment, addressing the apical and root morphology, crown/root ratio and partial hypodontia.

MATERIALS AND METHODS

The study was approved by the Institutional Review Board of the Postgraduate Center at São Leopoldo Mandic College (protocol n. 2008/0374). The study sample was obtained after detailed analysis of 407 patient records of the Specialization course in Orthodontics at Lavras Educational Center, Minas Gerais. All patients had been treated with fixed appliances by postgraduate orthodontic students by the same technique adopted by the department (conventional edgewise and pre-adjusted edgewise). Among the 407 records, 208 were excluded because they did not meet the inclusion criteria, namely patients voluntarily registering at the Triage Center of the Specialization Course in Orthodontics at Lavras Educational Center

and who signed an informed consent form agreeing to participate in the study. The exclusion criteria comprised patients who interrupted the treatment or were referred to other professionals; incomplete initial or final orthodontic records; periapical radiographs of poor quality (elongated, shortened or distorted images or not exhibiting part of the central incisors; rotated teeth; inadequately developed radiographs; etc); maxillary central incisors with incompletely formed roots; maxillary central incisors with fracture or restoration on the incisal edge during orthodontic treatment; or any other reasons that did not allow perfect measurement of the maxillary central incisors. Therefore, the final sample comprised 199 records. The initial and final periapical radiographs of these patients, obtained by the paralleling technique, were digitized (scanner model "Perfection V700", Epson®), adding up to 377 maxillary central incisors that were evaluated and measured.

Measurement technique

The digitized radiographic images were stored and edited using the Photoshop® software (Adobe®, Photoshop® Cs3 version 10.0, USA), maintaining their original dimensions, and analyzed on a microcomputer. Thereafter, the images were analyzed on the "Image j" software (designed by the U.S. National Institutes of Health - Image J 1.41 - public domain- <http://rsb.info.nih.gov/ij/>, downloaded on March 12th 2009) for the achievement of measurements. The root and tooth lengths were measured to the nearest 0.01 mm. In order to determine and calculate the changes in the tooth and root length on two different radiographs of the same patient, the study considered the premise that the crown size is not changed during orthodontic treatment (except in case of fracture or restoration).

Therefore, the variation between the initial (C1) and final crown length (C2) determined the magnification factor. If no change occurred in root length during treatment, the variation between the initial (R1) and final root length (R2) should be equal to the C1/C2 variation. If root shortening occurred during treatment, the amount of apical root resorption was calculated by the equation $R1-R2 \times (C1/C2)$ (Brezniak et al., 2004). The software "Image J" was used for tooth length measurement, using a standard scale for all images analyzed. This procedure comprised measurement of the mesiodistal diameter of the crown of a maxillary central incisor on the initial dental cast of one patient in the sample, whose value was 8.5 mm diameter. Thereafter, the digitized periapical radiograph of the same tooth was opened in the software "Image J" for measurement of the mesiodistal diameter using the tool "Straight line", followed by the steps "Analyze", "Set Scale", "Distance in Pixels" (107.000), "Known Distance" (8.5 mm), "Pixel Aspect Ratio" (1.0), "Unit of length" (mm), and "Global". This revealed a final standard scale of 12.588 "Pixels/mm", which was employed for measurement of all images in this study. After achievement of the standard scale, the digitized radiographs of all patients were opened on the software and measured using the tools "Plugins", "Analyze", "Measure and Label". The initial and final values were entered on an Excel® worksheet to calculate root shortening (Microsoft Office Excel version 97-2003®).

For the measurement of each radiographic image, the median cemento-enamel junction (CEJ) point was taken as reference, which corresponds to the midpoint between the mesial and distal points of the CEJ line. The root length was measured as the distance between the median CEJ point and the root apex. After achievement of the root length, the total tooth length was measured (between the root apex and the incisal edge) and the crown length was calculated as the difference between the total length and the root length, which represents the distance between the median CEJ point and the incisal edge (Figure 1).

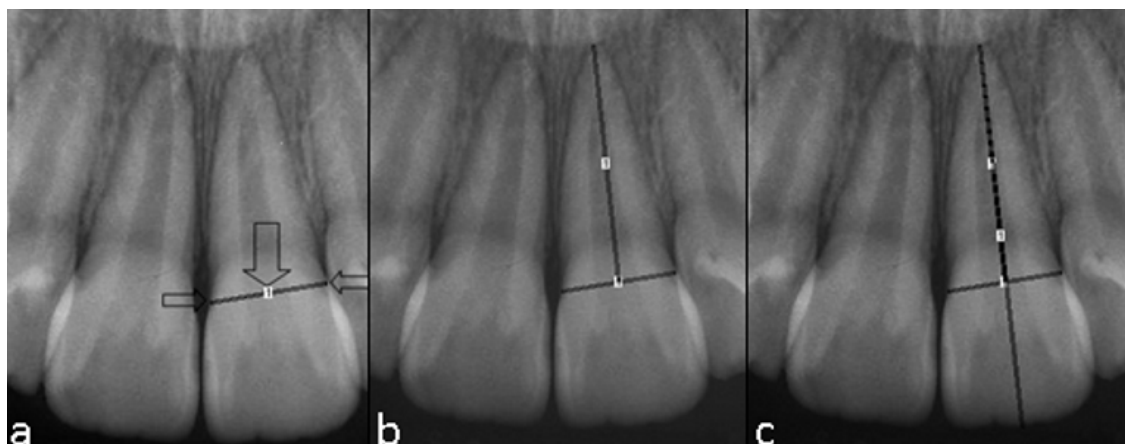


Figure 1. a) CEJ (cemento-enamel junction) line, formed by the union of the mesial and distal CEJ points (small arrows), with the large arrow indicating the median CEJ point that corresponds to the midpoint between the mesial and distal CEJ points. b) Root length measurement, corresponding to the distance from the median CEJ point to the root apex. c) The line indicating the total tooth length (superimposed to the line indicating the root length) runs from the root apex to the incisal edge, passing through the median CEJ point.

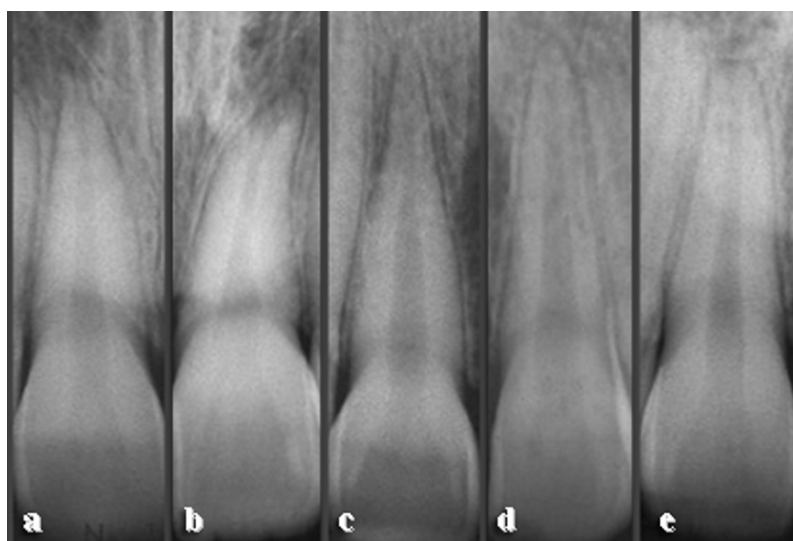


Figure 2. Sample classification according to apical morphology: a) Pipette-shaped; b) Dilacerated; c) Pointed; d) Rounded; e) Rectangular.

Sample classification

The 377 maxillary central incisors were divided in groups according to the study objective, namely the apical morphologies (Figure 2): G1 - pipette-shaped ($n = 11$), G2 - dilacerated ($n = 16$), G3 - pointed ($n = 49$), G4 - rounded ($n=289$) and G5 - rectangular ($n=12$); crown/root ratio: G6 - short teeth (with roots smaller than 1.6 times the crown size) and G7 - normal teeth; and partial hypodontia: G8 - presence of partial hypodontia ($n = 60$), G9 - multiple partial hypodontia ($n = 17$) and G10 - absence of partial hypodontia ($n = 300$). Concerning the formation of groups with partial hypodontia, the inclusion criteria comprised at least one

missing tooth, while multiple partial hypodontia was considered if three or more teeth were missing (except for the third molars) or if hypodontia affected at least two different groups of teeth (e.g. affecting third molars and premolars and/or any other two groups of teeth).

Statistical analysis

Data were described as means and standard deviations. The Kolmogorov-Smirnov test was applied to check if the data presented normal distribution. Comparison between two groups

Table 1. Relationship between root shortening after orthodontic treatment and apical morphology (in millimeters). Comparison of apical morphology between groups with different apical morphologies.

Apical morphology	Groups	Patients (N)	Teeth (N)	\bar{x}	SD	P value	
Pipette-shaped	G1	10	11	2.44	1.48	G2:	0.8385
						G3:	0.1420
						G4:	0.0094**
						G5:	0.0005***
Dilacerated	G2	14	16	2.33	1.39	G3:	0.1492
						G4:	0.0057**
						G5:	0.0003***
Pointed	G3	33	49	1.74	1.40	G4:	0.09509
						G5:	0.0043**
Rounded	G4	163	289	1.40	1.29	G5:	0.0164*
Rectangular	G5	11	12	0.49	0.70		
Abnormal	G1+G2+G3	57	76	1.96	1.43	G4:	0.0010***
						G5:	0.0007***
						G4+G5:	0.0004***

\bar{x} = mean root shortening; SD = standard deviation; some patients presented one central incisor with one type of morphology and the other central incisor with a different morphology and thus are present in different groups, which explains the number of patients greater than 199. * $p < 0.05$, ** $p < 0.01$, *** $p < 0.001$.

was performed by the Student t test. Comparison between three or more groups was performed by one-way analysis of variance (ANOVA). If statistically significant difference was observed, the Tukey test for multiple comparisons was applied. All statistical tests were applied at a significance level of 5% ($p < 0.05$) and were run using the statistics software Past (Hammer et al., 2001).

Method error

All radiographs were analyzed by a single examiner. To analyze the visual accuracy of the examiner when scoring the apical morphology, images of 50 randomly selected periapical radiographs of maxillary incisors were analyzed, adding up to 100 teeth, which were classified in five different apical morphologies: pipette-shaped, dilacerated, pointed, rounded and rectangular (Figure 2). After 30 days, the 100 teeth were once again evaluated and classified for calculation of the Kappa index in the intra-examiner evaluation, which revealed a value of 0.76, evidencing substantial agreement. In order to determine the reliability of results, the method error was evaluated by analysis of casual and systematic errors. Images of 16 periapical radiographs were randomly selected, from which 32 measurements were obtained (of the two maxillary central incisors) in two different periods at a four-week interval. The error was calculated by the Dahlberg formula, revealing values of 0.195 and 0.179 for the casual error and 0.054 and 0.314 for the systematic error, for the root and crown lengths, respectively. Analysis of the method error revealed that the identification of points and the achievement of measurements were reliable, since the accuracy of measurements was within acceptable parameters (Table 6).

RESULTS

The relationship between root shortening and the apical morphology are presented in Table 1. Table 1 reveals that, after corrective orthodontic therapy, the maxillary central incisors with abnormal shapes (pipette-shaped, dilacerated and triangular) exhibited greater root shortening than incisors with rounded apices ($P = 0.001$). There was also a great difference in the occurrence of external apical root resorption between central incisors with rectangular apex and teeth with abnormal apical shapes ($P = 0.0007$), also in relation to incisors with rounded apices ($P = 0.0164$). This evidences the higher risk of root resorption in teeth with abnormal apices and the lower risk in teeth with rounded and especially rectangular apical morphology.

Concerning the inadequate crown/root ratio, that is, teeth with roots smaller than 1.6 times the crown size (Smale et al., 2005), the occurrence of root shortening after orthodontic treatment in this study was similar to teeth with normal size (Table 2).

The greater occurrence of root resorption in permanent central incisors after orthodontic treatment in patients with partial hypodontia or multiple partial hypodontia was not confirmed in this study (Table 3).

DISCUSSION

The results concerning the consistent influence of the

Table 2. Relationship between root shortening after orthodontic treatment according to the crown/root ratio (in millimeters). Comparison between short teeth (R<1.6C) and teeth with normal size.

Teeth	Group	Patients (N)	Teeth (N)	\bar{x}	SD	P value
Short	G6	50	74	1.26	1.21	0.1008
Normal	G7	149	303	1.54	1.36	

\bar{x} = mean; SD = standard deviation.

Table 3. Relationship between root shortening after orthodontic treatment according to the presence of partial hypodontia and multiple partial hypodontia (in millimeters). Comparison with normal patients.

	Groups	Patients (N)	Teeth (N)	\bar{x}	SD	P value
Hypodontia	G8	41	60	1.22	1.19	G9: 0.0947
						G10: 0.0973
Multiple hypodontia	G9	9	17	1.81	1.61	G10: 0.3967
Normal	G10	149	300	1.53	1.34	

\bar{x} = mean, SD = standard deviation, ANOVA P = 0.1544.

Table 4. Data on root resorption in published studies addressing the apical morphology factors.

Author	Morphology	P	D	Po	Ro	Rec	C/R	Method
Bellamy et al., 2008		NS	NS	NS	NS	NS	-	PP/C
Provenzano, 2008		-	-	-	-	-	-	PP
Nigul and Jagomagi, 2006		-	-	NS	-	-	+	PN
Smale et al., 2005		+	+	+	-	-	-	PP
Consolaro, 2005		+	+	+	-	-	+	O
Otis et al., 2004		NS	NS	NS	NS	NS	-	PN/O
Sameshima and Sinclair, 2004		+	+	+	-	-	-	PP
Kook et al., 2003		NS	NS	NS	NS	NS	-	PP
Furquim, 2002		+	+	+	-	-	NS	PP
Consolaro et al., 2001		+	+	+	-	-	+	NS
Sameshima and Sinclair, 2001		+	+	+	-	NS	NS	PP
Velloso et al., 2001		+	+	+	-	-	+	NS
Levander et al., 1998		+	NS	+	-	NS	NS	O
Levander et al., 1998		+	+	+	-	-	-	PP
Kurol et al., 1997		NS	NS	NS	NS	NS	-	PP
Baumrind et al., 1996		NS	NS	NS	NS	NS	-	PP
Kjaer, 1995		+	+	+	-	-	+	NS
Mirabela and Artun, 1995		+	+	+	-	-	-	PP/C
Levander and Malmgren, 1988		+	+	+	-	-	-	PP
Total		+ = 12	+ = 11	+ = 12	+ = 0	+ = 0	+ = 5	PP = 12
		- = 2	- = 2	- = 1	- = 14	- = 12	- = 11	PN = 2
								C = 2
								O = 3

P = Pipette-shaped; D = dilacerated; Po = pointed; Ro = rounded; Rec = rectangular; C/R = crown/root ratio; + = related with root resorption; - = not related with root resorption; PP = periapical; PN = panoramic; C = cephalogram; O = others; NS = non-specified.

Table 5. Data on root resorption in published studies addressing the presence of partial hypodontia and multiple partial hypodontia

Author	Specificity	Partial hypodontia	Multiple partial hypodontia	Method
Consolaro et al., 2001		+	NS	PP
Velloso et al., 2001		+	NS	PP
Mavragani et al., 2000		+	NS	PP
Lee et al., 1999		-	NS	PP
Levander et al., 1998		+	+	PP
Kjaer, 1995		+	NS	NS
Total		+ = 5; - = 1	+ = 1	PP = 5

+ = Related with root resorption; - = not related with root resorption; PP = periapical; NS = non-specified.

Table 6. Calculation of method error intraexaminer. Difference between first and second mensuration (millimeters), casual error (Dahlberg) and systematic error ("t" test).

Measure length (mm)	Measures				Error		Significance
	1st		2nd		Casual	Systematic	
	\bar{x}	SD	\bar{x}	SD	(Dahlberg)	(P)	
Root	16.1	2.26	16.19	2.21	0.195	0.054	ns
Crown	8.67	0.68	8.62	0.66	0.179	0.314	ns

ns = Not significant; \bar{x} = average; SD = standard deviation.

apical morphology on the greater occurrence of external apical root resorption after corrective orthodontic treatment observed in this study agree with the daily clinical findings and several published studies employing similar methodologies (Levander and Malmgren, 1988; Kjaer, 1995; Mirabella and Artun, 1995; Levander et al., 1998a, b; Consolaro et al., 2001; Sameshima and Sinclair, 2001; Velloso et al., 2001; Furquim, 2002; Sameshima and Sinclair, 2004; Consolaro, 2005; Smale et al., 2005). Conversely, other studies did not correlate the root shortening after orthodontic treatment with the apical morphology (Nigul and Jagomagi, 2006; Provenzano, 2008). Concerning the inadequate crown/root ratio, according to several investigators (Kjaer, 1995; Consolaro, 2001; Velloso et al., 2001; Nigul and Jagomagi, 2006), it is directly related to the greater occurrence of root resorption after orthodontic treatment. However, other studies did not find a higher frequency of root resorption in teeth with short roots (Levander and Malmgren, 1988; Mirabela and Artun, 1995; Baumrind et al., 1996; Kurol et al., 1997; Levander et al., 1998a; Kook et al., 2003; Sameshima and Sinclair, 2004; Otis et al., 2004; Smale et al., 2005; Provenzano, 2008; Bellamy et al., 2008). A detailed evaluation of the study groups evidences that short teeth are not homogeneously distributed between groups, with a considerably higher number of teeth with short roots in the groups of rounded

and rectangular roots, which are less susceptible to root resorption compared to the other groups. Among the 74 short central incisors, 62 were in the groups of rounded and rectangular apices (83.78%).

The greater occurrence of root resorption in patients with partial hypodontia was not confirmed in this study, similarly to Lee et al. (1999). It should be highlighted that a detailed analysis of the 60 incisors in the group with partial hypodontia revealed that only 15 incisors (19.48%) exhibited pointed apices, being only two with pipette-shaped apices and one with dilacerated apical morphology. Moreover and surprisingly, no tooth in the group with multiple partial hypodontia presented pointed, dilacerated or pipette-shaped apical morphology, which explains the similar occurrence of root shortening between groups with and without partial hypodontia. However, this does not indicate a greater morphological simplification for this sample particularly.

Discordantly, based on the aforementioned characteristics of such patients, several investigators have reported a correlation between greater root resorption after orthodontic treatment and the presence of partial hypodontia (Kjaer, 1995; Levander et al., 1998a; Mavragani et al., 2000; Consolaro et al., 2001; Velloso et al., 2001). Based on the present results, it was concluded that teeth with pipette-shaped, dilacerated and pointed apical morphology presented greater tendency of external

apical root resorption after corrective orthodontic treatment. However, short teeth and partial hypodontia did not influence the occurrence to root resorption. The susceptibility or individual predisposition to tooth resorptions during orthodontic treatment may be related to the apical morphology.

REFERENCES

- Arte S, Nieminen P, Apajalahti S, Haavikko K, Thesleff I, Pirinen S (2001). Characteristics of Incisor - Premolar Hypodontia in Families. *J. Dent. Res.*, 80: 1445-1450.
- Baumrind S, Korn EL, Boyd RL (1996). Apical root resorption in orthodontically treated adults. *Am. J. Orthod. Dentofac. Orthop.*, 110: 311-320.
- Bellamy LJ, Kokich VG, Weissman JA (2008). Using orthodontic intrusion of abraded incisors to facilitate restoration: the technique's effects on alveolar bone level and root length. *J. Am. Dent. Assoc.*, 139: 725-733.
- Brezniak N, Goren S, Zoizner R, Dinbar A, Arad A, Wasserstein A, Et Al (2004). A Comparison Of Three Methods To Accurately Measure Root Length. *Angle Orthod.*, 74: 86-91.
- Consolaro A, Ennes JP, Oliveira AG, Furquim LZ, Velloso TRG (2001). Partial Anodontia: form and size of remaining teeth and orthodontics implications. In Annual Session of the American Association of Orthodontics; Annals...Toronto: American Association of Orthodontics.
- Consolaro A (2005). Reabsorções dentárias nas especialidades clínicas. 2a ed. Maringá: Dental Press.
- Furquim LZ (2002). Perfil endocrinológico de pacientes ortodônticos com e sem reabsorções dentárias: correlação com a morfologia radicular e da crista óssea alveolar [tese]. Bauru: Faculdade de Odontologia de Bauru, Universidade de São Paulo, p. 122
- Hammer Ø, Harper DAT, Ryan PD (2001). PAST: Paleontological Statistics Software Package for Education and Data Analysis. *Palaeontologia Electronica*, 4: 9. http://palaeo-electronica.org/2001_1/past/issue1_01.htm.
- Kjaer I (1995). Morphological characteristics of dentitions developing excessive root resorption during orthodontic treatment. *Eur. J. Orthod.*, 16: 25-34.
- Kook YA, Park S, Sameshima GT (2003). Peg-shaped and small lateral incisors not at higher risk for root resorption. *Am. J. Orthod. Dentofac. Orthop.*, 123: 253-258.
- Kuroi J, Owman-Moll P, Lundgren D (1997). Reabsorção radicular apical em adultos tratados ortodonticamente. *R. Dental Press Ortodon. Ortop. Facial*, 2: 46-47.
- Lee RY, Artun J, Alonzo TA (1999). Are dental anomalies risk factor for apical root resorption in orthodontic patients? *Am. J. Orthod. Dentofac. Orthop.*, 116: 187-195.
- Levander E, Malmgren O (1988). Evaluation of the risk of root resorption during orthodontic treatment: A study of upper incisors. *Eur. J. Orthod.*, 10: 30-38.
- Levander E, Malmgren O, Stenback K (1998). Apical root resorption during orthodontic treatment of patients with multiple aplasia: a study of maxillary incisors. *Eur. J. Orthod.*, 20: 427-434.
- Levander E, Bajka R, Malmgren O (1998). Early radiographic diagnosis of apical root resorption during orthodontic treatment: a study of maxillary incisors. *Eur. J. Orthod.*, 20: 57-63.
- Mavragani M, Vergari A, Selliseth NJ, Boe OE, Wisth PJ (2000). A radiographic comparison of apical root resorption after orthodontic treatment with a standard edgewise and a straight wire edgewise technique. *Eur. J. Orthod.*, 22: 665-674.
- Mirabella AD, Artun J (1995). Risk factors for apical root resorption of maxillary anterior teeth in adult orthodontic patients. *Am. J. Orthod. Dentofac. Orthop.*, 108: 48-55.
- Nigul K, Jagomagi T (2006). Factors related to apical root resorption of maxillary incisors in orthodontic patients. *Stomatologija*, 8: 76-79.
- Oliveira AG (1988). Associação da anodontia parcial com o tamanho e morfologia dos dentes permanentes, com o apinhamento dentário e com as dimensões do arco dentário de brasileiros. [tese]. Bauru: Faculdade de Odontologia de Bauru, Universidade de São Paulo, p. 116
- Oliveira AG, Consolaro A, Henriques JFC (1991). Relação entre a anodontia parcial e os dentes permanentes de brasileiros. I: Associação de sua ocorrência com o tamanho mesiodistal das coroas dentárias. *Rev. Odont. USP*, 5: 7-14.
- Otis LL, Hong JSH, Tuncay OC (2004). Bone Structure effect on root resorption. *Orthod. Craniofacial.*, 7: 165-177.
- Peck S, Peck L, Kataja, M (1996). Prevalence of tooth agenesis and peg-shaped maxillary lateral incisor associated with palatally displaced canine(PDC) anomaly. *Am. J. Orthod. Dentofac. Orthop.*, 110: 441-443.
- Provenzano MGA (2008). Reabsorção Radicular nos Incisivos Superiores de Pacientes Classe II Esquelética Tratados Ortodonticamente [monografia]. Maringá: Centro Universitário de Maringá.
- Sameshima GT, Sinclair PM (2001). Predicting and preventing root resorption: Part I. diagnostic factors. *Am. J. Orthod. Dentofac. Orthop.*, 119: 505-510.
- Sameshima GT, Sinclair PM (2004). Characteristic of patients with severe root resorption. *Orthod. Craniofac.*, 7: 108-114.
- Smale I, Artun J, Behbehani F, Doopel D, van't Hof M, Kuijpers-Jagtman AM (2005). Apical root resorption 6 months after initiation of fixed orthodontic appliance therapy. *Am. J. Orthod. Dentofac. Orthop.*, 128: 57-67.
- Velloso TRG, Oliveira AG, Furquim LZ, Martins-Ortiz MF (2001). Anodontia parcial: forma e tamanho dos dentes remanescentes e prováveis implicações clínicas In: Reunião Anual da Sociedade Brasileira de Pesquisa Odontológica; 2001; Águas de Lindóia; Pesq. Odontol. Bras.; São Paulo: Universidade de São Paulo.