

# A randomized, double-blind, placebo- and active-controlled, half-head study to evaluate the effects of platelet-rich plasma on alopecia areata

A. Trink,<sup>1</sup> E. Sorbellini,<sup>1</sup> P. Bezzola,<sup>1</sup> L. Rodella,<sup>2</sup> R. Rezzani,<sup>2</sup> Y. Ramot<sup>3</sup> and F. Rinaldi<sup>1</sup>

<sup>1</sup>International Hair Research Foundation (IHRF), Milan, Italy

<sup>2</sup>University of Brescia, Brescia, Italy

<sup>3</sup>Department of Dermatology, Hadassah – Hebrew University Medical Center, Jerusalem, Israel

## Summary

### Correspondence

Fabio Rinaldi.

E-mail: [fabio.rinaldi@studiorinaldi.com](mailto:fabio.rinaldi@studiorinaldi.com)

### Accepted for publication

16 April 2013

### Funding sources

None.

### Conflicts of interest

None declared.

DOI 10.1111/bjd.12397

**Background** Alopecia areata (AA) is a common autoimmune condition, causing inflammation-induced hair loss. This disease has very limited treatment possibilities, and no treatment is either curative or preventive. Platelet-rich plasma (PRP) has emerged as a new treatment modality in dermatology, and preliminary evidence has suggested that it might have a beneficial role in hair growth.

**Objectives** To evaluate the efficacy and safety of PRP for the treatment of AA in a randomized, double-blind, placebo- and active-controlled, half-head, parallel-group study.

**Methods** Forty-five patients with AA were randomized to receive intralesional injections of PRP, triamcinolone acetonide (TrA) or placebo on one half of their scalp. The other half was not treated. Three treatments were given for each patient, with intervals of 1 month. The endpoints were hair regrowth, hair dystrophy as measured by dermoscopy, burning or itching sensation, and cell proliferation as measured by Ki-67 evaluation. Patients were followed for 1 year.

**Results** PRP was found to increase hair regrowth significantly and to decrease hair dystrophy and burning or itching sensation compared with TrA or placebo. Ki-67 levels, which served as markers for cell proliferation, were significantly higher with PRP. No side-effects were noted during treatment.

**Conclusions** This pilot study, which is the first to investigate the effects of PRP on AA, suggests that PRP may serve as a safe and effective treatment option in AA, and calls for more extensive controlled studies with this method.

### What's already known about this topic?

- Platelet-rich plasma (PRP) has emerged as a new treatment modality in dermatology, and preliminary evidence has suggested that it might have a beneficial role in hair growth.
- No study has ever evaluated the effect of PRP on hair growth in patients with alopecia areata (AA).

### What does this study add?

- PRP was found to increase hair regrowth compared with triamcinolone acetonide or placebo, and Ki-67 levels were significantly higher. PRP also decreased the percentage of dystrophic hairs and burning or itching sensation.
- This study, which is the first to investigate the effects of PRP on AA, suggests that PRP may serve as a safe and effective treatment option in AA.

Alopecia areata (AA) is the most common condition to cause inflammation-induced hair loss, having a calculated lifetime risk of 2%.<sup>1</sup> It is characterized by well-demarcated patches of hair loss, which can progress to complete loss of hair from the scalp (alopecia totalis) or from the whole body in severe cases (alopecia universalis).<sup>2</sup> Most patients are relatively young, and disease burden is commonly substantial, leading to overwhelming effects on the patient's quality of life and self esteem. AA is considered an organ-specific autoimmune disease, stemming from loss of the immune privilege of the hair follicle (HF); therefore, therapies are mostly immunosuppressive. Nevertheless, treatment is still a challenge in AA, and no treatment is either curative or preventive.<sup>3</sup> Finding new therapies for this condition, and improving the effectiveness of existing conditions are therefore of utmost importance.

Platelet-rich plasma (PRP) is an autologous preparation of platelets in concentrated plasma.<sup>4</sup> It has been investigated in several disciplines in medicine for its role in wound healing, especially in orthopaedics and dentistry.<sup>5</sup> Recently, it has also been found to be beneficial in dermatology, for example in acne scarring, wound healing and fat transplantation. It has also been shown to promote hair survival and growth, both *in vitro* and *in vivo*.<sup>4,6</sup> However, no study has ever evaluated the effects of PRP on hair growth in patients with AA. It is on this basis that we performed a randomized, double-blind, placebo- and active-controlled, half-head, parallel-group study on 45 patients to evaluate the efficacy and safety of PRP in patients with AA. This is the first time that such extensive and comprehensive assessment methods have been used for evaluating the efficacy of AA treatment.

## Patients and methods

### Study design

This was a randomized, double-blind, placebo- and active-controlled, half-head, parallel-group study. All patients provided written informed consent before participating in the study, which was performed according to the Declaration of Helsinki.

### Patients

The subjects were 45 male and female otherwise healthy patients with AA with chronic, recurring disease of at least 2 years' duration, and having between four and six symmetrically distributed patches of hair loss. For each patient, essential background data were collected at baseline according to the guidelines of the National Alopecia Areata Foundation.<sup>7,8</sup> In accordance with these guidelines, in addition to patient demographics, the following parameters were collected: pattern of hair loss, age of onset, number of relapses, total duration of disease, duration of last relapse and number of AA patches. Table S1 (see Supporting Information) summarizes patient demographics and parameters of disease severity for all patients enrolled in the study. Exclusion criteria included any

other medical condition or other scalp or hair diseases. All patients were evaluated and enrolled into the study at the Rinaldi Dermatologic Clinic, Milan, Italy. Ki-67 evaluation was performed at the University of Brescia, Brescia, Italy.

### Treatment

A statistician who was not involved in the study prepared a randomized allocation table. Patients were randomized to one of three groups: PRP, triamcinolone acetonide (TrA; 2.5 mg mL<sup>-1</sup>, current standard treatment modality) or placebo. For PRP preparation, 36 mL of peripheral blood was centrifuged for 8 min at 70 g. The PRP fraction was separated and suspended with calcium gluconate. The platelet count was on average about 3.5 times higher than in whole blood. One lesion in each patient was treated with intralesional injections of PRP, TrA or placebo. Patients with lesions localized to the temporal and nuchal areas were injected with the test material only on the right side of their scalp, while patients with lesions in the frontal-occipital parts were injected with the test material only in the occipital part of the scalp. The other side was injected with distilled water. In total, three treatments were given for each patient, with an interval of 1 month from each other. As the consistency and colour of the three different treatments differ from each other, the physicians injecting the test material were not blinded to the treatment modalities. Nevertheless, the injections were concealed from the patients themselves, and the injecting personnel were not involved in the evaluation of efficacy of treatment.

### Assessment criteria

All patients were evaluated at four time points: T0, beginning of study; T1, 2 months; T2, 6 months; and T3, 12 months. Each patch was digitally macrophotographed, measured, and evaluated by videodermoscopy for the detection of dystrophic forms and possible skin-associated manifestations.

In accordance with the guidelines of the National Alopecia Areata Foundation, for the evaluation of hair regrowth we used the Severity of Alopecia Tool (SALT) score, which represents hair regrowth as the percentage of change from baseline.<sup>8-10</sup> Macrographs were evaluated by three independent evaluators, who were blinded to treatment modalities.

As patches of AA are commonly accompanied by burning or itching sensation, which often appears during the development of the disease,<sup>11</sup> subjective assessment of burning or itching sensation was also performed. This was determined on a four-point scale: 3, strong sensation; 2, moderate sensation; 1, mild sensation; 0, no itching or burning sensation.

Dermoscopic evaluation was carried out using dermoscopic photomicrographs, which were evaluated by two independent evaluators. This evaluation was intended to determine the number of dystrophic hairs in the patch area. Markers for dystrophic hairs included exclamation-mark hairs, black dots, yellow dots and pigtail regrowing hair. The percentage of

dystrophic hairs was evaluated on a four-point scale: 3, > 50%; 2, 30–50%; 1, 1–29%; 0, no dystrophic hairs.

Levels of Ki-67, a marker for cellular proliferation, were assessed from 20 hairs that were removed from the active margins of patches at each time point. Ki-67 levels were measured by immunohistochemical staining with the immunoperoxidase method using Ki-67 monoclonal antibodies.

A two-sample Student *t*-test was used for comparisons at baseline and during the study. The tests were interpreted with the risk  $\alpha$  of 5%.

## Results

Forty-five patients with AA (20 men, 25 women, mean age 28 years) were enrolled into the study between June 2009 and January 2010. Patients had between four and six symmetrically distributed patches of hair loss (mean 4.85). The duration of last relapse was 1–3 years (mean 1.6), and no treatment had been given to the patients for at least 1 year. Comprehensive assessment of blood parameters showed normal levels for all patients, except for two patients with mild elevation in antinuclear antibody titres (1 : 80) and one patient with elevated cholesterol levels. Groups were homogeneous in terms of age, sex and severity. A summary of patient characteristics is listed in Table 1 (full patient characteristics can be found in Table S1; see Supporting Information).

Administration of both TrA and PRP led to significant hair regrowth in AA lesions compared with placebo, as assessed by three different independent dermatologists (Fig. 1a). Both treatments also led to increased hair regrowth compared with the untreated side of the scalp (Figs 1 and 2 and Figs S1–3; see Supporting Information). Additionally, patients treated with PRP had significantly increased hair regrowth compared with those treated with TrA; 27% of patients treated with TrA achieved complete remission at T3, compared with 60% of patients treated with PRP, which is significantly higher than TrA- and placebo-treated patients.

At T2, 38% of the patients in the TrA group had relapse of disease, while no patients from the PRP group had relapse at this time point. At T3, 71% of the patients in the TrA group experienced relapse of disease, while only 31% of the patients in the PRP group had a relapse. While 96% of the patients in

the PRP group had regrowth of fully pigmented hair from the beginning of hair growth, only 25% in the TrA group had pigmented hair at the beginning of hair regrowth.

In accordance with these results, both PRP and TrA decreased the number of dystrophic hairs as assessed by dermoscopic photomicrographs, and also decreased the itching or burning sensation of the patients (Fig. 1b,c and Fig S4; see Supporting Information). PRP led to significantly better dermoscopy results compared with TrA treatment (Fig. 1b).

Both PRP and TrA significantly increased the levels of Ki-67 in AA patches compared with placebo, and levels were significantly higher after PRP treatment compared with TrA (Fig. 1d). The effect of PRP on Ki-67 levels was evident already after 2 months (T1), and was sustained throughout the study period (1 year, T3). No adverse effects were noted with placebo, TrA or PRP administration.

## Discussion

In this randomized, double-blind, placebo- and active-controlled, half-head, parallel-group study, we have shown that PRP administration leads to major improvements in AA lesions, with 60% of patients achieving complete remission at study termination. It should be noted that spontaneous remissions have been reported to occur in 34–50% of patients at 1 year.<sup>12</sup> Nevertheless, in this study cohort, comprising patients suffering from a chronic, recurring disease, these figures are believed to be lower.

Ki-67 analysis revealed that PRP administration led to a significant increase in Ki-67 levels in AA patches. Both Ki-67 and SALT score parameters were significantly better than with TrA administration, which is currently considered as the treatment of choice for patch-stage AA.<sup>13</sup> This is the first report to establish the efficacy of PRP as a treatment modality in AA, and the first time that such extensive and comprehensive assessment methods have been used to evaluate the efficacy of AA treatment. These comprehensive methods, where patients served as their own control, helped us to eliminate allocation bias. Nevertheless, it should be noted that as AA affects mainly young men and women, the age of the patients enrolled to the study was relatively low. Additionally, our study focused on the more chronic and relapsing form of AA, and not the more common spontaneously remitting type of AA. Therefore, the results may not be applicable to other age groups or to the spontaneously remitting type.

PRP is known to contain more than 20 different growth factors, which are important in promoting cell proliferation and differentiation.<sup>14</sup> These properties are thought to lead to its beneficial effects on acne scarring<sup>15</sup> and wound healing.<sup>16</sup> More recently, the role of PRP in promoting hair growth has also been investigated. Uebel *et al.*<sup>6</sup> have shown that storing hair grafts in PRP can enhance graft survival, improve hair density and stimulate the growth of transplanted follicular units. Still, the mechanisms by which PRP exerts its effects on HFs are still obscure. A recent study has shown *in vitro* that PRP increases the proliferation of dermal papilla cells, and activates

**Table 1** Patient characteristics at baseline

	Placebo	TrA	PRP
Number of patients	15	15	15
Average age (years)	28.1	27.2	28.8
AA duration (years)	4.36	4.64	4.57
Duration of last relapse (years)	1.2	1.5	1.6
Average number of AA patches	4.84	4.93	4.6
SALT score at baseline <sup>a</sup> (%)	32	36	35

AA, alopecia areata; PRP, platelet-rich plasma; SALT, Severity of Alopecia Tool; TrA, triamcinolone acetonide. <sup>a</sup>Calculated according to Olsen *et al.*<sup>8</sup>

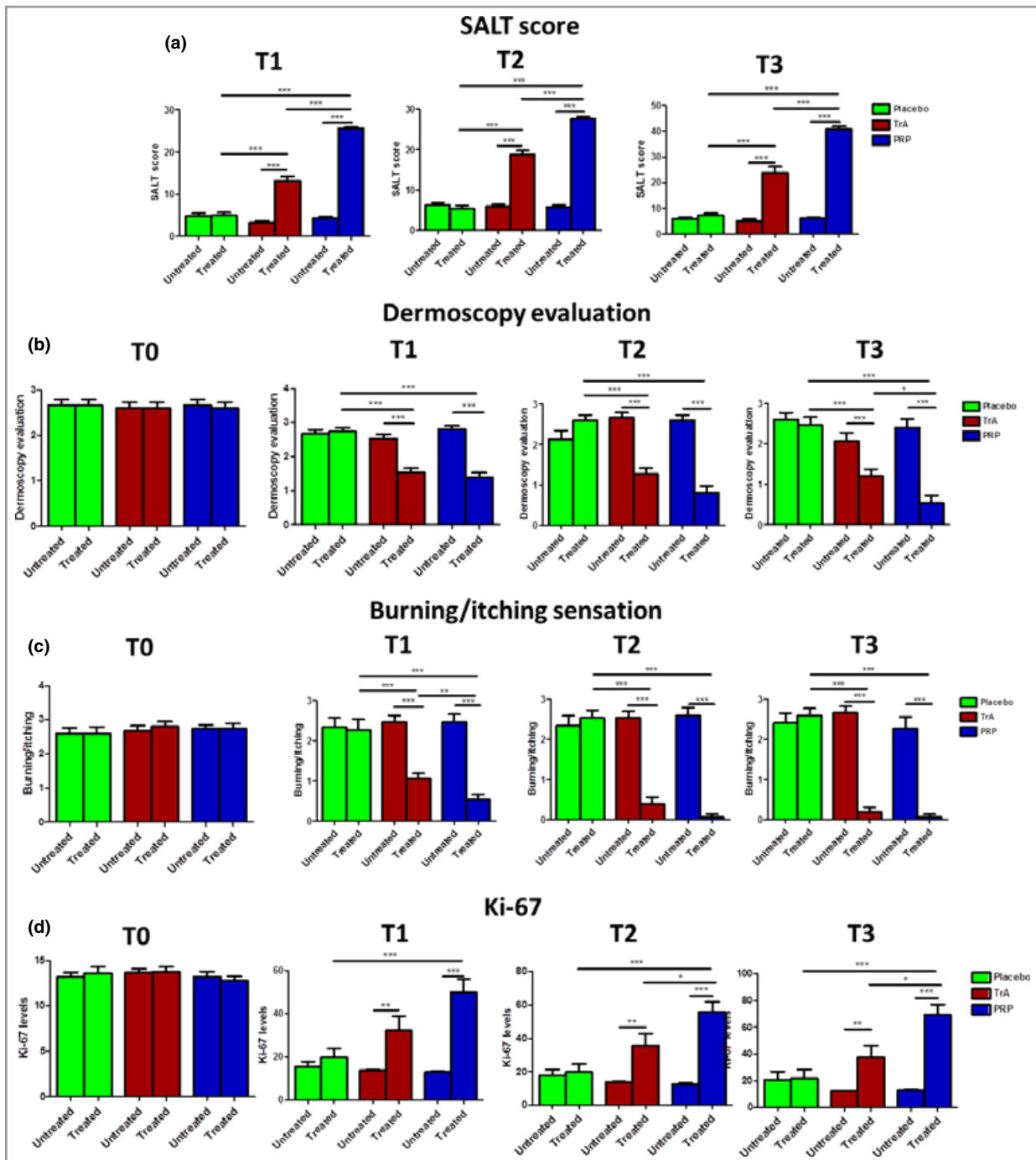
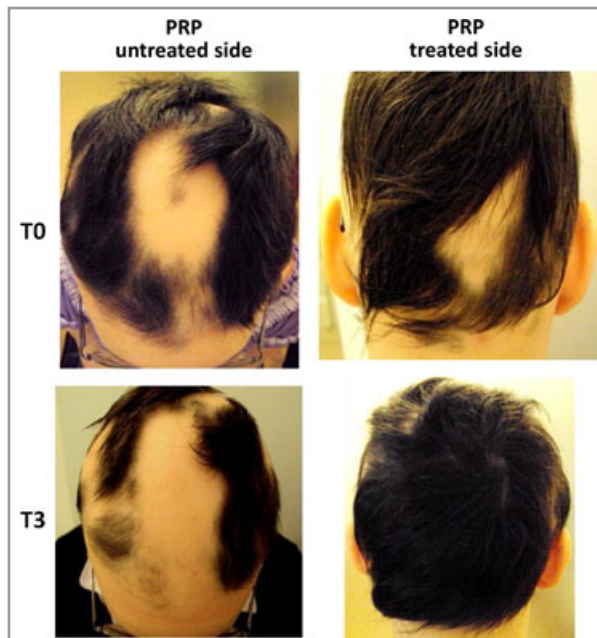


Fig 1. Evaluation scores of (a) Severity of Alopecia Tool (SALT), (b) dermoscopy, (c) burning/itching sensation and (d) Ki-67 levels at four time points: T0, beginning of study; T1, 2 months; T2, 6 months; T3, 1 year. N = 15 for each treatment modality. Student t-test, \*P < 0.05, \*\*P < 0.01, \*\*\*P < 0.001.

the extracellular signal-regulated kinase and Akt signalling pathways.<sup>4</sup> Additionally, fibroblast growth factor-7 and beta-catenin, which are both stimulators of HF growth, were stimulated after PRP administration. Our study gives further support to the growth-promoting effect of PRP in hair, by providing evidence that levels of Ki-67, a marker for cell proliferation, are increased after PRP administration in humans.

In addition to its proliferation-inducing effects, PRP is also a potent anti-inflammatory agent, which can suppress cytokine release and thereby limit local tissue inflammation.<sup>17</sup> As AA is characterized by an extensive inflammatory infiltrate, responsible for secretion of a variety of inflammatory cytokines, it is probable that the anti-inflammatory effects of PRP may be of great benefit in this condition.



**Fig 2.** Clinical photographs of the scalp of a patient with alopecia areata (AA) who was treated on the occipital part of the scalp with platelet-rich plasma (PRP) and on the frontal part of the scalp with placebo. The patch treated with PRP had completely resolved after 1 year (T3), while the frontal patch of AA increased in size.

Taken together, this study suggests PRP as a new treatment modality for AA, being a safe and more efficient alternative to TrA, the current treatment of choice for AA. However, further controlled and randomized studies are needed to validate our findings in a larger cohort of patients.

## References

- Gilhar A, Etzioni A, Paus R. Alopecia areata. *N Engl J Med* 2012; **366**:1515–25.
- Alkhalifah A, Alsantali A, Wang E *et al.* Alopecia areata update: part I. Clinical picture, histopathology, and pathogenesis. *J Am Acad Dermatol* 2010; **62**:177–88, quiz 189–90.
- Alkhalifah A. Topical and intralesional therapies for alopecia areata. *Dermatol Ther* 2011; **24**:355–63.
- Li ZJ, Choi HI, Choi DK *et al.* Autologous platelet-rich plasma: a potential therapeutic tool for promoting hair growth. *Dermatol Surg* 2012; **38**:1040–6.
- Rogers N. Commentary on autologous platelet-rich plasma: a potential therapeutic tool for promoting hair growth. *Dermatol Surg* 2012; **38**:1047–8.
- Uebel CO, da Silva JB, Cantarelli D, Martins P. The role of platelet plasma growth factors in male pattern baldness surgery. *Plast Reconstr Surg* 2006; **118**:1458–66; discussion 1467.
- Olsen E, Hordinsky M, McDonald-Hull S *et al.* Alopecia areata investigational assessment guidelines. National Alopecia Areata Foundation. *J Am Acad Dermatol* 1999; **40**:242–6.
- Olsen EA, Hordinsky MK, Price VH *et al.* Alopecia areata investigational assessment guidelines – Part II. National Alopecia Areata Foundation. *J Am Acad Dermatol* 2004; **51**:440–7.
- Olsen EA. Investigative guidelines for alopecia areata. *Dermatol Ther* 2011; **24**:311–19.
- Price VH, Hordinsky MK, Olsen EA *et al.* Subcutaneous efalizumab is not effective in the treatment of alopecia areata. *J Am Acad Dermatol* 2008; **58**:395–402.
- Hordinsky M. Clinical presentations of alopecia areata. *Dermatol Ther* 2001; **14**:291–6.
- MacDonald Hull SP, Wood ML, Hutchinson PE *et al.* Guidelines for the management of alopecia areata. *Br J Dermatol* 2003; **149**:692–9.
- Alkhalifah A, Alsantali A, Wang E *et al.* Alopecia areata update: part II. Treatment. *J Am Acad Dermatol* 2010; **62**:191–202, quiz 203–4.
- Takikawa M, Nakamura S, Nakamura S *et al.* Enhanced effect of platelet-rich plasma containing a new carrier on hair growth. *Dermatol Surg* 2011; **37**:1721–9.
- Lee JW, Kim BJ, Kim MN, Mun SK. The efficacy of autologous platelet rich plasma combined with ablative carbon dioxide fractional resurfacing for acne scars: a simultaneous split-face trial. *Dermatol Surg* 2011; **37**:931–8.
- Chen TM, Tsai JC, Burnouf T. A novel technique combining platelet gel, skin graft, and fibrin glue for healing recalcitrant lower extremity ulcers. *Dermatol Surg* 2010; **36**:453–60.
- El-Sharkawy H, Kantarci A, Deady J *et al.* Platelet-rich plasma: growth factors and pro- and anti-inflammatory properties. *J Periodontol* 2007; **78**:661–9.

## Supporting Information

Additional Supporting Information may be found in the online version of this article at the publisher's website:

**Fig S1.** Clinical photos of the scalp of a patient who was treated only with placebo. Both areas did not change after 1 year of follow-up.

**Fig S2.** Clinical photos of the scalp of a patient who was treated with TrA and placebo. The patch treated with TrA showed partial regrowth of hair after 1 year (T3), while the placebo-treated patch did not change in size.

**Fig S3.** Clinical photos of the scalp of a patient who was treated with PRP and placebo. The patch treated with PRP showed complete regrowth of hair after 1 year (T3), while the placebo-treated patch did not change in size.

**Fig S4.** Dermoscopic photomicrographs of a patient who was treated with TrA and placebo. The patch treated with TrA shows partial regrowth of hair after 1 year (T3), while the placebo-treated patch shows characteristic black dots, with no change from baseline.

**Table S1.** Demographics, number of relapses, total disease duration, length of last relapse, number of AA patches and SALT score at baseline for the 45 patients recruited for the study.