

# Retinal Arteriolar Vascular Reactivity in Untreated and Progressive Primary Open-Angle Glaucoma

Subba T. Venkataraman,<sup>1,2</sup> Chris Hudson,<sup>1,2</sup> Rony Rachmiel,<sup>1</sup> Yvonne M. Buys,<sup>1</sup> Samuel N. Markowitz,<sup>1</sup> Joseph A. Fisher,<sup>3</sup> Graham E. Trope,<sup>1</sup> and John G. Flanagan<sup>1,2</sup>

**PURPOSE.** To determine (1) the magnitude of retinal arteriolar vascular reactivity to normoxic hypercapnia in patients with untreated primary open-angle glaucoma (uPOAG) or progressive (p)POAG and in control subjects and (2) the effect of treatment with 2% dorzolamide on retinal vascular reactivity in uPOAG.

**METHODS.** The sample comprised 11 patients with uPOAG (after undergoing treatment, they became treated (t)POAG), 17 patients with pPOAG (i.e., manifesting optic disc hemorrhage), and 17 age-similar control subjects. The partial pressure of end-tidal CO<sub>2</sub> (PETCO<sub>2</sub>) was stabilized at 38 mm Hg at baseline. After baseline (10 minutes), normoxic hypercapnia was then induced (15 minutes) with an automated gas flow controller. Retinal arteriolar and optic nerve head (ONH) blood hemodynamics were assessed. The procedures were repeated after treatment with 2% dorzolamide for 2 weeks in tPOAG.

**RESULTS.** Baseline arteriolar hemodynamics were not different across the groups. In control subjects, diameter, velocity, and flow increased ( $P < 0.001$ ) in response to normoxic hypercapnia. There was no change in all three hemodynamic parameters to normoxic hypercapnia in uPOAG, whereas only blood flow increased ( $P = 0.030$ ) in pPOAG. Vascular reactivity was decreased in uPOAG and pPOAG patients compared with that in control subjects. After treatment with topical 2% dorzolamide for 2 weeks, the tPOAG group showed an increase in diameter, velocity, and flow ( $P \leq 0.04$ ) in response to normoxic hypercapnia. Similar trends were noted for ONH vascular reactivity.

**CONCLUSIONS.** A reduced magnitude of arteriolar vascular reactivity in response to normoxic hypercapnia was shown in uPOAG and in pPOAG. Vascular reactivity improved after dorzolamide treatment in POAG. (*Invest Ophthalmol Vis Sci* 2010;51:2043–2050) DOI:10.1167/iovs.09-3630

From the <sup>1</sup>Glaucoma and Retina Research Group, Department of Ophthalmology and Vision Sciences, University of Toronto, Toronto, Ontario, Canada; the <sup>2</sup>School of Optometry, University of Waterloo, Waterloo, Ontario, Canada, and the <sup>3</sup>Department of Anesthesiology, Toronto General Hospital, Toronto, Ontario, Canada.

Supported by an Operating Grant from the Canadian Institutes of Health Research (JGF, CH, YMB, GET), Glaucoma Research Society of Canada (CH, JGF, STV), the American Optometric Foundation, and the William C. Ezell fellowship (STV).

Submitted for publication February 26, 2009; revised August 18 and October 8, 2009; accepted October 22, 2009.

Disclosure: **S.T. Venkataraman**, None; **C. Hudson**, Thornhill Scientific, Inc. (I), P; **R. Rachmiel**, None; **Y.M. Buys**, None; **S.N. Markowitz**, None; **J.A. Fisher**, Thornhill Scientific, Inc. (I), P; **G.E. Trope**, None; **J.G. Flanagan**, None

Corresponding author: Chris Hudson, Department of Ophthalmology and Vision Sciences, University of Toronto, Toronto, Ontario M5T 2S8, Canada; [chudson@scimail.uwaterloo.ca](mailto:chudson@scimail.uwaterloo.ca).

Glaucomatous optic neuropathy (GON) is characterized by the apoptotic loss of retinal ganglion cells and their axons.<sup>1</sup> Elevated intraocular pressure (IOP) has been identified as the primary risk factor in the development and progression of POAG. Abnormal vascular regulation has also been suggested to be involved in the development of POAG.<sup>1–6</sup> Studies have shown decreased optic nerve head (ONH) and retinal blood flow in patients with POAG.<sup>7–11</sup> A decrease in the number of capillaries in the ONH<sup>12</sup> and atrophy of the peripapillary capillaries supplying the retinal nerve fiber layer (RNFL) has also been reported in POAG.<sup>13,14</sup> Color Doppler imaging (CDI) showed reduced peak systolic and end diastolic velocities and increased resistive index in the central retinal artery (CRA) and nasal posterior ciliary artery (PCA) in patients with advanced glaucoma compared with healthy control subjects and those with early glaucoma.<sup>15</sup> In addition, there is also evidence of decreased cerebrovascular blood velocities in POAG.<sup>16</sup>

However, the effect of IOP-lowering medications on ocular blood flow remains poorly understood. Most studies have shown no change in retinal blood flow after treatment with timolol<sup>17,18</sup> or brimonidine<sup>19,20</sup> and a decrease in blood velocity of the ophthalmic artery after treatment with xalatan in POAG.<sup>21</sup> In particular, treatment with carbonic anhydrase inhibitors (CAIs) has been reported to increase ocular hemodynamics in POAG,<sup>18,22–26</sup> to increase cerebral hemodynamics in young subjects,<sup>27</sup> and also to result in an enhanced autoregulation of retinal vessels after treatment with dorzolamide.<sup>28,29</sup> A few studies have found no change<sup>20,30,31</sup> in retinal hemodynamics after CAI treatment. Most of the studies have assessed only the effect of CAIs in either patients receiving prior treatment or after an inadequate washout period. However, previous studies have not assessed the effect of treatment with CAIs on vascular reactivity in response to normoxic hypercapnia in POAG.

Increase in the arterial partial pressure of CO<sub>2</sub> (PaCO<sub>2</sub>) above normal resting values (hypercapnia) results in vasodilation of retinal vessels in healthy volunteers.<sup>32–37</sup> In POAG, studies have shown reduced vascular reactivity with CDI,<sup>9,38</sup> whereas another study has shown normal reactivity of the short posterior ciliary arteries (SPCA).<sup>39</sup> Minimal vascular reactivity of the middle cerebral artery (MCA) to hyperoxia in POAG<sup>16</sup> and, more recently, in healthy control subjects has been reported.<sup>40</sup>

Hypercapnia also results in hyperventilation leading to an unpredictable change in the arterial partial pressure of O<sub>2</sub> (PaO<sub>2</sub>).<sup>41</sup> Slessarev et al.<sup>42</sup> have developed hypercapnic provocations that simultaneously stabilize PaO<sub>2</sub>. This normoxic hypercapnic stimulus has been applied in our laboratory to assess retinal and ONH vascular reactivity in healthy volunteers.<sup>35,37</sup> In this study, we induced normoxic hypercapnia, such that the partial pressure of end-tidal O<sub>2</sub> (PETO<sub>2</sub>) was maintained at physiological resting levels throughout the provocation. The primary purpose of this study was to assess the magnitude of retinal arteriolar and ONH vascular reactivity to

normoxic hypercapnia in patients with untreated (u)POAG, progressive (p)POAG and in healthy control subjects. The secondary purpose was to quantify vascular reactivity in patients with newly treated (t)POAG after topical treatment with 2% dorzolamide for 2 weeks.

## METHODS

### Sample

The study was approved by the Research Ethics Boards of the University Health Network, University of Toronto, and the Office of Research Ethics of the University of Waterloo. All subjects provided signed informed consent before participation after explanation of the nature and possible consequences of the study according to the tenets of the Declaration of Helsinki. Eleven patients with newly diagnosed uPOAG, 17 patients with pPOAG, and 17 healthy age-similar control subjects were recruited. A subgroup of these patients was included to assess ONH vascular reactivity (5 patients with uPOAG, 12 patients with pPOAG, and 12 control subjects). Patients with pPOAG had a clinically identified optic disc hemorrhage within the previous 24 months. The uPOAG group were treated with 1 drop of 2% dorzolamide twice daily for 2 weeks to form the tPOAG group ( $n = 5$ ; ONH assessment). Retinal vascular reactivity was defined as a change in any hemodynamic parameter in the retinal arterioles and capillaries in response to the standardized normoxic hypercapnic provocation.

All participants had a visual acuity of 20/40, or better, and a refractive error less than  $\pm 6.00$  DS and  $\pm 1.50$  DC. They were free of other ocular disease and were nonsmokers. Participants with cardiovascular disorders, uncontrolled systemic hypertension, or diabetes were excluded. Healthy control subjects had no family history of glaucoma or diabetes. All participants were asked to abstain from caffeine-containing food or drinks and were asked to adhere to a low-nitrate diet for at least 12 hours before the study visit(s), since these factors can influence blood flow.

### Gas Delivery System

A sequential gas delivery (SGD) breathing circuit (Hi-Ox<sup>80</sup>; Viasys Health care, Yorba Linda, CA) was modified by placing a rebreathing bag on the exhalation port of a commercial three-valve oxygen delivery system. This breathing circuit is described in detail elsewhere.<sup>35-37,43,44</sup>

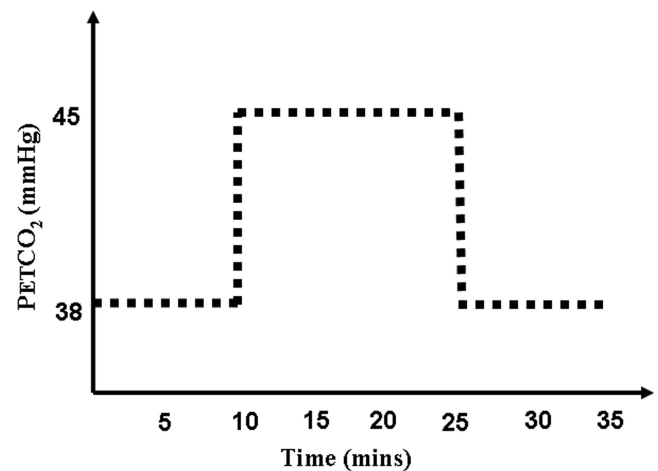
### Retinal Blood Flow Assessment

**Bidirectional Laser Doppler Velocimetry.** The principle and technical details of the laser blood flowmeter (LBF; model 100; Canon, Tokyo, Japan) have been published elsewhere.<sup>35,43,45-50</sup> The LBF is based on the principle of bidirectional laser Doppler velocimetry. It simultaneously measures blood velocity (millimeters per second) and vessel diameter (micrometers) to calculate the rate of blood flow (microliters per minute).

**Scanning Laser Doppler Flowmetry.** The principle and description of scanning laser Doppler flowmetry (SLDF) have been detailed elsewhere.<sup>36,51,52</sup> Briefly, it is based on the principle of the Doppler effect. SLDF measurements were undertaken with a retinal flowmeter (Heidelberg Retina Flowmeter [HRF], software ver. 1.03 W; Heidelberg Engineering GmbH, Dossenheim, Germany).

### Procedures

All participants attended for two visits. Patients with uPOAG returned for a third visit and were then assigned to the tPOAG group. Both eyes were dilated (Mydracil 1%; Alcon Canada, Inc., Mississauga, Ontario, Canada) at visit 1, and only the study eye was dilated during subsequent visits. Visit 1 consisted of an assessment of visual acuity, central visual field assessment (24-2 SITA-standard; Humphrey Visual Field Analyzer 740; Carl Zeiss Meditec, Dublin, CA), scanning laser tomography (Heidelberg Retina Tomograph 2, ver. 3, Heidelberg Engineering, Heidelberg, Germany), stereo fundus photography (model TRC-



**FIGURE 1.** Time-protocol showing the three breathing conditions (baseline for 10 minutes; normoxic hypercapnia during the next 15 minutes and posthypercapnia during the last 10 minutes) with standardized baseline PETCO<sub>2</sub> and a target level of 15% increase in PETCO<sub>2</sub> during normoxic hypercapnia.

50VT; Topcon, Tokyo, Japan) of the ONH, and Goldmann tonometry. Based partly on the results of these assessments, the diagnosis was established by a glaucoma specialist (YMB, GET). One eye was randomly chosen as the study eye.

During the second visit, IOP and blood pressure (BP) were assessed. After an initial 15-minute rest, participants were fitted with a face mask connected to the automated gas flow controller. Three breathing conditions were established such as baseline, normoxic hypercapnia, and posthypercapnia. The timeline of the protocol and the PETCO<sub>2</sub> levels are detailed in Figure 1. At least, three LBF measurements of either the superior or inferior temporal arteriole were obtained in each of the breathing phases. The arteriole of interest was chosen based on the criteria of having a relatively straight vessel segment and also its proximity to the ONH (i.e., the point of measurement was within 1 to 2 disc diameters of the ONH). A similar breathing paradigm was repeated in a subgroup of patients with POAG and control subjects, to assess ONH vascular reactivity with the retinal flowmeter. Optimal focus at the temporal rim of the ONH was established by using the retinal tomograph before retinal flowmetry.<sup>37</sup> PETCO<sub>2</sub>, PETO<sub>2</sub>, and respiration rate were monitored by an automated gas flow controller (RespirAct; Thornhill Research Inc., Toronto, Ontario, Canada). PETCO<sub>2</sub> and PETO<sub>2</sub> are accurate measurements of PaCO<sub>2</sub> and PaO<sub>2</sub>, respectively, in a subject breathing via a sequential gas delivery circuit.<sup>53</sup> Pulse rate, oxygen saturation, and BP (every 2.5 minutes), were monitored by using a rapid response critical care gas analyzer (CardiCap 5; Datex-Ohmeda, Helsinki, Finland).

Patients with uPOAG were then prescribed 2% dorzolamide (Trusopt; Merck Frosst, Canada, Ltd., Kirkland, Quebec, Canada), 1 drop every 12 hours in the study eye for 2 weeks. After 2 weeks, the same procedures were used to retest the tPOAG patients.

### Analysis

**Retinal and ONH Blood Flow Analysis.** LBF analysis software was used to analyze the velocity waveforms after a standardized protocol.<sup>45</sup> SLDF images of the temporal rim of the ONH were analyzed using automated full-field perfusion image analysis (AFFPIA; ver. 3.3; Heidelberg Engineering, Heidelberg, Germany).

Mean ocular perfusion pressure (MOPP) was calculated by the formula

$$\text{MOPP} = \frac{2}{3}[\text{Diastolic} + \frac{1}{3}(\text{Systolic} - \text{Diastolic})] - \text{IOP}$$

**Gas Parameters Analysis.** The gas parameters were analyzed with customized software (Labview, ver. 7.1; National Instruments,

TABLE 1. Age, IOP, and MOPP in All the Groups

Parameter	uPOAG	tPOAG	pPOAG	Controls	P
Age, y	54.0 ± 11.4	54.0 ± 11.4	65.0 ± 7.7*	55.0 ± 6.7	0.002
IOP, mm Hg	22.5 ± 2.2†	18.0 ± 2.0†‡	12.1 ± 2.0	13.0 ± 2.1	<0.001
MOPP, mm Hg	39.0 ± 8.2†	37.6 ± 4.5†	46.7 ± 7.8	44.9 ± 4.5	0.001

Data are the group mean ± SD. *P*-value denotes significance across all groups using one-way ANOVA.

\* Denotes the group that is significantly different when compared to other groups.

† Denotes the group that is significantly different when compared to pPOAG and controls.

‡ Denotes the group that is significantly different when compared to uPOAG.

Austin, TX).  $P_{ETCO_2}$  and  $P_{ETO_2}$  were calculated breath-by-breath as the maximum  $P_{ETCO_2}$  value and minimum  $P_{ETO_2}$  value, respectively, during exhalation.

**Statistical Analysis.** A repeated-measures analysis of variance (reANOVA; Statistica ver. 7.0; StatSoft, Tulsa, OK) with Greenhouse-Geisser correction was used to determine any significant change in retinal arteriolar diameter, blood velocity, or blood flow across the breathing paradigm within each group. A one-way ANOVA (SAS, ver. 9.1.3; SAS, Cary, NC) was used to determine the significance of any difference in the baseline arteriolar hemodynamics, IOP, MOPP, age, and the magnitude of change in vascular reactivity of arteriolar diameter, blood velocity, and blood flow during normoxic hypercapnia across groups. Fisher's least-significant difference (LSD) post hoc test (SAS) was used for comparison between the groups. It identifies groups that are significantly different from other groups at a level of  $P < 0.05$  but does not provide specific *P*-values. The Friedman ANOVA (nonparametric test) was performed on the ONH capillary blood flow results across the breathing paradigm in each group (Statistica, ver. 7.0; StatSoft). A separate reANOVA was performed to determine any signif-

icant change in pulse rate, systolic and diastolic BP, oxygen saturation,  $P_{ETCO_2}$ ,  $P_{ETO_2}$ , or respiration rate across the breathing paradigm within each group.

## RESULTS

The mean age, IOP, and MOPP in each group is provided in Table 1. The group average visual field mean deviation (MD) was  $-1.4$  (SD 1.6) in uPOAG/tPOAG,  $-2.1$  (SD 2.0) in pPOAG, and  $-0.3$  (SD 1.0) in control subjects. The group mean pattern standard deviation (PSD) in uPOAG/tPOAG, pPOAG, and control subjects was 2.6 (SD 2.7), 5.0 (SD 3.0), and 2.0 (SD 0.4), respectively.

The mean percentage increase in  $P_{ETCO_2}$  during hypercapnia in all groups (i.e., uPOAG, pPOAG, and control subjects) was 15.4% (SD 2.5,  $P < 0.001$ ; Table 2). In tPOAG,  $P_{ETCO_2}$  increased by 15.9% (SD 4.6,  $P < 0.001$ ). During normoxic hypercapnia, there was a concomitant increase in the mean

TABLE 2. Gas and Systemic Parameters of the Study Groups in the Three Breathing Conditions

Gas and Systemic Parameters	Baseline	Hypercapnia	Post-hypercapnia	P
<b>uPOAG</b>				
$P_{ETCO_2}$ , mm Hg	38.9 ± 0.7	44.9 ± 1.1	39.2 ± 0.9	<0.001
$P_{ETO_2}$ , mm Hg	105.4 ± 2.6	108.6 ± 2.7	107.4 ± 2.2	<0.001
Respiration rate, breaths/min	17.2 ± 5.4	19.0 ± 3.6	19.0 ± 4.7	NS
Pulse rate, beats/min	71.9 ± 10.4	73.6 ± 11.3	72.7 ± 10.5	NS
Systolic BP, mm Hg	133 ± 17.4	136.9 ± 17.7	134.0 ± 18.6	<0.001
Diastolic BP, mm Hg	81.8 ± 8.7	83.8 ± 8.4	82.8 ± 9.3	NS
O <sub>2</sub> saturation, %	97.8 ± 1.1	98.1 ± 1.0	98.0 ± 1.0	NS
<b>ntPOAG</b>				
$P_{ETCO_2}$ , mm Hg	39.1 ± 1.4	45.2 ± 1.0	38.7 ± 1.4	<0.001
$P_{ETO_2}$ , mm Hg	103.9 ± 5.0	106.5 ± 4.6	106.5 ± 5.2	=0.020
Respiration rate, breaths/min	18.6 ± 5.9	19.4 ± 4.7	20.2 ± 7.1	NS
Pulse rate, beats/min	70.8 ± 8.7	72.5 ± 8.7	72.0 ± 9.1	NS
Systolic BP, mm Hg	124.0 ± 12.3	131.1 ± 11.7	129.0 ± 13.2	=0.009
Diastolic BP, mm Hg	78.6 ± 10.8	78.9 ± 10.7	78.5 ± 10.9	NS
O <sub>2</sub> saturation, %	98.1 ± 0.8	98.3 ± 0.5	98.6 ± 0.7	=0.003
<b>pPOAG</b>				
$P_{ETCO_2}$ , mm Hg	38.9 ± 1.2	45.0 ± 1.5	38.6 ± 1.0	<0.001
$P_{ETO_2}$ , mm Hg	104.8 ± 2.9	108.0 ± 2.9	106.8 ± 2.7	<0.001
Respiration rate, breaths/min	19.9 ± 4.25	20.2 ± 4.8	20.3 ± 4.7	NS
Pulse rate, beats/min	66.0 ± 8.7	67.2 ± 8.1	67.8 ± 7.2	NS
Systolic BP, mm Hg	128.9 ± 13.9	139.4 ± 12.5	134.6 ± 14.9	<0.001
Diastolic BP, mmHg	80.9 ± 6.0	85.2 ± 6.8	83.1 ± 9.1	=0.004
O <sub>2</sub> saturation, %	98.5 ± 0.9	98.6 ± 0.8	98.8 ± 0.8	=0.020
<b>Control</b>				
$P_{ETCO_2}$ , mm Hg	39.0 ± 1.6	45.0 ± 1.4	38.9 ± 1.6	<0.001
$P_{ETO_2}$ , mm Hg	106.1 ± 4.8	109.1 ± 4.3	107.9 ± 4.7	<0.001
Respiration rate, breaths/min	21.0 ± 4.8	21.2 ± 3.8	21.8 ± 3.9	NS
Pulse rate, beats/min	65.5 ± 7.9	67.5 ± 8.7	67.0 ± 8.9	=0.020
Systolic BP, mm Hg	118.5 ± 13.5	125.2 ± 15.7	124.2 ± 12.2	<0.001
Diastolic BP, mm Hg	77.6 ± 7.7	80.7 ± 9.1	79.0 ± 6.6	=0.007
O <sub>2</sub> saturation, %	98.1 ± 1.0	98.5 ± 0.8	98.5 ± 0.9	=0.005

Data are the group mean ± SD. The *P*-value denotes significance of each parameter across the three breathing conditions using reANOVA. NS denotes not significant.

TABLE 3. Resting PETCO<sub>2</sub> in the Study Groups

Groups	uPOAG	tPOAG	pPOAG	Controls
Resting PETCO <sub>2</sub> , mm Hg	36.6 ± 3.0	35.6 ± 3.0	36.5 ± 2.1	35.8 ± 3.6

Data are expressed as the group mean ± SD of measurements taken before the start of the study, with the automated gas flow controller.

PETCO<sub>2</sub> of 3.1% (SD 2.0;  $P \leq 0.020$ ). The PETCO<sub>2</sub> before start of the study is detailed in Table 3.

There was no difference in the baseline retinal arteriolar diameter, blood velocity, and blood flow across groups. However, this finding should be interpreted with caution, as a larger sample size may be necessary to test baseline hemodynamic differences between groups.

In healthy control subjects, diameter, blood velocity, and blood flow increased by +2.3%, +17.9%, and +22.4%, respectively, (reANOVA  $P < 0.001$ ; Figs. 2A-C) in response to normoxic hypercapnia. There was no change in any of the hemodynamic parameters to normoxic hypercapnia in the uPOAG group (Fig. 2). Diameter and blood velocity did not change in the pPOAG group (Fig. 2) but blood flow manifested an increase of +9.1% ( $P = 0.030$ , Fig. 2).

The change in vascular reactivity in response to normoxic hypercapnia was different in terms of velocity (one-way ANOVA  $P = 0.004$ ) and blood flow ( $P = 0.013$ ) between

groups. The magnitude of vascular reactivity in terms of velocity and flow were reduced in uPOAG and pPOAG compared with control subjects and tPOAG (Fisher's LSD post hoc test), suggesting that dorzolamide improved retinal vascular reactivity in the previously untreated patients (i.e., there was a recovery of vascular reactivity between uPOAG and tPOAG states).

The vascular reactivity of the capillaries at the temporal ONH rim showed a nonsignificant increase of +6.1% and +10.9% in the uPOAG and pPOAG groups, respectively, and a +19.8% ( $P < 0.001$ ) increase in blood flow to normoxic hypercapnia in the control subjects (Fig. 3).

In the tPOAG group (previously the uPOAG group), the response to normoxic hypercapnia increased diameter by +3.0% ( $P = 0.040$ , Fig. 2A), velocity by +18.9% ( $P < 0.001$ , Fig. 2B), and flow by +25.8% ( $P < 0.001$ , Fig. 2C). The magnitude of ONH vascular reactivity exhibited a nonsignificant increase of +17.2% ( $P = 0.091$ ) in tPOAG (Fig. 3).

## DISCUSSION

The primary finding of this study was that retinal vascular reactivity was reduced in patients with uPOAG or pPOAG compared with control subjects. The use of a sustained and stable normoxic hypercapnic stimulus was essential for the assessment of retinal arteriolar vascular reactivity so that repeated hemodynamic measurements could be obtained.

Various studies have shown a decrease in homeostatic blood flow in POAG/normal tension glaucoma (NTG) with the

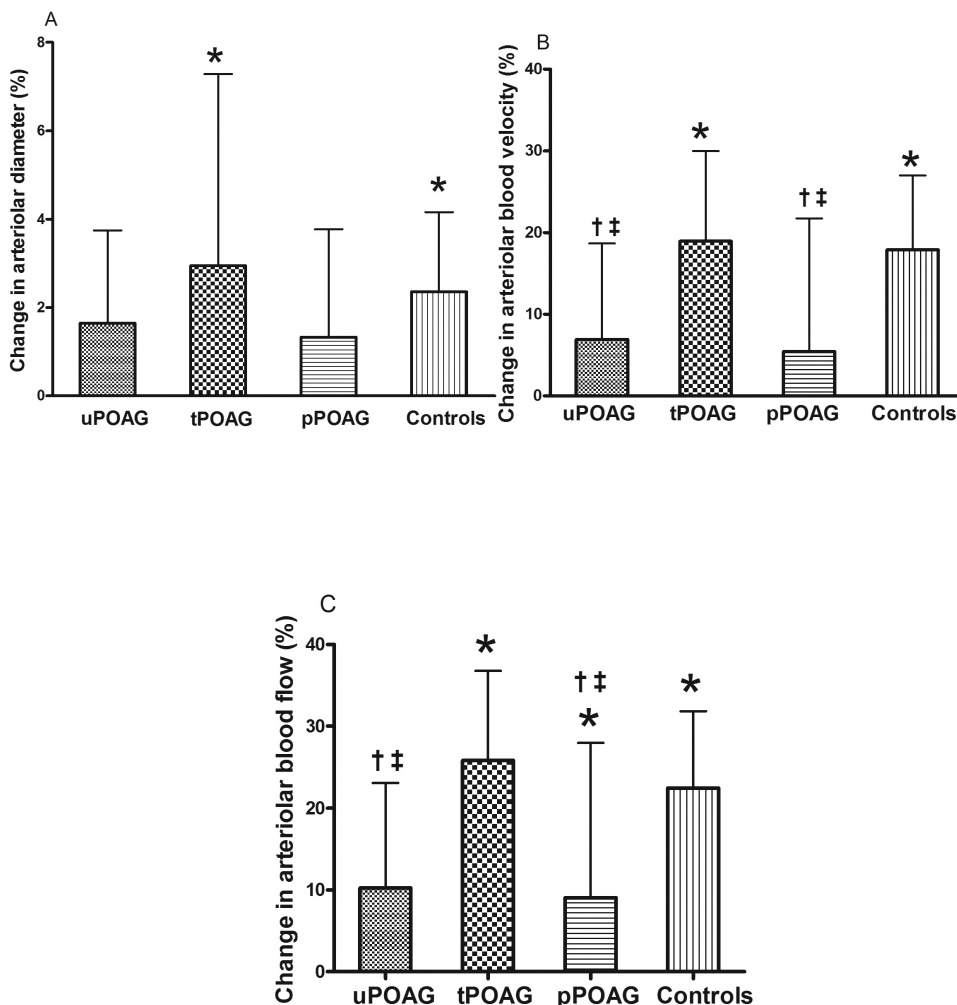
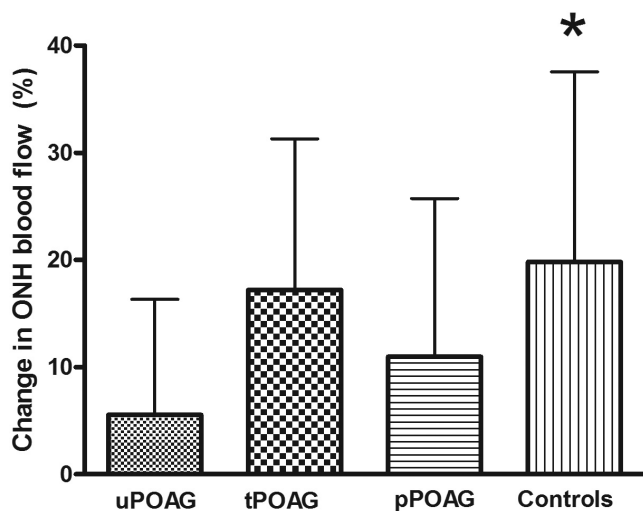


FIGURE 2. The percentage change from baseline in group mean (A) retinal arteriolar diameter, (B) blood velocity, and (C) blood flow in response to normoxic hypercapnia in patients with uPOAG, tPOAG, or pPOAG and control subjects. Error bar, SD (%). \*Significance when compared across the three breathing conditions (baseline, normoxic hypercapnia, and posthypercapnia) within the group at the level of  $P < 0.05$ ; †significant difference when the change in arteriolar hemodynamic parameter in response to normoxic hypercapnia is compared to the change in tPOAG; ‡significant difference when the change in arteriolar hemodynamic parameter in response to normoxic hypercapnia is compared to the change in control subjects.



**FIGURE 3.** The percentage change from baseline in group mean temporal rim ONH blood flow in response to normoxic hypercapnia in patients with uPOAG, tPOAG, pPOAG, and control subjects. Error bar represents SD (%). The sample comprised five patients with uPOAG of mean age 54 years (SD 8.6), 12 patients with pPOAG of mean age 65 years (SD 7.5), and 12 healthy control subjects of mean age of 55 years (SD 7.4). Normoxic hypercapnia was induced identical with the protocol described for retinal arteriolar vascular reactivity assessment. \*Significance when compared across the three breathing conditions (baseline, normoxic hypercapnia and posthypercapnia) within the group at the level of  $P < 0.05$ .

LBF,<sup>10</sup> CDI,<sup>9,54-56</sup> and pulsatile ocular blood flowmeter (POBF).<sup>57</sup> In this study, however, there was no difference between baseline hemodynamic parameters in the uPOAG group compared with the others. The techniques used in previous studies have limitations. CDI requires an experienced operator to obtain reliable measurements and is unable to quantify volumetric blood flow, and it can be difficult to differentiate responses between the CRA and SPCA.<sup>58</sup> Similarly, the results of the POBF can be influenced by ocular rigidity, and the measurement is dominated by the choroidal circulation.<sup>59</sup> The use of the LBF in our study offers an alternative approach, since it objectively quantifies volumetric retinal blood flow in real units. The results of the study are not directly comparable to those of earlier work, in that the vascular reactivity was assessed in the retinal arterioles of uPOAG patients, whereas in most other studies, patients were already receiving IOP-lowering medications.

Most studies have assessed only the homeostatic blood flow in POAG/NTG patients, often with CDI,<sup>7-9,15</sup> and have found contradictory results. Gugleta et al.<sup>60</sup> showed that ONH blood flow increased in patients with vasospasm and decreased in patients without vasospasm when assessed with LDF in response to hypercapnia. In the present study, a decrease in the magnitude of vascular reactivity to normoxic hypercapnia was noted in both the uPOAG and pPOAG groups, but all, apart from the uPOAG group, showed evidence of increased retinal blood flow in response to normoxic hypercapnia. Similarly, a reduction in the vascular reactivity of the CRA with CDI has also been shown in POAG.<sup>38</sup> Of interest, NTG patients showed an increase in the peak systolic velocity of the CRA and posterior ciliary artery (PCA) and also end-diastolic velocity of the OA during hypercapnia with no change in control subjects.<sup>9</sup> Similarly, with CDI, vasodilation of the retrobulbar vessels was noted during hypercapnia in POAG.<sup>39</sup> With the LBF, Fekke and Pasquale<sup>61</sup> also showed evidence of abnormal retinal arteriolar response in POAG to posture change compared with that in control subjects. This altered response was seen only in a

subgroup of patients who were treated with IOP-lowering medications.

As glaucoma is primarily characterized by either compromise of the ONH perfusion or mechanical compression of the lamina cribrosa, we also assessed the response of the capillaries at the temporal rim of the ONH to normoxic hypercapnia. Several studies have demonstrated a decrease in blood flow in the ONH in POAG with different assessment techniques.<sup>62-65</sup> In this study, we showed a reduced percentage magnitude of ONH vascular reactivity in a subgroup of patients with uPOAG or pPOAG compared with control subjects and patients with tPOAG. We have previously shown that the percentage change in capillary vascular reactivity is comparable to that of arteriolar vascular reactivity in young healthy volunteers.<sup>37</sup> An interesting finding of the ONH substudy was that the vascular reactivity of the ONH capillary bed was reduced in percentage in the uPOAG and pPOAG groups to an extent similar to that of the superior/inferior temporal arteriole. The vascular reactivity of the control subjects and the recovery of vascular reactivity after dorzolamide treatment in the tPOAG group were similar between the arteriolar and ONH sites.

A secondary finding of this study was that vascular reactivity improved to the level of the control subjects in the tPOAG group, after 2 weeks of treatment with 2% dorzolamide. It has been suggested that CAIs, in particular dorzolamide, may improve blood flow. However, many of the earlier studies have used an additional IOP-lowering medication<sup>24-26</sup> or atypical methods of drug delivery.<sup>22</sup> In this study, vascular reactivity was assessed in patients who had never undergone treatment. The inclusion of previously untreated patients was essential, to avoid any residual vascular effects of medication on the response of the vasculature. In addition, we also assessed vascular reactivity in patients with progressive disease (i.e., currently receiving treatment, have achieved target IOP reduction, and have a history of optic disc hemorrhage), as there is evidence that these patients exhibit vascular dysregulation.<sup>66,67</sup> This study supports the previous findings since patients with pPOAG exhibited a reduced vascular reactivity.

Previous studies have assessed the effect of treatment on homeostatic retinal blood flow, rather than on vascular reactivity, per se, in POAG. Retinal vascular reactivity in response to hypercapnia has been assessed with various techniques in healthy subjects after treatment with dorzolamide, and no change has been found.<sup>68</sup> Our study is the first to investigate the effect of dorzolamide on retinal vascular reactivity in response to normoxic hypercapnia in patients with POAG. Vascular reactivity improved after short-term treatment of POAG with dorzolamide. However, there was no difference across the groups in the baseline arteriolar hemodynamics after treatment. The controversy in terms of baseline hemodynamic findings of our study and previous reports is probably due to differences in experimental design and blood flow quantification techniques, including the concomitant use of other medications and also due to variation in the duration of dorzolamide administration. In the absence of a nonpharmacologic control treatment that resulted in a similar reduction in IOP, such as laser trabeculoplasty, it is not evident whether the improvement in vascular reactivity after treatment is due to the reduction in IOP or is a direct effect of dorzolamide on the vasculature. Nevertheless, in this study, there was no difference in the MOPP between uPOAG and tPOAG, indicating that the improvement in retinal vascular reactivity in tPOAG is due to a direct effect of dorzolamide on the retinal vasculature. This finding should be interpreted with caution until comparison to a group with a nonpharmacologically induced reduction in IOP is established.

In a related study (Hudson C, et al. *IOVS* 2008;49:ARVO E-Abstract 4609), plasma levels of biochemical markers of en-

dothelial function—namely endothelin-(ET)1 and cyclic guanosine monophosphate (cGMP i.e., a surrogate marker of nitric oxide), were assessed in uPOAG, tPOAG, pPOAG, and control subjects at baseline and during normoxic hypercapnia. A relationship was found between the change in the magnitude of vascular reactivity and the change in biochemical markers during normoxic hypercapnia in the control subjects. ET-1 levels were found to be repeatedly lower in uPOAG and tPOAG, suggesting that there is a systemic endothelial dysfunction in uPOAG that remains unaltered, even after short-term treatment. In addition, there was a strong association between baseline arteriolar blood flow and baseline levels of cGMP in uPOAG and tPOAG. These results further validate the functional vascular reactivity abnormalities observed in this study.

In previous studies, isoxic hypercapnia was induced to provoke an increase in retinal blood flow in healthy subjects and in those with POAG.<sup>9,32,39,69,70</sup> However, in these studies, there was no report or monitoring of concomitant changes in  $P_{ET}O_2$ . In addition, elevated  $P_{ET}CO_2$  levels were achieved by dynamic end-tidal forcing (DEF), an integral proportional feedback system that makes breath-by-breath corrections to inspired gases, but this technique does not actually target the arterial concentration of  $CO_2$  ( $PaCO_2$ ). DEF requires a complex setup including multiple large gas tanks and tubing. In contrast, the RespirAct system is about the size of a desktop computer and supplies gas at about the subject's minute ventilation to a small fitted face mask. An additional advantage is that RespirAct uses a sequential gas delivery breathing circuit whereby  $P_{ET}CO_2$  has been shown to be equal to  $PaCO_2$ . With DEF, there is a large variation between  $P_{ET}CO_2$  and  $PaCO_2$ , and so the latter is not precisely known from noninvasive measures.<sup>53,71</sup>

The study has several limitations. Retinal vascular reactivity of either the superior or inferior temporal arteriole was assessed. Previous work has shown a similar magnitude of vascular reactivity in response to hyperoxia in all quadrants,<sup>72</sup> whereas another study showed similar baseline arteriolar blood flow in the superior and inferior quadrants of the retina.<sup>73</sup> Unpublished work from our group has also shown a similar magnitude of vascular reactivity in the superior and inferior temporal arterioles. Based on this evidence, it is reasonable to interchangeably use either the superior or the inferior temporal retinal arteriole to assess vascular reactivity. There was a significant increase in systolic BP in uPOAG and tPOAG and in both systolic and diastolic BP in pPOAG and control subjects. The magnitude of increase in BP during normoxic hypercapnia, however, was small ( $\leq 8\%$ ) and well within the range of autoregulation of the retinal vessels and would not be expected to have a major influence on vascular reactivity.<sup>74,75</sup> In addition, there was a small increase in peripheral  $O_2$  saturation ( $SpO_2$ ) in the tPOAG, pPOAG, and control subjects during normoxic hypercapnia. To put this in perspective, one can typically measure physiologic responses to changes in  $SpO_2$  that reach approximately 70%.<sup>76,77</sup> There are no known physiological responses to changes of 1% in the range of nearly saturated hemoglobin (97%–99%). Also, the control subjects were not age-matched to the pPOAG group, since patients with pPOAG were those who had relatively long-standing glaucoma compared with those with uPOAG and were also those who had shown progression. Previous work in our laboratory has shown a negligible difference in the magnitude of the vascular reactivity in healthy subjects over the range of ages of the subjects in this study (Rose PA, et al. *IOVS* 2007;48:ARVO E-Abstract 2266).

## CONCLUSIONS

Arteriolar vascular reactivity was reduced in uPOAG and pPOAG patients compared to healthy subjects. Vascular reac-

tivity improved after short-term treatment of uPOAG with dorzolamide. Based on a substudy, the ONH capillary bed provided findings similar to those of the retinal arterioles. It is not clear whether this improvement was a direct effect of the medication or a secondary effect of the decrease in IOP.

## Acknowledgments

The authors thank Erin Harvey for her assistance in the statistical analysis.

## References

1. Mozaffarieh M, Grieshaber MC, Flammer J. Oxygen and blood flow: players in the pathogenesis of glaucoma. *Mol Vis*. 2008;14:224–233.
2. Henry E, Newby DE, Webb DJ, Hadoke PW, O'Brien CJ. Altered endothelin-1 vasoreactivity in patients with untreated normal-pressure glaucoma. *Invest Ophthalmol Vis Sci*. 2006;47:2528–2532.
3. Haefliger IO, Dettmann E, Liu R, et al. Potential role of nitric oxide and endothelin in the pathogenesis of glaucoma. *Surv Ophthalmol*. 1999;43(suppl 1):S51–S58.
4. Chung HS, Harris A, Evans DW, Kagemann L, Garzoni HJ, Martin B. Vascular aspects in the pathophysiology of glaucomatous optic neuropathy. *Surv Ophthalmol*. 1999;43(suppl 1):S43–S50.
5. Flammer J, Haefliger IO, Orgul S, Resink T. Vascular dysregulation: a principal risk factor for glaucomatous damage? *J Glaucoma*. 1999;8:212–219.
6. Flammer J, Orgul S. Optic nerve blood-flow abnormalities in glaucoma. *Prog Retin Eye Res*. 1998;17:267–289.
7. Plange N, Kaup M, Weber A, Arend KO, Remky A. Retrobulbar haemodynamics and morphometric optic disc analysis in primary open-angle glaucoma. *Br J Ophthalmol*. 2006;90:1501–1504.
8. Kaiser HJ, Schoetzau A, Stumpf D, Flammer J. Blood-flow velocities of the extraocular vessels in patients with high-tension and normal-tension primary open-angle glaucoma. *Am J Ophthalmol*. 1997;123:320–327.
9. Harris A, Sergott RC, Spaeth GL, Katz JL, Shoemaker JA, Martin BJ. Color doppler analysis of ocular vessel blood velocity in normal-tension glaucoma. *Am J Ophthalmol*. 1994;118:642–649.
10. Berisha F, Feke GT, Hirose T, McMeel JW, Pasquale LR. Retinal blood flow and nerve fiber layer measurements in early-stage open-angle glaucoma. *Am J Ophthalmol*. 2008;146:466–472.
11. Butt Z, McKillop G, O'Brien C, Allan P, Aspinall P. Measurement of ocular blood flow velocity using colour doppler imaging in low tension glaucoma. *Eye*. 1995;9:29–33.
12. Gottanka J, Kuhlmann A, Scholz M, Johnson DH, Lütjen-Drecoll E. Pathophysiologic changes in the optic nerves of eyes with primary open angle and pseudoexfoliation glaucoma. *Invest Ophthalmol Vis Sci*. 2005;46:4170–4181.
13. Kornzweig AL, Eliasoph I, Feldstein M. Selective atrophy of the radial peripapillary capillaries in chronic glaucoma. *Arch Ophthalmol*. 1968;80:696–702.
14. Tezel G, Kass MA, Kolker AE, Wax MB. Comparative optic disc analysis in normal pressure glaucoma, primary open-angle glaucoma, and ocular hypertension. *Ophthalmology*. 1996;103:2105–2113.
15. Liu CJ, Chiou HJ, Chiang SC, Chou JC, Chou YH, Liu JH. Variations in ocular hemodynamics in patients with early and late glaucoma. *Acta Ophthalmol Scand*. 1999;77:658–662.
16. Harris A, Zarfati D, Zalish M, et al. Reduced cerebrovascular blood flow velocities and vasoreactivity in open-angle glaucoma. *Am J Ophthalmol*. 2003;135:144–147.
17. Lubeck P, Orgul S, Gugleta K, Gherghel D, Gekkieva M, Flammer J. Effect of timolol on anterior optic nerve blood flow in patients with primary open-angle glaucoma as assessed by the Heidelberg Retina Flowmeter. *J Glaucoma*. 2001;10:13–17.
18. Fuchsjaeger-Mayrl G, Wally B, Rainer G, et al. Effect of dorzolamide and timolol on ocular blood flow in patients with primary open angle glaucoma and ocular hypertension. *Br J Ophthalmol*. 2005;89:1293–1297.
19. Costagliola C, Parmeggiani F, Ciancaglini M, D'Oronzo E, Mastropasqua L, Sebastiani A. Ocular perfusion pressure and visual

- field indice modifications induced by alpha-agonist compound (clonidine 0.125%, apraclonidine 1.0% and brimonidine 0.2%) topical administration. an acute study on primary open-angle glaucoma patients. *Ophthalmologica*. 2003;217:39–44.
20. Simsek T, Yanik B, Conkbayir I, Zilelioglu O. Comparative analysis of the effects of brimonidine and dorzolamide on ocular blood flow velocity in patients with newly diagnosed primary open-angle glaucoma. *J Ocul Pharmacol Ther*. 2006;22:79–85.
  21. Martinez A, Sanchez M. Retrobulbar haemodynamic effects of the latanoprost/timolol and the dorzolamide/timolol fixed combinations in newly diagnosed glaucoma patients. *Int J Clin Pract*. 2007;61:815–825.
  22. Rassam SM, Patel V, Kohner EM. The effect of acetazolamide on the retinal circulation. *Eye*. 1993;7:697–702.
  23. Zeitz O, Matthiessen ET, Reuss J, et al. Effects of glaucoma drugs on ocular hemodynamics in normal tension glaucoma: a randomized trial comparing bimatoprost and latanoprost with dorzolamide. *BMC Ophthalmol*. 2005;5:6.
  24. Martinez A, Sanchez M. A comparison of the effects of 0.005% latanoprost and fixed combination dorzolamide/timolol on retrobulbar haemodynamics in previously untreated glaucoma patients. *Curr Med Res Opin*. 2006;22:67–73.
  25. Uva MG, Longo A, Reibaldi M, Reibaldi A. The effect of timolol-dorzolamide and timolol-pilocarpine combinations on ocular blood flow in patients with glaucoma. *Am J Ophthalmol*. 2006;141:1158–1160.
  26. Siesky B, Harris A, Cantor LB, et al. A comparative study of the effects of brinzolamide and dorzolamide on retinal oxygen saturation and ocular microcirculation in patients with primary open-angle glaucoma. *Br J Ophthalmol*. 2008;92:500–504.
  27. Harris A, Tippke S, Sievers C, Picht G, Lieb W, Martin B. Acetazolamide and CO<sub>2</sub>: Acute effects on cerebral and retrobulbar hemodynamics. *J Glaucoma*. 1996;5:39–45.
  28. Nagel E, Vilser W, Lanzl IM. Retinal vessel reaction to short-term IOP elevation in ocular hypertensive and glaucoma patients. *Eur J Ophthalmol*. 2001;11:338–344.
  29. Nagel E, Vilser W, Lanzl I. Functional analysis of retinal vessel diameter reaction to artificially raised intraocular pressure in glaucoma patients with and without dorzolamide therapy. *Vasa*. 2002;31:230–234.
  30. Bergstrand IC, Heijl A, Harris A. dorzolamide and ocular blood flow in previously untreated glaucoma patients: a controlled double-masked study. *Acta Ophthalmol Scand*. 2002;80:176–182.
  31. Faingold D, Hudson C, Flanagan J, et al. Assessment of retinal hemodynamics with the canon laser blood flowmeter after a single dose of 2% dorzolamide hydrochloride eyedrops. *Can J Ophthalmol*. 2004;39:506–510.
  32. Chung HS, Harris A, Halter PJ, et al. Regional differences in retinal vascular reactivity. *Invest Ophthalmol Vis Sci*. 1999;40:2448–2453.
  33. Arend O, Harris A, Martin BJ, Holin M, Wolf S. Retinal blood velocities during carbogen breathing using scanning laser ophthalmoscopy. *Acta Ophthalmol (Copenb)*. 1994;72:332–336.
  34. Dorner GT, Garhoefer G, Zawinka C, Kiss B, Schmetterer L. Response of retinal blood flow to CO<sub>2</sub>-breathing in humans. *Eur J Ophthalmol*. 2002;12:459–466.
  35. Venkataraman ST, Hudson C, Fisher JA, Flanagan JG. Novel methodology to comprehensively assess retinal arteriolar vascular reactivity to hypercapnia. *Microvasc Res*. 2006;72:101–107.
  36. Venkataraman ST, Hudson C, Fisher JA, Flanagan JG. The impact of hypercapnia on retinal capillary blood flow assessed by scanning laser doppler flowmetry. *Microvasc Res*. 2005;69:149–155.
  37. Venkataraman ST, Hudson C, Fisher JA, et al. Retinal arteriolar and capillary vascular reactivity in response to isoxic hypercapnia. *Exp Eye Res*. 2008;87(6):535–542.
  38. Sines D, Harris A, Siesky B, et al. The response of retrobulbar vasculature to hypercapnia in primary open-angle glaucoma and ocular hypertension. *Ophthalmic Res*. 2007;39:76–80.
  39. Hosking SL, Harris A, Chung HS, et al. Ocular haemodynamic responses to induced hypercapnia and hyperoxia in glaucoma. *Br J Ophthalmol*. 2004;88:406–411.
  40. Kisilevsky M, Mardimae A, Slessarev M, Han J, Fisher J, Hudson C. Retinal arteriolar and middle cerebral artery responses to combined hypercarbic/hyperoxic stimuli. *Invest Ophthalmol Vis Sci*. 2008;49:5503–5509.
  41. Rhoades RA. Ventilation and mechanics of breathing. In: Rhoades RA, Tanner GA, eds. *Medical Physiology*. Philadelphia: Lippincott Williams & Wilkins; 2003;309–336.
  42. Slessarev M, Fisher JA, Volgyesi G, et al, inventors. A new method and apparatus to attain and maintain target end tidal gas concentrations. International patent WO/2007/012170. January 2, 2007.
  43. Gilmore ED, Hudson C, Preiss D, Fisher J. Retinal arteriolar diameter, blood velocity, and blood flow response to an isocapnic hyperoxic provocation. *Am J Physiol Heart Circ Physiol*. 2005;288:H2912–H2917.
  44. Gilmore ED, Hudson C, Venkataraman ST, Preiss D, Fisher J. Comparison of different hyperoxic paradigms to induce vasoconstriction: Implications for the investigation of retinal vascular reactivity. *Invest Ophthalmol Vis Sci*. 2004;45:3207–3212.
  45. Guan K, Hudson C, Flanagan JG. Variability and repeatability of retinal blood flow measurements using the canon laser blood flowmeter. *Microvasc Res*. 2003;65:145–151.
  46. Nagaoka T, Mori F, Yoshida A. Retinal artery response to acute systemic blood pressure increase during cold pressor test in humans. *Invest Ophthalmol Vis Sci*. 2002;43:1941–1945.
  47. Kida T, Harino S, Sugiyama T, Kitanishi K, Iwahashi Y, Ikeda T. Change in retinal arterial blood flow in the contralateral eye of retinal vein occlusion during glucose tolerance test. *Graefes Arch Clin Exp Ophthalmol*. 2002;240:342–347.
  48. Riva CE, Feke GT, Eberli B. Bidirectional LDV system for the absolute measurement of blood speed in retinal vessels. *Appl Opt*. 1979;18:2301–2306.
  49. Feke GT, Goger DG, Tagawa H, Delori FC. Laser doppler technique for absolute measurement of blood speed in retinal vessels. *IEEE Trans Biomed Eng*. 1987;34:673–680.
  50. Sato E, Feke GT, Menke MN, Wallace McMeel J. Retinal haemodynamics in patients with age-related macular degeneration. *Eye*. 2006;20:697–702.
  51. Michelson G, Welzenbach J, Pal I, Harazny J. Automatic full field analysis of perfusion images gained by scanning laser doppler flowmetry. *Br J Ophthalmol*. 1998;82:1294–1300.
  52. Roff EJ, Harris A, Chung HS, et al. Comprehensive assessment of retinal, choroidal and retrobulbar haemodynamics during blood gas perturbation. *Graefes Arch Clin Exp Ophthalmol*. 1999;237:984–990.
  53. Ito S, Mardimae A, Han J, et al. Non-invasive prospective targeting of arterial P(CO<sub>2</sub>) in subjects at rest. *J Physiol*. 2008;586:3675–3682.
  54. Cellini M, Possati GL, Profazio V, Sbrocca M, Caramazza N, Caramazza R. Color doppler imaging and plasma levels of endothelin-1 in low-tension glaucoma. *Acta Ophthalmol Scand Suppl*. 1997(244):11–13.
  55. Bjarnhall G, Tomic L, Mishima HK, Tsukamoto H, Alm A. Retinal mean transit time in patients with primary open-angle glaucoma and normal-tension glaucoma. *Acta Ophthalmol Scand*. 2007;85:67–72.
  56. Zeitz O, Galambos P, Wagenfeld L, et al. Glaucoma progression is associated with decreased blood flow velocities in the short posterior ciliary artery. *Br J Ophthalmol*. 2006;90:1245–1248.
  57. O' Brien C. Pulsatile ocular blood flow in normal pressure glaucoma. In: Pillunat LE, Harris A, Anderson DR Greve EL, eds. *Current Concepts on Ocular Blood Flow in Glaucoma*. The Hague, The Netherlands: Kugler Publications; 1999;111–117.
  58. Harris A, Kagemann L, Ehrlich R, Rospigliosi C, Moore D, Siesky B. Measuring and interpreting ocular blood flow and metabolism in glaucoma. *Can J Ophthalmol*. 2008;43:328–336.
  59. Garzozzi HJ, Shoham N, Chung HS, Kagemann L, Harris A. Ocular blood flow measurements and their importance in glaucoma and age-related macular degeneration. *Isr Med Assoc J*. 2001;3:443–448.
  60. Gugleta K, Orgul S, Hasler P, Flammer J. Circulatory response to blood gas perturbations in vasospasm. *Invest Ophthalmol Vis Sci*. 2005;46:3288–3294.
  61. Feke GT, Pasquale LR. Retinal blood flow response to posture change in glaucoma patients compared with healthy subjects. *Ophthalmology*. 2008;115(2):246–252.

62. Kerr J, Nelson P, O'Brien C. A comparison of ocular blood flow in untreated primary open-angle glaucoma and ocular hypertension. *Am J Ophthalmol*. 1998;126:42-51.
63. Grunwald JE, Piltz J, Hariprasad SM, DuPont J. Optic nerve and choroidal circulation in glaucoma. *Invest Ophthalmol Vis Sci*. 1998;39:2329-2336.
64. Nicolela MT, Hnik P, Drance SM. Scanning laser doppler flowmeter study of retinal and optic disk blood flow in glaucomatous patients. *Am J Ophthalmol*. 1996;122:775-783.
65. Schwartz B, Rieser JC, Fishbein SL. Fluorescein angiographic defects of the optic disc in glaucoma. *Arch Ophthalmol*. 1977;95:1961-1974.
66. Grieshaber MC, Terhorst T, Flammer J. The pathogenesis of optic disc splinter haemorrhages: a new hypothesis. *Acta Ophthalmol Scand*. 2006;84:62-68.
67. Siegner SW, Netland PA. Optic disc hemorrhages and progression of glaucoma. *Ophthalmology*. 1996;103:1014-1024.
68. Sponsel WE. Topical carbonic anhydrase inhibitors and visual function. In: Pillunat E, Harris A, Anderson DR, Greve EL, eds. *Current Concepts on Ocular Blood Flow in Glaucoma*. The Hague, The Netherlands: Kugler Publications; 1999;251-265.
69. Harris A, Anderson DR, Pillunat L, et al. Laser doppler flowmetry measurement of changes in human optic nerve head blood flow in response to blood gas perturbations. *J Glaucoma*. 1996;5:258-265.
70. Hosking SL, Evans DW, Embleton SJ, Houde B, Amos JF, Bartlett JD. Hypercapnia invokes an acute loss of contrast sensitivity in untreated glaucoma patients. *Br J Ophthalmol*. 2001;85:1352-1356.
71. Robbins PA, Conway J, Cunningham DA, Khamnei S, Paterson DJ. A comparison of indirect methods for continuous estimation of arterial PCO<sub>2</sub> in men. *J Appl Physiol*. 1990;68:1727-1731.
72. Jean-Louis S, Lovasik J, Kergoat H. Systemic hyperoxia and retinal vasomotor responses. *Invest Ophthalmol Vis Sci*. 2005;46:1714-1720.
73. Feke GT, Tagawa H, Deupree DM, Goger DG, Sebag J, Weiter JJ. Blood flow in the normal human retina. *Invest Ophthalmol Vis Sci*. 1989;30:58-65.
74. Dumskyj MJ, Eriksen JE, Dore CJ, Kohner EM. Autoregulation in the human retinal circulation: assessment using isometric exercise, laser doppler velocimetry, and computer-assisted image analysis. *Microvasc Res*. 1996;51:378-392.
75. Riva CE, Grunwald JE, Petrig BL. Autoregulation of human retinal blood flow. an investigation with laser doppler velocimetry. *Invest Ophthalmol Vis Sci*. 1986;27:1706-1712.
76. Lucy SD, Kowalchuk JM, Hughson RL, Paterson DH, Cunningham DA. Blunted cardiac autonomic responsiveness to hypoxemic stress in healthy older adults. *Can J Appl Physiol*. 2003;28:518-535.
77. Radwan L, Koziorowski A, Maszczyk Z, et al. Respiratory response to inspiratory resistive load changes in patients with obstructive sleep apnea syndrome (in Polish). *Pneumonol Alergol Pol*. 2000; 68:44-56.