

## Obscure gastrointestinal bleeding persisting for a decade: a rare manifestation of a common disease

Surinder S. Rana, Vishal Sharma, Chalapathi Rao, Kartar Singh, Deepak K. Bhasin

Post Graduate Institute of Medical Education and Research (PGIMER), Chandigarh, India

### Abstract

Celiac disease commonly presents with diarrhea but variable presentation with anemia, osteoporosis, incidental recognition, and liver function abnormalities is also known. Overt blood loss is uncommon in celiac disease. We present the case of a 60-year-old female who presented with obscure gastrointestinal blood loss for more than a decade necessitating multiple transfusions and was eventually diagnosed to have celiac disease. After introduction of gluten-free diet, her symptoms improved and there has been no recurrence of gastrointestinal bleeding.

**Keywords** celiac disease, capsule endoscopy, gastrointestinal bleeding

*Ann Gastroenterol* 2012; 25 (3): 1-3

### Introduction

Celiac disease is an autoimmune enteropathy precipitated by exposure to gluten. Although initially considered a rare malabsorption syndrome in children, it is now recognized as a systemic disorder with varying presentation and multiple manifestations affecting both pediatric and adult populations [1]. It commonly presents with diarrhea in children, whereas in adults the presentation is variable and may include anemia, osteoporosis, and liver function abnormalities [1,2]. Although occult gastrointestinal blood loss is common [3], overt bleeding is uncommon. We present the case of a 60-year-old lady who presented with obscure gastrointestinal blood loss for more than a decade necessitating multiple transfusions until celiac disease was eventually diagnosed.

### Case report

A 60-year-old lady was referred to us for melena of 12 years duration. She had earlier undergone repeat evaluations at multiple private hospitals. She was initially diagnosed with duodenal ulcer and underwent exploratory laparotomy with pyloroplasty and truncal vagotomy. However, she rebelled

and thereafter underwent antrectomy with retrocolic gastrojejunostomy. She also received proton pump inhibitors, and eradication therapy for *Helicobacter pylori*. Despite the aggressive treatment, the patient continued to have melena episodes and required multiple blood transfusions (~170 transfusions over a decade). Her esophagogastroduodenoscopy, colonoscopy and barium meal follow through did not reveal any abnormality. Contrast enhanced computed tomography (CECT) of abdomen and the technetium-99m red blood cell scan were also non-contributory. A capsule endoscopy was performed by placing capsule in efferent limb under endoscopic guidance (Fig. 1). It revealed multiple ulcers of varying sizes throughout the small bowel (Fig. 2). As there was no history of non steroidal anti inflammatory drugs (NSAID) ingestion, a possibility of chronic non-specific small bowel ulcers was kept. Antinuclear antibodies and anti-neutrophil cytoplasmic antibodies were negative. However, IgA anti-tissue transglutaminase and anti-gliadin antibodies were positive. Antegrade double balloon enteroscopy was performed and biopsies were obtained from ulcer edge as well as mucosal folds. Histological examination of the biopsies from the ulcer edge revealed chronic inflammation and from the mucosal folds revealed increased intraepithelial lymphocytes. She was started on prednisolone 40 mg daily along with gluten-free diet. The melena subsided and thereafter steroids were tapered off. She remains well after one-year follow up, there has been no recurrence of bleeding and her hemoglobin has risen to 13.4 mg/dL.

Department of Gastroenterology, Post Graduate Institute of Medical Education and Research (PGIMER), Chandigarh 160012, India

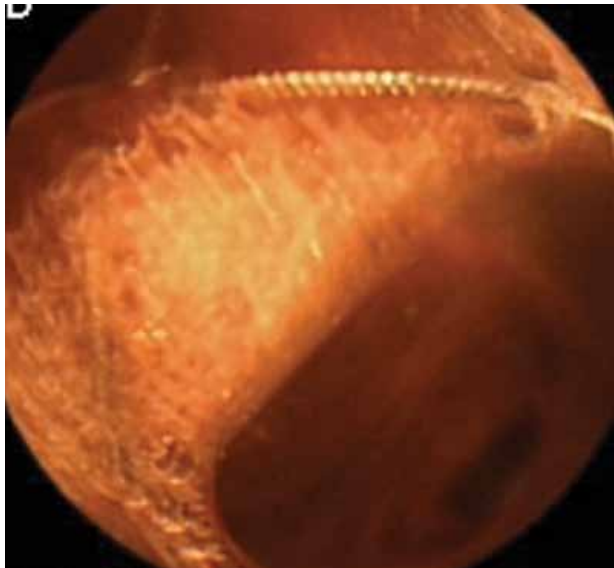
Conflict of Interest: None

Correspondence to: Dr Surinder Singh Rana, Asst. Prof., Department of Gastroenterology, Postgraduate Institute of Medical Education and Research (PGIMER), Chandigarh, India 160012, Tel: +91 172 2749123, Fax: +91 172 2744401, e-mail: drsurinderrana@yahoo.co.in, sonalisurinder@yahoo.co.in

Received 16 February 2012; accepted 26 March 2012

### Discussion

Celiac disease is an autoimmune disorder characterized by sensitivity to gluten. It can be complicated by occurrence



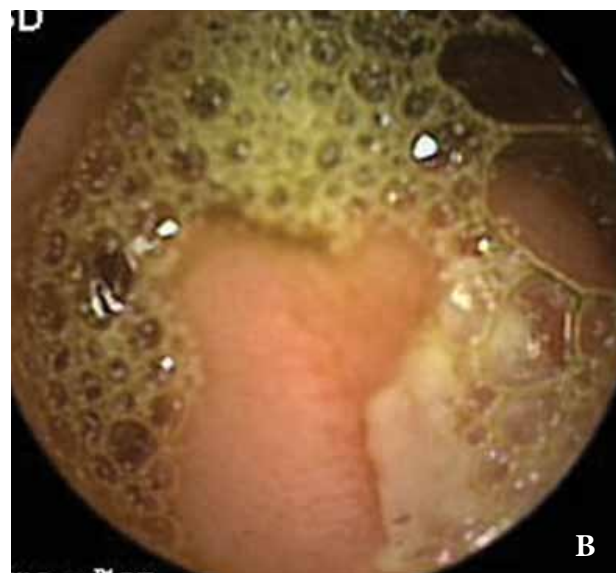
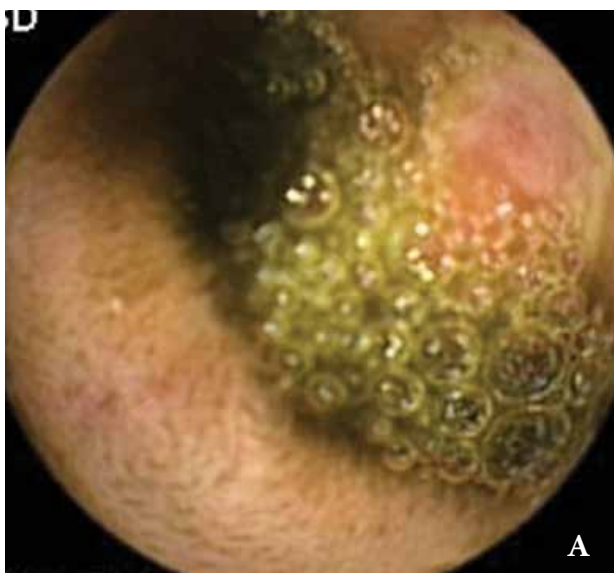**Figure 1** Videocapsule endoscope being deployed in the efferent loop. Wires of the dormia seen around the capsule endoscope

of ulcerative jejunoileitis or malignant transformation [1]. Celiac disease has been associated with occult gastrointestinal blood loss [3,4]. In a study in children, occult gastrointestinal blood loss was reported in around one-fourth of patients and improved with gluten-free diet [3]. However, another study which utilized the more specific direct radiochromium-labeled red blood cells indicated that the blood loss was infrequent and the traditional colorimetric test were false positive probably due to excess intestinal cell loss or malabsorption affecting peroxidase containing foods [5]. Overt gastrointestinal blood loss in a patient with celiac disease may point to presence of

malignancy like enteropathy-associated T cell lymphoma or adenocarcinoma, ulcerative jejunoileitis, vitamin K deficiency, occasionally due to varices, which may result from associated portal vein thrombosis or chronic liver disease, or other unrelated causes [6-9].

In our patient the capsule endoscopy revealed multiple ulcers in the small bowel. She was initially thought of having chronic non-specific ulceration of the small bowel. However, eventually celiac disease was found to be the cause of overt gastrointestinal bleeding in our patient. She improved after treatment with steroids and initiation of gluten-free diet and remained well with a rise in hemoglobin even after steroids were tapered. The long duration of the disease, the complete response after the introduction of gluten-free diet, and the absence of refractory symptoms suggest that these ulcers may have been benign. The etiology of these ulcers is not clear but, similar to the aphthous ulcers in the oral cavity of celiac disease patients, they might be immunologically mediated. Absence of relapse on gluten-free diet also suggests that the exclusion of the antigen from the diet may have led to remission.

The surgically altered proximal bowel also complicated the evaluation of the patient. Capsule endoscopy may be indicated in patients with celiac disease for evaluation of acute abdominal pain or occult gastrointestinal blood loss and is particularly useful in evaluation of complicated celiac disease [10,11]. In certain cases of iron deficiency anemia the diagnosis of celiac disease may be established only after capsule endoscopy [12]. The present report is also important as it highlights celiac disease with mucosal ulcerations as a cause of overt gastrointestinal blood loss. An earlier report had implicated celiac-related lymphocytic gastritis as a cause of fatal gastrointestinal blood loss even in the absence of malignant transformation [13]. Mucosal ulceration of the small intestine, especially jejunum, is common in celiac disease [14]. To conclude, celiac disease



**Figure 2** Ulcer in the jejunum (A) and ulcer with normal surrounding small bowel mucosa (B)

must be considered in the differential diagnosis in patients with obscure gastrointestinal bleeding and when ulcers are visualized in the small bowel.

## References

1. Green PH, Cellier C. Celiac disease. *N Engl J Med* 2007;**357**:1731-1743.
2. Arya S, Rana SS, Sinha SK, Nagi B, Bhasin DK. Celiac disease and chronic calcific pancreatitis with pancreas divisum. *Gastrointest Endosc* 2006;**63**:1080-1081.
3. Shamir R, Levine A, Yalon-Hacohen M, et al. Faecal occult blood in children with coeliac disease. *Eur J Pediatr* 2000;**159**:832-834.
4. Fine KD. The prevalence of occult gastrointestinal bleeding in celiac sprue. *N Engl J Med* 1996;**334**:1163-1167.
5. Mant MJ, Bain VG, Maguire CG, Murland K, Yacyshyn BR. Prevalence of occult gastrointestinal bleeding in celiac disease. *Clin Gastroenterol Hepatol* 2006;**4**:451-454.
6. Yang DH, Myung S, Chang H, et al. A Case of Enteropathy-associated T-cell lymphoma presenting with recurrent hematochezia. *Korean J Gastroenterol* 2003;**42**:527-532.
7. Borulf S, Pettersson A, von Schéele C. Celiac disease and malabsorption of vitamin K with severe gastrointestinal hemorrhage. *Lakartidningen* 1976;**73**:1428-1429.
8. Thorburn D, Stanley AJ, Foulis A, Campbell Tait R. Coeliac disease presenting as variceal haemorrhage. *Gut* 2003;**52**:758.
9. Dogan M, Sal E, Akbayram S, Peker E, Cesur Y, Oner AF. Concurrent celiac disease, idiopathic thrombocytopenic purpura and autoimmune thyroiditis: a case report. *Clin Appl Thromb Hemost* 2011;**17**:E13-E16.
10. Rana SS, Bhasin DK. Gastrointestinal bleeding: capsules, balloons and spirals! *Endoscopy* 2010;**42**:53-57.
11. Culliford A, Daly J, Diamond B, Rubin M, Green PH. The value of wireless capsule endoscopy in patients with complicated celiac disease. *Gastrointest Endosc* 2005;**62**:55-61.
12. Muhammad A, Pitchumoni CS. Newly detected celiac disease by wireless capsule endoscopy in older adults with iron deficiency anemia. *J Clin Gastroenterol* 2008;**42**:980-983.
13. Weiss AA, Yoshida EM, Poulin M, Gascoyne RD, Owen DA. Massive bleeding from multiple gastric ulcerations in a patient with lymphocytic gastritis and celiac sprue. *J Clin Gastroenterol* 1997;**25**:354-357.
14. Baer AN, Bayless TM, Yardley JH. Intestinal ulceration and malabsorption syndromes. *Gastroenterology* 1980;**79**:754-765.