

Unrelated Cord Blood Transplantation in a Pair of Siblings with X-linked Severe Combined Immunodeficiency: The Case for Early Diagnosis and Transplant

PYT CHAN, MHK HO, DKL CHEUK, TL LEE, SY HA, YL LAU

Abstract

Haematopoietic stem cell transplantation is a curative therapy for severe combined immunodeficiency (SCID) after the first success forty years ago. We report a pair of Chinese siblings with X-linked SCID who had very different transplant outcomes. The elder brother was diagnosed late and had multiple infections before transplant. He developed severe graft-versus-host-disease and life-threatening haemolytic anaemia. He died from overwhelming septicaemia. The younger brother, who was diagnosed at birth and infection-free before transplant, underwent an uneventful transplant. Early transplant within the first 3 months of life results in over 90% disease-free survival. Newborn screening is now being pursued to achieve this goal.

Key words

Haematopoietic stem cell transplantation; Haemolytic anaemia; Pneumatosis intestinalis; Severe combined immunodeficiency; Transplant outcome

Introduction

Severe combined immunodeficiency (SCID) is a fatal disorder characterised by profound deficiencies of T-lymphocyte and B-lymphocyte function with extreme susceptibility to infections. The incidence of SCID is estimated to be 1:50,000 to 1:500,000 live births. In Taiwan, the incidence is 1:53,196.¹ Approximately 50% of SCID is X-linked. The incidence of autosomal recessive SCID will be higher in countries where consanguineous marriage is common. The defect in X-linked SCID has been identified as a mutation in the gene for the IL-2 receptor common gamma chain (IL2RG). Mutational studies of 42 Chinese

and Southeast Asian infants with SCID have shown IL2RG mutation in 45% of cases. Haematopoietic stem cell transplantation (HSCT) is the main curative treatment for SCID. Timing of the transplant and presence of pre-transplant infections significantly affect the transplant outcome.

Sibling 1: Poor Transplant Outcome Attributed to Delayed Diagnosis (Figure 1)

Case 1 was the second son of a non-consanguineous Chinese couple. The first son died at 3 months old with profound lymphopenia, BCGosis and intractable diarrhoea. This child had developed chronic diarrhoea and numerous infections since 2 months old. Seen by various physicians in Xiamen and Sichuan, he was referred to Hong Kong for suspected immunodeficiency and failure to thrive at 24 months old. On admission, he had profound lymphopenia ($0.62 \times 10^9/L$, Normal 1.5-7). He had previously been given intravenous immunoglobulin. IgG level was relatively normal while IgM and IgA levels were both low. Lymphocyte subset showed presence of B cells, near absent CD3 T cells and near absent NK cells. Lymphocyte proliferation was seriously impaired to below 10% of normal proliferation. Clinical phenotype was compatible with T-B+NK- XL SCID. Genetic study identified mutation of a previously unreported mutation of a gene encoding

Department of Paediatrics and Adolescent Medicine, Queen Mary Hospital, 102 Pokfulam Road, Pokfulam, Hong Kong, China

PYT CHAN (陳英婷) FHKCPaed, FHKAM(Paed)
MHK HO (何學工) FHKCPaed, FHKAM(Paed)
DKL CHEUK (卓家良) FHKCPaed, FHKAM(Paed)
TL LEE (李子良) FHKCPaed, FHKAM(Paed)
SY HA (夏修賢) FHKCPaed, FHKAM(Paed)
YL LAU (劉宇隆) FHKCPaed, FHKAM(Paed)

Correspondence to: Prof YL LAU

Received January 21, 2013

for IL2RG, which was a C>T substitution at nucleotide position 996 according to Genbank report, resulting in Arginine codon (CGA) change to Stop codon (TGA).

A 5/6 human leucocyte antigen (HLA)-matched unrelated cord blood transplantation was performed at 27 months old without conditioning. Mycophenolate mofetil (MMF), cyclosporine (CyA) and methylprednisolone were used as graft-versus-host disease (GVHD) prophylaxis. Donor and recipient blood groups were A+ and B+, respectively. T-cell engraftment was evident on post-transplant Day 23. CD3 T cell count reached normal range on Day 45. Mutational study by polymerase chain reaction sequencing of IL2RG gene showed small amount of normal signal.

He had pneumatosis intestinalis presented as diffuse abdominal pain on post-transplant Day 8 (Figures 1A & 1B). This was followed by grade 4 skin, gastrointestinal and liver GVHD (Figure 2). Immunosuppression was stepped up. Octreotide was tried without effect. Good partial control was achieved using infliximab and basiliximab.

He developed anemic symptoms with tea-coloured urine since Day 40. Mixed type autoimmune haemolytic anaemia was evident by the presence of warm and cold red blood cell antibodies in his serum. Four doses of rituximab were given and four sessions of plasmapheresis were carried out (Figure 1D). He required daily red cell transfusion in order to keep his haemoglobin above 6 g/dL. A total of 42 units of packed cells were given within 10 weeks. Ferritin rose up to >20000 pmol/L (normal 34-367 pmol/L) on Day 63. No improvement in haemolysis was observed despite laparoscopic splenectomy performed on Day 80. There was great difficulty obtaining matched blood for transfusion due to abundant red cell antibodies.

He further deteriorated on Day 94 with fever and extensive erythroderma. Stool and blood cultures grew carbapenem-resistant *Escherichia coli*. Haemolysis became refractory to transfusion. The sufferings of the child and futility of treatment led to redirection of care. He passed away on Day 112 due to fulminant septicaemia.

Sibling 2: Good Outcome After HSCT Related to Early Diagnosis

Mother was pregnant when she brought her second son to Hong Kong. Antenatally, cordocentesis done at Chong Qing Children's Hospital showed low T cell count. Sex of the fetus was not examined as it was prohibited in China. The third son was born at 38 weeks with a birth weight of 3300 g by lower segment Caesarean section in Hong Kong. Physical examination was unremarkable. He was kept under reverse isolation in hospital since birth. Differential blood

count showed lymphopenia ($0.7 \times 10^9/L$). Lymphocyte subset at birth showed near absent CD3 T cells, low NK cells and near normal B cell count. Immunoglobulin pattern was normal. Genetic study confirmed the same mutation as his brother. Cotrimoxazole, nystatin and 2-weekly intravenous immunoglobulin prophylaxis was given. He was free of infections before transplant. Reduced intensity conditioning regimen with treosulphan (36 g/m^2) and fludarabine was given without adverse reaction. A 6/6 HLA matched unrelated cord blood transplantation was performed at 3 months old. Neutrophil engraftment ($>0.5 \times 10^9/L$ on the first of 3 consecutive days) and platelet engraftment (unsupported counts $>20 \times 10^9/L$) were noted on post-transplant Day 15 and Day 30, respectively. Nasal swab on Day 40 was positive for rhinovirus but the baby was asymptomatic. MMF and cyclosporine were stopped on Day 30 and Day 102, respectively. At 8 months post-transplant, he contracted influenza A infection but he recovered quickly. He was thriving well with body weight along the 50th percentile and body height along the 25th percentile. Mutational analysis showed full restoration of wild type signal. Lymphocyte subset at 8 months post-transplant showed normal T cell, B cell and NK cell numbers. Regular intravenous immunoglobulin was stopped 12 months after transplant. He is now well without medications at 12 months post-transplant.

Discussion

An absolute lymphocyte count of less than $2.5 \times 10^9/L$ in a sick infant with recurrent infections must raise alarm for SCID. Excessive or early deaths in the males on the maternal side is suggestive of X-linked SCID while parental consanguinity raises the likelihood of autosomal recessive SCID. The ultimate goal of haematopoietic stem cell transplantation for SCID is to achieve immune reconstitution of normal T, B, and NK cells.

A recent large European cohort, based on the experience from 23 centres investigating 699 patients with SCID, provides important prognostic factors that determine transplant outcomes.² Younger age at transplant, absence of viral infection and absence of respiratory impairment before transplant, B+SCID, genotypical and phenotypical donors are associated with better prognosis for 10-year survival. Survival is better and treatment-related morbidity is lower in infants who have been transplanted in the first 3.5 months of life.^{3,4} Infants transplanted in the newborn period have higher numbers of T cells in the first 3 years of life than those who are transplanted later.⁵

There are three types of donors for SCID transplantation: matched sibling, mismatched related donor or matched unrelated donor. The advantages of matched sibling donor include less time to work up the donor and obtain the graft, excellent engraftment rates despite no conditioning regimen, low rates of severe acute GVHD, minimal chronic GVHD and rapid immune reconstitution. Nevertheless, matched sibling donor is only available in 15-20% of SCID cases.

Mismatched related donor (MMRD), i.e. parents, are usually highly motivated donor. Since one HLA haplotype is usually fully disparate between the donor and the recipient, the stem cell source must be T-cell depleted to avoid life threatening GVHD.

Grunebaum et al reported 80.5% survival in SCID patient treated with matched unrelated donor grafts (cord blood or bone marrow).⁶ A recent European cohort study from 32 centres with 249 SCID patients showed that the MMRD

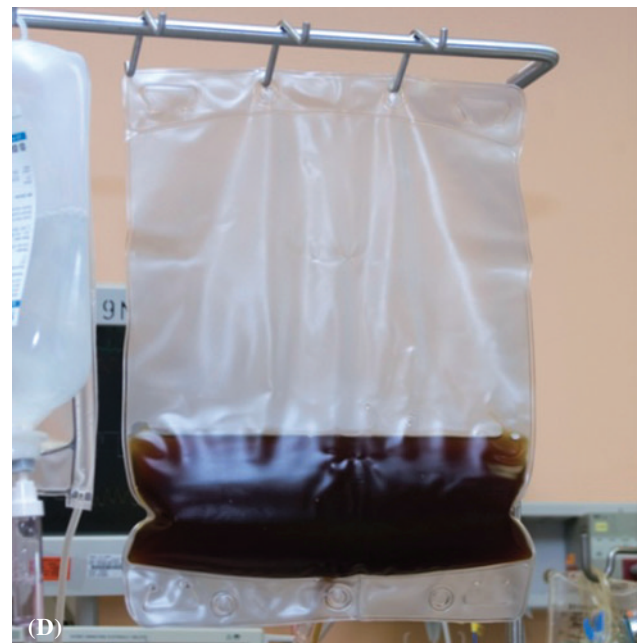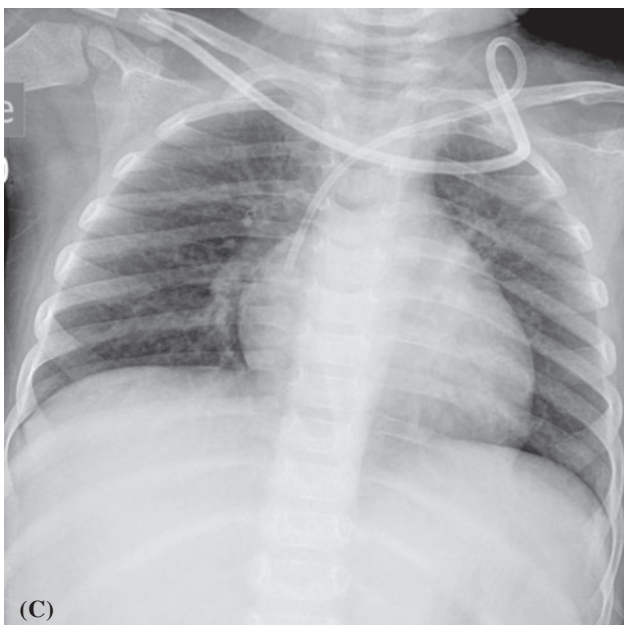
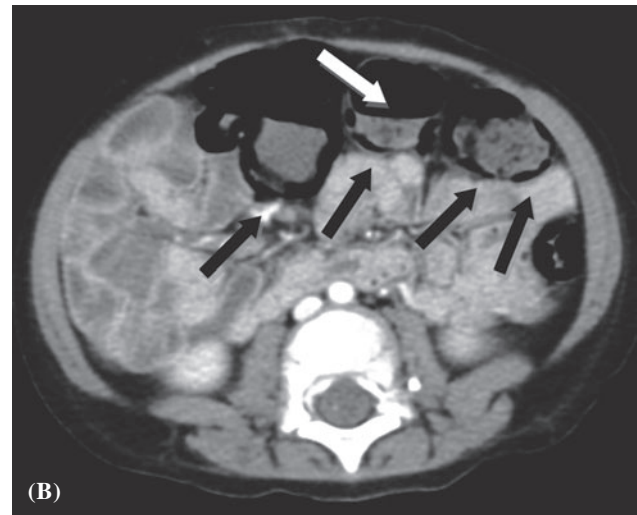
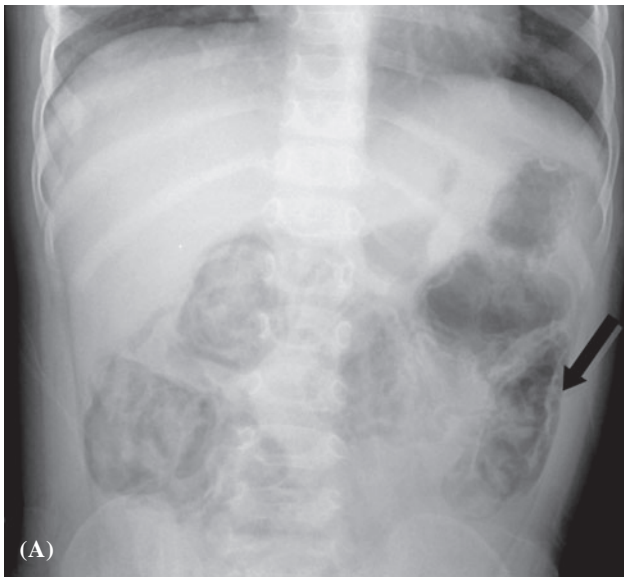


Figure 1 Clinical imaging/photographs of sibling 1. (A) Abdominal X-ray showing pneumatosis intestinalis. (B) Abdominal CT scan with contrast showing pneumatosis intestinalis. Black arrows (↑) indicating intestines with intramural gas. White arrow (↑) indicating lumen of intestine. (C) Chest radiograph showing interstitial pneumonitis due to *Mycoplasma pneumoniae*. Note the absence of thymus shadow. (D) Tea-colour plasma product obtained from plasmapheresis.

transplant and unrelated cord blood transplant (UCBT) groups did not differ in terms of T-cell engraftment, CD 4+ and CD3+ recoveries, engraftment rates and 5-year survival. Immunoglobulin replacement was discontinued sooner after UCBT but these patients had higher incidence of chronic GVHD. Higher proportion of patients in the MMRD group had to undergo a repeated transplantation as a result of poor graft function compared with UCBT recipients.⁷

Infants with X-linked SCID (T-B+NK-) do not have T-lymphocytes and thus cannot reject transplanted T-cells. Although B-cells are present, they may be deficient in number and function. The presence of host B cells can affect the engraftment of B cells. Pre-transplant conditioning is given to optimise the chance of B cell engraftment. Without pre-transplant conditioning, two-thirds of infants with X-linked SCID required immunoglobulin treatment after transplant.⁸ No conditioning regimen was given to sibling 1

as the risk of him dying from reactivation of microbial infections after conditioning outweighed the risk of non-engraftment.

Sibling 2 was given a reduced intensity conditioning (RIC) regimen with treosulphan and fludarabine. These agents, compared to conventional myeloablative agents (e.g. busulphan and cyclophosphamide), have less drug toxicities, fewer infection-related complications, and less long term complications on growth and development.

Mycophenolate mofetil and cyclosporine were used as GVHD prophylaxis for both transplantations. Sibling 1 was given prednisolone even before the transplantation as there was an expected higher chance of hyper acute GVHD without conditioning.

The incidence of pneumatosis intestinalis in children with combined immunodeficiency is about 5%. Children usually present in the early post-transplant period

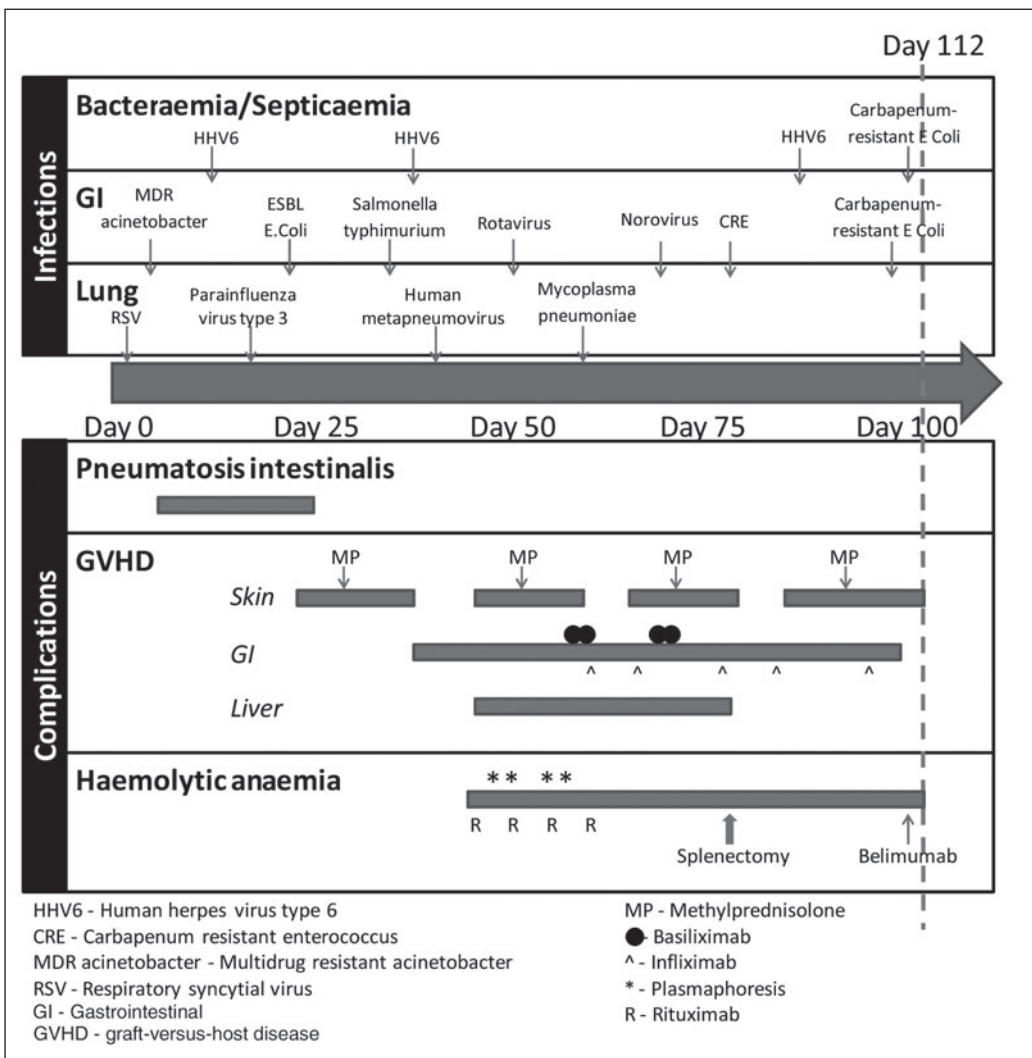


Figure 2 Post-transplant complications of sibling 1.

with fever, abdominal pain, abdominal distension, haematochezia, diarrhoea and bowel obstruction. Corticosteroid treatment is a predisposing factor. Management is conservative with fasting, parenteral nutrition and intravenous antibiotics. Mortality associated with pneumatosis intestinalis in post-transplant SCID patients is 17%.⁹

Autoimmune haemolytic anaemia (AIHA) is more common after haematopoietic stem cell transplantation than solid organ transplantation. Incidence of AIHA in SCID patients who received T-cell depleted haploidentical transplant was quoted to be 9.5-19.5%.¹⁰ The lack of regulatory T cells post-transplant may have accounted for the emergence of unregulated immunoglobulin-producing B cell clones. The delayed T-cell reconstitution enables their persistence. Patients with both warm and cold autoantibodies are rarely seen but they have the most severe clinical course. The main stay of therapy is immunosuppression with corticosteroids. Splenectomy is an effective second line therapy. However, a proportion of patients relapse subsequently.¹¹

In vivo haemagglutination was sibling 1's major problem. The combination of corticosteroids and immunosuppressants (CycA and MMF) was ineffective. Therapy was targeted at removal of autoantibody and reduction of autoantibody production. Plasmapheresis and splenectomy were targeted at the former while Rituximab and Belimumab were targeted at the latter. We attempted to cease the production of autoantibodies by targeting the B-cell production lineage at different levels. Rituximab and Belimumab were used to bind mature B cell and inhibit plasma cell respectively. Only 1 dose of Belimumab was given as the child later developed flare of skin GVHD and reactivation of infections. As complement activation played a critical role in the manifestation of cold haemolytic anaemia, we considered the use of eculizumab, which is a C5 inhibitor. Nonetheless, the drug was not available in Hong Kong at the time of his transplant.

Early transplant for patients with SCID provides excellent chance of cure. Awareness of lymphocyte count of less than $2.5 \times 10^9/L$ in an at-risk infant may lead to early diagnosis of SCID. Newborn screening¹² is an effective means for early diagnosis and effective management.

Acknowledgements

The authors would like to express their sincere gratitude to the following people who helped the boys sail through their journey before, during and after the transplants:

nursing colleagues and doctors in K7, K8 and K10; Professor GCF Chan, Dr. Nai-Shun Tsoi, Dr. Yiu-Ki Ng, Dr. Alan Chiang, Dr. Chun-Yin Chong, Dr. Pamela Lee, Dr. Janette Kwok, Dr. Eric Chan, Dr. Rock Leung, Dr. Jason So and Mr. Koon-Wing Chan. They would also like to thank the Hong Kong Society for the Relief of Disabled Children for funding the molecular testing of primary immunodeficiency disorders for their patients.

Declaration of Interest

We declare that we have no conflict of interests.

References

- Chien YH, Chiang SC, Chang KL, et al. Incidence of severe combined immunodeficiency through newborn screening in a Chinese population. *J Formos Med Assoc* 2012 (in press).
- Gennery AR, Slatter MA, Grandin L, et al. Transplantation of hematopoietic stem cells and long-term survival for primary immunodeficiencies in Europe: entering a new century, do we do better? *J Allergy Clin Immunol* 2010;126:602-10.e1-11.
- Buckley RH. Transplantation of hematopoietic stem cells in human severe combined immunodeficiency: longterm outcomes. *Immunologic research. Immunol Res* 2011;49:25-43.
- Railey MD, Lokhnygina Y, Buckley RH. Long-term clinical outcome of patients with severe combined immunodeficiency who received related donor bone marrow transplants without pretransplant chemotherapy or post-transplant GVHD prophylaxis. *J Pediatr* 2009;155:834-40 e1.
- Myers LA, Patel DD, Puck JM, Buckley RH. Hematopoietic stem cell transplantation for severe combined immunodeficiency in the neonatal period leads to superior thymic output and improved survival. *Blood* 2002;99:872-8.
- Grunebaum E, Mazzolari E, Porta F, et al. Bone marrow transplantation for severe combined immune deficiency. *JAMA* 2006;295:508-18.
- Fernandes JF, Rocha V, Labopin M, et al. Transplantation in patients with SCID: mismatched related stem cells or unrelated cord blood? *Blood* 2012;119:2949-55.
- Haddad E, Leroy S, Buckley RH. B-cell reconstitution for SCID: Should a conditioning regimen be used in SCID treatment? *J Allergy Clin Immunol* 2013;131:994-1000.
- Tang ML, Williams LW. Pneumatosis intestinale in children with primary combined immunodeficiency. *J Pediatr* 1998;132(3 Pt 1):546-9.
- Horn B, Viele M, Mentzer W, Mogck N, DeSantes K, Cowan M. Autoimmune hemolytic anemia in patients with SCID after T cell-depleted BM and PBSC transplantation. *Bone marrow transplantation* 1999;24:1009-13.
- Petz LD. Treatment of autoimmune hemolytic anemias. *Curr Opin Hematol* 2001;8:411-6.
- Verbsky JW, Baker MW, Grossman WJ, et al. Newborn screening for severe combined immunodeficiency; the Wisconsin experience (2008-2011). *J Clin Immunol* 2012;32:82-8.