

The Nystagmus Blockage Syndrome

Congenital Nystagmus, Manifest Latent Nystagmus, or Both?

L. F. Dell'Osso,* C. Ellenberger, Jr.,* L. A. Abel,* and J. T. Flynn†

We have carefully studied, by quantitative oculography, a patient with the nystagmus blockage syndrome (NBS), and two patients with a similar disorder of eye movements that might be mistaken clinically for NBS. Our recordings revealed two distinctly different abnormalities present in a single patient with NBS. Our NBS patient exhibited congenital nystagmus (CN) waveforms when viewing at distance; the CN did not damp with convergence on a near target. When the patient allowed one eye to become esotropic, however, the nystagmus damped considerably and abruptly changed from CN to manifest latent nystagmus (MLN). This peculiar transition from CN to MLN has not been described previously. The appearance of MLN in a case with ongoing CN suggests that two different mechanisms may underlie NBS, since the only other case documented with eye movement recordings showed no transition to MLN. Because the diagnosis of NBS usually is made on evidence of clinical signs alone, it is probable that these two types have been combined indiscriminately and presented as one syndrome. In addition, our discovery of two mechanisms discernable only by quantitative recording suggests that NBS has been diagnosed inappropriately in patients with clinically similar but oculographically different eye signs. Further quantitative studies are required to fully define NBS and to determine if these are the only two mechanisms found in this syndrome. *Invest Ophthalmol Vis Sci* 24:1580-1587, 1983

The nystagmus blockage (blockierungs, compensation) syndrome (NBS) denotes a particular type of nystagmus that begins in early infancy (ie, congenital nystagmus—CN) and is accompanied by esotropia. NBS is characterized by a reduction of the nystagmus when esotropia increases. As the viewing eye follows a target moving laterally towards the primary position and then into abduction, the nystagmus increases and the esotropia decreases. The name “nystagmus blockage syndrome” reflects the prevalent assumption that patients block their nystagmus by adducting one eye. The adducted eye may be the fixing eye (ie, accompanied by a head turn) or it may be the non-fixing eye (ie, when a patient views an object in primary position with his head straight). In both cases, the nystagmus is reduced when the esotropia occurs.

The diagnosis of NBS is difficult to make because (1) precise and uniform diagnostic criteria are lacking; (2) similar, more common disorders, such as esotropia

associated with manifest latent nystagmus (MLN), are mistaken for NBS; and (3) the diagnosis usually is made by clinical observation rather than by accurate oculography. The patients most commonly misdiagnosed as having NBS are those with MLN, esotropia, and Alexander's Law variation; they have been well-described and their ocular movements recorded.¹ Alexander's Law variation is the nystagmus amplitude increase as the eyes are directed towards the fast phases of the nystagmus.

We describe the clinical and oculographic findings of three patients. One patient had NBS, and two had a combination of esotropia and nystagmus that clinically resembled NBS, but, by both careful clinical and oculographic measurements, was not. Using quantitative oculography with special attention to the relative positions of each eye and the target, we can elucidate at least two different mechanisms underlying NBS and begin to define accurate criteria for its diagnosis.

Case Reports

Case 1

A six-year-old girl had nystagmus that was first noticed at the age of three months. Her mother also had noticed at an early age that she had a tendency to turn her head to either side. Esotropia was suspected early but never treated. Birth had been normal, but early development was delayed slightly. Because of this delay, mild spasticity in the legs, and nystagmus, she under-

From the Ocular Motor Neurophysiology Laboratory, Cleveland Veterans Administration Medical Center, the Department of Neurology, Case Western Reserve University School of Medicine,* and the Department of Ophthalmology, University of Miami School of Medicine.†

Supported, in part, by the Veterans Administration.

Submitted for publication: March 7, 1983.

Reprint requests: L. F. Dell'Osso, PhD, Ocular Motor Neurophysiology Lab (127A), Veterans Administration Medical Center, Cleveland, OH 44106.

went neurologic evaluation at age six months: ventriculogram, EEG, cerebrospinal fluid, and amino acid screen were normal. Later, at three years of age, a CT scan was also normal. The child was given spectacles to correct mild myopic astigmatism. Our examination at the Division of Neuro-Ophthalmology, University Hospitals of Cleveland, revealed a preference to turn her head to either side. With the head in either of these positions and the fixing eye adducted, visual acuity was 20/40 in both eyes. When her head was held straight in relation to the eye chart, nystagmus worsened and vision became 20/60 bilaterally. Pupils were equal and equally reactive to light. Because of the nystagmus and dark irises, we were unable to determine whether pupillary constriction accompanied adduction of either eye. Nystagmus, its fast phase beating in the direction of the fixing eye, increased as that eye abducted and the esotropia lessened and decreased when the fixing eye adducted to a maximum esotropia of 36 prism diopters. She was diagnosed clinically as having NBS.

Case 2

A 14-year-old girl was seen at the Bascom Palmer Eye Institute. She was myopic and had a history of variable esotropia since at least one year of age which had not been treated. On examination, the visual acuity with correction was 20/30— in both eyes. Cycloplegic retinoscopy was: right eye, +5.50 +1.00 × 40; left eye, +6.50 +1.00 × 135. She read the visual acuity chart with her face turned in the direction of the fixating eye; when reading the chart with her right eye, which she preferred, she fixated with the right eye in adduction and her face turned to the right shoulder. By prism cover measurements with correction, fixating on an accommodative target, she had an esotropia of 8–10 prism diopters with 3–4 of left hypertropia in the primary position; she had 10 prism diopters of esotropia with 6 of left hypertropia at distance. Without correction, she had a variable 20–40 prism diopters of left esotropia. On clinical examination, she appeared to have latent nystagmus, the nystagmus being right-beating when the right eye fixed and left-beating when the left eye fixed. On sensory testing, she had Worth 4 dot fusion up to 4 feet; beyond that, she suppressed her left eye. Stereopsis was absent. NBS was not diagnosed.

Case 3

A 10-year-old girl was seen at the Bascom Palmer Eye Institute. Right esotropia had been noted at 2½ months of age but not treated. Later, eyeglasses were prescribed. Her parents had noted nystagmus in addition to her esotropia at a very early age. The family history included both consanguinity and nystagmus

(her grandparents were first cousins and both the maternal grandmother and mother had nystagmus). Binocular visual acuity was 20/40; the visual acuity of the right eye was 20/50, and 20/40 for the left eye. She turned her head to the right when reading with the right eye and vice versa. A fine, pendular or left-beating jerk type of nystagmus was seen when the eyes were in the primary position. It diminished on lateral gaze more to the left than to the right and ceased when she converged. Her nystagmus became right-beating in right gaze and left-beating in left gaze. No strabismus was noted on cover test during this examination despite previous observations of esotropia and its subsequent documentation by recording. Her discs and maculas appeared normal and retinoscopy values were +0.50 sphere O.U. No specific treatment was advised. NBS was not diagnosed.

Materials and Methods

Horizontal eye movement recordings were made using infrared oculography, with a full-system bandwidth (position and velocity) of DC to 100 Hz (Biometric Model-200 and rectilinear Beckman Type-R Dynograph; both modified to achieve the above bandwidths). Simultaneous position and velocity recordings were made for each eye. The patients were seated in a chair with a head brace and chin rest at the center of a five-foot arc containing red light-emitting diodes. Recordings were carried out in subdued light and each eye was calibrated individually while the other eye was occluded. In this way we could align exactly the tracings for each eye on the target and then, when the cover was removed, detect even the smallest tropias during binocular viewing. The term "binocular viewing" is used in this paper to describe the condition where both eyes were open with neither occluded, and it does not imply "binocular fixation," a term that we use to designate fixation of the target by both eyes. After calibration, the patients were asked to view each light-emitting diode as it came on and the ongoing nystagmus at all gaze angles of interest was recorded. Then, a near target-induced convergence and the eye movements were recorded both during the act of convergence and the return to distance viewing. In addition to the study of MLN,¹ we have used similar methodology to study hereditary CN,² CN waveforms,³ and the effects of CN surgery.⁴

Results

Case 1

Waveforms recorded during binocular viewing of a distant target were those of CN. The waveforms shown in Figure 1 were predominantly jerk and jerk with extended foveation. Most beats were jerk right; a few were jerk left. Note that both eyes were fixating the target which was in primary position (ie, there was no

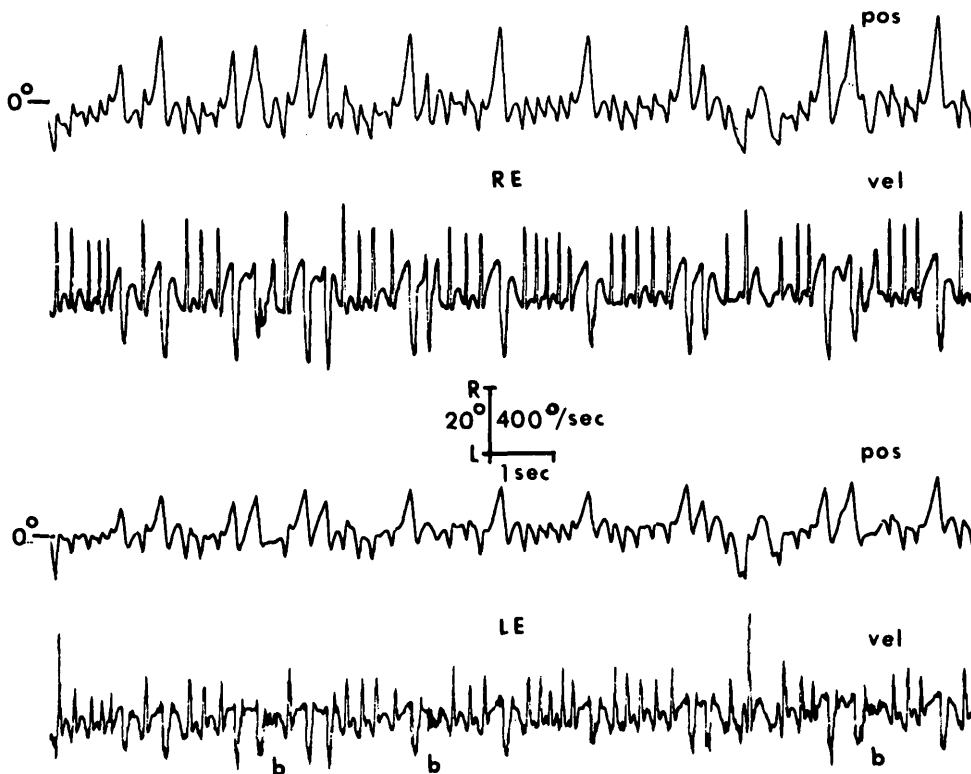


Fig. 1. Position (pos) and velocity (vel) recordings of the eye movements of patient 1 during binocular viewing of a distant target. The waveforms are CN and are mainly jerk-right with extended foveation. Occasional exponentially increasing runaways to the right gave rise to large jerk-left beats. In this and all other figures, R = right; L = Left; RE = right eye; LE = left eye; and b = blink.

esotropia). The eyes were on target just after completion of the fast phase (after the dynamic overshoot if one existed). For some cycles, a flattened portion (the period of extended foveation) existed when the eye remained motionless on the target. In this example, target foveation usually was followed by an exponentially increasing runaway to the left (ie, the eyes moved with increasing velocity away from the target). There were also occasional runaways to the right, much larger in amplitude (10–12°).

Figure 2 illustrates a truly remarkable finding in this case. Initially, the target at 15° to the right was being fixated binocularly (without esotropia) and the patient had CN as shown in Figure 1. Then, as the right eye became esotropic the nystagmus abruptly shifted to jerk left MLN (reflecting fixation by the left eye alone). This persisted during the time the right eye was esotropic and immediately converted back to CN when the right eye again achieved target foveation.

Figure 3 illustrates the use of the adducting eye to pursue a moving target. As the target moved across the midline to the left, the tracking was done with the right eye, and as the target came back towards midline, the left eye picked it up and tracked it throughout right gaze. In this way the nystagmus was minimized since the fixating eye was always the adducting eye.

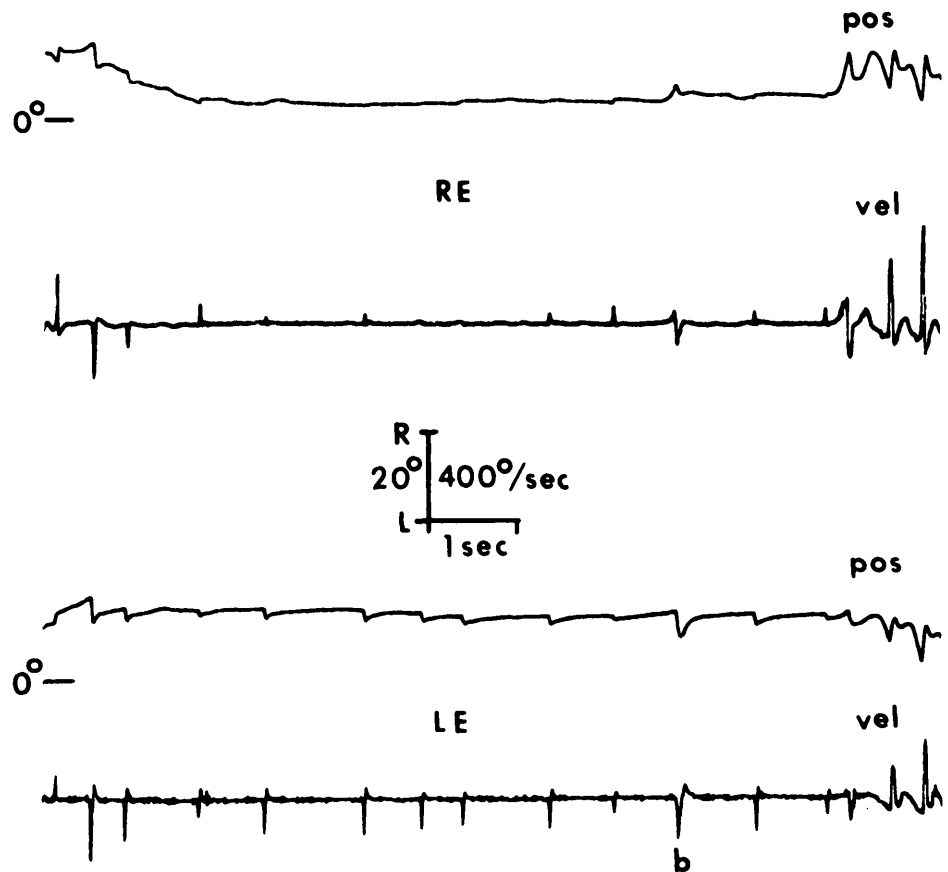
Case 2

This patient had a combination of CN, esotropia, and a strong superimposed latent component to the

CN. Recording showed all waveforms to be CN, with no MLN, and that her nystagmus damped significantly with convergence. Figure 4 shows the sequence of events that transpired as the patient viewed a target that was moved from distance to near and back. She initially fixated with the left eye (the right eye was esotropic) and had a jerk left with extended foveation CN waveform. As the target came closer, the left eye converged and the right eye became less esotropic until at near she had very little nystagmus and was fixating binocularly. As the target moved back to the distant position, she followed it with her right eye while the left eye remained esotropic and had a jerk right with extended foveation CN waveform. Thus, there was no conversion to MLN and the change with convergence was a typical example of convergence-induced damping of CN, despite the accompanying esotropia. Although this patient had a null at 20° right gaze in dim light, she chose to change fixation from left eye to her right eye when in bright light. Therefore, she did not have a consistent null that could be exploited therapeutically.

Figure 5 documents the retention of CN waveforms of patient 2 as she viewed a target in primary position and alternately shifted between right and left esotropia. Initially she was fixating with the left eye and had jerk left with extended foveation waveforms (the right eye was esotropic). As the right eye drifted toward the primary position, she assumed fixation with the right eye (at the first arrow) and the left eye became esotropic. During this right eye fixation the nystagmus waveform

Fig. 2. Position (pos) and velocity (vel) recordings of both eyes (patient 1) during binocular viewing of a target 15° to the right. The waveforms are CN at the beginning and end of this illustration when both eyes were simultaneously on target (ie, no esotropia). As the right eye became esotropic, the CN abruptly changed to left-beating MLN which persisted until the esotropia disappeared.



was jerk right with extended foveation. At the second arrow she abruptly switched to left eye fixation with the right eye esotropic and exhibited left pseudo-cycloid waveforms. At the third arrow she switched back to right eye fixation with the left eye esotropic and her waveforms were both jerk right and jerk left with extended foveation. Although she was an alternate fixer, her waveforms were always CN and not MLN.

Figure 6 illustrates the fact that this patient could be perfectly binocular in her fixation. She initially viewed a target in primary position with a jerk right with extended foveation waveform. Then, both eyes began a period of wandering during which time they remained conjugate. After four seconds of this wandering she was instructed to view a target at 15° to the right which she did immediately using a 20° saccade followed by a 10° slow phase movement to foveate the new target. While viewing the target, her CN waveform was left pseudo-cycloid.³ The slight distortion seen at the extreme right-most portions of the right eye tracing were caused by the infrared system being driven out of its linear range (beyond 25°).

Case 3

This patient also had only CN waveforms with no MLN. She had an alternating esotropia and fixated

with her adducted eye in both left and right gaze. She had a nystagmus null between 0–5° left gaze. Figure 7 shows the complete nulling of this patient's nystagmus with convergence. When viewing a target at distance, the left eye was esotropic and the waveform was jerk right with extended foveation; some of the fast phases had dynamic overshoots. When the target was brought near, the left eye position remained relatively constant and the right eye converged to the target eliminating the esotropia. As the eye converged the nystagmus stopped completely and remained suppressed while the target was near. The significant findings for this patient also are listed in Table 1.

Discussion

We have used quantitative oculography to study a patient with the nystagmus blockage syndrome (NBS) in an effort to better define this condition and uncover its underlying ocular motor mechanism. In addition, we also have applied these same oculographic techniques to the study of two patients whose clinical symptoms are similar to NBS and who represent the types of CN patient that we feel could easily have been suspected clinically to have NBS.

It is *extremely* important in the study of congenital nystagmus (CN), latent and manifest latent nystagmus

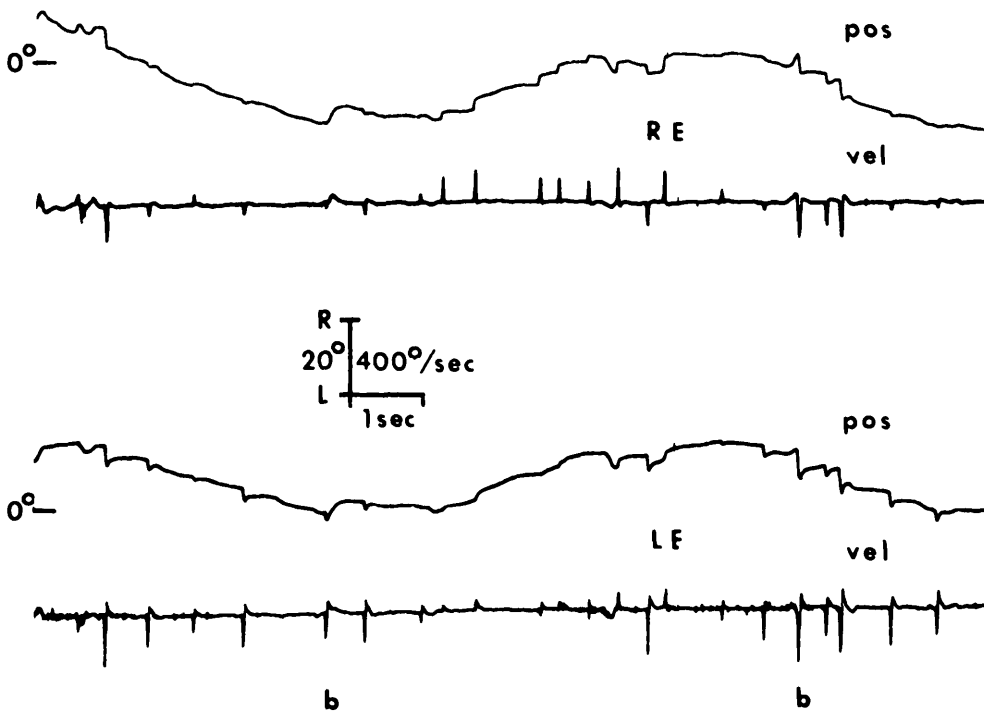


Fig. 3. Position (pos) and velocity (vel) recordings of both eyes (patient 1) during horizontal tracking of a slowly moving target. As the target moved across the midline in each direction, the adducting eye assumed fixation and tracked it.

(LN/MLN), and strabismus, to accurately calibrate each eye individually (ie, when viewing monocularly while the other is behind cover). In this way both the nystagmus waveform and the actual position of each eye relative to the target may be determined so that any small tropia (variable or fixed) can be identified.¹ This has never been done for NBS and, unfortunately, is still not done routinely by many who study nystagmus. As a result, neither the readers nor the authors of such studies can be sure, when viewing the eye movement data, exactly where each eye is, where the target is, or which eye actually is fixating the target.

Speculations arising from such data are suspect and difficult to support. We have found that many nystagmus patients have small variable tropias that are missed on clinical examination.

Because most of the literature on the subject lacks accurate ocular motility recordings and is based solely on clinical observation, it has been difficult to properly characterize the ingredients that make up NBS. The syndrome first was identified in 1966 by Adelstein and Cüppers.⁵ Since that time, several other reports have appeared in the literature.⁶⁻¹³ In attempt to clarify further exactly what constitutes NBS, we extracted the

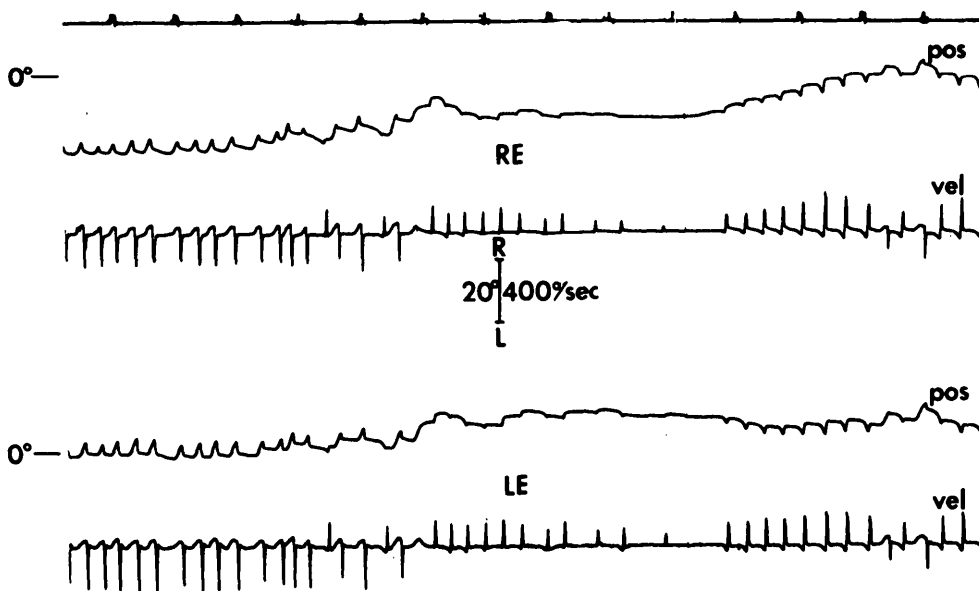


Fig. 4. Position (pos) and velocity (vel) recordings of both eyes (patient 2) during binocular viewing of a target which was moved from distance to near and back to distance. Initially, the right eye was esotropic and the nystagmus was CN with a jerk-left with extended foveation waveform. As the target moved in to a near position, the nystagmus became CN with a jerk-right with extended foveation waveform. As the target was moved back to the distance position, the left eye remained esotropic as the right eye tracked, and the nystagmus continued to be CN with a jerk-right with extended foveation waveform.

following signs that were cited in the majority of these reports: esotropia; nystagmus (type unspecified); a head turn; and an increase in the magnitude of the (jerk) nystagmus with abduction of the viewing eye.

The reported incidence of NBS in esotropic patients is quite variable and seems to reflect a geographical bias (10.2% in Europe and 4-5% in America) as well as over-diagnosing in conjunction with a lack of quantitative data. Only the work of Kommerell⁸ contains an accurate NBS eye movement recording, but even this paper does not have the type of simultaneous binocular recordings of the one NBS patient presented that would allow us to determine the exact position of each eye relative to the target. Although Metz and Smith¹³ do discuss NBS, the recordings clearly show that their patient had manifest latent nystagmus (MLN)¹ and that the MLN amplitude varied in accordance with Alexander's Law. Hoyt,¹⁴ in a paper that contained no eye movement recordings, claimed that eight of 32 patients with congenital esotropia had NBS. Without recordings CN cannot be differentiated from MLN, and the diagnosis of NBS cannot be verified. Indeed, our patient 2 was diagnosed clinically as having LN when, in fact, recordings revealed that she had CN. Based on our experience in recording over 300 CN and MLN patients, we suspect that Hoyt's patients all had MLN, which varied in accordance

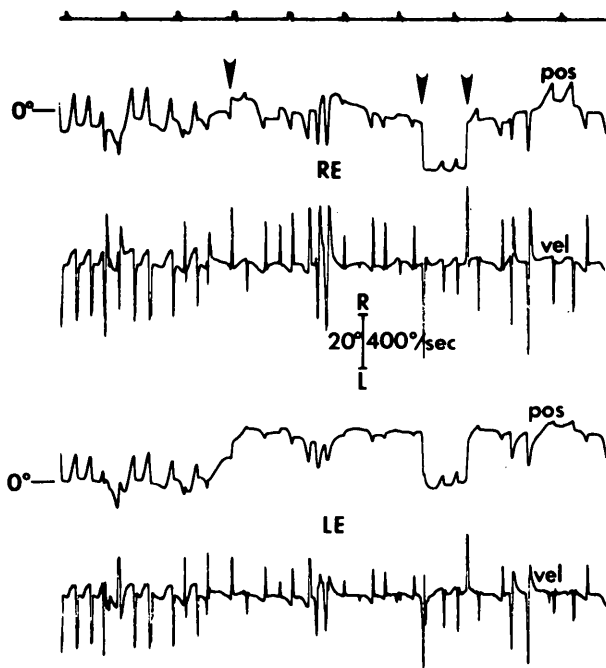


Fig. 5. Position (pos) and velocity (vel) recordings of the CN waveforms of patient 2 during binocular viewing of a target in primary position. Initially, the right eye was esotropic. At the first arrow the left eye became esotropic, at the second arrow the right eye, and at the third arrow the left eye became esotropic again. CN waveforms persisted throughout.

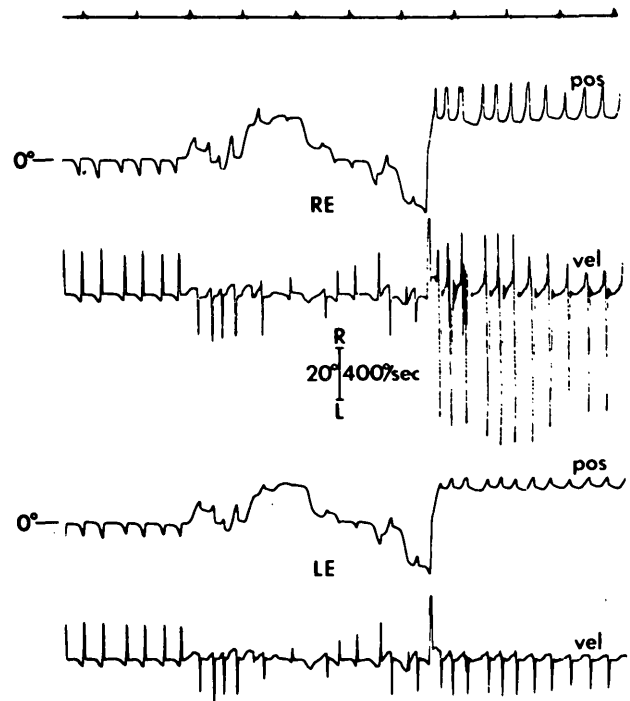


Fig. 6. Position (pos) and velocity (vel) recordings of both eyes of patient 3. Initially, the patient was binocularly fixating a target in primary position and had CN with jerk-right with extended foveation waveforms. In the middle of the tracing, both eyes began a conjugate wandering until the point at which the patient was instructed to view a target 15° to the right and made a saccade to that target. Binocular fixation and the CN waveform, jerk-left with extended foveation, resulted. At no time during these fixations or during the wandering did the patient's esotropia become manifest.

with Alexander's Law, and did not have NBS in agreement with Kommerell⁸ who cautions that NBS should not be confused with infantile esotropia accompanied by MLN. Hoyt's patients certainly did not have "abduction nystagmus," a term commonly used to describe the dissociated nystagmus of internuclear ophthalmoplegia.

Authors who have written about NBS seem to be divided into two camps; some have claimed that NBS is the result of an induced convergence (or esotropia) whose sole purpose is to reduce an ongoing nystagmus ("nystagmus blockage syndrome") and others have held that an underlying esotropia is responsible for the syndrome. Without accurate ocular motility recordings of the various patients discussed by these authors, it is impossible to know if they were talking about the same entity. Therefore, we can only add the patient presented by Kommerell⁸ to our discussion of the patients that we have recorded and presented in this paper.

Our recordings have documented the existence of two distinctly different abnormalities involved in NBS. In Case 1 we saw a conversion from CN, when both eyes were parallel, to MLN, when one eye became

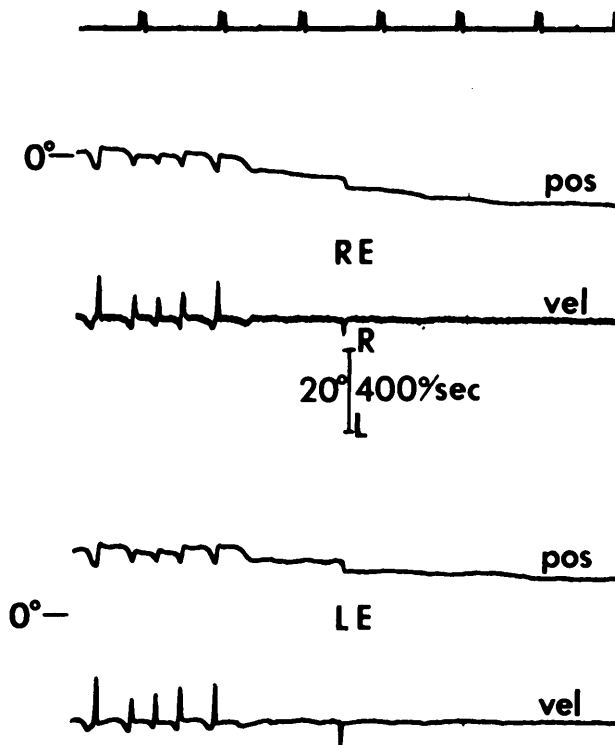


Fig. 7. Position (pos) and velocity (vel) recordings of both eyes of patient 3 during the process of convergence. When viewing the target at distance, the left was esotropic and the nystagmus was CN with a jerk-right with extended foveation waveform. As the patient converged on the target that was moving to a near position along the midline, the CN nulled completely.

esotropic. In contrast to our patient, Kommerell's⁸ NBS patient constantly had CN waveforms whether the eyes were parallel or one was esotropic. This latter NBS patient differs from most with CN by the ability to increase an esotropia at distance and reduce the nystagmus without diplopia. In Kommerell's figure, the waveforms are CN with no MLN during the esotropia. Likewise, our NBS patient became esotropic but showed no true convergence. In contrast, the two non-NBS patients we have presented, who had signs similar to NBS, were able to converge binocularly and exhibited only CN waveforms. Their esotropia did not

substantially reduce the nystagmus amplitude. The combination of CN, esotropia, and a strong superimposed latent component (patient 2) makes diagnosis difficult, and at one point, it was thought that she might have NBS. The strong superimposed latent component could have easily been misdiagnosed as latent nystagmus.

While it is not rare to find patients who have both CN and MLN,¹ it is rare to find a patient who has better acuity during the MLN waveforms than during the CN waveforms. The utilization of a very low amplitude MLN to enhance visual acuity has not been described previously. Most CN waveforms have increasing-velocity slow phases and much longer periods of foveation time (>100 mseconds) per cycle than MLN, which has decreasing-velocity slow phases and minimal foveation time. This patient's visual acuity is better with MLN only because her MLN is of much lower amplitude than her CN.

We propose, on the basis of our and Kommerell's⁸ findings, that the diagnosis of nystagmus blockage syndrome be made *only* when the ongoing waveform is of CN (with both eyes parallel) and when the nystagmus markedly diminishes with esotropia. Therefore, true NBS is indeed a "blockage" of an ongoing nystagmus (ie, CN) present with both eyes parallel, produced by an added esotropia. The esotropia may reduce the nystagmus by one of two mechanisms: it may convert the nystagmus to a very low amplitude MLN (Case 1); or it may reduce an ongoing CN much in the same manner as true binocular convergence reduces the amplitude of CN in many patients (Kommerell's case and another which we have recorded). Until more patients with NBS are studied with quantitative, binocular oculography, we cannot say with certainty that we have fully described this syndrome; we *have* accurately described two variations of it.

In addition, quantitative eye movement recordings have measured the variable angle of esotropia and illustrated its time course, disclosed the MLN (when fixing eye appeared motionless to clinical observation), demonstrated the crossed fixation pattern, and doc-

Table 1. Patient data

Patient	Age (yr) and sex	Clinical diagnosis	CN/Waveforms	MLN	N ↓ with convergence		1° Tropia	Visual suppression
					TRUE/ET	Null Angle		
1	6, F	NBS	YES (P, J, J _{EF} , PC, T)	YES	NA/YES*	NONE	ΔET(ALT)†	YES
2	14, F	CN	YES (J, J _{EF} , PC)	NO‡	YES/NO	20°R§	ΔET, HT (OS)§	YES
3	10, F	CN	YES (J, J _{EF})	NO	YES/NO	0-5°L	ET (OD)†	YES

Δ = variable; L = left; R = right; P = pendular; J = jerk; EF = extended foveation; PC = pseudo-cycloid; T = triangular; and DJ = dual jerk.

* Nystagmus changed from CN to low amplitude MLN.

† Fixation was with adducted eye in left and right gaze.

‡ Had superimposed latent effect on her CN but *no* MLN.

§ Fixated with OD in bright light and OS in dim light (our lab) so that her null was not consistent.

umented the MLN reduction with adduction. The value of eye movement records for characterization, measurement, and understanding the mechanism of NBS is complemented by its critical use in diagnosing this complex syndrome. The large discrepancies in reported incidences (10% in Europe and 4–5% in America) suggest the absence of uniform criteria. It is probable that over-diagnosis is caused by the absence of quantitative eye movement data and the inclusion of many patients with MLN (manifest because of amblyopia or suppression in one eye). In accordance with Alexander's Law, the MLN (whose fast phases are towards the fixing eye) would increase with abduction and decrease with adduction. Also, the decreasing-velocity slow phases of MLN cannot be distinguished from the increasing-velocity slow phases of CN by visual inspection of the patient; eye movement recording is necessary.

The well-known hallmarks of NBS are: a variable angle of esotropia; damping of the nystagmus when one or the other eye is adducted; worsening of the nystagmus when the fixating eye is abducted by disappearance of the angle of squint; and augmentation of the angle of convergent squint when a base-out prism is placed before the fixating eye. In addition, another useful clinical sign in differentiating NBS from other forms of convergence excess is the size of the pupils (and presumably the accommodative state of the eye) when the eye assumes its adducted position to block the nystagmus. There should be no evidence of pupillary constriction.⁵ The accommodative state of the fixating eye remains exactly the same under these circumstances, indicating that no accommodative mechanisms are in play. These patients are not using their accommodative vergence mechanism to block the nystagmus but instead, are depending upon some other mechanism to bring about damping of the nystagmus. This is little emphasized in the literature but is an important, albeit disputed,⁹ clinical diagnostic point.

In summary, we agree with Kommerell⁸ who indicated that his NBS patient was "rare" (we have seen

only two cases in over three hundred recorded with CN and/or MLN) and with von Noorden who stated, "we need more electronystagmographic tracings to learn more about the mechanics of this syndrome".¹¹ We also share their opinions that NBS is over-diagnosed and often confused with the common combination of esotropia and MLN.

Key words: nystagmus blockage syndrome, congenital nystagmus, latent nystagmus, esotropia

References

1. Dell'Osso LF, Schmidt D, and Daroff RB: Latent, manifest latent, and congenital nystagmus. *Arch Ophthalmol* 97:1877, 1979.
2. Dell'Osso LF, Flynn JT, and Daroff RB: Hereditary congenital nystagmus: an intrafamilial study. *Arch Ophthalmol* 92:366, 1974.
3. Dell'Osso LF and Daroff RB: Congenital nystagmus waveforms and foveation strategy. *Doc Ophthalmol* 39:155, 1975.
4. Dell'Osso LF and Flynn JT: Congenital nystagmus surgery: a quantitative evaluation of the effects. *Arch Ophthalmol* 97:462, 1979.
5. Adelstein F and Cüppers C: Zum Problem der echten und scheinbaren Abducenslähmung (das sogenannte "Blockierungssyndrom"), *In Augenmuskellähmungen*, Buch d Augenarzt Heft 46, Stuttgart, Enke F, editor. 1966, pp. 271–278.
6. Haase W: Zur Diagnose und Therrapie des Nystagmusblockierungssyndroms (elektromyographische Untersuchungen). *Klin Monatsbl Augenheilkd* 157:500, 1970.
7. Cüppers C: Probleme der operativen Therapie des okulären Nystagmus. *Klin Monatsbl Augenheilkd* 159:145, 1971.
8. Kommerell G: Nystagmusoperationen zur Korrektur verschiedener Kopfwangshaltungen. *Klin Monatsbl Augenheilkd*, 164:172, 1974.
9. von Noorden GK: The nystagmus compensation (blockage) syndrome. *Am J Ophthalmol* 82:283, 1976.
10. Kommerell G: Relations between strabismus and nystagmus, *In Disorders of Ocular Motility*, Kommerell G, editor. J. F. Bergmann, München, Verlag, 1978, pp. 367–372.
11. von Noorden GK: The nystagmus blockage syndrome. *Austral J Ophthalmol* 7:31, 1979.
12. Frank JW: Diagnostic signs in the nystagmus compensation syndrome. *J Pediatr Ophthalmol Strabismus* 16:317, 1979.
13. Metz HS and Smith G: Abduction nystagmus. *J Pediatr Ophthalmol Strabismus* 15:312, 1978.
14. Hoyt CS: Abnormalities of the vestibulo-ocular response in congenital esotropia. *Am J Ophthalmol* 93:704, 1982.