

Auricular Graft vs. Chemoterapy in the Managment of Craniomandibular Joint Ankylosis

¹Mohamed Baha'a Khidr, ²Fatma Zaiton, ³Hazim Tantawy, ⁴Mohamed A. Foda and ⁵Mostafa Abu Ghala

¹Oral and Maxillofacial Surgery, Al-Minia University, Egypt

^{2,3}Radiology, Zagazig University, Egypt

⁴Oral and Maxillofacial Surgery, Al-Azhar University, Assiut Branch, Egypt.

⁵Anaesthesia, Zagazig University, Egypt.

Received: 12 November 2013; Revised: 14 December, 2013; Accepted: 20 December 2013.

© 2013 AENSI PUBLISHER All rights reserved

ABSTRACT

A variety of techniques for the management of craniomandibular ankylosis have been described. However, no single technique has proved entirely satisfactory. These techniques pose a significant challenge due to a high incidence of recurrence. Aim: The aim of this study was to evaluate and compare between the interpositional auricular graft and local application of chemotherapy procedures. Patients/methods : The study has been used on 31 patients with true TMJ ankylosis (18 had unilateral and 13 had bilateral ankylosis with average age ranged between 12 and 41). Two procedures for the management of TMJ ankylosis were done. Group (I) included 16 patients were subjected to small gap arthroplasty and topical application chemotherapeutic agent having antiproliferative property to suppress fibrous proliferation and vascular ingrowth between the osteotomy sites. Group (II) included 15 patients were subjected to interpositional arthroplasty using auricular graft of the ipsilateral side. All patients were examined and followed clinically and radiologically using panoramic view, CT and MRI, after the operation for a period extended to 4 years to confirm absence of recurrence. All patients had no recurrence after surgery. Results : Considerable improvement in maximal incisal opening (33 mm) was noted in all patients during the follow up period. Conclusion : The study concluded that both techniques provided satisfactory results. However, chemical application of chemotherapeutic agent was found to be superior in some aspects; no mandibular shifting during the movement, elimination of grafting problems and saving surgical time.

Key words: Craniomandibular ankylosis, interpositional auricular graft, chemotherapy procedures

Introduction and Review of literatures:

An elegant principle in the practice of maxillofacial surgery is to keep the reconstruction as simple as possible, consistent with the overall goal. Also, the reconstructive technique must not overshadow the defect to be repaired. Ankylosis of temporomandibular joint (TMJ) is an extremely disabling affliction that causes problems in mastication, digestion, speech, appearance, and hygiene. It also has an impact on the psychologic development of the patient and can place his or her life in jeopardy at any time because of the inability to open the mouth [22].

TMJ ankylosis is common and occurs primarily in the first decade of life; the percentage of onset under 10 years is described as 35% to 92% in all cases [11,1]. It is most commonly associated with trauma (13% to 100% of all cases), local or systemic infection (0% to 53%), or systemic disease, such as ankylosis spondylitis, rheumatoid arthritis, and psoriasis (28%). Ankylosis can also occur after TMJ surgery [10,12].

A variety of techniques for the management of cranio- mandibular ankylosis have been described. However, no single technique has proved entirely satisfactory. The treatment of TMJ ankylosis poses a significant challenge because of technical difficulties and a high incidence of recurrence. It usually requires adequate excision of involved structures, with or without immediate reconstruction by the interposition of autogenous or alloplastic materials [22]. TMJ ankylosis should be treated as soon as the condition is recognized. The main objectives of the treatment have been surgical removal of the ankylosis together with reestablishment of joint function and a harmonious relationship [9,13].

Mitomycin C is an anticancer agent isolated from streptomyces caespitosus, it has antiproliferative property. It has the ability to significantly suppress fibrosis and vascular ingrowth. It has been widely used in pterygium excision and trabeculectomy with favorable results [2,4].

Auricular graft considered one of the important intrpositioning grafts of TMJ. Its cone- shaped is constantly present in mammals and its shape and dimensions characterize the external aspect of the

ear. Several muscles in deferent layers insert on the auricular cartilage and are responsible for the movement of the external ear. These muscles mostly insert on the rostromedial aspect of the base of the cartilage and were preserved when the cartilage graft was harvested.

The condylar and disc positions in TMJ have attracted significant attention in clinical TMD research. Magnetic resonance imaging (MRI) provides noninvasive images of the TMJ disc position and shape [18]. Re-ankylosis is of major concern in all ankylosis treatment. The aim of this study was to Compare Chemical Vs Mechanical Procedure in TMJ Ankylosis Management. The chemical procedure was represented by using mitomycin C as local application in gap arthroplasty surgery. The mechanical procedure was done in the form of auricular graft as interposition arthroplasty of the TMJ.

Computed tomography and magnetic resonance imaging ideally complement each other for the thorough examination of the structures of the TMJ. Radiographically, ankylosis presents features that facilitate the diagnosis on conventional radiographic techniques. However, its visualization is not clear in most of the cases. With the evolution of radiographic techniques, CT became an important examination in the diagnosis of the ankylosis of TMJ [6]. The development of magnetic resonance imaging has greatly aided the diagnosis of TMJ disorders. The ability to noninvasively resolve anatomic detail can be performed easily and quickly using magnetic resonance imaging.. The best imaging modality for assessment of soft-tissue structures of the TMJ is magnetic resonance imaging (MRI), which can detect abnormalities in 80% of patients with TMJ pain and dysfunction.

Patients and Methods:

Thirty one consecutive patients were chosen from those attending the outpatient clinic of maxillofacial department of Zagazig university hospitals. They were complaining of inability to open the mouth, facial asymmetry, psychic depression, and sometimes failure of dental treatment and performing of tonsillectomy. The cases (20 males and 11 females) had age ranged between 18 and 41. All patients have proven to have bony ankylosis of TMJ. Thirteen of them had bilateral ankylosis with birds face appearance (Fig.1). The rest eighteen had unilateral ankylosis. Two procedures for the management of TMJ ankylosis were done. Group (1) included 16 patients were subjected to small gap arthroplasty and topical application chemotherapeutic agent having antiproliferative property to suppress fibrous proliferation and vascular ingrowth between the osteotomy sites. Group (11) included 15 patients were subjected to interpositional arthroplasty using auricular graft of the ipsilateral side.

Preoperative assessment included history, physical examination and, photographs. Conventional X-rays including cephalometry, panorama, and axial and coronal CT scanning were also made (Fig.2&3). Charts were analyzed to determine cause of deformity, presenting signs and symptoms, and length of time from injury to repair. Then the patients were subjected for surgery.

Operations were performed under general anesthesia after awake intubation. The upper airway of sedated patient was topically anesthetized using Marcain 0.5%. Then, the supraglottic pathway (nasal cavity, nasopharynx, and oropharynx) was topically anesthetized by an irrigating system, which is a fenestrated malleable plastic tube surrounded by spongy like tissue that enable the anesthetist to anesthetized the mucosa of supraglottic airway gradually and continuously as patient needed. The glottic and infraglottic (tracheal mucosa) airway were topically anesthetized by the cricothyroid injection of local anesthesia. Prophylactic antibiotic cover was administrated intraoperatively using intravenous 1 g cephalosporin.

Subcutaneous infiltration of 1/100,000 epinephrine in sterile normal saline was used in the preauricular area to define the tissue planes, facilitate the dissection and provide hemostasis. The surgical exposure was made by preauricular incision combined with extended temporal incision in some cases. Sharp and blunt dissections were continued until the ankylotic joint was exposed. Two bony osteotomies with saw or sharp osteotome were made and the resected ankylotic bone was removed creating a gap of at least 0.5 Cm between the roof of the glenoid fossa and the mandible within the ankylotic mass itself (Fig. 4). A passive mandibular movement by mouth opening of at least 35 mm was achieved. A piece of micro sponge saturated with 0.2 mg/ml mitomycin C (Bristol- Myers Squibb Company- New Jersey, USA) was placed over the osteotomy site, and then removed after an application time of 5 minutes(Fig.5).

An auricular graft was harvested from the conchal region. The postauricular incision was designed so that it was started over the postauricular surface of the concha when the pinna was retracted anteriorly (Fig. 6 & 7). The incision is made through the conchal skin approximately 2 cm. The depth of the cut was down to the cartilage through the perichondrium, and a periosteal elevator was used to separate the perichondrium from the cartilage . The dissection is carefully advanced all around the dissected cartilage and a generous portion (usual diameter, 1.5 cm) of conchal cartilage was resected . The majority of grafts required do not exceed the dimension of the concha, which can be easily harvested up to a size of 2.5 _ 4 cm. If a larger graft is required, the dissection continues superiorly into the triangular fossa, with the upper incision placed for cosmesis.

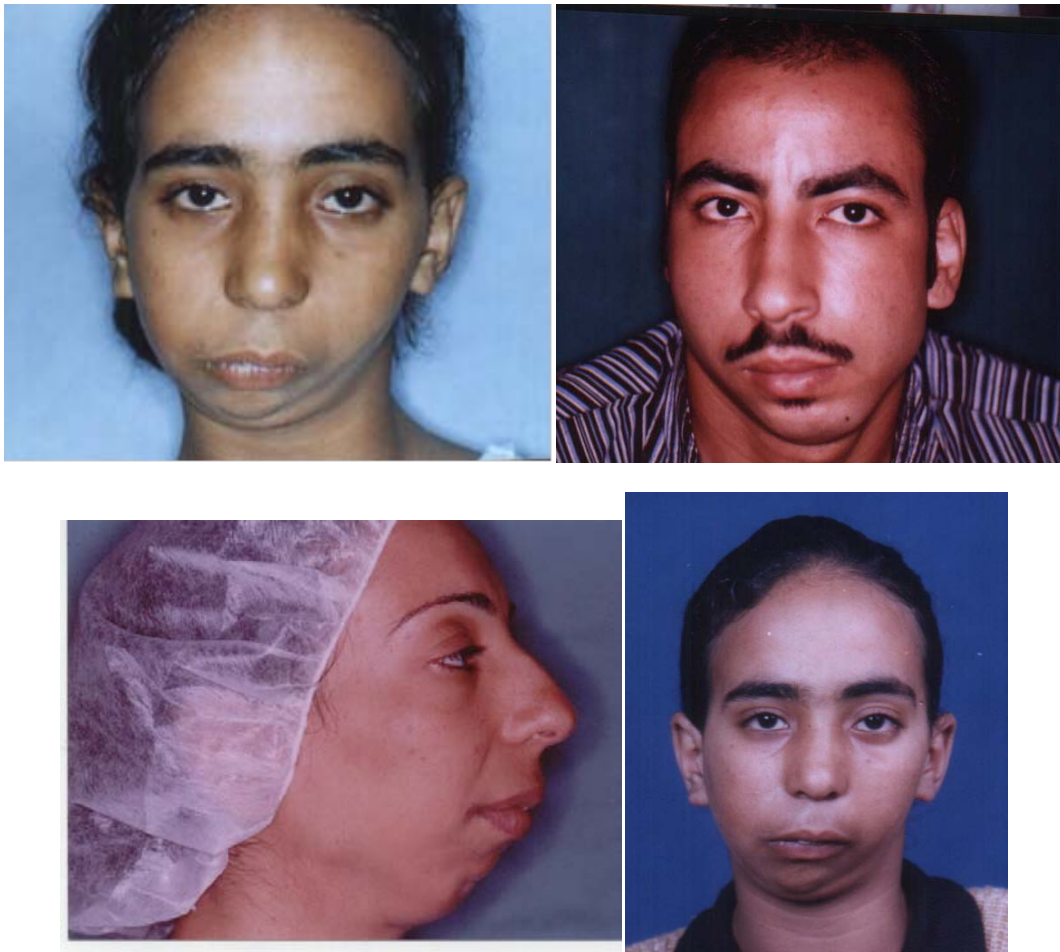

Fig. 1: Photographs for four patients showing bilateral and unilateral ankylosis.

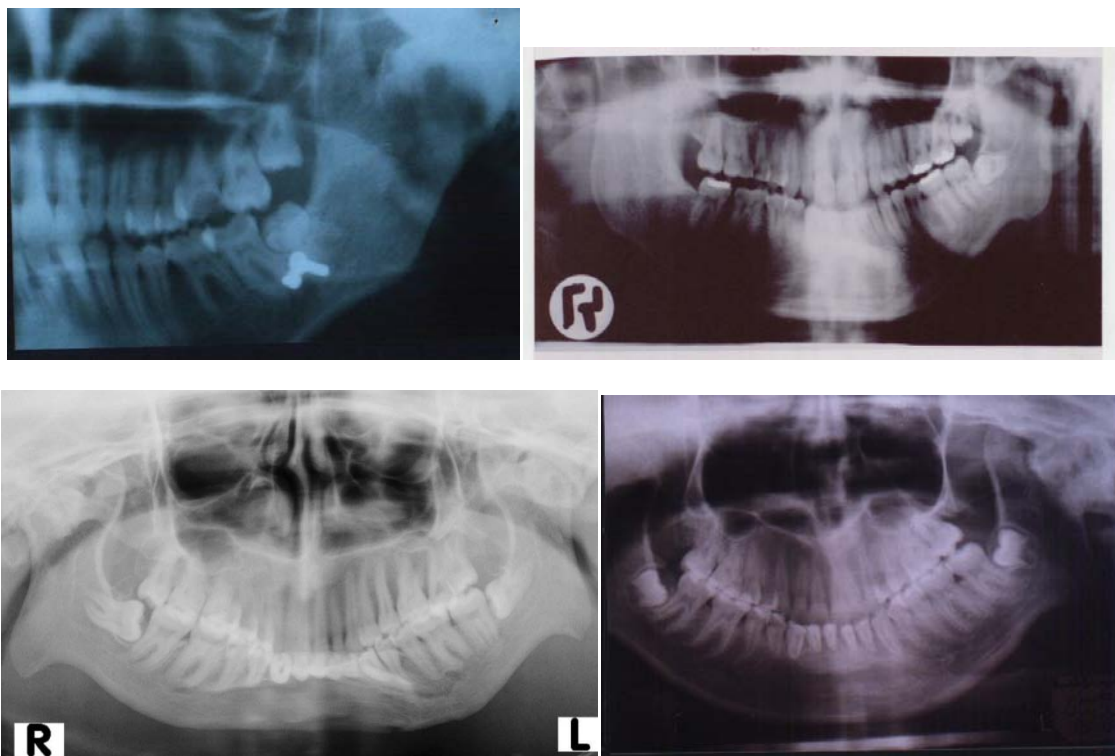


Fig. 2: Panoramic X-rays reveals bilateral and unilateral ankylosis.

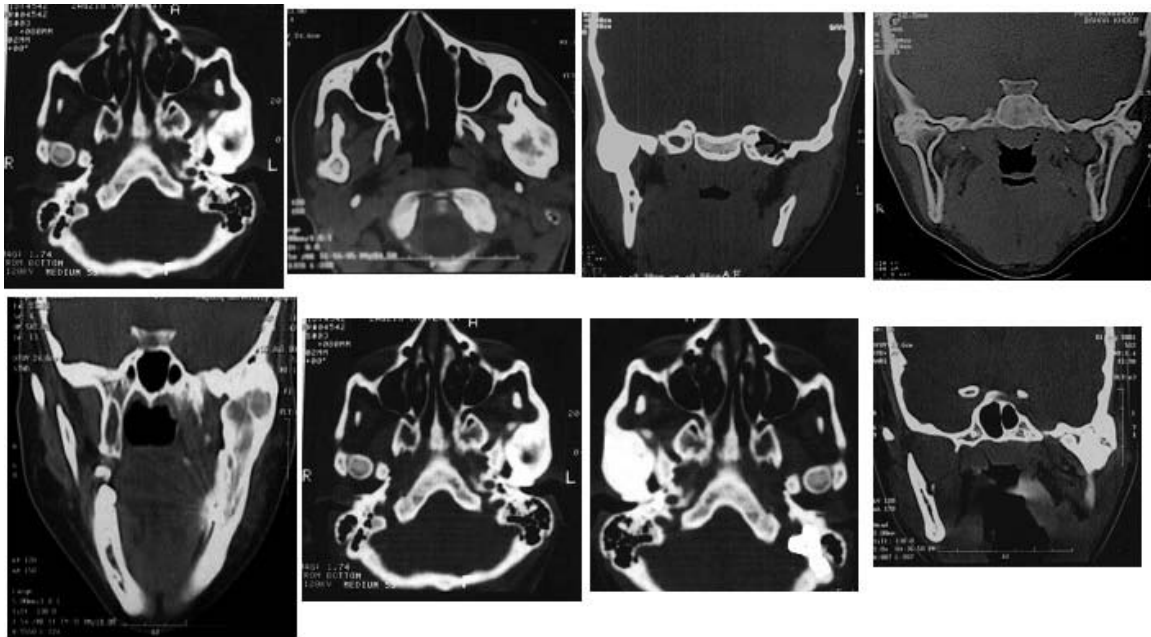


Fig. 3: Axial and coronal CT reveals the bilateral and the unilateral of ankylosis.

The size of the graft is almost the same as the size of the lateromedial dimension of the remained stump of the condyle, whereas the cartilage was harvested in an elliptical shape. The graft is harvested from the site, which has a similar curvature to that of the defect. The cartilage is sutured tightly

to the bed of the osteotomy at a minimum of two points with 2-0 non absorbable suture. The transversal axis of the harvested cartilage is sutured as horizontally as possible so as to fit the direction of the remained stump of the osteotomy cut.

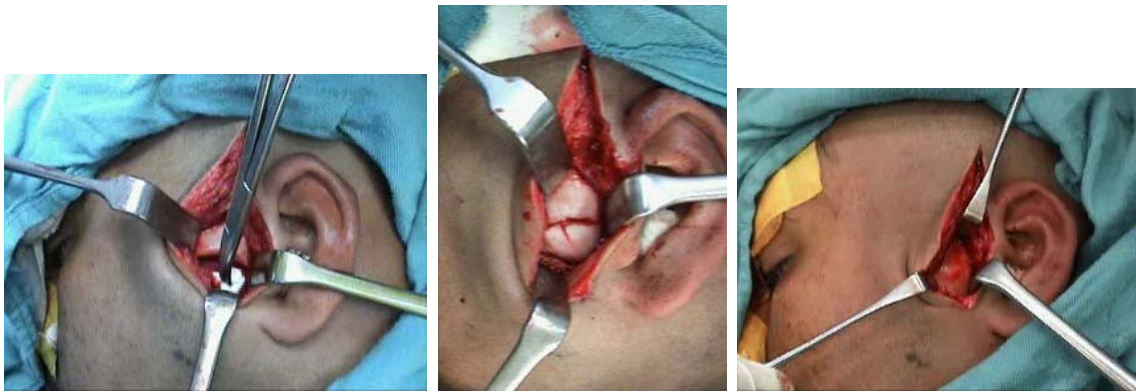

Fig. 4: Resection of ankylosed bone were removed creating a gap of at least 0.5 CM.

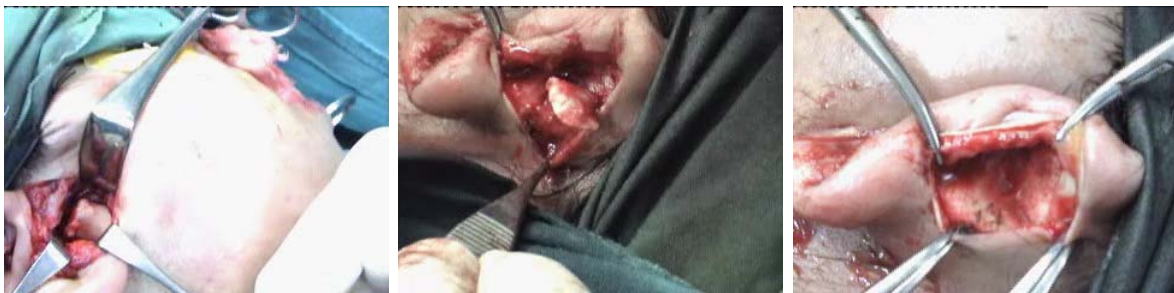

Fig. 5: Harvesting of the Auricular graft.

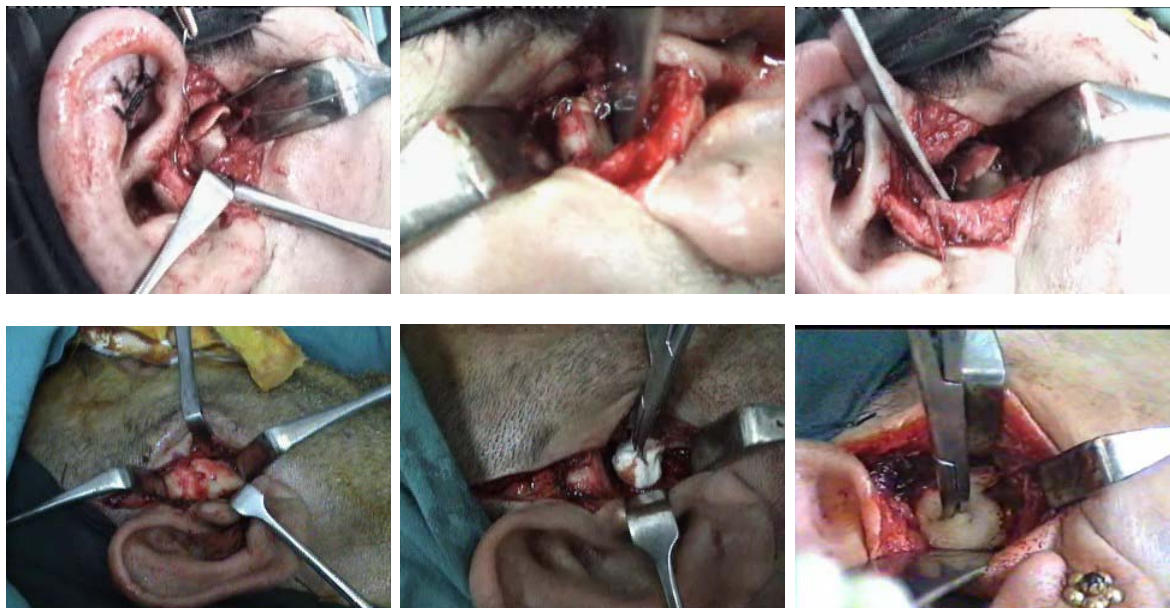

Fig. 6&7: Auricular graf in placed.

Closure of the donor site was performed primarily after placement of the graft. The skin is sutured using 5-0 nylon suture and no special dressing is needed. There is no consequence to the structural integrity of the auricle that leaves a near-perfect cosmetic closure of the wound and the postauricular scar was well hidden.

Ipsilateral and/or contralateral coronoidectomy was only performed in cases of long-standing untreated ankylosis where the passive mouth opening following surgery was inadequate. Closure of the incisions was done in layers using vicryl 3/0 for subcutaneous soft tissues and 5/0 black silk with interrupted or subcuticular sutures for the skin. Tight dressing was applied immediately on the incisions and removed on the second postoperative day. Vacuum suction drainage was left 48 hours. Removal of the skin stitches was done seven days postoperatively.

Jaw exercises began as early as 8 hours postoperatively and varied according to the level of patient's cooperation. Each patient was given wooden tongue blades and was asked to follow its use by application from 8 to 12 hours postoperatively. The patients were instructed to insert the blades in the molar area anteroposteriorly, make at least 7 to 10 blades per try, and make 10 or 15 tries every day. These rates were increased to 10 to 18 blades per try and 15 to 25 tries per day during the next 48 to 96 hours. By the 7th to 10th postoperative day the patients were asked to use the blades as many times as possible. This regimen continued for the next 4 or 8 weeks. As a supplement to the exercises, the patients were asked to eat food requiring active biting and chewing. Also, they recommended using chewing gum through the day for the first 6 months.

Particular effort was made to detect the postoperative complications. All patients were clinically and radiographically followed up for four years with successive reviews at 60 days. Immediate and 12 month postoperative panoramic X-rays were done for most patients. Clinical assessment and follow-up was done at 2, 4 weeks, 3,6,12 and 4 years after surgery. MR imaging was performed for all patient at the end of the follow up period with their mouth closed and open using 0.5 Tesla super-conductive machine (*Signa contour. General Electric [GE] medical system*).

Preparation of the patients for MR imaging:

The patients were asked about any contraindication for MR imaging examination as cardiac pacemaker, artificial valves or aneurysm clips. The patients were informed about the nature and duration of the examination (ranged from 20 to 30 minutes), and were instructed to remove any metallic object. Head coil was used for all cases. The patients were examined in a supine position. All patients were examined using oblique sagittal plane (perpendicular to the horizontal long axis of the mandibular condyle) and oblique coronal plane (perpendicular to the vertical long axis of the mandibular condyle) T1 and T2 weighted spin-echo sequences.

Results:

Of the 31 cases included in this study, 9 patients (29 %) had previous surgery for release of ankylosis; four of them were subjected to two operations. The male- to female ratio was 2:1. The mean age of patients was 23 year; the mean duration of ankylosis

was 10.8 years. Of these 31 patients, 18 (58%) had unilateral involvement and 13 (42%) had bilateral involvement.

History of trauma to the chin and TMJ was documented in 93% of cases. The presence of a distinct scar under the chin was noted in most cases.

In 6.4% of cases the cause of ankylosis was infection. The mean preoperative maximal incisal opening was 3 mm. In 40% of cases, the bony mass was palpated in the preauricular region, indicating excessive growth of bone lateral to the joint.

Table 1: Showing the Imaging parameters used:

Pulse-sequence	TR	TE	Interslice gap	Slice thickness	FOV	Matrix size	NEX
T1	440-600	10-15	0.5	3 mm	22x16.5	224x128	3
T2	3000-4000	85	0.5	3 mm	22x16.5	256x160	3

[TR: repetition time, TE: echo time, FOV: field of views, NEX: number of excitation (signal acquired)]

We have used 17 auricular grafts for management of 15 patients. Thirteen patients were unilateral and the remaining two were had bilateral ankylosis. Also, 12 patients had unilateral and 4 patients had bilateral ankylosis in the group 1. In all cases, the surgical approach was not changed in the form of preauricular approach. Follow-up periods ranged from 3 to 4 years. The grafted cartilage measured 1.5 cm and it was almost the same as the size of the lateromedial dimension of the remained stump of the condyle. The donor site healed without any problem. In all cases, no patients suffering a feeling of discomfort and an acceptable shape of the ear was achieved. There were no deformational changes in the graft donor site.

The complication of immediate and temporary postoperative facial nerve weakness was encountered in seven cases. In none of the cases permanent facial nerve dysfunction was noted. Postoperative pain and discomfort was easily managed with analgesics. Eight patients had unstable occlusion immediately postoperatively; improvement was noted spontaneously at one year follow-up.

Three patients showed delayed wound healing. Wound disruption was noted during skin suture removal about 7 days postoperatively and the wound healed within 3 weeks leaving a barely visible scar with a successful result.

It is of interest that all patients had no recurrence. Considerable improvement in maximal incisal opening was noted in all patients during the

follow-up period that extended to four years. All patients were able to make all the mandibular movements with mean maximal incisal opening 33 mm (Fig.11). However, some of patients included in this study were cases of reankylosis. It is of interest that all patients were able to make mouth opening without mandibular shifting during the movement.

Preoperative panorama and CT in axial & coronal planes revealed abnormal bony outgrowth localized to the mandibular condyle in (4 cases), involve the mandibular condyle and extend posteriorly to the temporal bone in (8 cases), and large bony mass with anterior extension to the zygomatic arch and posterior extension to the temporal bone in 7 cases. The TMJ space was completely obliterated in all cases. Asymmetry in the length of mandibular rami at both sides was detected in the unilateral cases (15 cases).

Of the 15 cases followed and evaluated for at least 4 years, there were no conchal bowl (donor site) deformities noted. No detectable complications were noted at the postauricular closure sites of all cases.

Post operative MRI follow up in 1st group reveals no significant post operative hypointense fibrous tissue scar development within the gap filled Mitomycin C. In the 2nd group MRI shows normal appearance of the placed auricular graft with normal signal intensity. The remained part of the mandibular ramus shows normal bone marrow signal intensity (Figs 8,9&10).

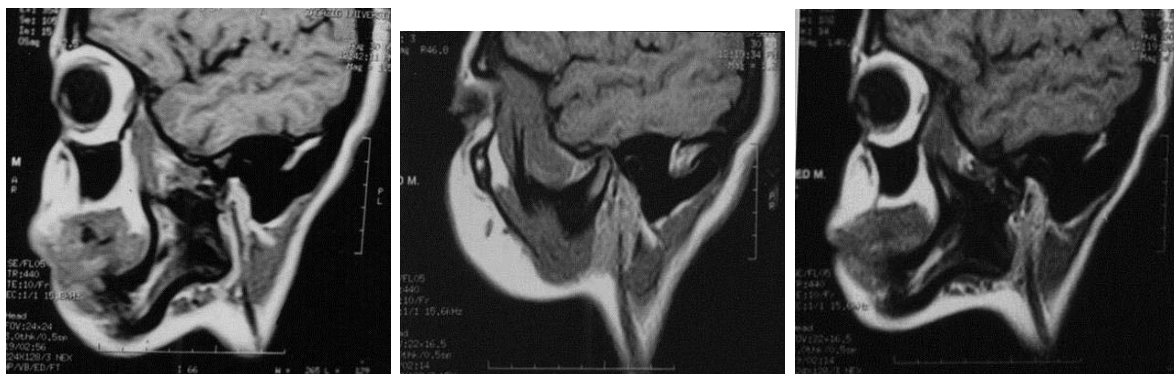


Fig. 8: MRI shows normal appearance of the placed auricular graft with normal signal intensity.

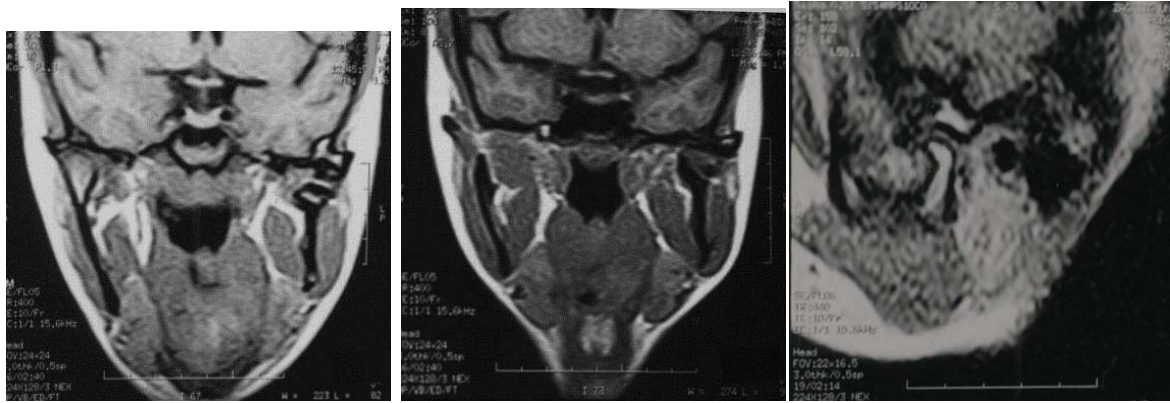


Fig. 9: MRI follow up reveals no significant post operative hypointense fibrous tissue scar development within the gap filled Mitomycin C.

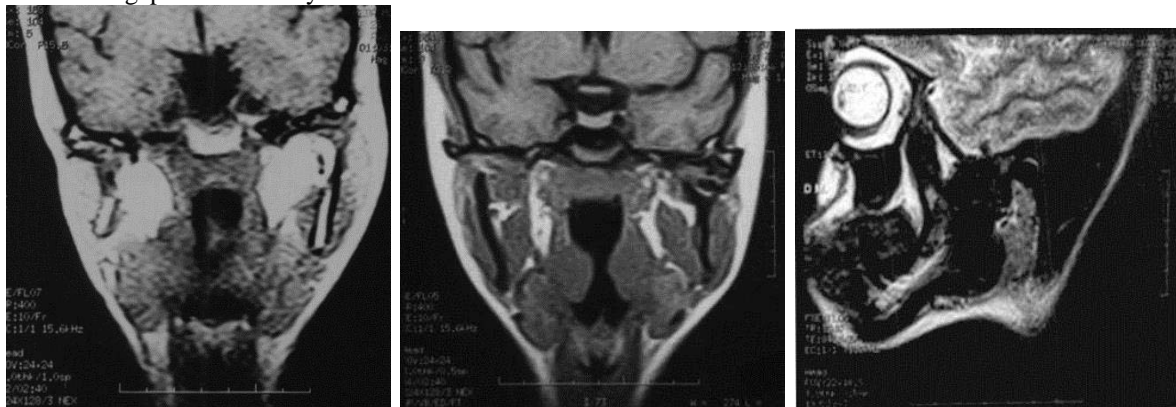

Fig. 10: MRI reveals the remained part of the mandibular ramus with normal bone marrow signal intensity.

The contra lateral joint space were examined in all unilateral cases and revealed normal MRI of TMJ

anatomy and no detected abnormal disc position in both open and closed mouth examination (Fig.11).

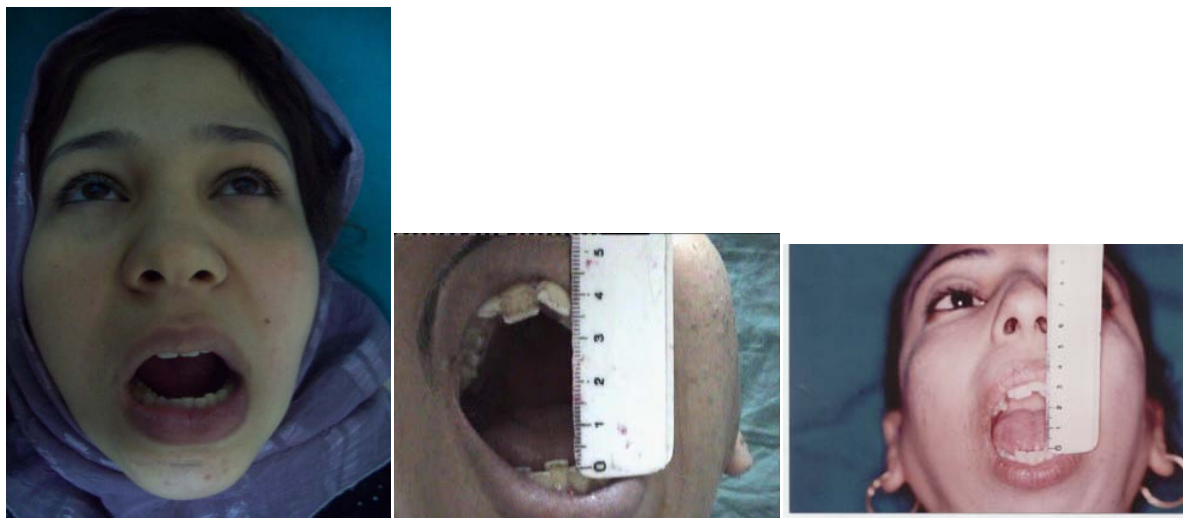


Fig. 11: Maximal incisal opening was measured.

Discussion:

Mitomycin C is an antibiotic isolated from the broth of streptomyces caespitosus which has been shown to have antitumor activity. It selectively

inhibits the synthesis of deoxyribonucleic acid (DNA). The compound is heat stable, has a high melting point, and is freely soluble in organic solvents. It has the ability to significantly suppress fibrosis and vascular ingrowth. It has been widely

used in pterygium excision and trabeculectomy with favorable results. The literature is replete with intravenous uses of the drug as adjuvant and/ or palliative treatment for cancer and its topical uses in ophthalmologic surgery [2,4]. According our knowledge, it is the first time to be used for TMJ surgery.

TMJ ankylosis remains a challenge for oral and maxillofacial reconstructive surgery [25]. The characteristic pathology of ankylosis is the formation of a bony mass, which replaces the articulation resulting in restriction of mandibular movements. The common objective to all surgical techniques is, therefore, partial or radical removal of this ankylotic mass. Three major problems are encountered. First, the volume and extent of the ankylotic bony mass in relation to the cranial base is highly variable and radical excision, therefore, may pose a considerable risk. Second, the scar tissue that surrounds the ankylotic mass often prevents unimpeded mandibular movements even when the bony mass has been meticulously excised. Hence, management of reankylosis in particular becomes progressively difficult as the scar tissue increases with each surgical intervention. Third, radical removal of the bony mass leaves large opposing surfaces of healing bone, which is likely to be bridged by dense scar tissue that can result in restriction of mandibular movement and give rise to reankylosis [13,5,20].

The ankylotic bony mass is not a neoplastic process capable of continued growth. For this reason excision of mass is not necessary. Paul, [21] discussed another alternative to the conventional approach on 14 patients. He managed ankylosis by converting it into subcondylar fracture. He reported that the area of normal bone immediately below the ankylotic mass is the best site for formation of a pseudoarthrosis. He added that although this approach did not address the pathology itself, it offered the most effective means for the management of ankylosis even in cases of recalcitrant ankylosis where other techniques had proved unsatisfactory.

The standard techniques of interposition arthroplasty are rarely able to bridge the entire area of exposed bone particularly at the medial aspect therefore, may contribute to reankylosis [21]. In addition the removal of each failed implant means a second surgical intervention in the joint area with subsequent scarring and functional limitation. For these reasons excision of the bony mass and alloplastic interposition implants in the treatment of cranio- mandibular ankylosis is associated with some disadvantages. The results of this study coincide with that concept in which mitomycin C as a liquid could be reach to the entire area of exposed bone especially at the medial side of the joint by direct application and dissemination and preventing the formation of dense scar tissue thus, it might be overcoming the disadvantages of interposition arthroplasty.

Meticulous and radical elimination of the ankylotic bone as recommended by Gunaseelan, [8] and Kaban *et al.*, [13] offered a logical issue. However, the surgical risk is considerable and the advantage gained marginal, since complete elimination of the ankylotic bone still creates an extensive area of healing bone where only scar tissue will inevitably form. A piece of micro sponge saturated with 0.2 mg/ml mitomycin C used in the present work prevents the scar tissue to form after an application time of 5 minutes. So, the surgical risk is reduced whenever no need for removal of large area of ankylotic bone. In addition, the chemical effects of the drug suppress the fibrosis tissue.

The vertical extent of the ankylotic mass may be highly variable particularly in cases of recurrent ankylosis. The base of ankylotic mass is usually at a lower level on the medial aspect. So, it is essential to place the osteotomy cut at 5 millimeters inferior to the base of the ankylotic mass as visualized on the lateral aspect [21]. On the other hand, this study recommended that the osteotomy site might be made through the ankylotic mass itself at a higher level of the articulation with fossa depending on the chemical action of mitomycin C for prevention of scar tissue and fibrosis within the ankylotic bone itself.

Moreover, in cases of ankylosis, the ramus is short and its morphology is abnormal due to accentuated gonial angle. Also, the resected ankylotic mass in gap arthroplasty operations must be large enough; however, this will increased the shortness of the ramus and the deviation toward the affected side. In the present study, only 0.5 Cm was resected and there is no need for resection of wide segment of the ankylotic part thus overcoming the more shortness of the ramus and mandibular deviation during mouth opening postoperatively.

The functioning pseudoarthrosis relies upon the distance between resected bone surfaces and interpositional autogenous, homologous or alloplastic material to prevent reankylosis and facilitate functional joint activity [15]. Since the only tissue that can occupy the space created by the removal of the ankylotic bone is either scar or bone, these tissues bridge across a wide gap yields sufficiently to permit a degree of movement that perhaps accounts for the somewhat limited mouth opening consequently, the need for second operation and its complication. In contrast, results of the present work indicates that postoperative maximal incisal distance of all patients were within normal (30mm) without limitation of the mouth opening even in cases of bilateral ankylosis.

Kao *et al.*, [14] reported that the application of the mitomycin C over the osteotomy site during dacryocystorhinostomy (DCR) surgery is effective in maintaining a larger osteotomy site. In addition, Ugubas *et al.*, [24] studied the histopathological effects of the mitomycin C on transnasal DCR by using 0.5 mg/ ml mitomycin C soaking for 2.5 minutes over the osteotomy site. They concluded that

mitomycin C soaking can result in a decrease in density and cellularity of mucosa, and hence, enhance the success of DCR surgery. Moreover, Yeatts and Neves [26] reported eight cases of repeat DCR using mitomycin C soaking with successful results. They recommended that the adjunctive use of mitomycin C may increase the success rate of repeat DCR.

It is well recognized that auricular composite graft is useful material to provide skin with less shrinkage and rigid support. Many authors [7,19] have applied auricular composite graft to reconstruct defects of various sites that require support and recreation of a complex shape, including the ala nasi, nasal vestibule, ear, lower eyelid, and nail. Moreover, auricular composite graft has been used for recreating the philtrum dimple. This graft does not cause any cosmetic impact because the cartilage is taken from the middle of the pinna leaving sufficient peripheral cartilage to support the pinna and maintain ear shape. The important point in this study is that the cartilage is harvested in an elliptical shape and that the transversal axis of the cartilage is positioned in the mediolateral direction of the joint. In short, we believe that the elliptically shaped cartilage corresponding to the direction of the joint movement plays an important role in covering all raw bony stump of the joint.

Some complications due to mitomycin C application have been reported in both pterygium and glaucoma filtration operations [2,17,23]. In contrast, results of this study showed no complications such as hematoma, abnormal bleeding, tissue necrosis, or infection noted with mitomycin C soaking. This may be regard to the application form of the drug and its concentration used. Similar results were reported [27]. Delayed wound healing that was occurred in one case in this study may be the result of accidental contact of mitomycin C soaked sponge on the skin wound and could have been prevented by carefully managing the sponge.

In contrast to the fluoroscopic aided retrograde placement of guide wire for tracheal intubation in patients with limited mouth opening used by Biswas *et al.*, [3], a light aided blind nasal intubation was done safely in this work by the help of small illuminating lamp introduced through the nose and fixed at the tip of the endotracheal tube that could be shown and guided extraorally through the skin of the front of the neck.

Reduction of operative and anesthetic time, availability of the drug, prevention of re-ankylosis, decreased postoperative morbidity, saving an additional surgery of harvesting autogenous graft, and saving adverse reactions of alloplastic materials are some advantages of the first group technique.

Conclusion:

Although a success rate of different surgeries craniomandibular ankylosis, some cases still fail. In this study, the use of intraoperative mitomycin C soaking over the osteotomy site can minimize the adhesions and fibrosis. So, its use may be a useful modified procedure to improve the success rate of these operations with no significant complications resulted from its use. Also, this idea offers no a departure from the conventional philosophy of management of craniomandibular ankylosis but might be an addition to reduce the surgical risk and improve the results especially in the management of re-ankylosis and in cases where the ankylotic mass is extensive. In addition, auricular graft technique involves little tissue dissection, an ability to match the graft to any bony stump size or shape, and the ready availability of the graft with virtually no donor site morbidity.

References

1. Aggarwal, S., S. Mukhopadhyay, M. Brrry, S. Bhargava, 1999. Bony ankylosis of tempromandibular joint; a computed tomography study. *Oral Surg Oral Med Oral Pathol.*, 69: 128-32.
2. Bergstrom, T.J., W.S. Wilkinson, G.L. Skuta, 1991. The effects of subconjunctival mitomycin C on glaucoma filtration surgery in rabbits. *Arch Ophthalmol.*, 109: 1725-1730.
3. Biswas, B.K., P. Bhattacharyya, S. Joshi, U.R. Tuladhar and S. Baniwal, 2005. Fluoroscopic-aided retrograde placement of guide wire for tracheal intubation in patients with limited mouth opening. *British J of Anesthesia*, 94(1): 128- 131.
4. Cano-parra, J., M. Diaz-Liopis, M.J. Maldonado, 1995. Prospective trail of intraoperative mitomycin C in the treatment of primary pterygium. *Br J Ophthalmol.*, 79: 439-441.
5. Chossegros, C., L. Guyot, F. Cheynet, J.L. Blanc, P. Cannoni, 1999. Full thickness skin graft interposition after tempromandibular joint ankylosis surgery. A study of 31 cases. *Int J Oral Maxillofac Surg.*, 28: 330-4.
6. C.T. and M.R., 1988. Imaging of the temporomandibular joint Volume 8, Number 2 #149M arch, 1988 #149R adioGraphics.
7. Fred J. Stucker, Kenneth W. Sanders, 2002. A Method to Repair Auricular Defects After Perichondrial Cutaneous Grafting: *Laryngoscope*, 112: 1385-1392.
8. Gunaseelan, R., 1997. Condylar resection in extensive ankylosis of tempromandibular ankylosis in adults using resected segment as auto graft. A new technique. *Int J Oral Maxillofac Surg.*, 26: 405-7.

9. Guyuron, B., C.L. Lasa, 1992. Unpredictable growth pattern of costochondral graft. *Plast Reconstr Surg.*, 90: 880.
10. Haidar, Z., 1986. Ankylosis of tempromandibular joint: causes and management. *J Oral Med.*, 41: 246-9.
11. Izumi, Y., K. Kino, Y. Ohmura, H. Wake, T. Shibuya and T. Amagasa, 1964. Clinocostatistical study of tempromandibular joint ankylosis: etiology and onset age. *Journal of Japanese Society for tempromandibular joint*, 6: 100-13.
12. Kaban, L., M.A. Pogrel, D.H. Perrott, 1997. *Complication of maxillofacial surgery*. 1st ed Philadelphia: WB Saunders, pp: 98.
13. Kaban, L.B., D.H. Perrott, 1990. A protocol for management of tempromandibular joint ankylosis. *J Oral Maxillofac Surg.*, 48: 1145-51.
14. Kao, S.C.S., S.L. Liao, J.H.S. Tseng, 1997. Dacryocystorhinostomy with intraoperative mitomycin C. *Ophthalmology*, 104: 86-91.
15. Lello, G.E., 1990. Surgical correction of tempromandibular joint ankylosis. *J Craniomaxillofac Surg.*, 18: 19-26.
16. Magnetic Resonance Imaging of the Temporomandibular Joint Hayt, 2000. Michael W. M.D., D.M.D., Abrahams, James J.M.D., Blair, Jennifer B.A. *Topics in Magnetic Resonance Imaging*, 11(2): 138-146.
17. Megevand G.S., J.F. Salmon, R.P. Scholtz, 1995. The effect of reducing the exposure time of mitomycin C in glaucoma filtering surgery. *Ophthalmology*, 102: 84-90.
18. Meiqing Wang, Hongtao Cao, C. Yali Ge and E. Sven, 2009. Magnetic resonance imaging on TMJ disc thickness in TMD patients: A pilot study, *J Prosthet Dent.*, 102: 89-93.
19. Mitsuo Hatoko, Aya Tanaka, Masamitsu Kuwahara, Katsunori Niitsuma, Hiroshi Iioka, Kashihara, 2003. Auricular Composite Graft for Skin Defect of the Philtrum Dimple: *J craniofacial Surg.*, 14 (2).
20. Nitzan, D.W., J. Bar-Zin, A. Shteyer, 1998. Surgical management of tempromandibular joint ankylosis type 111 by retaining the displaced condyle and disc. *J Oral Maxillofac Surg.*, 56: 1133-8.
21. Paul, C.S., 2000. New perspectives in the management of cranio- mandibular ankylosis. *Int J Oral Maxillofac Surg.*, 29(5): 337-340.
22. Roychoudhury, A., H. Parkash and A. Trikha, 1999. Functional restoration by gap arthroplasty in tempromandibular joint ankylosis. *Oral Surg Oral Med Oral Pathol.*, 87(2).
23. Rubinfeld, R.S., R.R. Pfister, R.M. Stein, 1992. Serious complications of topical mitomycin C after pterygium surgery. *Ophthalmology*, 99: 1647-1654.
24. Ugurbas, S.H., G. Zilelioglu, M.F. Sargon, 1997. Histopathologic effects of mitomycin C on endoscopic transnasal dacryocystorhinostomy. *Ophthalmic Surg Laser.*, 28: 300-304.
25. Weng, Y., Y. Cao, C.A. Silva, M.P. Vacanti and C.A. Vacanti, 2001. Tissue-engineered composites of bone and cartilage for mandible condylar reconstruction. *J Oral Maxillofac Surg.*, 59: 185-190.
26. Yeatts, R.P. and R.B. Neves, 1999. Use of mitomycin C in repeat dacryocystorhinostomy. *Ophthalmic. Plast Reconstr Surg.*, 15: 19-22.
27. You, Y.A., C.T. Fang, 2001. Intraoperative mitomycin C in dacryocystorhinostomy. *Ophthalmic Plast Reconstr Surg.*, 17(2): 115-119.