

Available online at www.sciencedirect.com

SCIENCE @ DIRECT®

Psychiatry Research: Neuroimaging 131 (2004) 263–268

PSYCHIATRY
RESEARCH
NEUROIMAGINGwww.elsevier.com/locate/psychresns

Increased frontal cortical folding in autism: a preliminary MRI study

Antonio Y. Hardan*, Roger J. Jou, Matcheri S. Keshavan, Ravi Varma,
Nancy J. Minshew

*Department of Psychiatry, Western Psychiatric Institute and Clinic, University of Pittsburgh School of Medicine,
3811 O'Hara Street, Pittsburgh, PA 15213, USA*

Received 23 January 2004; received in revised form 1 June 2004; accepted 12 June 2004

Abstract

The gyrification index (GI), the ratio of total to outer cortical contour, was applied to measure the cerebral folding patterns in autism. GI was examined on a frontal coronal slice obtained from MRI scans of 30 nonmentally retarded individuals with autism and 32 matched healthy controls. In the autistic group, left frontal GI was higher in children and adolescents but not in adults. Cortical folding was decreased bilaterally with age in the total autistic sample but not in controls. These preliminary findings suggest that the gyrification patterns in autism may be abnormal, which could be related to the various cortical anomalies observed in this disorder.

© 2004 Elsevier Ireland Ltd. All rights reserved.

Keywords: Gyrification index; Magnetic resonance imaging; Prefrontal cortex; Cerebral convolution; Autistic disorder

1. Introduction

Autism is a pervasive developmental disorder characterized by marked deficits in reciprocal social interaction and communication, as well as a restricted repertoire of interests and activities (American Psychiatric Association, 1994). Neuropathologic and neuroimaging studies have reported a number of cortical abnormalities (Kemper and Bauman, 1998; Courchesne et al., 2001), including shifting of the superior and inferior frontal sulci (Levitt et al., 2003) and the existence of polymicrogyria and various

anomalies in the gyrification patterns (Piven et al., 1990). Moreover, the degree of cortical folding is closely associated with brain size and weight (Armstrong et al., 1995), and abnormalities in these two measures have been reported in autism (Kemper and Bauman, 1998; Courchesne et al., 2001). This converging evidence suggests an abnormal neurodevelopmental process with possible abnormalities of the gyrification patterns in autism throughout the brain, including the prefrontal cortex. Interestingly, no study to date has quantitatively examined the cerebral cortical folding in autism, and its investigation is warranted.

The gyrification index (GI), a measure of the degree of cortical folding, is calculated by dividing the lengths of the total contour by the outer contour as measured on coronal slices (Zilles et al., 1988).

* Corresponding author. Tel.: +1-412-246-6797; fax: +1-412-521-4073.

E-mail address: hardanay@upmc.edu (A.Y. Hardan).

Cortical gyrification is an important marker of cerebral development, and more importantly, convolutional maturation is associated with the development of neuronal connections (Armstrong et al., 1995). Cerebral cortical folding becomes progressively more complex during gestation, and the GI reaches a stable plateau value during the first year of life and appears to remain unchanged thereafter (Armstrong et al., 1995). GI was originally developed as a post-mortem strategy to examine cortical abnormalities but was recently applied to magnetic resonance imaging (MRI) to assess gyrification patterns in different neuropsychiatric disorders including schizophrenia (Kulynych et al., 1997).

The objective of this preliminary study was to examine the cortical folding in individuals with autism through the application of the GI in a selected region of the prefrontal cortex, because converging evidence from structural and functional studies have consistently implicated the frontal lobe in the pathophysiology of autism (Courchesne et al., 2001; Zilbovicius et al., 1995). It is hypothesized that individuals with autism will display increased gyrification patterns when compared with controls as measured by the GI, and this increase will be more prominent in children and adolescents than in adults.

2. Methods

The GIs were calculated for 30 nonmentally retarded males with autism and 32 healthy controls. The study was confined to right-handed males, because the sample size was too small to allow for structural variability associated with handedness and gender. Subjects with autism represented all consecutive referrals to a research clinic and met the following inclusion criteria: (1) diagnosis through expert clinical evaluation and two structured research diagnostic instruments, including the Autism Diagnostic Interview—Revised (Lord et al., 1994) and the Autism Diagnostic Observation Schedule (Lord et al., 1989); (2) age between 8 and 50 years; (3) full-scale IQ (FSIQ) >70 as determined using the age-appropriate version of the Wechsler Intelligence Scale; and (4) absence of any neurological disorders. Controls were medically healthy individuals recruited from communities through advertisements in areas socially and econom-

ically comparable to the communities of origin of the autistic subjects. All controls were free from neuropsychiatric disorders and had negative personal and family histories for any neurological or psychiatric disorders. After procedures were fully explained, all subjects or their legal guardians provided written informed consent, and verbal assent was obtained from all subjects. MRI scans were acquired using a General Electric (Milwaukee) 1.5 Tesla Signa scanner. The imaging protocol included a 1.5-mm spoiled gradient recalled echo in steady state (SPGR) coronal series (TR = 35, TE = 5, NEX = 1, flip angle = 45°), which was used for all measurements reported in this study.

MRI scans were analyzed using the Brains2 software package (Magnotta et al., 2002). Before analysis, all scans were aligned so the coronal plane was orthogonal to the anterior–posterior commissure line. Determining the GI typically involves the measurement of the gyrification patterns in multiple coronal slices, which is a very laborious process. However, taking into consideration the preliminary nature of this investigation, the first frontal coronal slice anterior to the corpus callosum (CC) was used. This slice was chosen because the CC is a large and distinct landmark that is easy to visualize across all scans.

The GI was measured bilaterally using a novel manual tracing technique (Fig. 1). The outer contour was taken as the superficially exposed cortical contour. It was traced in close approximation to the pial surface along the outer gyral ridge while passing over the sulcal grooves. Therefore, the length of the outer contour corresponds to the superficial perimeter of the brain. The total contour was calculated by adding the outer contour to the total sulcal length. Sulcal lengths were measured by tracing all sulcal grooves with a single line starting at the outer contour and stopping at the end of the groove. The total sulcal length was calculated by multiplying the sulcal lengths by two. Buried gyri were also included in this calculation. These gyri had the characteristics of regular gyri, except they did not communicate with the outer surface. They were traced with a single line that does not communicate with the outer contour. These single lines were also multiplied by a factor of two and included in the calculation of the length of the total contour. Finally, the GI was computed by dividing the length of the total contour by the length of the outer contour. All measurements were performed by the

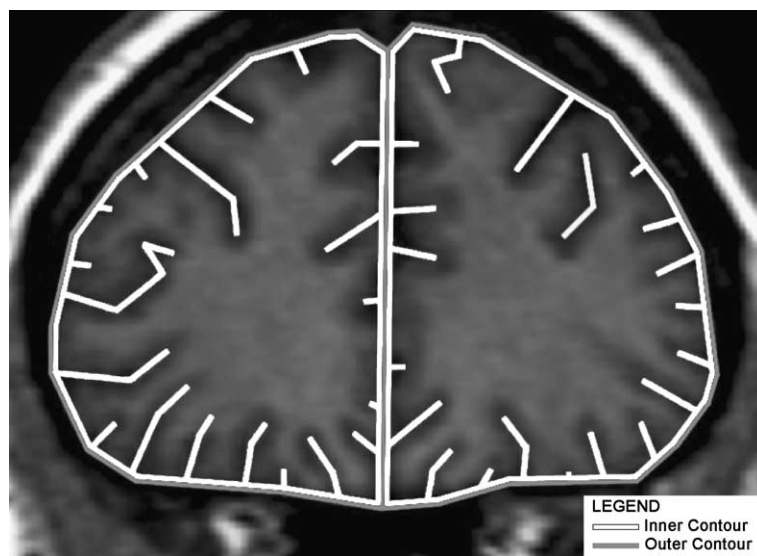


Fig. 1. Manually traced inner and outer cortical contours used for measuring the gyrification index.

same rater who was blind to the diagnoses of all study subjects. Reliability was conducted on 10 randomly selected brain scans between two raters (R.J. and R.V.) and revealed acceptable an intraclass correlation coefficient (ICC) of 0.90.

Measurements of total brain volume (TBV) were made on a Gateway 2000 graphics workstation (N. Sioux City, SD) using locally developed custom graphics software (Aylward et al., 1998). A semi-automated thresholding procedure was used for segmenting the brain from CSF and extracerebral tissue, as described elsewhere (Aylward et al., 1998). Measurements were performed blind to diagnosis. Interrater reliability for obtaining brain volumes with this procedure yielded an ICC of 0.99 on 10 brains. Because two different programs were used to conduct morphometric studies, TBV measurements were obtained from 10 scans using both methods and revealed high reliability between the two programs (0.95) and acceptable ICC (0.85).

Taking into consideration the developmental changes observed with the GI (Armstrong et al., 1995) and the age-related alterations reported in brain size in autism (Courchesne et al., 2001), analyses of the data were conducted for the whole sample initially and for children/adolescents and adults separately while setting an arbitrary cutoff at 18 years of age. A two-tailed statistical significance level was set at

$P < 0.05$ for all analyses. All GI measurements between the two groups were analyzed using Student's *t*-test. An analysis of covariance was used to compare the two groups on the GI while controlling for TBV. Pearson's correlations coefficients were used to examine the association between age and GI.

3. Results

There were no differences between the autistic and control groups in age, IQ, and TBV when all participants were examined together or divided by age group (Table 1). In children/adolescents, the mean left but not right frontal GI was significantly higher in the autistic group compared with the control group (Table 2). In contrast, no differences between autistics and controls were observed in adults. These results were unchanged after controlling for TBV. When children/adolescents and adults were examined together, no significant differences were found in the mean frontal GI values between the two groups on both the right (autistic group: mean GI = 2.86, S.D. = 0.21; control group: mean GI = 2.87, S.D. = 0.20; $t = -0.14$, $P = 0.89$) and left sides (autistic group: mean GI = 2.85, S.D. = 0.22; control group: mean GI = 2.86, S.D. = 0.19; $t = -0.25$, $P = 0.80$). These findings were unchanged after controlling for TBV. Interestingly, there was a significant

Table 1
Subject characteristics by diagnostic and age groups

Age group/characteristic	Autistics		Controls	
	Mean	S.D.	Mean	S.D.
< 18 years old	<i>N</i> =12		<i>N</i> =13	
Age	12.73	2.24	12.85	2.28
Full-scale IQ	104.9	16.21	110.2	12.67
Verbal IQ	106.7	16.11	111.1	12.34
Performance IQ	102.3	17.55	107.9	11.96
Total brain volume (cc)	1402	146	1317	105
≥ 18 years old	<i>N</i> =18		<i>N</i> =19	
Age	27.8	8.8	27.7	8.65
Full-scale IQ	99.7	12.1	102.0	13.03
Verbal IQ	104.1	15.3	101.8	12.18
Performance IQ	94.7	9.50	101.5	12.3
Total brain volume (cc)	1332	132	1264	128

No statistically significant differences ($P>0.05$).

decrease in the frontal gyrification patterns with age in the autistic group (right side: $r = -0.44$, $P = 0.012$; left side: $r = -0.48$, $P = 0.006$), which was not seen in controls (right side: $r = -0.12$, $P = 0.51$; left side: $r = -0.065$, $P = 0.72$). When the interaction between subject groups and age was examined, a trend toward significance was observed in the left frontal GI ($P = 0.057$), but not in the right ($P = 0.96$).

4. Discussion

The findings of this preliminary investigation suggest the possible existence of increased cortical

folding in the frontal lobe of children and adolescents with autism. This result may be consistent with anomalies of minicolumn structure in the superior and middle frontal gyri, indicating that cell columns in the brains of autistic patients are more numerous and dispersed (Casanova et al., 2002). Increased cortical folding in combination with minicolumn abnormalities is consistent with the radial unit hypothesis, which asserts that the surface area of a given region of the cerebral cortex depends on the number of contributing proliferative units that later form cell columns (Rakic, 1988). Therefore, abnormalities of the gyrification patterns observed here may reflect abnormalities in neuronal migration leading to a dysfunction of the frontal circuitry, which has been incriminated extensively in the development of the social and cognitive deficits in autism (Zilbovicius et al., 1995).

Developmental differences in the gyrification patterns of the frontal lobe between the autistic and control groups were also observed in the current pilot investigation. The negative correlation between the GI and age in the autistic group is consistent with neuropathological and neuroimaging studies reporting increased brain weight (Kemper and Bauman, 1998) and volume (Courchesne et al., 2001) in children/adolescents with autism, but not in adults. Therefore, it may be possible that a common pathway underlies the pathophysiology of both brain enlargement and abnormal gyrification in autism, which may be related to disturbances in the brain maturation processes. This is also consistent with the observation that the degree of cortical folding

Table 2
Gyrification index (GI) by diagnostic and age groups

Age group/GI	Autistics		Controls		<i>t</i> -test		TBV as a covariate	
	Mean	S.D.	Mean	S.D.	<i>t</i>	<i>P</i>	<i>F</i>	<i>P</i>
< 18 years old	<i>N</i> =12		<i>N</i> =13				<i>df</i> =23	
Right GI	2.97	0.16	2.94	0.20	0.420	0.679	0.301	0.589
Left GI	2.99	0.11	2.87	0.13	2.456	0.022	9.138	0.007
≥ 18 years old	<i>N</i> =18		<i>N</i> =19				<i>df</i> =35	
Right GI	2.80	0.20	2.82	0.19	-0.475	0.638	0.539	0.468
Left GI	2.76	0.23	2.86	0.21	-1.352	0.185	2.416	0.130

TBV = total brain volume.

is most closely associated with brain size (Armstrong et al., 1995). However, the exact significance of GI anomalies remains to be determined because GI may increase, decrease, or remain the same depending on the underlying pathology (Kulynych et al., 1997). Additionally, any age-related changes cannot be accurately assessed from cross-sectional studies, and only longitudinal studies will allow a better understanding of the relationship of age and gyrification.

The findings of this report must be interpreted in the context of a number of methodological limitations. First, examination was limited to the coronal slice immediately anterior to the CC. This approach was not consistent with other MRI studies of the GI, which used at least three (and up to 50) slices. Additionally, the number of data points sampled is insufficient to draw final conclusions about the cortical folding of the entire prefrontal cortex. Furthermore, the use of the CC as a landmark is not ideal, taking into consideration the variability of its location, especially in individuals with autism where decrease of its size has been reported (Hardan et al., 2000). Second, cortical contours were approximated by a manual tracing technique that is different from the standard post-mortem method for measuring the GI (Zilles et al., 1988). This strategy was employed because limitations in scan resolution made it impossible to perform exact tracing of the pial surface within sulci. It also has limited ability to account for sulcal variability when tracing the total contour. Third, adjustment for multiple comparisons was not conducted, which may have increased the probability of type I error. Finally, the GI as measured using MRI scans generally may not reflect the exact gyrification patterns, and comparative post-mortem studies are needed to assess the validity of this and other imaging methodologies examining GI.

In light of these limitations, additional studies are undoubtedly needed before any conclusions can be drawn regarding abnormal cortical gyrification in children and adolescents with autism. Cross-sectional and longitudinal studies are warranted to examine multiple brain regions using a larger number of slices in patients with a wide range of symptom severity levels while applying novel morphometric software with semiautomated methodologies.

Acknowledgements

This work was supported in part by NIMH grant MH 64027 to Dr. Hardan, and NINDS grant NS 33355 and NICHD grant HD 35469 to Dr. Minshew.

References

- American Psychiatric Association, 1994. *Diagnostic and Statistical Manual of Mental Disorders*, 4th ed. Author, Washington, DC.
- Armstrong, E., Schleicher, A., Omran, H., Curtis, M., Zilles, K., 1995. The ontogeny of human gyrification. *Cerebral Cortex* 5, 56–63.
- Aylward, E.H., Anderson, N.B., Bylsma, F.W., Wagster, M.V., Barta, P.E., Sherr, M., Feeney, J., Davis, A., Rosenblatt, A., Pearlson, G.D., Ross, C.A., 1998. Frontal lobe volume in patients with Huntington's disease. *Neurology* 50, 252–258.
- Casanova, M.F., Buxhoeveden, D.P., Switala, A.E., Roy, E., 2002. Minicolumnar pathology in autism. *Neurology* 58, 428–432.
- Courchesne, E., Karns, C.M., Davis, H.R., Ziccardi, R., Carper, R.A., Tigue, Z.D., Chisum, H.J., Moses, P., Pierce, K., Lord, C., Lincoln, A.J., Pizzo, S., Schreibman, L., Haas, R.H., Akshoomoff, N.A., Courchesne, R.Y., 2001. Unusual brain growth patterns in early life in patients with autistic disorder: an MRI study. *Neurology* 57, 245–254.
- Hardan, A.Y., Minshew, N.J., Keshavan, M.S., 2000. Corpus callosum size in autism. *Neurology* 55, 1033–1036.
- Kemper, T.L., Bauman, M., 1998. Neuropathology of infantile autism. *Journal of Neuropathology and Experimental Neurology* 57, 645–652.
- Kulynych, J.J., Luevano, L.F., Jones, D.W., Weinberger, D.R., 1997. Cortical abnormality in schizophrenia: an in vivo application of the gyrification index. *Biological Psychiatry* 41, 995–999.
- Lord, C., Rutter, M., Goode, S., Heemsbergen, J., Jordan, H., Mawhood, L., Schopler, E., 1989. Autism Diagnostic Observation Schedule: a standardized observation of communicative and social behavior. *Journal of Autism and Developmental Disorders* 19, 185–212.
- Lord, C., Rutter, M., LeCouteur, A., 1994. Autism Diagnostic Interview—Revised: a revised version of a diagnostic interview for caregivers of individuals with possible pervasive developmental disorders. *Journal of Autism and Developmental Disorders* 24, 659–685.
- Levitt, J.G., Blanton, R.E., Smalley, S., Thompson, P.M., Guthrie, D., McCracken, J.T., Sadoun, T., Heinichen, L., Toga, A.W., 2003. Cortical sulcal maps in autism. *Cerebral Cortex* 13, 728–735.
- Magnotta, V.A., Harris, G., Andreasen, N.C., O'Leary, D.S., Yuh, W.T., Heckel, D., 2002. Structural MR image processing using the BRAINS2 toolbox. *Computerized Medical Imaging and Graphics* 26, 251–264.
- Piven, J., Berthier, M.L., Starkstein, S.E., Nehme, E., Pearlson, G., Folstein, S., 1990. Magnetic resonance imaging evidence for a

- defect of cerebral cortical development in autism. *American Journal of Psychiatry* 147, 734–749.
- Rakic, P., 1988. Specification of cerebral cortical areas. *Science* 241, 170–176.
- Zilbovicius, M., Garreau, B., Samson, Y., Remy, P., Barthelemy, C., Syrota, A., Lelord, G., 1995. Delayed maturation of the frontal cortex in childhood autism. *American Journal of Psychiatry* 152, 248–252.
- Zilles, K., Armstrong, E., Schleicher, A., Kretschmann, H.J., 1988. The human pattern of gyrification in the cerebral cortex. *Anatomy and Embryology* 179, 173–179.