

## Evaluation of Intra-osseous Stability of Immediately Placed Implants into Infected Alveolar Socket

Niraj Mishra<sup>1</sup>, Bhaskar Agrawal<sup>2</sup>, Kamleshwar Singh<sup>1</sup>, Abhinav Shekhar<sup>4</sup>

<sup>1</sup>Dr Bhaskar Agarwal, <sup>2</sup>Kaushal Kishor Agrawal, <sup>3</sup>Gulam Sarwar Hashmi,

<sup>1</sup>Assistant Professor Department of Prosthodontics King George's Medical University

<sup>1</sup>Associate Professor, Department of Prosthodontics, King George's Medical University. Lucknow, U.P., India

<sup>2</sup>Assistant Professor, Department of Prosthodontics, King George's Medical University. Lucknow, U.P., India

<sup>3</sup>Professor, Department of Prosthodontics, Faculty of Dental Sciences, Aligarh Muslim University, Aligarh, U.P., India

<sup>4</sup>Department of Prosthodontics instead of Department of Oral & Maxillofacial Surgery (It should be Department of Oral & Maxillofacial Surgery

---

### Abstract

**Purpose:** To describe a protocol for the immediate placement of implant into infected alveolar socket.

**Materials & Method:** A total number of 40 implants were placed immediately into extraction socket. The periapical conditions were different in all the cases (acute, endodontic and periodontal infection). Great care has been taken in debridement of the socket and extraction of tooth/teeth, guided bone regeneration along with the use of preoperative & postoperative anti-microbial agent.

**Results:** All implants but three were osteo-integrated in six months to one year. Complications were related to the extraction process and bone regeneration process.

**Conclusion:** Predisposing factors for failures are incomplete debridement of the socket, poor oral hygiene, incomplete closure of the wound, systemic factors like hormones. With this study we may conclude that an experienced maxillofacial surgeon may consider immediate implants as a viable treatment option for the patient having periapical infections.

**Keywords:** Periapical pathology, Alveolar socket, Dental implants

---

### I. Introduction

Immediate implant placement at a site with infection is often deferred or avoided due to fear of failure. Recent comparative studies conclude that similar success rates have been reported for implants placed into infected sites compared to implants placed in non-infected sites.<sup>1</sup> Studies suggest that the presence of chronic infection, periapical or periodontal, does not modify osseointegration.<sup>2</sup> The placement of immediate implants represents an alternative to compromised teeth involved with infectious conditions. Nevertheless, evidence arising from the treatment of vertebral osteomyelitis in orthopedic surgery suggests that this might be a misconception. Subacute bone infection in vertebral osteomyelitis can be successfully managed by meticulous bone debridement and antibiotic therapy combined with titanium mesh cages that provide immediate support and stability for the weakened vertebrae.<sup>3,4</sup> Despite the preceding significant infectious state, these titanium cages were reported to achieve radiographic bone fusion, which is the orthopedic equivalent of osseointegration in implant dentistry. Alveolar ridge resorption after tooth extraction may considerably reduce the residual bone volume and compromise the favorable positioning of implants required for optimal restoration.<sup>5</sup> Following the correct clinical indications the immediate placement of the implants into the extraction sockets avoids this undesirable resorption.<sup>6,7</sup> Additional benefits, which are also valued by patients, are the avoidance of a second surgical intervention and the reduction in rehabilitation treatment time. Considering that immediate implants may be placed into infected sockets, this paper describes the procedure and evaluates marginal bone loss and intra-osseous stability of immediately placed implants into infected alveolar socket.

### II. Materials And Method

A total of 40 implants were immediately placed in the infected socket. Informed consent and pre operative preparation was done in all the patients and follow up of 6 – 12 month was recorded. Medical university protocols for immediate placement of dental implant were –

- I. Tab Clavum (Amoxicillin and Clavulonic acid) 625 mg TDS was given for three days before operation and next five days after operation given orally.

- II. Extraction was done with minimum trauma / with the help of drill, endodontic file without any damage to the buccal cortical plates. Removal of the pathology was performed with small size currette.
- III. Preparation of socket was done by sequential drilling that is extended up to 3 – 5 mm beyond the root apex.
- IV. After placement of the implant residual alveolar defect was filled with either Bio-oss or bone harvested from adjacent site (same site inter-radicular or buccal or lingual cortical plates).
- V. Platelet rich plasma was used in all cases.
- VI. Dexamethasone was used in acute cases (doses were 16 mg i.v. stat followed by 8 mg i.v. eight hourly for two days)
- VII. Defect was closed with proper suturing of the flap, in some of the cases membrane was used for guided bone regeneration, and in some cases flap was advanced for proper closure.

### III. Results

The present study was carried out to evaluate placement of implants in infected alveolar socket. A total 40 cases of immediate implantation were done by the pre-decided treatment protocol. Observation were made post operatively on 1<sup>st</sup> day, and 1<sup>st</sup>, 3<sup>rd</sup>, 6<sup>th</sup> & 12<sup>th</sup> week for pre designed clinical parameter like pain, swelling, stability, gingival status, mean probing depth, peri-implant radiolucency & marginal bone loss. All implants except one were osteointegrated, one implant placed in posterior maxilla was became mobile after four months of use. Implants were placed both in the maxilla and mandible.

It was observed that the marginal bone loss was absent at 1<sup>st</sup> day and 1<sup>st</sup> week in all patients and bone loss was present in 4 patient (40%) after 3<sup>rd</sup>, 6<sup>th</sup> and 12<sup>th</sup> week. Marginal bone loss reduces with time but non-significant (Table 1). Stability was present in all patients (100%) at 1<sup>st</sup> day, 1<sup>st</sup> week and 3<sup>rd</sup> week. After 6<sup>th</sup> week, stability was absent in four patients (10%). There was no significant difference in stability with time (Table 2).

### IV. Discussion

Immediate implant placement of dental implants into fresh extraction sockets was shown to be a predictable and successful procedure when proper protocols were followed. Placement into infected sites has been considered a relative contraindication. Literature suggests that periapical pathology may be a cause of implant failure.<sup>8,9,10</sup> So, most of the surgeon hesitates in placing the implants at infected sites and infection has become a relative contraindication for immediate implantation. Aiming to reduce the process of alveolar bone resorption and treatment time, the immediate placement of endosseous implants into extraction sockets has been propagated by some authors.<sup>11,12</sup> However, few clinical data are available on immediate implant placement in chronic periapical infected sites. Clinical reports have suggested that history of periodontal or endodontic infections is a predictive marker for implant infection and failure.<sup>13-16</sup> Thus, some authors<sup>17,18</sup> contraindicate the placement of immediate implants in the presence of periodontal or periapical lesions.

On the other hand, Novaes Jr. and Novaes<sup>19</sup> stated that the placement of immediate implants in chronically infected sites may not be necessarily contraindicated if appropriate clinical procedures like antibiotic administration, meticulous cleaning, and alveolar debridement are performed before implant surgical procedure. Recently, Lindeboom et al.<sup>20</sup> carried out a prospective and randomized study of 50 patients aiming to evaluate the clinical success of immediate implants in periapical infected sites. The results showed a success rate of 92% for the immediate implants and 100% for the delayed implants (placed 3 months post-extraction). Those authors concluded that immediate placement of single tooth implants for replacement of teeth with periapical lesions is a predictable treatment and can be indicated.

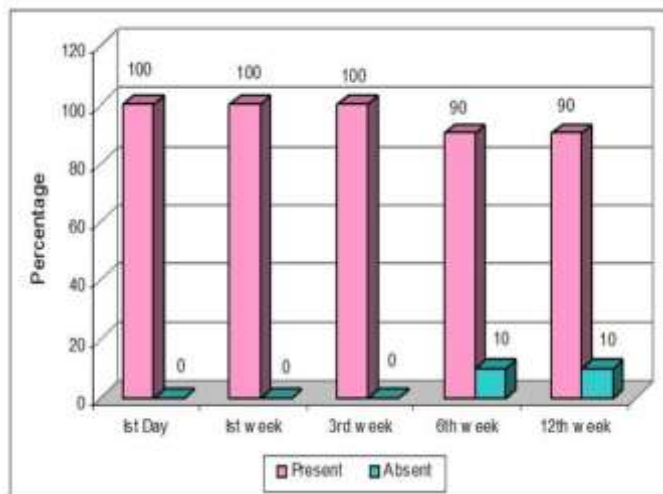
In this clinical study, we have performed the placement of immediate implant in the infected sites with our own designed university protocol. Consideration of preoperative antibiotics for the placement of the implant, is a vital tool for the reduction of infection.<sup>21</sup> In the cases of acute infection apart from antibiotics we have also added dexamethasone, debridement along with PRP and Bio-oss and in some cases we have also added guided bone regeneration to facilitate the healing in infected socket. This procedure is similar to the treatment of plaque induced peri-implantitis where bone regeneration is expected after removal of plaque with placement of membrane. This study suggests a favorable outcome of immediately placed implants in infected socket, if proper protocol is followed.

We advocate the placement of immediate implants into the infected sites but the protocol should be religiously followed. The supervision of experienced maxillofacial surgeon is utmost important (who can advice regarding the pathology and outcome). Our experience suggests that success is proportional to the adherence with the protocol but a long term study with bigger sample size is warranted for authentication of this protocol and procedure.

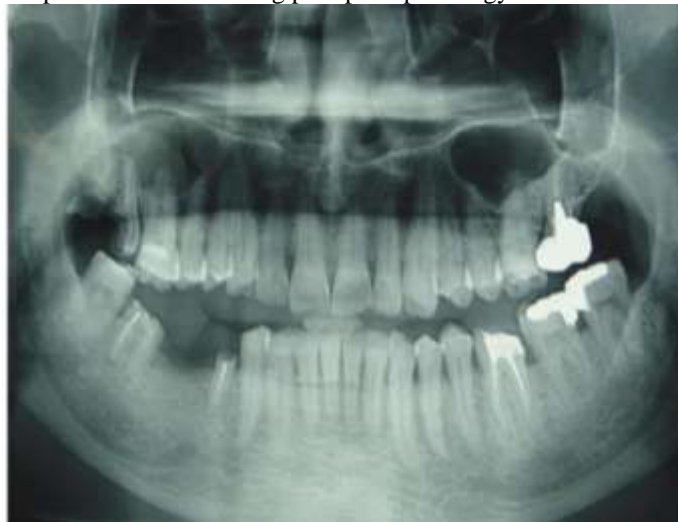### V. Figures And Tables

**Figures**

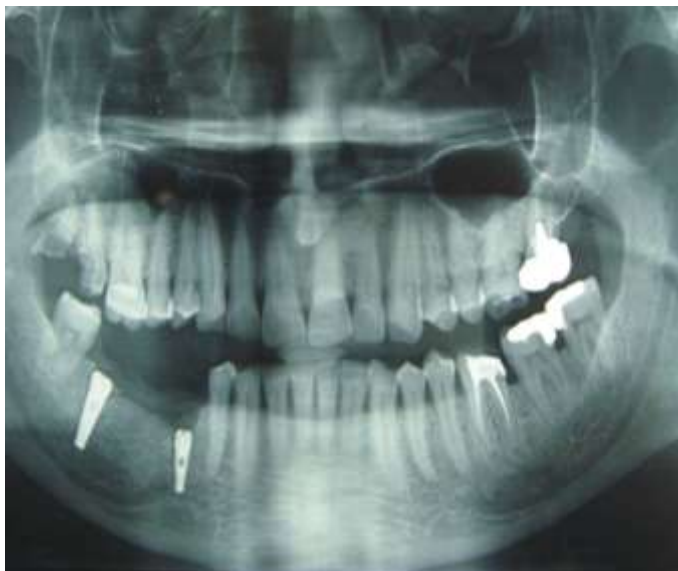**Figure 1.** Graphic presentation of Implant Stability



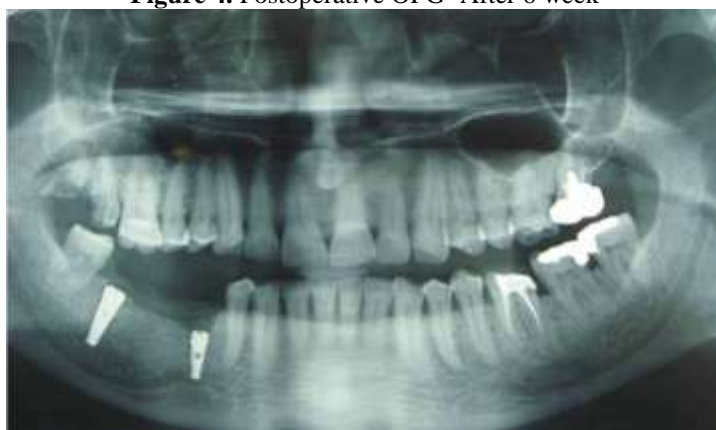**Figure 2.** Preoperative OPG showing periapical pathology in relation to tooth no. 47



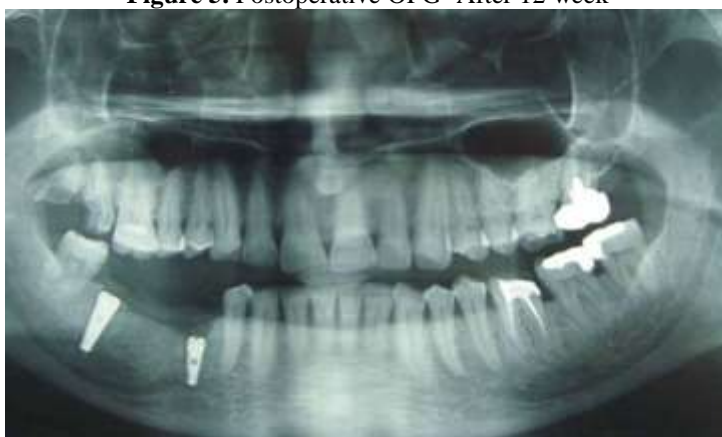**Figure 3.** Postoperative OPG- After 1 week



**Figure 4.** Postoperative OPG- After 6 week



**Figure 5.** Postoperative OPG- After 12 week



**Tables**

**Table -1** Marginal bone loss

	1 <sup>st</sup> Day		1 <sup>st</sup> week		3 <sup>rd</sup> week		6 <sup>th</sup> week		12 <sup>th</sup> week	
	N	%	N	%	N	%	N	%	N	%
Present	–	–	–	–	04	10.00	04	10.00	04	10.00
Absent	40	100.00	40	100.00	36	90.00	36	90.00	36	90.00
<b>Total</b>	<b>40</b>	<b>100.00</b>	<b>40</b>	<b>100.00</b>	<b>40</b>	<b>100.00</b>	<b>40</b>	<b>100.00</b>	<b>40</b>	<b>100.00</b>

$\chi^2 = 0.99$  'p' = 0.91 (NS)

**Table -2 Implant Stability**

	1 <sup>st</sup> Day		1 <sup>st</sup> week		3 <sup>rd</sup> week		6 <sup>th</sup> week		12 <sup>th</sup> week	
	N	%	N	%	N	%	N	%	N	%
Present	40	100.00	40	100.00	40	100.00	36	90.00	36	90.00
Absent	–	–	–	–	–	–	04	10.00	04	10.00
<b>Total</b>	<b>40</b>	<b>100.00</b>	<b>40</b>	<b>100.00</b>	<b>40</b>	<b>100.00</b>	<b>40</b>	<b>100.00</b>	<b>40</b>	<b>100.00</b>

$$\chi^2 = 3.13 \quad 'p' = 0.54 \text{ (NS)}$$

## VI. Conclusion

Immediate implants became a viable option to maintain the periodontal architecture because of their anatomic compatibility with the dental socket and the possibility of eliminating local contamination. Evidence suggests implants can be placed into sites with periapical and periodontal infections. The sites must be thoroughly debrided prior to placement. This study considered the possibility that implants could be inserted into thoroughly debrided, infected extraction sockets under an appropriate antibiotic regime. All implants placed in this study (except one, it was placed in posterior maxilla and it became mobile after four months of use) were osteointegrated,. Marginal bone loss was reduced with time but non-significant. It can therefore be concluded that when utilizing the protocol outlined, implants can be placed into extraction sockets previously associated with subacute or chronic infections of periodontal and endodontic origin.

## References

- [1]. Waasdorp JA, Evian CI, Mandracchia M (2010) Immediate placement of implants into infected sites: A systematic review of the literature. *J Periodontol* 81:801-8.
- [2]. Crespi R, Capparè P, Gherlone E (2010) Fresh-socket implants in periapical infected sites in humans. *J Periodontol* 81:378-83.
- [3]. Hee HT, Majd ME, Holt RT, Pienkowski D (2002) Better treatment of vertebral osteomyelitis using posterior stabilization and titanium mesh cages. *J Spinal Disord Tech* 15:149-156.
- [4]. Liljenqvist U, Lerner T, Bullmann V, Hackenbrg L, Halm H, Winkelmann W (2003) Titanium cages in the surgical treatment of severe vertebral osteomyelitis. *Eur Spine* 12:606-612.
- [5]. Kan JY, Shiotsu G, Rungcharassaeng K, Lozada, JL (2000) Maintaining and attenuating periodontal tissues for aesthetic implant placement. *J Oral Implantol* 26:35-41.
- [6]. Schropp L, Kostopoulos L (2003) Wenzel A. Bone healing following immediate versus delayed placement of titanium implants into extraction sockets: a prospective clinical study. *Int J Oral Maxillofac Implants* 18:189-199.
- [7]. Werbitz MJ, Goldberg PV (1992) The immediate implant: bone preservation and bone regeneration. *Int J Periodontics Restorative Dent* 12:206-217.
- [8]. Bartee BK (2001) Extraction site reconstruction for alveolar ridge preservation. Part 1: Rationale and materials selection. *J Oral Implantol* 27,187.
- [9]. Yang J, Lee HM, Vernino A (2000) Ridge preservation of dentition with severe periodontitis. *Compend Contin Educ Dent* 21,579.
- [10]. Kan JY, Shiotsu G, Rungcharassaeng K, et al (2000) Maintaining and attenuating periodontal tissues for aesthetic implant placement. *J Oral Implantol* 26,35.
- [11]. Lazzara RJ (1989) Immediate implant placement into extraction sites: surgical and restorative advantages. *Int J Periodontics Restorative Dent* 9:332-343.
- [12]. Öhrnell LO (1988) Hirsch JM, Ericsson I, Brånemark PI. Single-tooth rehabilitation using osseointegration. A modified surgical and prosthodontic approach. *Quintessence Int* 19:871-876.
- [13]. Yangco L, Sheridan PJ (2000) Development and treatment of retrograde peri-implantitis involving a site with a history of failed endodontic and apicoectomy procedures: a series of reports. *Int J Oral Maxillofac Implants* 16:412-417.
- [14]. h TJ, Yoon J, Wang H (2003) Management of the implant periapical lesion: a case report. *Implant Dent* 12:41-46.
- [15]. Karoussis IK, Salvi GE, Heitz-Mayfield LJ, Brägger U, Hämmerle CH, Lang NP (2003) Long-term implant prognosis in patients with and without a history of chronic periodontitis: a 10-year prospective cohort study of the ITI Dental Implant System. *Clin Oral Implants Res* 14:329-339.
- [16]. Polizzi G, Grunder U, Goené R, Hatano N, Henry P, Jackson WJ, et al. (2000) Immediate and delayed implant placement into extraction sockets: a 5-year report. *Clin Implant Dent Relat Res* 2:93-99.
- [17]. Becker W, Becker BE (1990) Guided tissue regeneration for implants placed into extraction sockets and for implant dehiscences: surgical techniques and case report. *Int J Periodontics Restorative Dent* 10:376-391.
- [18]. Barzilay I (1993) Immediate implants: their current status. *Int J Prosthodont* 6:169-175.
- [19]. Novaes AB Jr, Vidigal GM Jr, Novaes AB, Grisi MF, Polloni S, Rosa A (1998) Immediate implants placed into infected sites: a histomorphometric study in dogs. *Int J Oral Maxillofac Implants* 13:422-427.
- [20]. L indeboom JAH, Tijjook Y, Kroon FHM. (2006) Immediate placement of implants in periapical infected sites: a prospective randomized study in 50 patients. *Oral Surg Oral Med Oral Pathol Oral Radiol Endod* 101:705-710.
- [21]. Schropp L, Kostopoulos L, Wenzel A (2003) Bone healing following immediate vs delayed placement of titanium implants into extraction sockets: A prospective clinical study. *Int J Oral Maxillofac Implants* 18,189.