

## A Neurocognitive Approach to the Study of Private Speech

Dolors Girbau

Universitat de Jaume I, Spain

The paper presents the current state of the art of research identifying the neurophysiological and neuroanatomical substrates of private speech, both in typical and clinical (or atypical) populations. First, it briefly describes the evolution of private speech research, which goes from classic traditions as the naturalistic and referential paradigms to the neurocognitive approach. An overview of the neurophysiological (e.g., event-related potentials or ERPs) and neuroimaging techniques (e.g., functional magnetic resonance imaging or fMRI) is also presented. The next three sections review empirical works about the neurocognitive basis of private speech, across three groups of techniques: ERPs; fMRI/MRI; and other neuroimaging techniques (positron emission tomography [PET], magnetoencephalogram [MEG], and repetitive transcranial magnetic stimulation [rTMS]). Such neurocognitive research analyzes the neural activity of individuals during a variety of task settings, including spontaneous and instructed overt and inner private speech use, subvocal verbalizations, and silent and overt reading. The fifth section focuses on electrophysiological and neuroimaging studies of private speech in atypical populations, for example: schizophrenia, pure alexia, hearing impairment, blindness, social phobia, alexithymia, Parkinson, and multiple sclerosis. The neurocognitive study of the various forms of private speech appears to be very promising in the understanding of these pathologies. Lastly, the advances and new challenges in the field are discussed.

*Keywords:* private speech, neurocognition, neurolinguistics, psychopathologies, language disorders

Este trabajo presenta el estado actual de la investigación que identifica los sustratos neurofisiológicos y neuroanatómicos del lenguaje privado, tanto en poblaciones típicas como en clínicas (o atípicas). Primero describe brevemente la evolución de la investigación del lenguaje privado, que van desde las tradiciones clásicas como los paradigmas naturalistas y referenciales al abordaje neurocognitivo. También se presenta una revisión de las técnicas neurofisiológicas (por ejemplo, potenciales relacionados con eventos o ERPs) y de neuroimagen (por ejemplo, imagen de resonancia magnética funcional o fMRI). Las siguientes tres secciones revisan los trabajos empíricos sobre la base neurocognitiva del lenguaje privado a través de tres grupos de técnicas: ERPs; fMRI/MRI; y otras técnicas de neuroimagen (tomografía de emisión de positrones [PET], magnetoencefalograma [MEG] y la estimulación magnética repetitiva transcraneal [rTMS]). Esta investigación neurocognitiva analiza la actividad neuronal de los individuos durante diversas tareas, incluyendo el uso del lenguaje privado espontáneo y observable bajo instrucciones y el lenguaje privado interno, las verbalizaciones subvocales y la lectura silenciosa y observable. La quinta sección se centra en los estudios electrofisiológicos y de neuroimágenes del lenguaje privado en poblaciones atípicas, por ejemplo, esquizofrenia, alexia pura, hipoacusia, ceguera, fobia social, alexithymia, Parkinson, y esclerosis múltiple. El estudio neurocognitivo de varias formas del lenguaje privado parece muy prometedor para la comprensión de estas patologías. Por último, se comentan los avances y los nuevos retos en el campo.

*Palabras clave:* lenguaje privado, neurocognición, neurolingüística, psicopatologías, trastornos del lenguaje

---

This study was funded by a grant from the Ministerio de Sanidad y Consumo of Spain, Instituto Carlos III, PI041733 (D. Girbau, P.I.).

Correspondence concerning this article should be addressed to Dolors Girbau, Departamento de Psicología Básica, Clínica y Biológica, Universitat de Jaume I, Campus Riu Sec, 12071 Castelló, Spain. E-mail: girbau@psb.uji.es.

The present paper reviews the new directions on private speech research within a neurocognitive framework. This subject poses a challenge to scientists, especially due to the features of this type of speech. Traditionally, private speech has mostly been investigated from the naturalistic and referential paradigms; these two perspectives are briefly reviewed in the first section. Later on, the neurocognitive approach arose, incorporating new directions in this research topic, thanks to the use of techniques as event-related brain potentials (ERPs) and functional magnetic resonance imaging (fMRI), which are also explained in the introductory section.

The following three sections present the current state of the art of research, identifying the neurophysiological and neuroanatomical substrata of various types of private speech. This review is based on empirical works that have analyzed private speech by using ERPs, fMRI and other neuroimaging techniques (e.g., positron emission tomography or PET). The fifth section focuses on the neurocognition of private speech within a range of different atypical populations from a clinical approach. Finally, the advances and limitations of the studies, besides new challenges and trends in the field, are discussed.

### New Directions on Private Speech: From Classic Paradigms to the Neurocognitive Approach

Research about private speech has been carried out from different approaches across a century. This long tradition goes from the behavioral (Watson, 1919/1983) and developmental classic approaches (Piaget, 1923/1968; Vygotsky, 1934/1987) to the current cognitive and neurobiological studies. There have been two classic paradigms in research about private speech: naturalistic (or sociolinguistic), and referential. From the naturalistic approach, private speech is analyzed through an observational method in natural contexts. Conversely, the referential communication is usually based on experiments with referential tasks in laboratory settings. The naturalistic paradigm contributed to the advance of our knowledge about children's private speech, mostly within the age range from 4 to 8 years old (Diaz & Berk, 1992; Zivin, 1979). The ages of study are now progressively expanding towards older populations (cf. Duncan & Cheyne, 2001; Girbau, 2002a). Also, more types of context and clinical populations have been included, for example, hearing impairment (e.g., Kelman, 2001), sports (e.g., Papaioannou, Ballon, Theodorakis, & Vanden, 2004), etc.

Our research group has analyzed private speech in older children, from referential settings to naturalistic social contexts, and has incorporated new sequential methods for data analysis (Girbau, 2001, 2002b, 2002c; Girbau & Boada, 1996). We have also developed bridges between both traditions (referential and naturalistic) (Girbau, 1997; Girbau & Boada, 2004). Finally, our theoretical critique of

misleading interpretations of Vygotsky's concepts about private and inner speech needs to be considered (Girbau, 1996). In this later paper, private speech is defined as an emission that is neither addressed nor adapted to the decoder (that is, the receiver in communication), unlike social speech which is addressed to the decoder and can be adapted (reaching the intended public meaning) or not adapted (private meaning) to this decoder. From a naturalistic paradigm, we have analyzed several forms of private speech through category systems that include silent (inner speech), inaudible (in a very low voice), and audible categories.

Simultaneously to the advance of these classic paradigms, the neurocognitive approach to the field has arisen as a promising new source of knowledge not only for the study of private speech but for psycholinguistics in general. This more recent tradition has analyzed the neurobiological bases of the three cited forms of private speech, from which inner speech has been the one most studied.

In fact, over the last decade, psycholinguistics has experienced an increase of multidisciplinary research involving not only electrophysiology and neuroimaging techniques but also genetic analyses (Girbau, 2004). Particularly, human cognitive processes can be better understood thanks to the brain activation studies that are benefiting from these valuable techniques, which are accompanied by some behavioral measures. During the time-course of private speech, a wide range of neuroanatomical networks is activated and it is not easy to explore specific neural processes. One example is research about inner speech (defined as speech without external vocalization), which is required during execution of different psycholinguistic tasks, such as the ones involving phonological memory, silent reading, and linguistic judgments. Thus, to isolate the activity for inner speech, different experiments have been developed.

The psychophysiology of language is advancing thanks to various neurophysiological and imaging techniques (Brown & Hagoort, 1999; Kutas, Federmeier, Coulson, King, & Münte, 2000). Among the techniques that are being used, we can mention the following: ERPs, magnetic resonance imaging (MRI), fMRI, single photon emission computed tomography (SPECT), PET, magnetoencephalogram (MEG), repetitive transcranial magnetic stimulation (rTMS), etc. Particularly, ERPs show how this brain language processing unfolds over time. Techniques such as MRI, fMRI, and PET can help to pinpoint areas of the brain important for private speech. They have high spatial resolution, which contrasts with the high temporal resolution of ERPs. For example, fMRI allows assessing the brain areas activated while the individual is performing a task or perceiving a stimulus, without exposing the patient to radiation. This brain activity is measured through the blood oxygenation level-dependent (BOLD) endogenous contrast agent (see Logothetis, 2003, for more details). However, PET and SPECT require a radioactive marker administration. The advantages and main features of these techniques will be discussed here.

### *Event-Related Brain Potentials*

The register of ERPs has been used not only for the study of language (cf. Garnsey, 1993), but particularly as an on-line neurophysiological measure of private speech processing unfolding over time. ERPs are measures of electrical activity in the brain obtained using electrodes placed on the scalp. A standard method for placement of electrodes was defined first by Jasper (1958) on what was known as the *International 10-20 electrode system*, in order to enable a comparison of studies from different laboratories. Since then, some modifications to this 10/20 system have been introduced for its use with infants and small children, and also by increasing the number of electrodes from 21 up to 74 in the *10% system* (Chatrian, Lettich, & Nelson, 1985) and even for larger amounts. An example of these schematic diagrams of a human head with some electrode locations is shown in Figure 1.

ERPs can be obtained throughout the presentation of different types of stimuli (such as words or sentences), that are listened to and/or read by a person. Sometimes the task requires the participant to make a decision (e.g., word/non-word), which is also analyzed by recording reaction time

and response accuracy. However, along with the electrical activity due to the brain's processing of the experimental stimuli, activity from other sources, especially the so-called artifacts, is recorded. The most problematic noise sources for ERPs are eye movements and muscle activity in the head and neck. The number of those artifacts increases in children and they become more problematic when designing certain experiments about private speech.

Data analyses of ERPs are complex. There is a great variety in the types of measures and analyses used across the literature. An ERP waveform consists of a series of positive and negative peaks that occur in characteristic patterns for specific types of stimuli and tasks. The two basic measures for ERPs are latency and amplitude of peaks. Conventionally, the peaks are named "N" and "P" to indicate negative and positive polarity. However, there are two ways of naming peaks: (a) including the latency of the peak with respect to its eliciting event (e.g., P300, which is a positive peak with a peak latency of 300 milliseconds), and (b) naming the ordinal position of the peak in the waveform (e.g., N1, which is the first negative peak). ERP recordings offer complementary information to fMRI research.

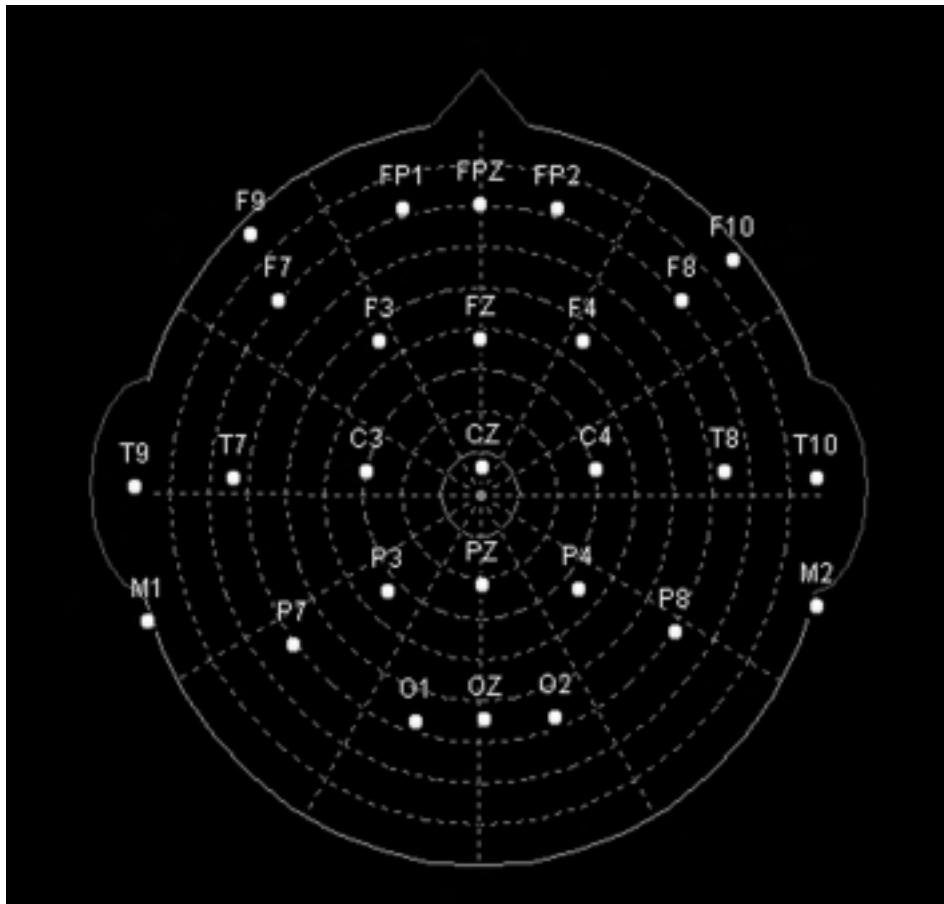


Figure 1. Schematic diagram of an example of a human head with some electrode locations indicated.

### *Magnetic Resonance Imaging and other Neuroimaging Techniques*

There are several imaging techniques currently available for investigation of neurocognitive mechanisms and for the diagnosis and treatment of diseases (Hirsch, 2003). MRI is an anatomical imaging technique that is used to observe brain structures. The discovery that MRI can map changes in brain hemodynamics that correspond to cognitive processes (e.g., related to a specific task) allowed, later on, inclusion of maps of human brain functions. This more recent technique is what is known as fMRI. Together, MRI and fMRI, by analyzing the structures and which of them seem to participate in specific functions, provide high resolution information including neural activity detected by a blood oxygenation level-dependent (BOLD) signal. Functional MRI is based on the increase in blood flow to the local vasculature that accompanies the brain's neural activity. This ability to directly observe brain functions opens a window to advance our understanding of brain organization and cognitive processes.

However, this line of research is not free from challenges (see for example, Jezzard, Matthews, & Smith, 2002). One source of variability is head motion during fMRI acquisition, which can pepper activation maps with Type I statistical errors (Petrovich et al., 2005). In the study of private speech, head motion may be minimized using fMRI paradigms in which the patient responds silently (covertly) rather than aloud (overtly). On the other hand, the particular imaging methods and procedures vary between research groups because they have independently developed the methods and analysis procedures required to acquire and process functional data. Progressively, the quality of the magnets is improving, and it is moving from 1.5 Teslas to 3 or even more (with better image resolution and shorter scanning time).

Functional MRI has advantages over other methods such as the earlier PET. Functional images obtained by PET require injections of radioactive isotopes, multiple acquisitions, and, therefore, extended imaging times. In contrast, fMRI does not require the administration of a radioactive marker and the total scan time required can be shorter. However, ERP recordings offer higher temporal resolution, as they measure the brain's immediate electrical response to the stimulus; in fMRI, the BOLD signal changes begin after 2 seconds of the stimulus presentation (e.g., Savoy, 2005). To overcome the independent difficulties of each technique, scientists are beginning to face the challenge of applying both fMRI and ERPs simultaneously in adults. All these techniques have been used separately to analyze private speech in typically developing and clinical populations.

#### The Study of Private Speech through Event-Related Brain Potentials

ERP technique has been used less frequently than other research tools to analyze the neurocognition of private

speech. There is a variation in the number of scalp electrodes that have been included across ERPs studies, but the trend is to increase it. Some of them have used electrodes monitoring throat movements. One of their main interests has been silent speech processing in adulthood.

For example, an ERP study used a discrimination task of pairs of sentences with different emotive prosody, to which adults listened either (a) silently or (b) by repeating them using inner speech after being trained not to perform any muscular or articulatory movement (Pihan, Altenmüller, Hertrich, & Ackermann, 2000). These two tasks (with/without inner speech) were run through Neuroscan equipment, using 26 scalp electrodes, in right-handed 19-34-year-old university students of both genders. Results revealed that their cortical activity differed across the two experimental settings. Particularly, a pronounced activation of right frontal regions was found in the experiment without inner speech (with only perceptive communicative demands). However, in the task with inner speech (involving perceptive and verbal-expressive communicative demands), the adults showed bilateral activation with left frontal predominance. The activation of this left area relates inner speech to the *articulatory loop*, which has two components: (a) a phonological short-term store and (b) an articulatory subvocal rehearsal system that refreshes this phonological representation, which otherwise would decay over a period of about two seconds (Baddeley, 2002).

Previously, another study also compared silent inner speech versus no inner speech, by recording ERPs at similar ages in 18-39-year-old right-handed men (Fujimaki, Takeuchi, Kobayashi, Kuriki, & Hasuo, 1994). Here, the experiments involved the silent speaking of the vowel /a/ (speaking mentally after instructions to suppress mouth and throat movement). ERPs with and without silent speech differed significantly in latencies of 360 to 690 msec and in shorter time intervals. A significant difference between both conditions was found in the occipital area (P300) and in the frontal area (N420). Alpha wave measures for silent speech (saying the vowel /a/ mentally, without vocalization) had smaller amplitude than without silent speech, and beta waves were more attenuated with silent speech. However, the authors recognized the difficulty of checking whether the participant actually produced silent speech (silent-speech condition) and/or said something silently despite being instructed not to do so (nonsilent-speech condition).

This work was expanded later (Fujimaki, Kuriki, Nakajima, Konychev, & Musha, 1997) in another research by comparing three speech tasks through ERPs: (a) silently speaking a word, (b) silently speaking a vowel, and (c) withholding silent speech (without silent speech). This report was based on a sample of 6 right-handed 20-36-year-old males. The main differences between average ERPs in silent speech of a vowel and a word (after subtracting those without silent speech) were found at the parietal area (P400), and especially the frontal region (N580). This supported the idea that the frontal negative difference may be related to motor planning for speech output.

In experiments of silent counting with ERPs (this procedure was also used with fMRI, e.g., Clark, Fannon, Lai, & Benson, 2001), it was concluded that subvocal rehearsal and the contents of working memory can be controlled by top-down processing (Gehring, Bryck, Jonides, Albin, & Badre, 2003). Other authors compared the localization results, including a similar task, that were obtained in two reports (Yamazaki et al., 2000; Yamazaki, Kamijo, Kiyuna, Takaki, & Kuroiwa, 2001). It was found that both silent counting and button-pressing tasks were located mainly at the frontal cortices, the hippocampal region, and the thalamus (for P300 dipoles).

Memory processes mediated by subvocalizations were also analyzed by considering the stimulus modality (auditory vs. visual), during the performance of verbal and non-verbal short-term memory tasks (Lang, Starr, Lang, & Lindinger, 1992). The authors found negative direct current potential shifts in some brain areas, which were affected by adults' cognitive strategies (e.g., some of them used subvocal auditory rehearsal in the visual task, some others used visual images in the auditory task, etc.).

As this section shows, the study of private speech with the use of the ERP technique has been focused on adult population. More scientific investigation is needed focusing on children's private speech through ERPs to better understand the psychophysiology of these processes across the age.

### Research on Private Speech and Magnetic Resonance Imaging

Basically, neuroimaging experiments of fMRI about private speech have been programmed in either a block or an event-related (more complex) design. One of the few event-related fMRI studies, without acoustic scanner noise, analyzed the brain activity that characterizes inner speech, in 21-29-year-old adults (MacSweeney et al., 2000). The authors concluded that silent speech-reading activates similar areas of the auditory cortex as listening to speech.

In fact, the regions that generate and perceive inner speech in the frontal and temporal cortex, respectively, interact in a way that allows monitoring one's verbal thoughts (Shergill et al., 2002). Specifically, fMRI was performed as males (aged 23-37 years) covertly generated the word "rest" repeatedly without speaking (covert articulation), once every 1, 2, or 4 seconds. Results showed that the faster rate was associated with activation in the left inferior frontal gyrus, the right pre- and postcentral gyri, and both superior temporal gyri. Temporal cortical activation was associated with increasing the rate of covert articulation, in the absence of external auditory input. Findings suggested that there is a fronto-temporal connectivity. Another fMRI work, with 6 adults using subvocal rehearsal, found significant left hemisphere activation in the inferior and middle frontal gyri

and inferior parietal gyrus (Logie, Venneri, della Sala, Redpath, & Marshall, 2003). Thus, the presence of subvocal rehearsal processes can cause a hemispheric lateralization, as it was found with other tasks as well (Gruber, Kleinschmidt, Binkofski, Steinmetz, & von Cramon, 2000).

Verbal working-memory was also investigated using fMRI to better understand the activation of the cerebellum (Desmond, Gabrieli, Wagner, Ginier, & Glover, 1997). In this work, a sample of 9 adults performed a working-memory task (in which they had to remember 1 or 6 visually presented letters) and a motor rehearsal task (they read subvocally 1 or 6 letters). During the two tasks, the activation increased for the 6-letter condition relative to the 1-letter one, in bilateral areas of the superior cerebellar hemispheres and part of the posterior vermis.

The right cerebellar hemisphere was also activated during "automatic speech" (Ackermann, Wildgruber, Daum, & Grodd, 1998). In this fMRI study, 18 adults said, repeatedly and silently, the names of the 12 months. Another report, using fMRI, concluded that the activation of the right cerebellum was related to areas such as the supplementary motor area (SMA), during both inner speech and auditory verbal imagery tasks in eight 26-37-year-old male adults (Shergill et al., 2001).

Other fMRI research has analyzed the relationship between subvocalization and activity in SMA located in the frontal lobe (e.g., Kawashima et al., 2000). This was tested by some authors using a timbre imagery task with fMRI (Halpern, Zatorre, Bouffard, & Johnson, 2004). Timbre refers to the sound quality of different musical instruments or voices. This study was performed with 10 healthy right-handed adults (mean age 24.3 years, 5 of each sex). All of them had had a minimum of 5 years of formal musical training and were able to generate auditory images. Each one participated in five conditions: silence, noise, visual imagery control, perception (with sounds of 8 musical instruments), and timbre imagery. Every condition involved mainly presentation of a stimulus pair and a response that was then given. The condition of greatest interest was the timbre imagery condition, in which the stimuli were the names of musical instruments, not accompanied by a sound. Here, the participants were asked to imagine the sounds of a pair of instruments named, and to rate the similarity of both on a scale of 1 (*high similarity*) to 5 (*low similarity*). So, generally, participants were scanned while making similarity judgments about the timbre of heard or imagined musical instrument sounds. Both the timbre perceived and imagined conditions activated secondary auditory regions. Interestingly, in the timbre imagery task, some activity in SMA was observed. The authors reported two possible explanations for this: (a) despite the fact that subvocalizing the timbre of an instrument is difficult, the timbre was accompanied by pitch, which itself is easily vocalizable; and (b) SMA may have a more general role in auditory imagery (e.g., image generation or preparation), regardless of any potential subvocal contribution to the image.

In line with some issues of that research, fMRI revealed two complementary cerebral networks subserving singing and speaking, as a new aspect of brain lateralization. Particularly, a series of studies showed the contribution of the insula to motor aspects of speech production (Ackermann & Riecker, 2004; Ackermann et al., 2001; Riecker, Ackermann, Wildgruber, Dogil, & Grodd, 2000). The most recent of these reports (Ackermann & Riecker) is a review concluding that there is now broad functional imaging and clinical evidence for a participation of the left anterior insula in speech motor control. Particularly, it has a relevant role in coordinating the up to 100 muscles that are involved in articulation and phonation. For example, significant blood flow increase at the level of intrasylvian cortex was found in overt tasks (speaking aloud, left anterior insula; singing aloud, right anterior insula). This pattern of insular activation turned out to be preserved after subtraction of the respective hemodynamic responses obtained during the silent modes of speaking and singing (overt vs. covert speech, overt vs. covert singing). Furthermore, a second cognitive subtraction procedure (i.e., singing aloud minus speaking aloud and vice versa) yielded the same double dissociation effect at the level of the anterior insula.

Among the potential clinical applications of fMRI associated with inner speech processes, one of special interest is the presurgical determination of hemispheric language dominance (HLD). Particularly, HLD can be evaluated by analyzing inner speech during visual imagery tasks that are run on fMRI, as HLD indexes for silent speech and for overt speech were found to correlate significantly (Baciu, Rubin, Décorps, & Segebarth, 1999). In this report, 10 healthy, right-handed volunteers (mean age 37 years old) performed two tasks. During the word production task, they were asked to imagine scenes (e.g., office, street, etc.) and to generate the nouns of all objects visualized in these scenes. During the control task, they only attended to the scanner noise. The sequence of speech production and control tasks was repeated five times during two functional scans. Speech production was covert in the first one and overt in the last one. During overt speech, subjects were instructed to articulate softly so as to generate as little movement artifacts as possible. Then, a language lateralization index (LI) was defined as the ratio of the interhemispheric difference (left minus right) of the number of pixels activated in predefined functional areas to the sum of the number of pixels activated in both hemispheres together in these areas (Brodmann areas 6, 9, 10, 39, 40, and 44-47). The number of pixels activated was the averaged result taken from the two identical scans. HLD indexes indicated left hemispheric language dominance for all adults examined. Similar HLD indexes were obtained for overt and covert versions of the paradigm.

Inner speech has also been used in fMRI research to study the way in which the relationship between native and second languages is spatially localized in the human cortex

(Kim, Relkin, Lee, & Hirsch, 1997). Silent, internally expressive linguistic tasks were performed in two languages by 12 adults (aged 23-38 years), who either acquired conversational fluency in their second languages as young adults (6 late bilinguals) or who acquired two languages simultaneously early in their development (6 early bilinguals). Data showed that in the early bilinguals, both languages are represented in common frontal cortical areas. However, in the late bilinguals, both are located separately within Broca's area at the frontal lobe.

Finally, we cannot forget the complexity of data analyses from the present approach of research. There is a continuous effort to improve the fitting models that explain the fMRI data. For example, path analytic models are interesting to many neuroscientists because they can quantify functional relationships between multiple brain regions (in terms of unidirectional connections, etc.). Path analysis of functional imaging data offers an opportunity to test psycholinguistic models empirically, to solve questions such as whether the theoretical model is good enough. Particularly, fMRI data from a semantic decision task were interpreted within a model with connections from frontal to parietal cortex that explained the sequential rehearsal and monitoring processes of the articulatory loop (Bullmore et al., 2000). This study was based on 20 right-handed adults of both genders ( $M = 44.4$  years,  $SD = 14.4$  years), who decided whether the presented word represented a living or nonliving object and subvocally articulated that decision.

#### Research on Private Speech with other Neuroimaging Techniques

As we have seen, fMRI research concentrates the greatest amount of neuroimaging studies on private speech. Only a few works have been reported about the topic using other techniques, some of which are considered invasive. The review will focus here and in the next section on investigations that used PET, MEG, and rTMS.

One of the PET reports (McGuire et al., 1996) investigated the neural correlates between the following tasks and conditions: inner speech (in which participants articulated sentences silently) and auditory verbal imagery (they imagined sentences being spoken to them in another person's voice). The adults were shown single words which they used to generate short, stereotyped sentences without speaking. Inner speech was found to be associated with increased activity in the left inferior frontal gyrus, whereas auditory verbal imagery was related to an increase in the same region, but also in the SMA, the left premotor cortex, and the left temporal cortex. The authors suggested that the silent articulation of sentences involves activity in an area concerned with speech generation, whereas imagining speech is associated with additional activity in regions associated with speech perception.

Sentences were also considered in other experiments about the neural basis for syntactic processing of sentences with relative clauses (Caplan, Alpert, Waters, & Olivieri, 2000). This PET study was based on 11 right-handed monolingual English-speaking men and women with a mean age of 25.8 years (range, 19-35 years). They judged the goodness of sentences presented visually, while they uttered the word “double” aloud. According to the data, processing of complex syntactic sentences, but not subvocal activity, led to an increase in blood flow in Broca’s area.

There are only very few reports that have applied more than one of these neurophysiological and imaging techniques in the same sample of participants (e.g., Fujimaki, Hayakawa, Matani, & Okabe, 2004). This research was based on 8 right-handed male and female Japanese-speakers, with a mean age of 33 years, who participated in both MEG and fMRI experiments with a delayed-response task. The aim was to isolate neural activity during inner speech of meaningless syllable sequences that excluded other phonological processes as well as orthographic, semantic, and syntactic processes. The adults had to decide whether a presented character was included in these sequences, after having been instructed to phonologically memorize them by performing rehearsals (i.e., using inner speech for the memorized syllables). The cited inner speech produced a notorious activity at latencies of 200-300 ms in the right hemisphere (language-nondominant), so that it involved processing of more prosodic characteristics (e.g., pitch) than phonemic ones.

#### Electrophysiological and Neuroimaging Studies of Private Speech in Atypical Populations

We already have a picture of the topic in typically developing adults. Several human disorders and deficits have also been studied by analyzing private speech from a neurocognitive approach: pure alexia, hearing impairment, blindness, social phobia, alexithymia, Parkinson, multiple sclerosis, etc. Applications of the analysis of silent and other types of speech have even been revealed as useful for neurosurgery (Petrovich et al., 2005). However, the greatest amount of research has been focused on patients with a diagnosis of schizophrenia, as it is believed that auditory verbal hallucinations (AVHs) may be due to dysfunctional inner speech-related cortical areas.

Research on the neurocognition of private speech in schizophrenia has been developed through several electrophysiological and neuroimaging measures: ERPs, especially the N1 component (Ford & Mathalon, 2004; Ford, Mathalon, Heinks, et al., 2001; Ford et al., 2001a, 2001b; Ford, Mathalon, Whitfield, Faustman, & Roth, 2002), fMRI (Bentaleb, Beauregard, Liddle, & Stip, 2002; Welchew, Honey, Sharma, Robbins, & Bullmore, 2002), electromyography or EMG (Junginger & Rauscher, 1987), and rTMS.

According to several authors (e.g., Schönfeldt-Lecuona et al., 2004), rTMS should be regarded very cautiously as a potential novel tool to develop treatment strategies for auditory hallucinations. This particular report did not find a reduction of hallucination severity after active stimulation was applied over Broca’s area and over the superior temporal gyrus.

One of the main goals of all these works has been finding the specific neurocognitive bases explaining the generation of AVHs (see David, 1999; Font, Parellada, Fernández-Egea, Bernardo, & Lomeña, 2003; for reviews). AVHs are a cardinal feature of psychosis. According to David, their complex cognitive and neurophysiological bases are on the way to being better understood thanks to research about inner speech using fMRI, PET, SPECT, etc.

The other review (Font et al., 2003) focuses on neuroimaging research of auditory hallucinations. The studies about the phenomenon are classified according to whether they are (a) sensory activation, (b) trait, or (c) state, which involve different designs, thus making it difficult to compare the results. All three types of works compare a group of study (patients with schizophrenia and AVHs or history of AVHs) with control groups, or do a retest in the same group of study once the hallucinatory phenomenon is not present. The studies of state are the most recent ones and analyze how the brain is functioning during the precise moment of the AVH occurrence, based on more accurate techniques (fMRI and PET H<sub>2</sub>O). The two main hypotheses proposed to explain the mechanisms underlying this symptom—external speech versus subvocal or inner speech—and the latest unitary theory are discussed. The reviewers conclude that the auditory hallucinations in schizophrenia appear to be related to a dysfunction of the neuroanatomical networks that are responsible of language production through activation in parallel of the subvocal speech motor areas and the perception areas for external speech (auditory-linguistic cortex).

Ford and collaborators developed a series of experiments in adults to better understand the mechanism that exists in the auditory system, particularly corollary discharges (Ford & Mathalon, 2004; Ford, Mathalon, Heinks et al., 2001; Ford et al., 2001a, 2001b, 2002). A corollary discharge seems to generate the communication between the frontal lobes (where speech and verbal thoughts are generated) and the temporal lobes (where they are heard or perceived). The authors analyzed, through ERPs, whether the neurophysiology of schizophrenia is related to failures of corollary discharge during speech, across different conditions: talking aloud, silence, directed inner speech, listening to one’s own recorded speech, etc. One of their conclusions is that auditory hallucinations can be linked to this dysfunction, which prevents patients from recognizing their own inner speech as self-generated.

For example, in one of these reports (Ford et al., 2001a), they analyzed how auditory cortical responsiveness was affected by inner speech. The ERP experiment was

performed with 15 patients with schizophrenia and 15 controls, aged 20 to 58 years old, and mostly men. For the acoustic stimuli (not for the visual ones), the N100 amplitude (at Fz and Cz scalp sites) was significantly larger during the silent baseline condition than during the self-directed inner speech (when repeating 7 typical hallucinatory statements) only in the control group. The authors interpreted the nonsignificant results for the patients as an indicator of corollary discharge dysfunction that could mislead them to attribute inner speech to an external voice.

As mentioned, other pathologies have been investigated in relation to the neurocognition of private speech. One of the cited clinical populations refers to pure alexia (e.g., Bone, 2002). This diagnosis category is characterized by severely impaired reading skills with relative sparing of all other language skills, including oral word recognition and writing. It is suggested that, in patients with pure alexia, explicit reading activates the right and left hemispheres, but implicit reading only involves the left hemisphere, according to an fMRI study (Bone, 2002). More research is needed to support these recent results.

Profoundly hearing impaired right-handed adults (aged 30-49 years old) were studied through PET (McGuire et al., 1997). All used British sign language (BSL, the sign language used in the United Kingdom) as their major form of communication. The 5 adults either had a congenital hearing loss or were diagnosed at 6 months of age maximum. Participants watched a video monitor which showed a man (fluent in BSL) signing; they had to mentally sign sentences generated by themselves according to a particular structure. During the "inner signing" of sentences, there was activation of the left inferior frontal cortex (instead of the expected visuo-spatial areas), which is also common in hearing individuals who articulate sentences silently. Thus, inner speech and inner signing are activated by the same brain region. The authors concluded that the left inferior frontal cortex seems to participate in the generation of language, whether it is covert or overt, spoken or signed.

Another deficit studied in relation to private speech is blindness. It has been analyzed with fMRI (in a block design) whether the finger movements during Braille reading lead to a cerebellar activation other than the sensory and motor ones in blind adults (Gizewski, Timmann, & Forsting, 2004). This was done in early blind and normal sighted participants. Of 12 blind German-speaking participants (age range, 24-80 years, and 6 of each gender), 9 were congenitally blind and 3 had minimal light perception before becoming blind early in life. None of the blind individuals had residual light perception and all used the right hand to read Braille. The control group was formed by 12 normal sighted right-handed subjects who were not able to read Braille, (7 women and 5 men within an age range of 20-66 years). They volunteered to perform a Braille reading task and other tactile tasks. After the scan, participants had to give a summary of the read text. To avoid nonspecific

activation, subjects were asked not to make any sort of response or to read aloud during the experiment. The most interesting finding was that inner speech led to a cerebellar activation within bilateral *Crus I* area during Braille reading by all blind participants, as also occurred in text reading by normal sighted adults.

Some authors have used audible private speech to better know social phobia correlates (Tillfors, Furmark, Marteinsdottir, & Fredrikson, 2002). In this PET experiment, adults with social phobia had to speak alone while they were scanned in one of the following conditions: before or after speaking in public. Only the former, who spoke alone before, showed an anticipatory anxiety response (e.g., heart rate, etc.) and activation of the left inferior temporal cortex, right dorsolateral prefrontal cortex, and the left amygdaloid-hippocampal area.

## Discussion

There are some challenging methodological limitations in the reviewed studies. The first one is related to the size of the reported samples, which are usually smaller than in behavioral research. This is due to the economical cost and complexity of neurophysiological and neuroimaging techniques and experiments.

Moreover, the recruited samples are usually right-handed adults within a large range of age. Further research is needed not only in left-handed adults but also in children, which would give us a better picture of the neurobiology of private speech and its development. Younger populations are more challenging for this type of research, particularly to get them to follow instructions such as the reduction of physical movement (which creates undesirable artifacts) or to perform long experimental tasks; but it is needed and feasible by training them. The current availability of better equipment (e.g., MRI machines of 3 Teslas or more) is also helping to reduce the time needed for scanning thanks to a better image resolution.

Particularly, from other research approaches, differences between children and adult brain regions are typically reported in terms of the location, magnitude, or volume of brain activity (Casey, 2002; Huttenlocher & Dabholkar, 1997; Schlaggar et al., 2002). As far as we are aware, Dr. Casey and colleagues published the first fMRI study on children around 1995. More research is still needed to better know how general brain activation in children diverges from that of adults, including the production of private speech processes. However, we cannot forget that some of these techniques are considered artificial or invasive, especially the ones that require administering a radioactive marker.

Probably, the most difficult step in this line of research is to design an experiment that will lead to an accurate and reliable measure of inner speech (verbal thoughts), especially in children. In several of the studies, we need to rely on the fact that participants are following experimenter's instructions



regarding the use of inner speech (e.g., repeating a sentence mentally). Although compelling, failures to monitor covert speech (thoughts) are not as amenable to investigation as failures to monitor overt speech (talking). A great effort needs to be devoted to design experiments that elicit different types of private speech. We need to mention that aspects of interest for the study of private speech, such as for example throat movements, cause artifacts when ERPs are recorded, although some external electrodes could be placed there to record them. In several of the referred works, trials contaminated by muscle artifact while talking were excluded. Fortunately, technology is improving to better control for this.

Additionally, there is a diversity of methods for the analyses of electrophysiological records and neuroimages. One example is the use of multidimensional scaling for analyzing fMRI data. This multivariate statistical technique helps to outline subsystems of brain regions that are functionally connected (e.g., Welchew et al., 2002). Thus, there is a progressive advance in the methodological field, though the variety of designs can sometimes make the comparison across studies difficult.

Several works have revealed very promising findings in helping us to understand some pathologies. Once the neurobiological processes that are involved in private speech across different populations is better known, we will be in a position to develop more applications to the field. From a cognitive-behavioral approach, some therapeutic treatments have proved to be efficient in improving the quality of private speech, self-control, etc. It would be very interesting to measure whether these changes are also reflected in the wide range of neuroanatomical networks activated during private speech (which, for example, show a dysfunction in some patients with schizophrenia). Thus, identifying the neurophysiological and neuroanatomical substrata of the various types of private speech throughout typical and atypical populations can open a window to research on therapeutic techniques. The efficiency of these techniques could now also be measured by performing two ERP and/or fMRI studies, before and after a particular treatment in a pretest-posttest design.

In sum, the last decade has experienced a significant advance in research about private speech involving electrophysiology and neuroimaging techniques. The use of this type of equipment is very promising, as their presence is progressively increasing in the laboratory facilities worldwide. We are already familiar with several brain structures and complementary cerebral networks subserving adults' private speech processes, including their dysfunctions underlying the etiopathogenesis in some clinical populations. These techniques start to help us to diagnose and also assess more accurately the efficiency of different therapeutic treatments in some pathologies from other fields (e.g., Small, Flores, & Noll, 1998). More research is still needed to better know how brain activation is involved in the various types of private speech and also its development, across different populations, especially the neurocognition of children's private speech.

## References

- Ackermann, H., & Riecker, A. (2004). The contribution of the insula to motor aspects of speech production: A review and a hypothesis. *Brain & Language, 89*, 320-328.
- Ackermann, H., Riecker, A., Mathiak, K., Erb, M., Grodd, W., & Wildgruber, D. (2001). Rate-dependent activation of a prefrontal-insular-cerebellar network during passive listening to trills of click stimuli: An fMRI study. *Neuroreport: An International Journal for the Rapid Communication of Neuroscience Research, 12*, 4087-4092.
- Ackermann, H., Wildgruber, D., Daum, I., & Grodd, W. (1998). Does the cerebellum contribute to cognitive aspects of speech production? A functional magnetic resonance imaging (fMRI) study in humans. *Neuroscience Letters, 247*, 187-190.
- Baciu, M.V., Rubin, C., Décorps, M.A., & Segebarth, C.M. (1999). fMRI assessment of hemispheric language dominance using a simple inner speech paradigm. *NMR in biomedicine, 12*, 293-298.
- Baddeley, A.D. (2002). Is working memory still working? *European Psychologist, 7*, 85-97.
- Bentaleb, L.A., Beaugard, M., Liddle, P., & Stip, E. (2002). Cerebral activity associated with auditory verbal hallucinations: A functional magnetic resonance imaging case study. *Journal of Psychiatry & Neuroscience, 27*, 110-115.
- Bone, R.B. (2002). Functional neuroimaging of implicit and explicit reading in patients with pure alexia. *Dissertation Abstracts International. Section B: The Sciences & Engineering, 62*, 3793.
- Brown, C.M., & Hagoort, P. (Eds.). (1999). *The neurocognition of language*. Oxford, UK: Oxford University Press.
- Bullmore, E., Horwitz, B., Honey, G., Brammer, M., Williams, S., & Sharma, T. (2000). How good is good enough in path analysis of fMRI data? *NeuroImage, 11*, 289-301.
- Caplan, D., Alpert, N., Waters, G., & Olivieri, A. (2000). Activation of Broca's area by syntactic processing under conditions of concurrent articulation. *Human Brain Mapping, 9*, 65-71.
- Casey, B.J. (2002). Neuroscience. Windows into the human brain. *Science, 296*, 1408-1409.
- Chatrjian, G.E., Lettich, E., & Nelson, P.L. (1985). Ten percent electrode system for topographic studies of spontaneous and evoked EEG activity. *American Journal of EEG Technology, 25*, 83-92.
- Clark, V.P., Fannon, S., Lai, S., & Benson, R. (2001). Paradigm-dependent modulation of event-related fMRI activity evoked by the oddball task. *Human Brain Mapping, 14*, 116-127.
- David, A.S. (1999). Auditory hallucinations: Phenomenology, neuropsychology and neuroimaging update. *Acta Psychiatrica Scandinavica Supplementum, 99*, 95-104.
- Desmond, J.E., Gabrieli, J.D., Wagner, A.D., Ginier, B.L., & Glover, G.H. (1997). Lobular patterns of cerebellar activation in verbal working-memory and finger-tapping tasks as revealed by functional MRI. *The Journal of Neuroscience: The Official Journal of the Society for Neuroscience, 17*, 9675-9685.
- Diaz, R.M., & Berk, L.E. (Eds.). (1992). *Private speech: From social interaction to self-regulation*. Hillsdale, NJ: Erlbaum.

- Duncan, R.M., & Cheyne, J.A. (2001). Private speech in young adults: Task difficulty, self-regulation, and psychological predication. *Cognitive Development, 16*, 889-906.
- Font, M., Parellada, E., Fernández-Egea, E., Bernardo, M., & Lomeña, F. (2003). Neuroimagen funcional de las alucinaciones auditivas en la esquizofrenia. *Actas Españolas de Psiquiatría, 31*, 3-9.
- Ford, J.M., & Mathalon, D.H. (2004). Electrophysiological evidence of corollary discharge dysfunction in schizophrenia during talking and thinking. *Journal of Psychiatric Research, 38*, 37-46.
- Ford, J.M., Mathalon, D.H., Heinks, T., Kalba, S., Faustman, W.O., & Roth, W.T. (2001). Neurophysiological evidence of corollary discharge dysfunction in schizophrenia. *American Journal of Psychiatry, 158*, 2069-2071.
- Ford, J.M., Mathalon, D.H., Kalba, S., Whitfield, S., Faustman, W.O., & Roth, W.T. (2001a). Cortical responsiveness during inner speech in schizophrenia: An event-related potential study. *American Journal of Psychiatry, 158*, 1914-1916.
- Ford, J.M., Mathalon, D.H., Kalba, S., Whitfield, S., Faustman, W.O., & Roth, W.T. (2001b). Cortical responsiveness during talking and listening in schizophrenia: An event-related brain potential study. *Biological Psychiatry, 50*, 540-549.
- Ford, J.M., Mathalon, D.H., Whitfield, S., Faustman, W.O., & Roth, W.T. (2002). Reduced communication between frontal and temporal lobes during talking in schizophrenia. *Biological Psychiatry, 51*, 485-492.
- Fujimaki, N., Hayakawa, T., Matani, A., & Okabe, Y. (2004). Right-lateralized neural activity during inner speech repeated by cues. *Neuroreport: An International Journal for the Rapid Communication of Neuroscience Research, 15*, 2341-2345.
- Fujimaki, N., Kuriki, S., Nakajima, H., Konychev, V. A., & Musha, T. (1997). Event-related potentials and equivalent current dipoles in silent speech using a vowel and word. *Journal of Psychophysiology, 11*, 12-20.
- Fujimaki, N., Takeuchi, F., Kobayashi, T., Kuriki, S., & Hasuo, S. (1994). Event-related potentials in silent speech. *Brain Topography, 6*, 259-267.
- Garney, S.M. (1993). Event-related brain potentials in the study of language: An introduction. *Language & Cognitive Processes, 8*, 337-356.
- Gehring, W.J., Bryck, R.L., Jonides, J., Albin, R.L., & Badre, D. (2003). The mind's eye, looking inward? In search of executive control in internal attention shifting. *Psychophysiology, 40*, 572-585.
- Girbau, D. (1996). Private and social speech in communication: Terminology and distinctive traits. *Journal of Psycholinguistic Research, 25*, 507-513.
- Girbau, D. (1997). El lenguaje privado y social en la comunicación referencial ecológica infantil. In H.Boada & M. Forns, (Eds.), Referential communication: An ecological perspective [Special Issue]. *Anuario de Psicología, 75*, 59-75.
- Girbau, D. (2001). Children's referential communication failure: The ambiguity and abbreviation of message. In H. Giles & J.J. Bradac (Eds.), Language, education and social dynamics: The legacy of W. Peter Robinson [Special Issue]. *Journal of Language and Social Psychology, 20*, 81-89.
- Girbau, D. (2002a). *Psicología de la comunicación*. Barcelona: Ariel.
- Girbau, D. (2002b). Private and social speech in children's dyadic communication in naturalistic context. *Anuario de Psicología, 33*, 339-354.
- Girbau, D. (2002c). A sequential analysis of private and social speech in children's dyadic communication. *The Spanish Journal of Psychology, 5*, 110-118.
- Girbau, D. (2004). New directions in Psycholinguistics and Communication Sciences: Neurocognitive processes and genetic bases of human communication. *SpeechPathology.com, 8/16/2004*. San Antonio, TX.
- Girbau, D., & Boada, H. (1996). Private meaning and comparison process in children's referential communication. *Journal of Psycholinguistic Research, 25*, 379-392.
- Girbau, D., & Boada, H. (2004). Accurate referential communication and its relation with private and social speech in a naturalistic context. *The Spanish Journal of Psychology, 7*, 81-92.
- Gizewski, E.R., Timmann, D., & Forsting, M. (2004). Specific cerebellar activation during Braille reading in blind subjects. *Human Brain Mapping, 22*, 229-235.
- Gruber, O., Kleinschmidt, A., Binkofski, F., Steinmetz, H., & von Cramon, D.Y. (2000). Cerebral correlates of working memory for temporal information. *Neuroreport: An International Journal for the Rapid Communication of Neuroscience Research, 11*, 1689-1693.
- Halpern, A.R., Zatorre, R.J., Bouffard, M., & Johnson, J.A. (2004). Behavioral and neural correlates of perceived and imagined musical timbre. *Neuropsychologia, 42*, 1281-1292.
- Hirsch, J. (2003). Imaging and biological function in health and disease. *Journal of Clinical Investigation, 111*, 1440-1443.
- Huttenlocher, P.R., & Dabholkar, A.S. (1997). Regional differences in synaptogenesis in human cerebral cortex. *Journal of Comparative Neurology, 387*, 167-178.
- Jasper, H.H. (1958). The ten-twenty electrode system of the International Federation, *Electroencephalography and Clinical Neurophysiology, 10*, 371-375.
- Jezzard, P., Matthews, P. M., & Smith, S.M. (Eds.). (2002). *Functional MRI: An introduction to methods*. Oxford, UK: Oxford University Press.
- Junginger, J. & Rauscher, F.P. (1987). Vocal activity in verbal hallucinations. *Journal of Psychiatric Research, 21*, 101-109.
- Kawashima, R., Okuda, J., Umetsu, A., Sugiura, M., Inoue, K., Suzuki, K., Tabuchi, M., Tsukiura, T., Narayan, S.L., Nagasaka, T., Yanagawa, I., Fujii, T., Takahashi, S., Fukuda, H., & Yamadori, A. (2000). Human cerebellum plays an important role in memory-timed finger movement: An fMRI study. *Journal of neurophysiology, 83*, 1079-1087.
- Kelman, C.A. (2001). Egocentric language in deaf children. *American Annals of the Deaf, 146*, 276-279.
- Kim, K.H.S., Relkin, N.R., Lee, K.M., & Hirsch, J. (1997). Distinct cortical areas associated with native and second languages. *Nature, 388*, 171-174.

- Kutas, M., Federmeier, K.D., Coulson, S., King, J.W., & Münte, T.F. (2000). Language. In J.T. Cacciopo, L.G. Tassinari, & G.G. Bernston (Eds.), *Handbook of psychophysiology* (pp. 576-601). Cambridge, UK: Cambridge University Press.
- Lang, W., Starr, A., Lang, V., & Lindinger, G. (1992). Cortical DC potential shifts accompanying auditory and visual short-term memory. *Electroencephalography & Clinical Neurophysiology*, *82*, 285-295.
- Logie, R.H., Venneri, A., della Sala, S., Redpath, T.W., & Marshall, I. (2003). Brain activation and the phonological loop: The impact of rehearsal. *Brain and Cognition*, *53*, 293-296.
- Logothetis, N.K. (2003). The neural basis of the blood-oxygen-level-dependent functional magnetic resonance imaging signal. In A. Parker, A. Derrington, & C. Blakemore (Eds.), *The physiology of cognitive processes* (pp. 62-116). Oxford, UK: Oxford University Press.
- MacSweeney, M., Amaro, E., Calvert, G.A., Campbell, R., David, A.S., McGuire, P., Williams, S.C.R., Woll, B., & Brammer, M.J. (2000). Silent speechreading in the absence of scanner noise: An event-related fMRI study. *Neuroreport: An International Journal for the Rapid Communication of Neuroscience Research*, *11*, 1729-1733.
- McGuire, P.K., Robertson, D., Thacker, A., David, A.S., Kitson, M., Frackowiak, R.S.J., & Frith, C.D. (1997). Neural correlates of thinking in sign language. *Neuroreport: An International Journal for the Rapid Communication of Research in Neuroscience*, *8*, 695-698.
- McGuire, P.K., Silbersweig, D.A., Murray, R.M., David, A.S., Frackowiak, R.S., & Frith, C.D. (1996). Functional anatomy of inner speech and auditory verbal imagery. *Psychological medicine*, *26*, 29-38.
- Papaioannou, A., Ballon, F., Theodorakis, Y., & Vanden, A.Y. (2004). Combined effect of goal setting and self-talk in performance of a soccer-shooting task. *Perceptual & Motor Skills*, *98*, 89-99.
- Petrovich, N., Holodny, A. I., Tabar, V., Correa, D.D., Hirsch, J., Gutin, P.H., & Brennan, C.W. (2005). Discordance between silent speech fMRI and intraoperative speech arrest. *Neurosurgery*, *103*, 267-274.
- Piaget, J. (1968). *Le langage et la pensée chez l'enfant. Etudes sur la logique de l'enfant* [The language and thought of the child] (7<sup>th</sup> ed.). Neuchâtel, Switzerland: Delachaux et Niestlé. (Original work published 1923.)
- Pihan, H., Altenmüller, E., Hertrich, I., & Ackermann, H. (2000). Cortical activation patterns of affective speech processing depend on concurrent demands on the subvocal rehearsal system. A DC-potential study, *Brain*, *123*, 2338-2349.
- Riecker, A., Ackermann, H., Wildgruber, D., Dogil, G., & Grodd, W. (2000). Opposite hemispheric lateralization effects during speaking and singing at motor cortex, insula and cerebellum. *NeuroReport: An International Journal for the Rapid Communication of Neuroscience Research* *11*, 1997-2000.
- Savoy, R.L. (2005). Experimental design in brain activation MRI: Cautionary tales. *Brain Research Bulletin*, *67*, 361-367.
- Schlaggar, B.L., Brown, T.T., Lugar, H.M., Visscher, K.M., Miezin, F.M., & Petersen, S.E. (2002). Functional neuroanatomical differences between adults and school-age children in the processing of single words. *Science*, *296*, 1476-1479.
- Schönfeldt-Lecuona, C., Grön, G., Walter, H., Büchler, N., Wunderlich, A., Spitzer, M., & Herwig, U. (2004). Stereotaxic rTMS for the treatment of auditory hallucinations in schizophrenia. *Neuroreport: An International Journal for the Rapid Communication of Neuroscience Research*, *15*, 1669-1673.
- Shergill, S.S., Brammer, M.J., Fukuda, R., Bullmore, E., Amaro, E., Murray, R.M., & McGuire, P.K. (2002). Modulation of activity in temporal cortex during generation of inner speech. *Human Brain Mapping*, *16*, 219-227.
- Shergill, S.S., Bullmore, E.T., Brammer, M.J., Williams, S.C.R., Murray, R.M., & McGuire, P.K. (2001). A functional study of auditory verbal imagery. *Psychological Medicine*, *31*, 241-253.
- Small S.L., Flores, D.K., & Noll, D.C. (1998). Different neural circuits subserve reading before and after therapy for acquired dyslexia. *Brain and Language*, *62*, 298-308.
- Tillfors, M., Furmark, T., Marteinsdottir, I., & Fredrikson, M. (2002). Cerebral blood flow during anticipation of public speaking in social phobia: A PET study. *Biological Psychiatry*, *52*, 1113-1119.
- Vygotsky, L.S. (1987). *The collected works of L. S. Vygotsky: Vol. 1. Problems of general psychology. Including the Volume Thinking and Speech*. (R.W. Rieber & A.S. Carton, Eds.; N. Minick, Trans.). New York: Plenum Press. (Original work published 1934.)
- Watson, J.B. (1983). *Psychology from the standpoint of a behaviorist*. London: Frances Pinter. (Original work published 1919.)
- Welchew, D.E., Honey, G.D., Sharma, T., Robbins, T.W., & Bullmore, E.T. (2002). Multidimensional scaling of integrated neurocognitive function and schizophrenia as a disconnection disorder. *NeuroImage*, *17*, 1227-1239.
- Yamazaki, T., Kamijo, K., Kenmochi, A., Fukuzumi, S., Kiyuna, T., Takaki, Y., & Kuroiwa, Y. (2000). Multiple equivalent current dipole source localization of visual event-related potentials during oddball paradigm with motor response. *Brain Topography*, *12*, 159-175.
- Yamazaki, T., Kamijo, K., Kiyuna, T., Takaki, Y., & Kuroiwa, Y. (2001). Multiple dipole analysis of visual event-related potentials during oddball paradigm with silent counting. *Brain Topography*, *13*, 161-168.
- Zivin, G. (Ed.). (1979). *The development of self-regulation through private speech*. New York: Wiley.

Received September 1, 2006

Revision received February 1, 2007

Accepted February 7, 2007