



Antiulcerogenic Effect of Camel Milk Against Ethanol Induced Gastric Ulcers in Rats

Corresponding Author:

Prof. Attia Hassan,
Prof of Pharmacology and Toxicology, Qassim University - Saudi Arabia

Submitting Author:

Dr. Naser A Al-Wabel,
Associate Professor of Cardiovascular Pharmacology and Toxicology, Qassim University, 51441 - Saudi Arabia

Article ID: WMC002804

Article Type: Research articles

Submitted on: 11-Mar-2012, 11:47:06 AM GMT **Published on:** 13-Mar-2012, 11:22:16 AM GMT

Article URL: http://www.webmedcentral.com/article_view/2804

Subject Categories: VETERINARY MEDICINE

Keywords: Camel milk, Gastric ulcers, Ulcer index, Salicylic acid, Ethanol

How to cite the article: Al-wabel N A, Hassan A , Abbas H , Muosa H . Antiulcerogenic Effect of Camel Milk Against Ethanol Induced Gastric Ulcers in Rats . WebmedCentral VETERINARY MEDICINE 2012;3(3):WMC002804

Copyright: This is an open-access article distributed under the terms of the [Creative Commons Attribution License](#), which permits unrestricted use, distribution, and reproduction in any medium, provided the original author and source are credited.

Source(s) of Funding:

None

Competing Interests:

None

Antiulcerogenic Effect of Camel Milk Against Ethanol Induced Gastric Ulcers in Rats

Author(s): Al-wabel N A, Hassan A , Abbas H , Muosa H

Abstract

The effect of oral administration of raw camel milk (5 ml/kg b.wt.) on ethanol- and aspirin-induced gastric ulcers was tested in rats. Oral administration of camel milk in rats with ethanol-induced gastric ulcer, significantly ($P < 0.05$) reduced the number of long ulcers, average length of ulcers, ulcer index and the volume of gastric juice. The total protein was significantly ($P < 0.05$) increased and the pH of gastric juice was not significantly changed. The curative ratio was 70.70% in camel milk treated group compared to 45.12% in ranitidine-treated rats. Oral administration of camel milk in rats with aspirin-induced gastric ulcers exhibited, significantly ($P < 0.05$), same actions with curative ratio of 65.03% compared to 34.03% in ranitidine-treated rats. In conclusion a significant protective effect of camel milk against ethanol- and aspirin-induced gastric ulcers was reported in rats.

Introduction

Although there is a large number of agents that have been used as antiulcerogenics, most of these drugs produced several side effects including arrhythmias, impotence, gynaecomastia and haematopoietic changes. In addition recurrence rates are high (Ariyoshi et al., 1986). Camel milk is different from other ruminants milk; having low cholesterol, low sugar, high minerals (sodium, potassium, iron, copper, zinc and magnesium), high vitamin C, B2, A and E, low protein and high concentrations of insulin (Rao et al., 1970). It has no allergic properties and it can be consumed by lactase deficient persons and those with weak immune systems. The milk is considered to have medicinal applications and in Sahara, fresh butter is often used as a base for remedies. The products of milk are developed to also include cosmetics or pharmaceuticals. A series of metabolic and autoimmune diseases are successfully treated with camel milk. In India, camel milk is used therapeutically against dropsy, jaundice, problems of the spleen, tuberculosis, asthma, anemia, piles and diabetes (Knoess, 1979). Beneficial role of raw camel milk in chronic pulmonary tuberculosis has been observed (Mal et al., 2001). In repeated trials, it was noticed that there was a 30-35%

reduction in the daily doses of insulin in type 1 diabetes patients receiving raw camel milk (Agrawal et al., 2002 and 2007; Mohamad et al., 2009). In human, camel milk has been shown to improve the clinical course of gastric ulcer with complete wound healing and remarkable decline of its size in 90% of patients, as well as pronounced antacid attributes (Sharmanov et al., 1981). Other therapeutic effects of camel milk have been reported such as improvement or normalization of the characteristics of blood clinical and biochemical analyses, an improvement of renal and hepatic functions (Sharmanov et al., 1982), antidiabetic effects (Agrawal et al., 2007; Mohamad et al., 2009) and hepatoprotective effect (Redwan and Tabll, 2007; Saltanat et al., 2009). Moreover, camel lactoferrin was the most active lactoferrin against *E. coli* 0157:H7 (Conesa, et al., 2008) and has a protective effect against hepatitis C virus (Redwan and Tabll, 2007). The aim of this work is to investigate the effect of camel milk on ethanol and aspirin experimentally induced gastric damage in rats.

Materials and methods

Ethanol induced gastric ulceration:

Animals:

Fifteen male Sprague-Dawley rats (150-200g bwt.) were kept under standard conditions before their use. Animals were starved for 48 hr before use to ensure an empty stomach and were kept in cages with raised floors of wide wire mesh to prevent coprophagy (Garg et al., 1993). To prevent excessive dehydration during the fasting period, rats were supplied with sucrose (BDH) 8% (w/v) solution in NaCl (BDH) 0.2% (w/v) which was removed 1 hr before experiments (Glavin and Mikhaeil (1976).

Rats were randomly divided into 3 equal groups (Table1). In the first day, Rats of group1 (positive control) were administered 2 doses of distilled water (5ml/kg) with 6 hrs intervals. Rats in group 2 received 2 doses of raw camel milk (5ml/kg) with 6 hrs intervals, while rats in the third group received 2 doses of ranitidine(100mg/kg orally) with the same time period. In the second day, control rats received 1 dose of distilled water (5ml/kg) and the second group was given a single dose of camel milk (5ml/kg), while rats of the third group received 1 dose of ranitidine. After

90 min 80% alcohol was given at a dose of 10 ml/kg to all rats. One hour after ethanol administration, all rats were euthanized by an over dose of chloroform and the abdomen was opened, the stomach was removed, opened along the greater curvature and gently rinsed under running water. Lesions in the glandular part of the stomach were measured under illuminated magnifying microscope (10x). Long lesions were counted and measured along the greater length. Petechial lesions were counted with the aid of a 1-mm squares grid (Ogle et al., 1985). Each five petechial lesions were taken as a 1 mm ulcer (Cho and Ogle, 1978). The sum of the total length of long ulcers and petechial lesions in each group of rats were divided by its number to calculate the ulcer index (mm). The curative ratio was determined by the following formula: Curative ratio = (Control ulcer index – Test ulcer index) / (Control ulcer index) x 100

Aspirin induced gastric ulceration

Animals:

Fifteen male Sprague-Dawley rats (150-200g bwt.) were kept under standard conditions before their use. Rats were randomly allocated into 3 equal groups (Table 1). The modified method of (Goel, et al., 1985) was used for the induction of experimental gastric ulceration. Rats in group 1 (positive control) were given distilled water and after 3 hrs aspirin (200 mg/kg) dissolved in 1% carboxymethylcellulose was given orally then after 3 hrs distilled water was given again. Instead of receiving distilled water, rats in group 2 and 3 were given, orally, camel milk (5ml/kg) and ranitidine (100 mg/kg), respectively, in addition to aspirin. Treatments were continued for 3 days. On the fourth day, stomach was explored and the pylorus was ligated under ether anaesthesia. The abdomen was closed and the animals were left to recover, while drinking water was withheld. After 4 hrs rats were killed with an overdose of chloroform and the oesophagus was ligated then the stomach was removed. The gastric mucosa was washed with 3 ml of distilled water. The gastric juice and the washings were homogenized and centrifuged at 5000 rpm for 5 min. The volume of gastric juice was measured and expressed as ml/100g of body weight. The stomach was then cut along the great curvature and the glandular portion was examined under dissecting microscope. The number of ulcers was counted and the total length was measured to calculate the curative ratio as was mentioned above.

Determination of protein content

Total protein (g/dl) in the gastric juice was determined by the Biuret Reagents (Mehl, 1945) using commercial kits.

Statistical analysis

Differences between control and treated groups (Mean±SD) were tested for significance using a one-way analysis of variance (ANOVA) followed by Duncan's multiple range test. Differences were considered of significance at a level of $P < 0.05$ using SPSS version 10 computer program.

Results

Oral administration of camel milk in rats with alcohol-induced gastric ulcers significantly ($P < 0.05$) reduced the number of long ulcers, average length of ulcers and ulcer index. The volume of gastric juice was also significantly ($P < 0.05$) reduced; however, the pH of gastric juice was not significantly changed. The total protein was slightly increased.

Oral administration of ranitidine in rats with alcohol-induced gastric ulcers slightly reduced the total protein. The curative ratio was 70.70% in camel milk-treated group compared to 45.12% in ranitidine-treated rats (Table 2).

Oral administration of camel milk in rats with aspirin-induced gastric ulcers significantly ($P < 0.05$) reduced the number of long ulcers, ulcer index, volume of gastric juice and increased the total protein. The pH of gastric juice was not significantly changed. Pretreatment with ranitidine, orally, significantly decreased the number of long ulcers and ulcer index. The total protein was significantly ($P < 0.05$) increased; however, there was a slight change in the volume of gastric juice. The curative ratio was 65.03% in camel milk-treated group compared to 34.03% in ranitidine-treated one (Table 3).

Macroscopic and microscopic examination of gastric mucosa revealed large patches of petechial hemorrhages seen in the stomach of alcohol-treated rats (not presented). These lesions were markedly reduced in stomach of camels milk-treated rats. Oral administration of aspirin induced long ulcerations of the gastric mucosa which were decreased in number and length in the stomach of camel milk-treated rats. Moderate effects were seen in ranitidine-treated rats (Fig. 1).

Discussions and conclusion

The present data clearly demonstrate the protective effect of oral administration of camel milk against gastric damage induced experimentally by ethanol or salicylic acid (aspirin) in rats. Two models of gastric ulcers were used; acute gastric damage was induced by ethanol and delayed onset of gastric ulceration was

induced by the nonsteroidal anti-inflammatory agent (NSAID); salicylic acid.

Ethanol is one of the most widely used agents in experimental models for the evaluation of drugs antiulcerative activity in rats (Akhtar and Ahmad, 1995; Atta et al., 2005). The acute effect of ethanol has been proved to be due to protein precipitation of the cytoplasmic components in the superficial cells of the gastric mucosa and release of the vasoactive mediators such as leukotrienes C₄ (LTC₄) and histamine (Jamal et al., 2006). The vasoactive mediators cause blood flow stasis in the microcirculation of the mucous membrane; an effect which may contribute to the increased lesions in this model (Konturek et al., 1988; Wallace, 2001). In addition, alcohol may also induce solubilization in the mucous of the stomach wall, increase the flow of sodium and potassium into the lumen, increase the pepsin release, and decrease the tissue levels of DNA, RNA and proteins, which predisposes the mucous membrane unprotected, thus leading to tissue injury (Robert et al., 1979). Moreover, ethanol has been proved to increase the production of reactive oxygen species (ROS) and free radicals (Gazzieri, 2007). In the results, the ironic and bizarre behavior of ranitidine in ethanol-treated group in which the total protein was reduced resulted from the interaction between this drug and alcohol that curtails protein synthesis in the mucosal membrane.

The use of non steroidal anti-inflammatory drugs as a model for induction of experimental gastric damage has been widely practiced (Atta et al., 2005). Inhibition of endogenous prostaglandins renders the stomach to be more susceptible to damage. These eicosanoids inhibit acid secretion by the parietal cells and promote secretion of cytoprotective mucous in the stomach (Robert, 1981). The mechanism of aspirin-induced ulcerogenic effect is by the inhibition of endogenous prostaglandins synthesis (Whittle and Vane, 1983) which, consequently, decreases the cytoprotective action of prostaglandins. Anti-inflammatory drugs, such as indomethacin, injure the gastric mucous membrane through the inhibition of the gastric cyclooxygenase (COX) enzyme, resulting in the cessation of prostaglandins production (Wallace, et al., 2000). Prostaglandins, such as E₂ and prostacyclins, act on the synthesis of mucus and bicarbonate, the regulation of acid secretion and the blood flow in the gastric mucous membrane; hence their inhibition critically compromises the gastric cytoprotection (Whittle et al., 1985). The increased production of these prostanoids provides greater resistance of gastric mucosal membrane against several agents, such as anti-inflammatory drugs (Wallace, 2001; Arun

and Asha, 2008; Nguelefack et al., 2008).

Camel milk have been proved to have more pronounced antacid properties (Sharmanov et al., 1981). Nonetheless, it has been reported that camel milk contains high levels of vitamins C, A, B₂ and E and is very rich in magnesium and zinc (Rahman et al., 2005). These vitamins are antioxidants that found to be useful in reducing the oxidative stress caused by toxic agent (Sajitha et al., 2010; Traber and Stevens, 2011). Magnesium is very essential for biosynthesis of glutathione; since the enzyme glutathione synthetase requires γ -glutamyl cysteine, glycine, ATP and magnesium ions (Virginia, et al., 1971). Magnesium deficiency has been associated with the production of reactive oxygen species and magnesium supplementation protects cell against oxyradical damage and assists in the absorption and metabolism of vitamins, B, C and E (Martin et al., 2003). Vitamin E has been suggested to enhance glutathione levels and may play a major protective role in magnesium deficiency-induced cardiac lesions (Barbagallo, 1999). More recently, magnesium significantly enhances the antioxidant defence and was effective against alcohol-induced oxidative stress, disturbance of liver function and elevated cholesterol, particularly when given with selenium (Markiewicz et al., 2011).

Another interpretation of the protective effect of camel milk reported in the present investigation might be due to the fact that it is rich in zinc (Rahman et al., 2005). Zinc is a trace element essential for the activity of many enzymes in the living organisms. A protective effect of zinc has been reported against the cellular toxicity induced by cadmium. This action probably due to palliative effect on oxidative stress and apoptosis and to decreased lipid peroxides (Goering, and Klaassen, 1984; Jemai et al., 2007; Jihen et al., 2011). It also plays an important role in the DNA replication, transcription and protein synthesis, influencing cell division and differentiation (Frederickson, 1989). Moreover, zinc deficiency increases lipid peroxidation in various rat tissues, whereas supplementation corrects the impairment (Shaheen, and El-Fattah, 1995). It has been reported that zinc can prevent cell damage through activation of the antioxidant system (Sato and Bremner, 1993; Powell, 2000; Ozturk, et al., 2003). The antiperoxide drugs have been reported to possess a gastroprotective effect against ethanol-induced gastric damage (Mizui and Hirose, 1987). One more explanation is that it has been reported that camel milk can generate nitric oxide (Hashad, et al., 2006) similar to endogenous breastmilk (Stevens et al., 2000) through its content of xanthine oxidase. The nitric oxide is well recognized as a fundamental mediator in the gastric defense

mechanisms because it stimulates mucus production, inhibits the adherence of neutrophils to the endothelial cells and, especially, increases the blood flow to the gastric mucous membrane (Coruzzi et al., 2000; Olinda et al., 2008).

In conclusion, administration of camel milk can protect gastric mucosa against ethanol or salicylic acid induced gastric damage. In spite of the presented results, the exact mechanism of gastroprotective requires further investigation. One can explore camel milk protection against gastric bacterial infection (*Helicobacter pylori*) and future analysis is needed to evaluate its content and sequence of amino acids and lipoproteins.

References

1. Agrawal RP; S.Budania; P. Sharma ;R. Gupta; DK. Kochar; RB.Panwar and MS Sahani (2007) Zero prevalence of diabetes in camel milk consuming Raica community of north-west Rajasthan, India. *Diabetes Res Clin Pract.* May;76(2):290-6.
2. Agrawal, RP; SC Swami; R Beniwal; DK Kochar and RP Kothari. (2002) Effect of camel milk on glycemic control, risk factors and diabetes quality of life in type-1 diabetes: A randomized prospective controlled study. *Int. J. Diabetes Develop. Countries.*; 22: 70-74.
3. Akhtar AH and KU, Ahmad (1995) Antiulcerogenic evaluation of the methanolic extracts of some indigenous medicinal plants of Pakistan in aspirin-ulcerated rats, *J Ethnopharmacol.*; 46: 1-6
4. Ariyoshi I.; A.Toshiharu; F.Sugimura; M, Abe; Y, Matsuo and T. Honda (1986) Recurrence during maintenance therapy with histamine H₂ receptors antagonist in cases of gastric ulcers, *Nikon Univ J Med.*; 28: 69-74
5. Arun M and VV. Asha (2008) Gastroprotective effect of *Dodonaea viscosa* on various Experimental Ulcer Models *Bhoparmacol.*: 460-465
6. Atta, A.H; Soad M.Nasr and Samar M. Mounair (2005) Antiulcerogenic effect of some plant extracts *Natural Product Radiance*, 4: 258-263
7. Barbagallo, M, (1999) Effects of vitamin E and glutathione on glucose metabolism: Role of magnesium *Hypertension*, 34: 1002-1006
8. Cho.C.H and C.W.A.Ogle (1978) Correlative study of the antiulcer effect of zinc sulphate in stressed rats, *Eur J Pharmacol.* , 48, 97-105
9. Conesa .C; L. Sánchez; C. Rota; MD.Pérez ; M. Calvo ; S.Farnaud and RW.Evans (2008) Isolation of lactoferrin from milk of different species: calorimetric and antimicrobial studies *Comp Biochem Physiol B Biochem Mol Biol* May;150(1):131-9
10. Coruzzi G; M.Adami; G.Morini; C. Pozzoli; C. Cena; M. Bertinaria and A. Gasco (2000) Antisecretory and gastroprotective activities of compounds endowed with H₂ antagonistic and nitric oxide (NO) donor properties. *J Physiol Paris.* Jan-Feb;94(1):5-10.
11. Frederickson, CJ (1989) Neurobiology of zinc and zinc containing neurons. *Int Rev Neurobiol*, 31: 145-238
12. Garg G P; S K, Nigam and C W. Ogle (1993) The gastric antiulcer effects of the leaves of the Neem tree, *Planta Med*, 59, 215-217
13. Gazzieri D (2007) Substance P released by TRPV1-expressing neurons produces reactive oxygen species that mediate ethanol-induced gastric injury *Free Radic Biol Med*, 43: 581-589
14. Glavin G B and A A, Mikhaeil (1976) Stress and ulcer etiology in the rat, *Physiol Bhav*, 16, 135-139
15. Goel R K.; A. Chakrabarti and A K Sanyal (1985)The effect of biological variables on the anti-ulcerogenic effect of vegetable plantain banana, *Planta Med*, 2, 85-88.
16. Goering, PL and CD Klaassen(1984) Zinc induced tolerance to cadmium hepatotoxicity *Toxicol Applied Pharmacol*, 74: 299-307
17. Hashad, M; M. Al-dubaib; K. Al-kheriji and S.A.Galal (2006) Preliminary Study on The Production of Nitric Oxide and Expression of Nitric Oxide Synthase by Camel milk Assiut *Vet Med J Egypt*, 52 (111): oct
18. Jamal A; Kalim Javed; M, Aslama and Ma Jafri (2006) Gastroprotective effect of cardamom, *Elettaria cardamomum* Maton fruitsin rats *J Ethnopharmacol* 103: 149-153
19. Jemai H; I, Messaoudi; A, Chaouch and A Kerkeni (2007) Protective effect of zinc supplementation on blood antioxidant defense system in rats exposed to cadmium *J Trace Elem Med Biol*;21(4):269-73 Epub 2007 Oct 29
20. Jihen EH; S.Sonia; H. Fatima;Mohamed.S.Tahar and K Abdelhamid (2011) Interrelationships between cadmium, zinc and antioxidants in the liver of the rat exposed orally to relatively high doses of cadmium and zinc *Ecotoxicol Environ Saf.* Jul 2
21. Knoess KH, (1979) Milk production of the dromedary *Proceeding of the IFS Symposium Camels*, (SC'79), Sudan, pp: 201-214 23
22. Konturek SJ; T, Brzozowski; D, Drozdowicz and G Beck (1988) Role of leukotrienes in acute gastric lesions by ethanol, taurocholate, aspirin, platelet activating factor and stress in rats *Dig Dis Sci* 33:806-813
23. Mal, G; DS Sena; VK Jain and MS Sahani, (2001) Therapeutic utility of camel milk as nutritional

- supplement in chronic pulmonary tuberculosis *Livestock Int*, pp: 4-8
24. Markiewicz-Górka.I; M,Zawadzki; L.Januszewska; K.Hombek-Urban and K Pawlas 2011 Influence of selenium and/or magnesium on alleviation alcohol induced oxidative stress in rats, normalization function of liver and changes in serum lipid parameters *Hum Exp Toxicol* Apr 7 (Epub ahead of print)
25. Martin HL. Richert and A Berthelot(2003) Magnesium deficiency induces apoptosis in primary cultures of rat hepatocytes *J Nutr*, 133: 2505-2511
26. Mehl J W(1945) Determination of protein by biuret reagent, *J Biol Chem*, 157, 173.
27. Mizui T.H and Sato F. Hirose (1987) Doteuchi M Effect of antiperoxidative drugs on gastric damage induced by ethanol in rats *Life Sci*;41:755–763
28. Mohamad. R.H; H.A. Zekry; O. Al-Mehdar; S.E. Salama; AA, El-Shaieb; MG.El-Basmy and Al-said SM Sharawy (2009) Camel milk as an adjuvant therapy for the treatment of type 1 diabetes: verification of a traditional ethnomedical practice *J Med Food* Apr;12(2):461-5
29. Nguielefack TB; CB, Feumebo; G, Ateufack; P, Watcho; S, Tatsimo ; AD, Atsamo; P, Tane and A Kamanyi (2008) Anti-ulcerogenic properties of the aqueous and methanol extracts from the leaves of *Solanum torvum* Swartz (Solanaceae) in rats *J Ethnopharmacol* 119: 135-140
30. Ogle C W; C H Cho and S H, Wong (1985) The effect of nicotine on ethanol-induced gastric ulcer in rats, *Experimentia*, , 41, 1140-1141
31. Olinda TM; TLG Lemos; LI Machado; VS Rao and FA Santos (2008). Quebracchitol-induced gastroprotection against acute gastric lesions: Role of prostaglandins, nitric oxide and K+ATp channels. *Phytomedicine*. J.15: 327- 333.
32. Ozturk, A; AK Baltaci; R Mogulkoc; E Oztekin; A Sivrikaya; E Kurtogh and A Kul(2003) Effects of zinc deficiency and supplementation on malondialdehyde and glutathione levels in blood and tissue of rats performing swimming exercise *Biol Trace Elem Res*, 94: 157-166
33. Powell, SR (2000) Antioxidant properties of zinc. *J Nutr*,130:1447-1454
34. Rahman, I; SK J Biswas; LA Menez; M Torres and H Jay Forman, (2005) Glutathione, stress responses and redox signaling in lung inflammation *Antioxid Redox Signal*, 7: 45-59
35. Rao, M.B; R.C. Gupta and N.N. Dastur(1970) Camels' milk and milk products *Indian J Dairy Sci*, 23: 71-78
36. Redwan el-R.M and A Tabll (2007) Camel lactoferrin markedly inhibits hepatitis C virus genotype 4 infection of human peripheral blood leukocytes. *J Immunoassay Immunochem*;28(3):267-77
37. Robert A. (1981) Current history of cytoprotection, International workshop on protective actions of prostaglandins on the gastrointestinal mucosa, *Prostaglandins*, , 21, suppl, 89-96
38. Robert A; JE.Nezamis; C.Lancaster and AJ Hanchar (1979) Cytoprotection by prostaglandins in rats Prevention of gastric necrosis produced by alcohol, HC1, NaOH, hypertonic NaCl and thermal injury *Gastroenterology* 77: 433-443
39. Sajitha GR, R.Jose; A. Andrews ; KG Ajantha; P Augustine and KT Augusti (2010) Garlic Oil and Vitamin E Prevent the Adverse Effects of Lead Acetate and Ethanol Separately as well as in Combination in the Drinking Water of Rats *Indian J Clin Biochem* 2010 Jul;25(3):280-8 Epub Aug 25
40. Saltanat H; H. Li ; Y. Xu ; J Wang; F. Liu and XH Geng (2009) The influences of camel milk on the immune response of chronic hepatitis B patients *Xi Bao Yu Fen Zi Mian Yi Xue Za Zhi* May;25(5):431-3
41. Sato, M and I Bremner(1993) Oxygen free radicals and metalothionein *Free Radic.Biol Med*,J. 14: 325-327
42. Shaheen, AA and AA El-Fattah(1995) Effect of dietary zinc on lipid peroxidation, glutathione, protein levels and superoxide dismutase activity in rat tissues.*Int J Biochem Cell Biol*, 27: 89-95
43. Sharmanov TSh; AK.Zhangabylov and RD Zhaksylykova (1982) Mechanism of the therapeutic action of whole mare's and camel's milk in chronic hepatitis *Vopr Pitan* Jan-Feb;(1):17-23
44. Sharmanov.T.Sh; R.Kh.Kadyrova and B.A. Salkhanov (1981) Effectiveness of peptic ulcer diet therapy using rations containing whole mare's and camel's milk *Vopr Pitan* May-Jun;(3):10-4
45. Stevens, C R; T M Millar; J G Clinch; J M Kanczler; T Bodamyali and D R Blake (2000) Antibacterial properties of xanthine oxidase in human milk *Lancet* Sep 2;356 (9232):829-30
46. Traber MG and JF Stevens (2011) Vitamins C and E: Beneficial effects from a mechanistic perspective *Free Radic Biol Med* May 25 (Epub ahead of print)
47. Virginia, M; MB Smith; MJ Brauner and W Phili(1971) Majerus Glutathione biosynthesis in human erythrocytes I Identification of the enzymes of glutathione synthesis in hemolysates *J Clin Invest*, 50: 507-513
48. Wallace JL (2001) Mechanisms of protection and healing: current knowledge and future research *Am J Med* 110:19-23
49. Wallace JL; W, Mcknight; BK, Reuter and N Vergnoll (2000) NSAID-induced gastric damage in rats: requirement for inhibition of both cyclooxygenase 1 and 2 *Gastroenterology*, 119: 706-714

50. Whittle B J R and J R, Vane (1983) Prostacyclin, thromboxanes, and prostaglandins-actions and roles in the gastrointestinal tract In progress in Gastroenterology, (Jerzy Glass G B and Sherlock P, eds), Grune & Stratton, Inc, New York, , pp 3-30
51. Whittle BJ; N.Oren-Wolman and PH Guth (1985) Gastric vasoconstrictor actions of leukotriene C₄,PGF₂ alpha,and thromboxane mimetic U-46619 on rat submucosal microcirculation in vivo . Am J Physiol Gastrointest Liver Physiol 248: 580-586

Illustrations

Illustration 1

Table 1

Experimental Design

15 Rats (Ethanol-Induced Ulcer)				15 Rats (Aspirin-Induced Ulcer)			
Interval	Groups			Interval	Groups		
	1	2	3		1	2	3
Day 1	D.W (2doses)	C.M	Ran.	0 hr	D.W	C.M	Ran.
Day 2	D.W (1dose)	C.M	Ran.	3 hrs	Asp.	Asp.	Asp.
90 min	80 % Alcohol (10 ml/kg)			3 hrs	D.W	C.M	Ran.
1 hr	Euthanasia			Continuous Treatments for 3 days			
				Day 4	Pylorus Ligation		
				4 hrs	Stomach Removal		

D.W = Distilled water 5 ml/kg

C.M = Camel Milk 5 ml/kg

Ran. = Ranitidine 100 mg/kg

Asp = Aspirin 200 mg/kg suspended in 1 % Carboxymethylcellulose

Illustration 2

Table 2

Antiulcerogenic Effect of Camel Milk Against Ethanol-Induced Gastric Damage in Rats (Mean \pm SD, n = 5)

	Number of Long Ulcers	Length of Ulcer (mm)	Ulcer Index	Curative Ratio (%)	Volume of Gastric Juice (ml/100g)	pH	Total Protein g/dl
Control	4.50 \pm 1.11 ^b	4.24 \pm 0.88 ^b	1.02 \pm 0.4 ^b	--	1.61 \pm 0.25 ^b	7.40 \pm 0.55 ^a	14.67 \pm 4.27 ^a b
Camel Milk (5ml/kg)	1.8 \pm 0.27 ^a	1.26 \pm 0.59 ^a	0.32 \pm 0.2 ^a	70.70	1.15 \pm 0.27 ^a	6.60 \pm 0.55 ^a	17.80 \pm 4.6 ^a
Ranitidine (100mg/kg)	4.60 \pm 1.14 ^b	5.26 \pm 0.27 ^b	1.36 \pm 0.4 ^b	45.12	1.89 \pm 0.39 ^b	7.0 \pm 0.71 ^a	11.97 \pm 2.83 ^a

Means with different letters in the same column are significant at P<0.05

Illustration 3

Table 3

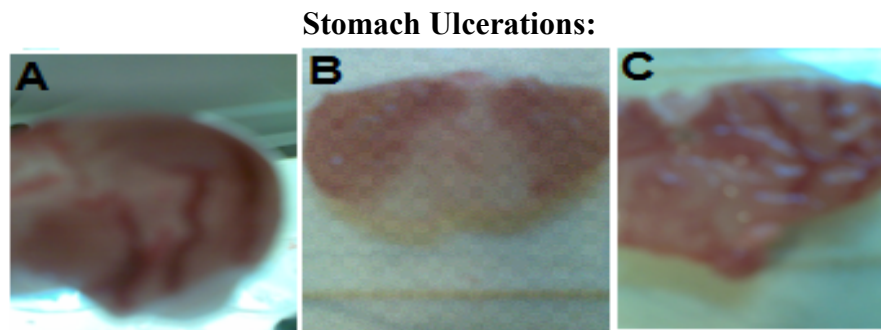
**Antiulcerogenic Effect of Camel Milk on Aspirin-Induced
Gastric Ulcer in Rats (Mean \pm SD, n = 5)**

Total Protein g/dl	pH	Volume of gastric juice ml/100 g	Curative Ratio (%)	Ulcer Index	Number of Long Ulcers	
5.64 \pm 1.43 ^a	5.75 \pm 0.96 ^a	2.24 \pm 0.33 ^b	--	3.43 \pm 0.67 ^c	4.4 \pm 1.14 ^b	Control
100.27 \pm 2.94 ^b	5.6 \pm 1.34 ^a	1.87 \pm 0.27 ^a	65.03	1.2 \pm 0.51 ^a	0.6 \pm 0.55 ^a	Camel Milk (5ml/kg)
11.29 \pm 3.36 ^b	6.8 \pm 1.10 ^a	2.04 \pm 0.11 ^{ab}	34.03	2.26 \pm 0.49 ^b	1.8 \pm 0.44 ^a	Ranitidine (100mg/kg)

Means with different letters in the same column are significant at P<0.05

Illustration 4

Figure 1



(A): Stomach of rat treated with salicylic acid alone showing severe damage and marked long ulceration of the gastric mucosa; (B): salicylic acid + camel milk showing slight congestion in the gastric mucosa; and (C): salicylic acid + ranitidine showing moderate damage with long ulceration.

Reviews

Review 1

Review Title: Antiulcerogenic Effect of Camel Milk Against Ethanol Induced Gastric Ulcers in Rats

Posted by Prof. Khaled Abo-EL-Sooud on 14 Mar 2012 01:49:54 PM GMT

1	Is the subject of the article within the scope of the subject category?	Yes
2	Are the interpretations / conclusions sound and justified by the data?	Yes
3	Is this a new and original contribution?	Yes
4	Does this paper exemplify an awareness of other research on the topic?	Yes
5	Are structure and length satisfactory?	Yes
6	Can you suggest brief additions or amendments or an introductory statement that will increase the value of this paper for an international audience?	Yes
7	Can you suggest any reductions in the paper, or deletions of parts?	Yes
8	Is the quality of the diction satisfactory?	Yes
9	Are the illustrations and tables necessary and acceptable?	Yes
10	Are the references adequate and are they all necessary?	Yes
11	Are the keywords and abstract or summary informative?	Yes

Rating: 8

Comment:

the manuscript is of high interest as the use of natural products is a worldwide concern.

Please some suggestions

I prefer the title is changed to Antiulcerogenic Effect of Camel Milk Against Ethanol and **Aspirin** Induced Gastric Ulcers in Rats

Please mention the source of camel milk and Rantidine

Ref 24 2011 have to be between two brackets

Finally I strongly recommend the acceptance of this valuable work.

Invited by the author to make a review on this article? : Yes

Experience and credentials in the specific area of science:

Pharmacodynamics of herbal extracts

Publications in the same or a related area of science: Yes

References: under publications

How to cite: Abo-EL-Sooud K. Antiulcerogenic Effect of Camel Milk Against Ethanol Induced Gastric Ulcers in Rats [Review of the article 'Antiulcerogenic Effect of Camel Milk Against Ethanol Induced Gastric Ulcers in Rats ' by]. WebmedCentral 1970;3(3):WMCRW001588

Disclaimer

This article has been downloaded from WebmedCentral. With our unique author driven post publication peer review, contents posted on this web portal do not undergo any prepublication peer or editorial review. It is completely the responsibility of the authors to ensure not only scientific and ethical standards of the manuscript but also its grammatical accuracy. Authors must ensure that they obtain all the necessary permissions before submitting any information that requires obtaining a consent or approval from a third party. Authors should also ensure not to submit any information which they do not have the copyright of or of which they have transferred the copyrights to a third party.

Contents on WebmedCentral are purely for biomedical researchers and scientists. They are not meant to cater to the needs of an individual patient. The web portal or any content(s) therein is neither designed to support, nor replace, the relationship that exists between a patient/site visitor and his/her physician. Your use of the WebmedCentral site and its contents is entirely at your own risk. We do not take any responsibility for any harm that you may suffer or inflict on a third person by following the contents of this website.