

Oxidative Stress in Keratoconus?

Emma Arnal,¹ Cristina Peris-Martínez,^{1,2} Jose Luis Menezo,¹ Siv Johnsen-Soriano,¹ and Francisco Javier Romero^{1,3}

PURPOSE. The purpose of this study was to establish the alterations of oxidative stress-related markers in keratoconus (KC) corneas.

METHODS. A total of 6 healthy and 11 ectatic corneas (7 KC and 4 post-LASIK) were studied. Different oxidative stress-related markers were determined to assess their implication in the KC pathophysiology. Total antioxidant capacity and total nitrites present in the samples were assayed. Furthermore, lipid peroxidation products and the glutathione contents were determined, together with 4-hydroxynonenal (4-HNE) immunohistochemistry, to establish the relationship between KC and oxidative stress.

RESULTS. The antioxidant capacity and glutathione content in KC corneas were decreased significantly when compared with healthy corneas. Moreover, the total nitrites and lipid peroxidation were significantly elevated in the corneas with KC when compared with the controls. There was a statistically significant difference in the amount of HNE-positive cells in KC corneas when compared with healthy corneas by immunohistochemistry. Post-LASIK ectatic corneas and KC corneas showed similar results.

CONCLUSIONS. The increased levels of oxidative stress markers and the decreased antioxidant capacity and antioxidant defenses in KC corneas, as well as in the post-LASIK ectatic corneas, indicate that oxidative stress might be involved in the development of this disease and may provide new insights for its prevention and treatment in the future. (*Invest Ophthalmol Vis Sci.* 2011;52:8592-8597) DOI:10.1167/iovs.11-7732

Keratoconus (KC) is a significant clinical problem worldwide and a leading indication for corneal transplantation. KC is a progressive, noninflammatory corneal ectasia that results in protrusion and thinning due to a weakening of the cornea.¹ It classically manifests in the teenage years to young adulthood and leads to a variable decrease in the quality of vision and ocular discomfort.² The weakened cornea is one of the most challenging conditions for surgeons to recognize before performing LASIK (laser in situ keratomileusis) or to treat after LASIK.³ LASIK is one of the most common refractive surgical procedures for the treatment of myopia. The molecu-

lar pathogenesis of KC is poorly understood and to understand how to strengthen the cornea, one must first understand how the cornea is weakened by keratoectasia and KC. Previous reports suggested that oxidative stress may be involved in KC.⁴⁻⁸ It is commonly known that the accumulation of reactive oxygen species (ROS) can damage cells by reacting with proteins, DNA, and membrane phospholipids. Normally, the cornea's natural antioxidant enzymes eliminate the ROS before they damage cells; these include superoxide dismutase, catalase, glutathione reductase, and glutathione peroxidase,^{9,10} but in the disease state, ROS may overwhelm cellular defenses and promote cell damage.

Cells can also be damaged by subproducts formed during ROS-induced lipid peroxidation^{11,12} and the release of different reactive aldehydes, such as malondialdehyde (MDA) and 4-hydroxy-2, 3-*trans*-nonenal (HNE).^{9,13} Aldehydes are relatively stable compared with free radicals and can diffuse to attack distant target sites. These aldehydes are highly reactive and can covalently interact with proteins and DNA to form adducts that alter signal transduction, gene expression, and proliferation. Aldehydes disrupt the membranes of lysosomes and cells releasing lysosomal proteolytic enzymes, including cathepsin.¹⁴ Former reports have demonstrated that KC corneas have increased levels of cathepsin-B and -G, and lysosomal enzymes (acid esterases, acid phosphatases, and acid lipases),¹⁵ but there are no data available regarding the presence of lipid peroxidation products in this tissue.

HNE is a prominent aldehyde generated during lipid peroxidation, and is thought to play a major role in cell dysfunction and death in disorders ranging from atherosclerosis,^{16,17} diabetes, and retinal degenerative disorders.¹⁸ HNE can modify proteins on cysteine, lysine, and histidine residues and such modifications can impair protein function and promote protein aggregation. For example, HNE has been shown to impair the function of ion-motive adenosine triphosphatases (ATPases), glucose, and glutamate transporters, and guanosine triphosphate (GTP)-binding proteins in experimental models of degenerative disorders^{19,20} and even inhibit glutathione peroxidase activity.²¹

Although some antioxidant enzymatic activities and protein levels have been examined in normal and KC corneas,^{4,5,7} the role of oxidative stress and HNE in KC corneas is not clear. Data reported herein are novel and may provide new insights into the pathophysiology of corneal ectasia.

METHODS

A total of 17 human corneal buttons obtained at the Fundación Oftalmológica del Mediterráneo (FOM-Valencia, Spain) were studied (Table 1). Eleven ectatic corneas (seven KC and four ectatic corneas associated with LASIK surgery) were analyzed within 24 hours after penetrating keratoplasty. Age-matched normal corneas ($n = 6$) were used as a control group from healthy donors (the corneal rim, which is not used for corneal transplant) within 24 hours after death. Informed consent was obtained from all participants or relatives, and the study was performed according to the tenets of the Declaration of Helsinki for research involving human subjects.

From the ¹Fundación Oftalmológica del Mediterráneo (FOM), Valencia, Spain; ²Universidad CEU-Cardenal Herrera, Moncada, Spain; and ³Facultad de Medicina, Universidad Católica de Valencia 'San Vicente Mártir', Valencia, Spain.

Supported in part by Grants PRCEU-UCH/COP01/08 Copernicus-Santander and SAF2010-21317 from Plan Nacional de Biomedicina (FJR) and funds from Fundación Oftalmológica del Mediterráneo.

Submitted for publication April 13, 2011; revised August 9 and September 1, 2011; accepted September 1, 2011.

Disclosure: E. Arnal, None; C. Peris-Martínez, None; J.L. Menezo, None; S. Johnsen-Soriano, None; F.J. Romero, None

Corresponding author: Francisco Javier Romero, Facultad de Medicina, Universidad Católica de Valencia 'San Vicente Mártir', C/Quevedo, 2, 46001-Valencia, Spain; fj.romero@ucv.es.

TABLE 1. Characteristics of Normal and Ectatic Corneas

Control Group			Keratoconus Group			Post-LASIK Group		
Cornea (n)	Age (y)	Sex	Cornea (n)	Age (y)	Sex	Cornea (n)	Age (y)	Sex
1	27	M	1	29	M	1	30	M
2	45	M	2	41	M	2	39	M
3	31	F	3	33	F	3	31	M
4	28	M	4	26	M	4	27	F
5	33	M	5	31	M			
6	45	F	6	35	M			
			7	40	F			
Mean age, y	34.8			33.57			31.75	

Antioxidant Capacity

The antioxidant capacity was measured with a commercial kit (Antioxidant Assay Kit, Cayman, MI) that is used to measure the total antioxidant capacity of the different samples (Fig. 1). The assay relies on the ability of the antioxidants in the sample to inhibit the oxidation of 3-ethylbenzotiazolin 6-sulfonic acid (ABTS) to ABTS+ by metmyoglobin. The amount of ABTS+ can be monitored by reading the absorbance at 405 nm which is proportional to its concentration.

Level of Nitrites

To measure the total nitrites, a commercial kit was used (Parameter, Total Nitrite, R&D Systems, Oxford, UK). The principle of this assay is the determination of nitric oxide (NO) concentrations based on the enzymatic conversion of nitrate to nitrite. The amount of total nitrites can be monitored by reading the absorbance at 540 nm which is proportional to the NO concentration.

Lipid Peroxidation

The lipid peroxidation was measured with a commercial kit (Lipid Peroxidation Microplate Assay Kit, Oxford Biomedical Research, Rochester Hills, MI) following the manufacturer's instructions (see Fig. 3). This assay is based on the reaction of two molecules of a chromogenic reagent, N-methyl-2-phenylindole, with one molecule of malondialdehyde (MDA), at 45°C, to yield a stable chromophore with a maximal absorbance at 586 nm. The amount of MDA can be monitored by reading the absorbance at 586 nm which is proportional to its concentration.

Glutathione Levels

The concentration of total glutathione (GSH) was measured with a commercial kit (NWLSS Glutathione Assay, Northwest Life Science, Vancouver, WA) following the manufacturer's instructions (see Fig. 4).

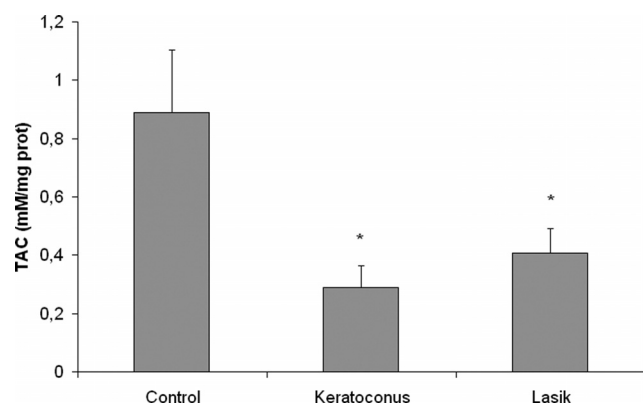


FIGURE 1. Total Antioxidant capacity (TAC) in control, keratoconus, and ectasia after LASIK corneas. The figure shows a significant difference in KC and LASIK samples versus control group (* $P < 0.05$).

The test principle is a modification of the method first described by Tietze.²² The general thiol reagent, 5-5'-dithiobi (2-nitrobenzoic acid) (DNTB, Ellman's reagent) reacts with GSH to form the 412 nm chromophore, 5-thionitrobenzoic acid (TNB). The amount of total GSH was monitored by a microplate reader with kinetics capability at 405 nm.

4-Hydroxyl-2,3-trans-nonenal Immunohistochemistry

Corneal sections were prepared for immunohistochemical staining by fixation in 4% fresh formaldehyde and embedded in paraffin. Three-micrometer sections were cut and stained with Hematoxylin & Eosin (H&E). The sections were also stained with the antibody against the oxidative stress marker HNE (HNE11-S, 1:200, Alpha Diagnostic International, Cambridge, UK). The staining was done (Autostainer Benchmark Classic; Ventana Medical Systems, Inc., Tucson, AZ) and visualized using a standard peroxidase technique (ultraVIEW Universal DAB detection kit; Ventana Medical Systems, Inc.). The positive immunoreactions of the primary antibody were detected by a secondary antibody conjugated with peroxidase-labeled polymer with diaminobenzidine (DAB) as chromogen (see Fig. 5). These stained sections were used to count total HNE-positive cells in the different samples.

Confocal Microscopy Analysis

The samples were stained with Alexa Fluor 488 (Molecular Probes, Invitrogen, Carlsbad, CA) and imaged sequentially with a confocal microscope (EZ-C1 in Ti-U Eclipse Inverted Confocal microscope; Nikon, Tokyo, Japan) using a 60× oil objective (Plan Apo 60x oil, Nikon). For 4-HNE-stained tissue, the Ar-Kr 488-nm laser line was used at a voxel resolution of approximately $1.5 \times 1.5 \times 3 \mu\text{m}$. We used a pixel resolution of 1024×1024 in xy axes and an 8-bit intensity in all confocal scans.

Statistical Analysis

Data are expressed as mean \pm SEM. Comparisons between groups were done using 1- and 2-way ANOVA, and Student's two-tailed unpaired t -test. Statistical differences were set at the $P < 0.05$ level.

RESULTS

Antioxidant Capacity

The antioxidant capacity in keratoconus corneas was decreased significantly (0.29 ± 0.07 mM/mg protein) when compared with normal corneas (0.89 ± 0.27 mM/mg protein, $P < 0.05$ vs. control). This antioxidant capacity in ectasia associated with LASIK patients, was also decreased significantly (0.40 ± 0.086 mM/mg protein) when compared with normal corneas (see Fig. 1). However, there were no significant differences when keratoconus corneas (0.29 ± 0.07 mM/mg protein) were compared with ectasia associated with LASIK corneas (0.40 ± 0.086 mM/mg protein, $P > 0.05$).

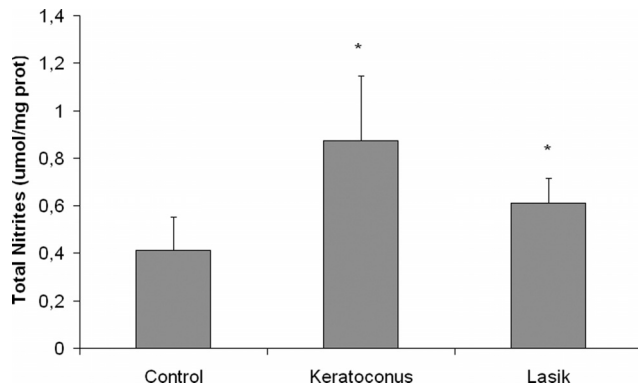


FIGURE 2. Total nitrites in control corneas and corneas with keratoconus and ectasia after LASIK (* $P < 0.05$).

Total Nitrites

Total nitrites were significantly elevated in the corneas with keratoconus ($0.87 \pm 0.27 \mu\text{mol/mg protein}$) and ectasia associated with LASIK ($0.61 \pm 0.10 \mu\text{mol/mg protein}$), when compared with the control ones ($0.42 \pm 0.15 \mu\text{mol/mg protein}$, $P < 0.05$ vs. control) (Fig. 2).

Lipid Peroxidation

The concentrations of the lipid peroxidation product MDA in the corneas of the different groups showed an increase with a statistical significant difference ($P < 0.05$) between keratoconus corneas ($0.58 \pm 0.11 \mu\text{mol of MDA/mg protein}$) and LASIK corneas ($0.42 \pm 0.1 \mu\text{mol of MDA/mg protein}$), when both groups were compared with the control one ($0.28 \pm 0.05 \mu\text{mol of MDA/mg protein}$). Again, no significant difference between keratoconus and LASIK group was observed (Fig. 3).

Glutathione

GSH contents were decreased in both the KC ($0.29 \pm 0.064 \mu\text{mol/mg protein}$) and ectasia associated with LASIK corneas groups ($0.31 \pm 0.079 \mu\text{mol/mg protein}$), when compared with the control group ($0.46 \pm 0.082 \mu\text{mol/mg protein}$). This tendency was observed in both groups with a statistical difference ($P < 0.05$). However, there is no statistical difference ($P < 0.05$) between the KC corneal group and the ectasia associated with LASIK group (Fig. 4).

HNE Immunohistochemistry

The oxidative marker HNE was used to confirm occurrence of lipid peroxidation. The corneas showed a significant increasing

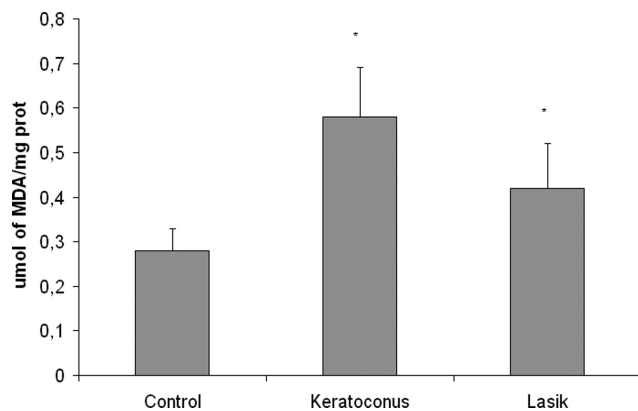


FIGURE 3. Malondialdehyde (MDA) concentration in the different groups of corneas (* $P < 0.05$).

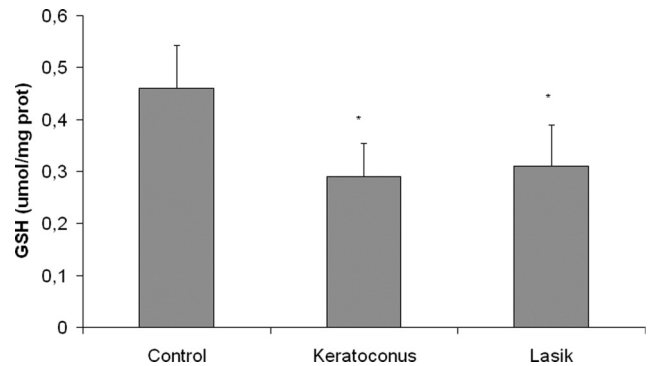


FIGURE 4. GSH content in all cornea groups studied (* $P < 0.05$).

amount of HNE-positive stained cells ($P < 0.05$) (Fig. 5A). The same observation was shown in the fluorescence-stained HNE cells (Fig. 5B). No marked difference in HNE staining could be observed between KC and LASIK groups.

DISCUSSION

Oxidative stress is a very relevant pathway in the pathologic processes associated with cardiovascular, diabetes, and retinal diseases,²³⁻²⁵ and major pathways are involved in oxidative damage including lipid peroxidation and nitric oxide metabolites.

Lipid peroxidation occurs in response to elevated levels of ROS. This can lead to cell membrane alterations with the release of reactive aldehydes, such as 4-HNE.^{9,13,26} Lipid peroxidation and reactive aldehydes are associated with chronic liver diseases, aging, amyotrophic lateral sclerosis, ischemia, and diabetes mellitus.²⁶⁻³¹ Herein, we examined lipid peroxidation and other oxidative alterations in diseased ectatic corneas and the presence of 4-HNE by immunohistochemistry.

Corneal cells are capable of expressing isoforms of the nitric oxide synthase (NOS), suggesting that significant quantities of nitric oxide (NO) are produced physiologically in the cornea.^{32,33} Because the cornea absorbs approximately 80% of the incident ultraviolet B (UVB) light,³¹ there is a potential for generating significant amounts of free radicals and ROS. Nitric oxide is a mediator in many complex cellular processes in ocular tissues.³⁴ Increased levels of nitric oxide have cytotoxic effects that are mediated by peroxynitrite,³⁵ which can be localized by the accumulation of a specific marker, nitrotyrosine.^{36,37} Recently, other studies reported that KC corneas have elevated levels of inducible nitric oxide synthase (iNOS) and accumulate nitrotyrosine when compared with normal corneas or corneas affected by other diseases.⁸ The expression of iNOS is usually associated with the generation of high levels of nitric oxide,^{38,39} which in turn can react with superoxide molecules to form peroxynitrite. In the cornea, endothelial NOS (eNOS) activity has been demonstrated in the epithelium and endothelium.⁴⁰ The NO/cGMP pathway may be important in preventing corneal edema and maintaining normal corneal thickness,⁴⁰ and nitric oxide has been shown to be involved in inflammation, angiogenesis, and the maintenance of corneal thickness.^{33,34} These previous results agree with the results obtained herein; Figure 2 shows a higher amount of total nitrites when compared with healthy corneas, and strongly supports the proposal that reactive nitrogen species (nitric oxide and peroxynitrite) might be involved in keratoconus etiopathology.

Lipid peroxidation may result from UV-induced oxidative destruction of cell membranes and the formation of cytotoxic aldehydes. These aldehydes can induce enzymatic activity im-

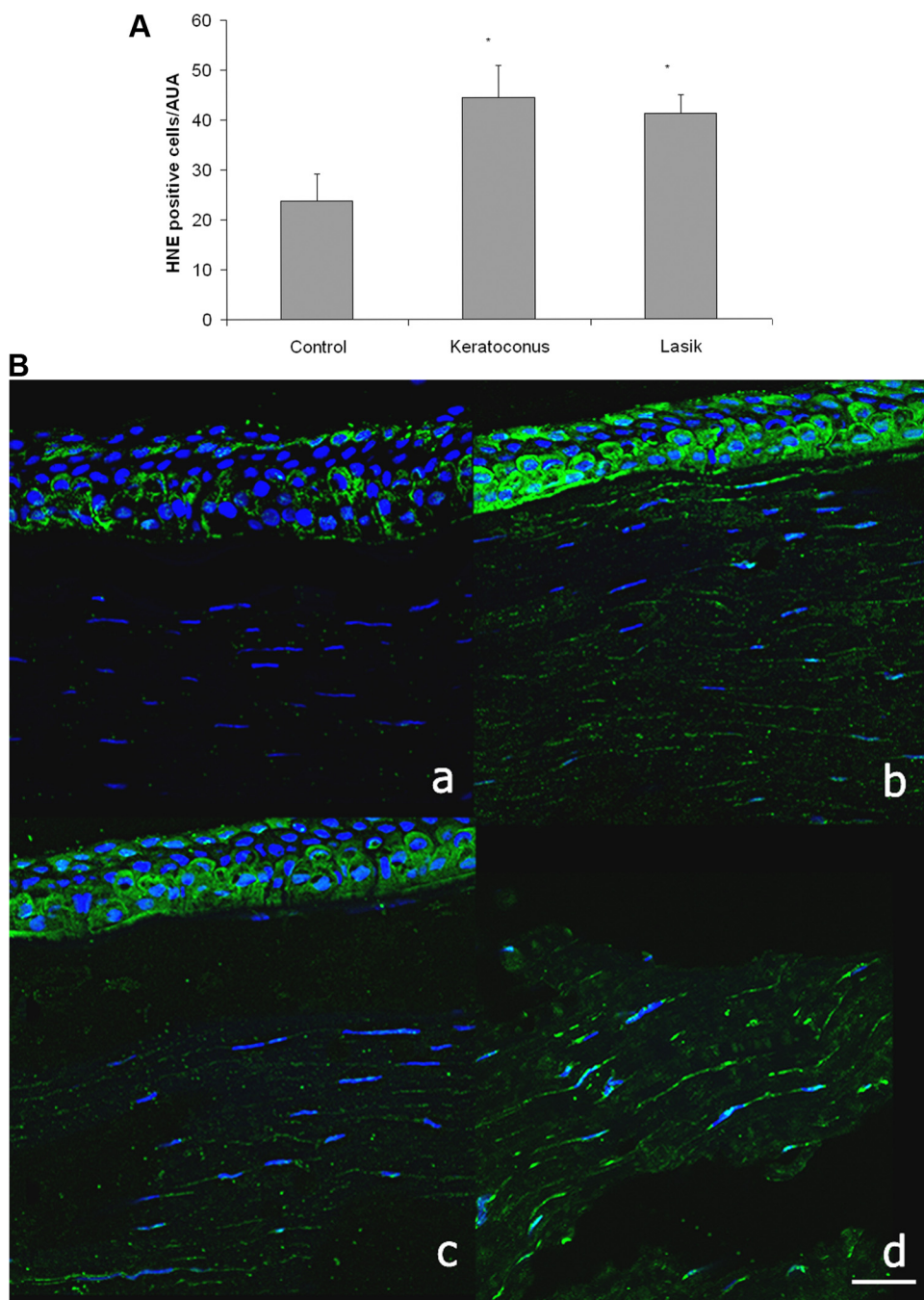


FIGURE 5. HNE immunofluorescence staining in the different corneal groups. **(A)** Number of positive HNE cells per group ($P < 0.05$). **(B)** Confocal micrographs of **(a)** normal corneas; **(b)** keratoconus corneas; and **(c)** ectasia after LASIK corneas. HNE fluorescence staining is clearly present in the stroma of corneal cells **(d)** (magnification, $\times 60$ oil objective). Scale bars, 100 μm .

pairments, inhibition of DNA/RNA/protein synthesis, and other damaging events.⁹ To our knowledge this is the first study to document the presence of the toxic aldehyde HNE in human diseased ectatic corneas and the possible relationship between KC disease and the antioxidant capacity, especially the reduced glutathione content, in this tissue. In normal corneas, high levels of aldehydedehydrogenase 3 (ALDH3) and SOD are present^{4,7,41} whose function is presumably to absorb UV and scavenge both free oxygen radicals (SOD) and the generated aldehydes (ALDH3). In this respect, a decrease of SOD1 expression⁴² has previously been demonstrated in KC corneas. Previous studies and immunohistochemical data demonstrated the presence of malondialdehyde (MDA) and nitrotyrosine (a marker for peroxynitrite, a cytotoxic product of the nitric oxide pathway) within the KC cornea compared with normal corneas or other corneal diseases.⁸

The toxicity of HNE and its mechanisms of toxicity are clearly defined in culture systems.^{19,43} Little evidence of HNE staining is observed in normal corneas; however, all the disease groups examined here showed significant and distinct patterns of 4-HNE staining (Fig. 5) confirming that HNE might play a role in this until now theoretically noninflammatory corneal disorder (i.e., keratoconus). The increased formation of total nitrates and HNE in KC corneas (and, to a lesser extent, in ectasia associated with LASIK surgery) allows the proposal of a relevant role of free radicals in their pathogenesis. In our study, KC and ectasia associated with LASIK results are similar. Ectasia is an uncommon but dreaded complication of LASIK surgery. Although the incidence of serious complications is relatively low, the visual consequences in some cases are severe.⁴⁴ Etiopathogenesis of corneal ectasia associated with LASIK is still controversial. There are some cases of post-LASIK ectasia pub-

lished in patients with apparently "normal" corneas, but in the majority of these cases, patients are found to have risk factors for ectasia, like for instance preoperative myopia greater than -8 diopters, undiagnosed previous KC, and residual stromal bed thickness after surgery $< 250 \mu\text{m}$,⁴⁵⁻⁴⁷ and so on. But several studies in relation with this controversial issue have failed to establish a consistent set of risk factors, which may reflect an inconsistent definition of this condition. LASIK substantially weakens the biomechanical strength and effective thickness of the cornea, which is similar in the KC condition. In the cases herein it was clinically difficult to know if the patients with the ectasia associated with LASIK had a KC or not before the refractive surgery. The similar results obtained in both samples regarding oxidative stress markers suggest a similar pathophysiology.

Such a mechanism could, over a period, cause alterations of the stromal collagen molecules in KC, perhaps making them more susceptible to digestion by activated enzymes, thus leading to stromal thinning. In addition to the effect on proteins, both nitric oxide (NO) and peroxynitrite are involved in multiple cytotoxic pathways. Both NO and peroxynitrite are toxic to DNA, leading to mutations and strand breaks.¹¹ In this context, it is important to note that sustained exposure to high levels of NO or peroxynitrite can trigger apoptosis,¹¹ and increased apoptotic activity has been reported in keratoconus corneas.⁴⁸ Further research on the apoptotic pathway in KC is certainly a relevant issue.

In conclusion, the data herein show unique patterns of HNE distribution in KC and ectasia after LASIK and an accumulation of products of oxidative stress (nitrates) in this tissue. The excessive amounts of both these substances and the reduction observed of the natural antioxidant defenses (GSH, antioxidant capacity) in the KC corneas support the hypothesis that oxidative damage may play a role in the pathogenesis of this corneal disease.

CONCLUSION

The increased levels of oxidative stress markers and the decreased antioxidant capacity and antioxidant defenses in keratoconus corneas indicate that oxidative stress may be involved in the development of this pathology and these results may provide new insights for the prevention and treatment of this disease in the future.

Acknowledgments

The authors thank Leticia Gómez and Diana Martínez at FOM, Valencia, Spain, for their excellent technical assistance.

References

- Rabinowitz YS. Keratoconus. *Surv Ophthalmol*. 1998;42:297-319.
- Krachmer JH, Feder RS, Belin MW. Keratoconus and related non-inflammatory corneal thinning disorders. *Surv Ophthalmol*. 1984;28:293-322.
- Seiler T, Quurke AW. Iatrogenic keratectasia after lasik in a case of forme fruste keratoconus. *J Cataract Refract Surg*. 1998;24:1007-1009.
- Gondhowiardjo TD, van Haeringen NJ, Volker-Dieben HJ, et al. Analysis of corneal aldehyde dehydrogenase patterns in pathologic corneas. *Cornea*. 1993;12:146-154.
- Gondhowiardjo TD, van Haeringen NJ. Corneal aldehyde dehydrogenase, glutathione reductase, and glutathione s-transferase in pathologic corneas. *Cornea*. 1993;12:310-314.
- Kenney MC, Brown DJ, Rajeev B. Everett Kinsey lecture. The elusive causes of keratoconus: a working hypothesis. *Clao J*. 2000;26:10-13.
- Behndig A, Karlsson K, Johansson BO, Brannstrom T, Marklund SL. Superoxide dismutase isoenzymes in the normal and diseased human cornea. *Invest Ophthalmol Vis Sci*. 2001;42:2293-2296.
- Buddi R, Lin B, Atilano SR, et al. Evidence of oxidative stress in human corneal diseases. *J Histochem Cytochem*. 2002;50:341-351.
- Esterbauer H, Schaur RJ, Zollner H. Chemistry and biochemistry of 4-hydroxynonenal, malonaldehyde and related aldehydes. *Free Radic Biol Med*. 1991;11:81-128.
- Squadrito GL, Pryor WA. Oxidative chemistry of nitric oxide: the roles of superoxide, peroxynitrite, and carbon dioxide. *Free Radic Biol Med*. 1998;25:392-403.
- Szabo C, Ohshima H. DNA damage induced by peroxynitrite: subsequent biological effects. *Nitric Oxide*. 1997;1:373-385.
- Murphy MP, Packer MA, Scarlett JL, Martin SW. Peroxynitrite: a biologically significant oxidant. *Gen Pharmacol*. 1998;31:179-186.
- Gutteridge JM, Halliwell B. The measurement and mechanism of lipid peroxidation in biological systems. *Trends Biochem Sci*. 1990;15:129-135.
- Hashimoto M, Sibata T, Wasada H, Toyokuni S, Uchida K. Structural basis of protein-bound endogenous aldehydes. Chemical and immunochemical characterizations of configurational isomers of a 4-hydroxy-2-nonenal-histidine adduct. *J Biol Chem*. 2003;278:5044-5051.
- Zhou L, Sawaguchi S, Twining SS, et al. Expression of degradative enzymes and protease inhibitors in corneas with keratoconus. *Invest Ophthalmol Vis Sci*. 1998;39:1117-1124.
- Rosenfeld ME, Palinski W, Yla-Herttuala S, Butler S, Witztum JL. Distribution of oxidation specific lipid-protein adducts and apolipoprotein b in atherosclerotic lesions of varying severity from whhl rabbits. *Arteriosclerosis*. 1990;10:336-349.
- Traverso N, Menini S, Odetti P, et al. Lipoperoxidation in hepatic subcellular compartments of diabetic rats. *Free Radic Biol Med*. 1999;26:538-547.
- Mattson MP. Modification of ion homeostasis by lipid peroxidation: roles in neuronal degeneration and adaptive plasticity. *Trends Neurosci*. 1998;21:53-57.
- Mark RJ, Pang Z, Geddes JW, Uchida K, Mattson MP. Amyloid-beta peptide impairs glucose transport in hippocampal and cortical neurons: involvement of membrane lipid peroxidation. *J Neurosci*. 1997;17:1046-1054.
- Blanc EM, Kelly JF, Mark RJ, Waeg G, Mattson MP. 4-Hydroxynonenal, an aldehydic product of lipid peroxidation, impairs signal transduction associated with muscarinic acetylcholine and metabotropic glutamate receptors: possible action on g alpha(q/11). *J Neurochem*. 1997;69:570-580.
- Bosch-Morell F, Flohé L, Marín N, Romero FJ. 4-Hydroxynonenal inhibits glutathione peroxidase: protection by glutathione. *Free Radic Biol Med*. 1999;26:1383-1387.
- Tietze F. Enzymic method for quantitative determination of nanogram amounts of total and oxidized glutathione: applications to mammalian blood and other tissues. *Anal Biochem*. 1969;27:502-522.
- Arnal E, Miranda M, Barcia J, Bosch-Morell F, Romero FJ. Lutein and docosahexaenoic acid prevent cortex lipid peroxidation in streptozotocin-induced diabetic rat cerebral cortex. *Neuroscience*. 2009;166:271-278.
- Arnal E, Miranda M, Johnsen-Soriano S, et al. Beneficial effect of docosahexaenoic acid and lutein on retinal structural, metabolic, and functional abnormalities in diabetic rats. *Curr Eye Res*. 2009;34:928-938.
- Saleh D, Barnes PJ, Giaid A. Increased production of the potent oxidant peroxynitrite in the lungs of patients with idiopathic pulmonary fibrosis. *Am J Respir Crit Care Med*. 1997;155:1763-1769.
- Halliwell B. Reactive oxygen species in living systems: source, biochemistry, and role in human disease. *Am J Med*. 1991;91:14S-22S.
- Paradis V, Kollinger M, Fabre M, et al. In situ detection of lipid peroxidation by-products in chronic liver diseases. *Hepatology*. 1997;26:135-142.
- Yoshino H, Hattori N, Urabe T, et al. Postischemic accumulation of lipid peroxidation products in the rat brain: immunohistochemical detection of 4-hydroxy-2-nonenal modified proteins. *Brain Res*. 1997;767:81-86.

29. Ohhira M, Ohtake T, Matsumoto A, et al. Immunohistochemical detection of 4-hydroxy-2-nonenal-modified-protein adducts in human alcoholic liver diseases. *Alcohol Clin Exp Res*. 1998;22:145S-149S.
30. Pedersen WA, Fu W, Keller JN, et al. Protein modification by the lipid peroxidation product 4-hydroxynonenal in the spinal cords of amyotrophic lateral sclerosis patients. *Ann Neurol*. 1998;44:819-824.
31. Cross AH, Manning PT, Stern MK, Misko TP. Evidence for the production of peroxynitrite in inflammatory CNS demyelination. *J Neuroimmunol*. 1997;80:121-130.
32. Dighiero P, Behar-Cohen F, Courtois Y, Goureau O. Expression of inducible nitric oxide synthase in bovine corneal endothelial cells and keratocytes in vitro after lipopolysaccharide and cytokines stimulation. *Invest Ophthalmol Vis Sci*. 1997;38:2045-2052.
33. McMenamin PG, Crewe JM. Cellular localisation and dynamics of nitric oxide synthase expression in the rat anterior segment during endotoxin-induced uveitis. *Exp Eye Res*. 1997;65:157-164.
34. Becquet F, Courtois Y, Goureau O. Nitric oxide in the eye: multifaceted roles and diverse outcomes. *Surv Ophthalmol*. 1997;42:71-82.
35. Beckman JS. Oxidative damage and tyrosine nitration from peroxynitrite. *Chem Res Toxicol*. 1996;9:836-844.
36. Kooy NW, Royall JA, Ischiropoulos H. Oxidation of 2',7'-dichlorofluorescein by peroxynitrite. *Free Radic Res*. 1997;27:245-254.
37. Kooy NW, Royall JA, Ye YZ, Kelly DR, Beckman JS. Evidence for in vivo peroxynitrite production in human acute lung injury. *Am J Respir Crit Care Med*. 1995;151:1250-1254.
38. Porasuphatana S, Tsai P, Rosen GM. The generation of free radicals by nitric oxide synthase. *Comp Biochem Physiol C Toxicol Pharmacol*. 2003;134:281-289.
39. Mikkelsen RB, Wardman P. Biological chemistry of reactive oxygen and nitrogen and radiation-induced signal transduction mechanisms. *Oncogene*. 2003;22:5734-5754.
40. Yanagiya N, Akiba J, Kado M, et al. Transient corneal edema induced by nitric oxide synthase inhibition. *Nitric Oxide*. 1997;1:397-403.
41. Pappa A, Sophos NA, Vasilioi V. Corneal and stomach expression of aldehyde dehydrogenases: from fish to mammals. *Chem Biol Interact*. 2001;130-132:181-191.
42. Udar N, Atilano SR, Brown DJ, et al. SOD1: a candidate gene for keratoconus. *Invest Ophthalmol Vis Sci*. 2006;47:3345-3351.
43. Kruman I, Bruce-Keller AJ, Bredesen D, Waeg G, Mattson MP. Evidence that 4-hydroxynonenal mediates oxidative stress-induced neuronal apoptosis. *J Neurosci*. 1997;17:5089-5100.
44. Twa MD, Nichols JJ, Joslin CE, et al. Characteristics of corneal ectasia after LASIK for myopia. *Cornea*. 2004;23:447-457.
45. Tuli SS, Iyer S. Delayed ectasia following LASIK with no risk factors: is a 300-um stromal bed enough?. *J Refract Surg*. 2007;23:620-622.
46. Randleman JB, Russell B, Ward MA, Thompson KP, Stulting RD. Risk factors and prognosis for corneal ectasia after LASIK. *Ophthalmology*. 2003;110:267-275.
47. Randleman JB, Woodward M, Lynn ML, Stulting RD. Risk assessment for ectasia after corneal refractive surgery. *Ophthalmology*. 2008;115:37-50.
48. Kim WJ, Rabinowitz YS, Meisler DM, Wilson SE. Keratocyte apoptosis associated with keratoconus. *Exp Eye Res*. 1999;69:475-481.