

## AN ELECTROMYOGRAPHIC ASSESSMENT OF F-WAVE IN CARPAL TUNNEL SYNDROME: CORRELATION STUDY WITH MRI CARPUS AND CERVICAL SPINE

MOHAMMAD ISMAIL ABDUL-KARIEM, SAMI ABDUL-HAKIEM MUSTAFA,  
HEGAZY MOGAHED AL-TAMIMY AND ABDELLAH NAZIER YASSIEN\*

*Rheumatology & Rehabilitation and Diagnostic Radiology\**  
*Departments, Al-Azhar University Faculty of Medicine*

**KEY WORDS:** CARPAL TUNNEL SYNDROME, F WAVE, ELECTRODIAGNOSIS,  
MRI.

### ABSTRACT

**Objectives:** *In this study we have analyzed the effect C.T.S. of focal median nerve injury carpal tunnel syndrome (CT) on F wave. We have determined the F wave parameters in C.T.S. patients and evaluate the relationship between F wave and severity of injury of CT and MRI finding of the wrist and cervical spine finding.*

**Methodology:** *The study was conducted on all patients(104) referred from out-patients clinic in the same hospital to electrophysiologic examination in Rheumatology, Physical Medicine and Rehabilitation Dep. and Radiology department, Al Hussein University Hospital as clinical assessed as a carpal tunnel syndrome, Standard electro diagnostic study was made on all of them bilaterally. MRI of carpal tunnel and cervical spine done for selected patients with C.T. S. According to F wave parameters, patients were divided into three groups, absent F-wave, abnormally prolonged F-wave and normal F-wave. According to electrophysiological testing results, the patients were grouped into mild, moderate or severe C.T. S.*

**Results:** *Absent F wave was presented in 8 hands (7.7%), prolonged latency in 9 hands (8.6%) and normal F wave in 87 of 104 hands (83.7%). the mean F wave latency were statistically different between the C.T.S. patients and the normal values (CI 95%,  $p < 0.0001$ ). Also, the entire F wave latencies*

were significantly prolonged in the severely injured group ( $p=0.0001$ ).

**Discussion:** F wave determination could show injury to proximal and also severe injury to distal parts of median nerve and especially axonal injury. According to abnormalities of this test the surgical release of nerve for prevention of irreversible changes must be considered. Results of our study supported the adding of F wave parameters study to standardize electrophysiological evaluation of C.T. S.

## INTRODUCTION

Carpal tunnel syndrome (C.T.S.) is a common clinical problem and frequently requires surgical release and sometimes starts as primarily (idiopathic) C.T.S. or associated with some disease activity that doesn't need surgical interference.

Numerous nerve conduction tests are used for the electrodiagnosis of carpal tunnel syndrome (C.T.S.), with a wide range of sensitivity and specificity reported for each test in clinical studies.

Distal motor latency: Stimulate the median nerve at the wrist and record at the abductor pollicis brevis muscle. A markedly prolonged distal latency may be measured. However, in over 50% of patients with C.T.S., distal median motor latency is within the normal limit (*Preston. 1999*).

The diagnosis of carpal tunnel syndrome (C.T.S.) is based on sensory nerve conduction over palm-wrist segment and terminal latency of median nerve. The median orthodromic sensory latencies were prolonged and sensory nerve action potential amplitude abnormalities were seen in patients with carpal tunnel syndrome (*Murthy & Meena 1999*).

Classic abnormalities in these tests are abnormal sensory conduction over the tested segments and prolonged terminal latency. With more severe C.T.S. cases, Electro-diagnostic study usually shows some secondary axonal loss. Axonal injury is reflected in reduced amplitude and area of the compound motor unit action potential (CMAP) in response to the stimulation at any point along the nerve.

The F-wave is a long latency muscle action potential seen after supra-maximal stimulation to a nerve. Although elicitable in a variety of muscles, it is the best obtained in the small foot and hand muscles. It is generally accepted that the F-wave is elicited when the stimulus travels antidromically along the motor fibers and reaches the anterior horn cell at a

critical time to depolarize it. The response is then fired down along the axon and causes a minimal contraction of the muscle. Conventionally, ten to twenty F-waves are obtained and the shortest latency F-wave among them is used (Cvetkovic & Petkovic 2003).

Electrophysiological examination of about half of the symptomatic persons showed median neuropathy (defined as distal motor latency above 4.2 ms or wrist-digit sensory latency above 3.7 ms) in only 18% of those with symptoms of C.T.S. (Ferry *et al.*, 1998).

F-wave is a late response recorded from muscle elicited by electric impulse conveyed antidromically to alpha-motor neurons of the spinal cord. F-wave latency and frequency are assessed in routine electroneurography providing information of conduction in the proximal segment of the nerves. F-wave amplitude is rarely analyzed, while it could add valuable information on excitability of motor neurons in different disease states. This study was conducted to determine whether F-wave amplitude is indicative of the level of the peripheral nervous system lesion (Kostera-Pruszczyk, *et al.*, 2004).

F waves are not sensitive in detecting compressive neuropathy. If the stimulus is applied distal to the lesion, the F wave latencies may be prolonged, establishing the presence of a lesion, but the result does not indicate the location because of the long length of the nerve included in the conduction pathway (Jablecki *et al.*, 2002).

The study showed that slowing of median nerve proximal motor conduction in patients with carpal tunnel syndrome (C.T. S) could be considered as an indicator of an additional proximal lesion (double crush syndrome) median nerve proximal conduction velocity slowing in patients with C.T.S. is restricted to the fibers that distally pass through the carpal tunnel and does not necessarily imply an additional proximal lesion (Anastasopoulos, & Chroni., 1997).

## **MATERIALS AND METHODS**

All patients' and controls were subject to the following electro-diagnostic test of median (orthodromic) nerve conduction studies the apparatus used was Medelec, Working, Surgery and England. Serial No.3253 and MRI of cervical and carpal tunnel imaging:

### **MRI apparatus:**

MRI was performed on closed 1.5 Tesla superconducting magnet (Magnetum vision: Siemens) Using surface coil on the receive mode.

### **Technique:**

**Wrist protocol:** 1-coronal T2 & STATA images

2-axial T1 & T2WI

**Cervical protocol:** 1-Sagittal T1&T2WI

2-Axial Gradient Echo-Image

In this study we analyzed the effect C.T.S. of focal median nerve injury on F wave and evaluated the relationship between F wave and severity of injury and its correlation with MRI of carpal tunnel and cervical spine.

### **Exclusion criteria:**

All patients were excluded from the study that has previous surgery for C.T. S, and / or clinical, radiological findings of cervical radiculopathy and every risk factor for neuropathy (i.e. diabetes mellitus, Hypothyroidism, rheumatoid arthritis, chronic renal failure, connective tissue disorders).

### **Inclusion criteria:**

The symptomatic persons were examined by the same physician who, based only on the history and clinical findings, diagnosed each person as having clinically C.T.S. or not. The diagnosis of clinically C.T.S. required the presence of recurring nighttime or activity-related numbness or tingling involving the palmar aspect of at least two radial fingers. The presence of positive Tinel or Phalen's test and of median nerve sensory or motor deficit was considered supportive of the diagnosis. The control persons were examined to verify the absence of hand symptoms.

All of the patients had standard electrodiagnostic study was made and using the criteria of the American Association of Electrodiagnostic Medicine (AAEM). All patients were studied bilaterally. Two of the following criteria for abnormal values were accepted to identify the patients with C.T.S.:

1) Antidromic sensory conduction velocity for the wrist-second digit segment less than 48.2 m/s,

2) The difference between median and ulnar sensory nerve distal latencies with recording from the fourth digit (recording-stimulation distance was kept 14 cm) exceeding 0.5 ms,

3) Distal motor latency to abductor pollicis brevis muscle greater than 4.2 ms.

According to F wave parameters, patients were divided into three groups, absent F-wave, abnormally prolonged F-wave and normal F-wave. According to following:

**Mild C.T.S.:** Prolongation of median distal sensory latency  $>3.5$  ms or relative prolongation of median compared to ulnar distal sensory latencies over identical distances.

**Moderate C.T.S.:** Reduced median SNAP amplitude ( $<50\%$  compared to unaffected side or  $<25$ mv) or prolonged median motor distal  $>4.5$  ms.

**Severe C.T.S.:** Reduced median CMAP amplitude ( $<50\%$  compared to unaffected side or  $<4$ mv) denervation of median innervated muscles on needle exam (*Aurora et al., 1998*).

According to AAN (American Academy Neurology) diagnostic features includes parameters studied included:

1. Motor Conduction Studies:

- A) Motor distal latencies of median and ulnar,
- B) Amplitude of the negative component of compound action potential (CMAP),
- C) Median and ulnar conduction velocities

2. Sensory Conduction Studies:

- A) Sensory onset latencies of median and ulnar nerves by orthodromic stimulation,
- B) Peak to peak amplitude of sensory nerve action potential (SNAP).

3. Palm-wrist conduction studies:

The median and ulnar nerves were stimulated in the palm between 2nd and 3rd and 4th and 5th metacarpal bones respectively at a point, 8 cm distal to the recording electrodes. The onset latencies were measured both for median and ulnar nerves. Median and ulnar nerve palmer latency differences were also calculated.

4. EMG of abductor pollicis brevis and first dorsal interosseous was done if indicated.

The criteria for electrodiagnosis of C.T.S. included:

- 1. Abnormal sensory conduction studies across the wrist of the median nerve in the symptomatic limb (sensory latency  $> 2$ SD mean of control, and amplitude  $<2$ SD mean of control).

2. Abnormal median sensory nerve conduction across the wrist over a short (8cm) conduction distance or abnormal median sensory conduction across the wrist when compared to ulnar nerve conduction ( $>2SD$  of control).

3. Abnormal median motor latency in the symptomatic hand ( $>2SD$  of control) was also considered, if the patient fulfilled any one of the above two criteria (Jablecki, et al., 1993).

## RESULTS

Demographic data in patients with carpal tunnel syndrome and control group showed that there is no significant differences between patients and control, group where  $p>0.05$  table 1.

Table (1): Demographic data in patients with carpal tunnel syndrome and control group.

	Cases Mean $\pm$ S D	Control Mean $\pm$ S D	T-Test	p value
Age (ys)	28.10 $\pm$ 10.27	26.45 $\pm$ 2.54	1.69	NS
Weight (kg)	68.10 $\pm$ 11.37	74.24 $\pm$ 5.24	1.59	NS
Height (cm)	162.30 $\pm$ 8.19	165.54 $\pm$ 7.58	0.87	NS
Duration (Ms)	4.70 $\pm$ 3.60	0	0	

NS = non significant differences where  $p>0.05$ .

Table (2): Clinical data in patient and control group.

	Mean $\pm$ S D cases	Mean $\pm$ S D control	T-Test	P value
ESR	25.50 $\pm$ 14.66	8.25 $\pm$ 6.88	3.25	$<0.04^*$
WBCS	7.69 $\pm$ 1.43	4.76 $\pm$ 1.44	2.98	$<0.05^*$
RBCS	4.76 $\pm$ 0.51	4.88 $\pm$ 1.54	1.87	NS
HB	13.34 $\pm$ 1.54	13.8 $\pm$ 1.68	0.44	NS
Platelets	326.45 $\pm$ 54.28	245.68 $\pm$ 44.65	1.89	NS
FBS	75.24 $\pm$ 13.57	67.59 $\pm$ 14.71	0.97	NS
PPBS	102.79 $\pm$ 14.57	98.74 $\pm$ 8.46	1.07	NS
RF	0	0	-	-

NS = non significant differences where  $p>0.05$ .

\* = significant differences where  $p<0.05$ .

As regard to laboratory finding in the study group it was showed that there was significant differences between patients and control groups in the ESR and WBCS count ( $p<0.05$  table 2). While, RBCS, HB, Platelet, FBS

and PPBS there was no significant differences between both groups where  $p > 0.05$ .

On neurological examination, a total of 46 hands (65.71%) out of 70 hands had positive Tinel's sign and 55 hands (78.57%) had positive Phalen's test. In 29 hands (41.43%) C.T.S. was mild, in 24 hands (34.28%) moderate and in 17 hands (24.29%) it was severe. Among 35 studied patients, 29 (82.85%) were female and 6 (17.15%) were male. Absent F wave was resented in 8 hands (11.42%), prolonged latency in 9 hands (12.86%) and normal f wave in 53 of 70 hands (75.72%). The mean F wave latency was  $27.15 \pm 2.9$  msec.

Table (3): Electromyographic data in patients and control group.

	Mean $\pm$ S D cases	Mean $\pm$ S D control	T-Test	P value
Amplitude	7.16 $\pm$ 1.25	2.71 $\pm$ 1.13	8.34	0.01**
Distal Latency	6.35 $\pm$ 1.70	3.07 $\pm$ 0.49	4.65	0.01**
F- wave	36.02 $\pm$ 9.37	24.06 $\pm$ 1.43	2.78	0.04*
Mild	28.36 $\pm$ 11.36	24.6 $\pm$ 1.30	2.57	<0.05*
Moderate	37.51 $\pm$ 2.41	23.8 $\pm$ 1.50	3.98	0.02**
Sever	42.2 $\pm$ 14.35	23.8 $\pm$ 1.50	4.66	0.01**

Table 3: showed that the normal mean F wave latency calculated  $24.06 \pm 1.43$  for control and  $36.02 \pm 9.37$  msec for patients with C.T. S. The mean F wave latency were statistically different between the C.T.S. patients and the normal values (CI 95%,  $p < 0.04$ ). There was significant mean F wave latency in hands with mild C.T.S. was  $28.36 \pm 11.36$  msec and the normal mean F wave for this group was  $24.6 \pm 1.30$  msec.

These data for moderate C.T.S. group was  $37.51 \pm 2.41$  msec and  $24.1 \pm 1.53$  msec. All of the F wave latencies were significantly prolonged in the severely injured group  $42.2 \pm 14.35$  msec, normal mean calculated for this group was  $23.8 \pm 1.5$  msec) compared to the moderate and mild injuries ( $p = 0.01$ ). Table 4: showed the relation between MRI finding of cervical and carpal tunnel in patients with C.T.S. with electromyographic finding revealed that there no

Table (4): Relation between MRI and EMG of C.T.S.

	Latency	p value	Amplitude	p value	F-wave	p value
MRI	0.76	NS	3.75	NS	4.25	NS
RF	0.44	NS	10.14	0.01**	14.25	0.01**
CRP	12.45	0.01**	12.8	0.01**	13.54	0.01**
ESR	25.56	0.01**	13.56	0.01**	14.57	0.01**

There was significant relation between MRI and EMG of C.T.S. where  $p > 0.05$ . But electromyography had a positive relation laboratory finding where  $P < 0.05$  table 4.

**MRI Results:**

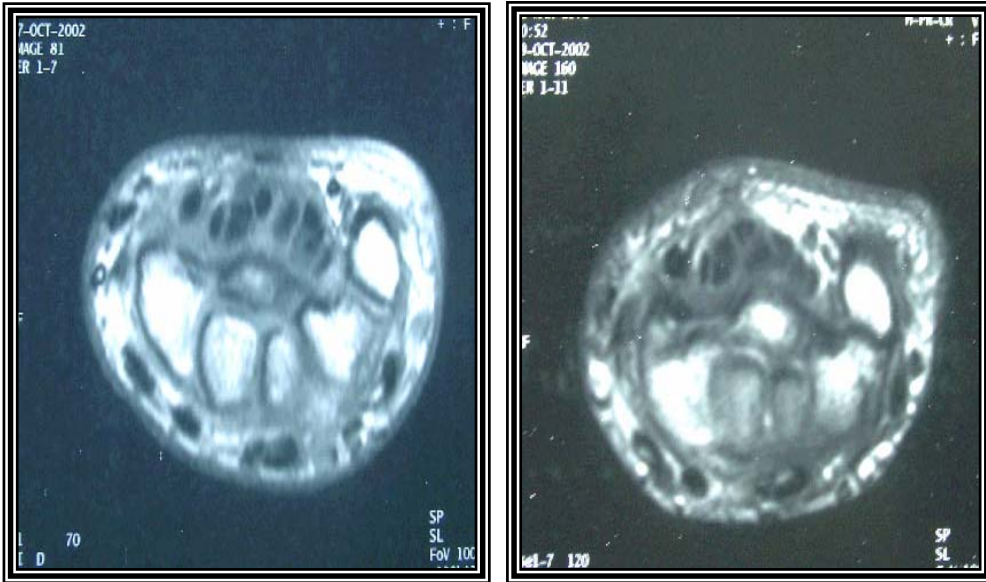


Fig. (1 a): bilateral foraminal narrowing with C.T. S.

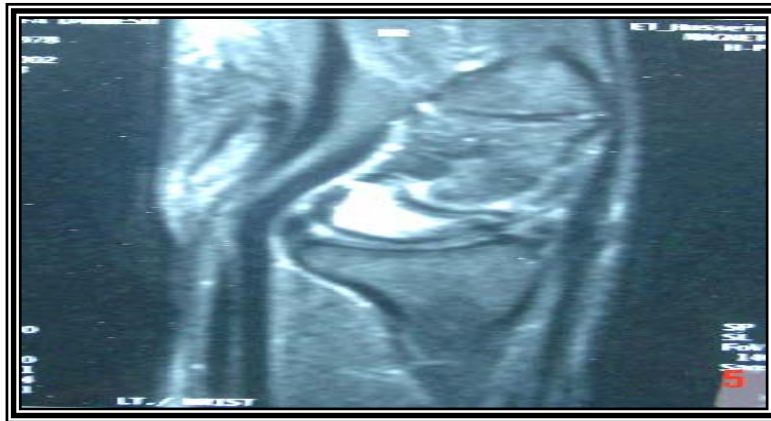

Fig. (1 b): bilateral foraminal narrowing with C.T. S.



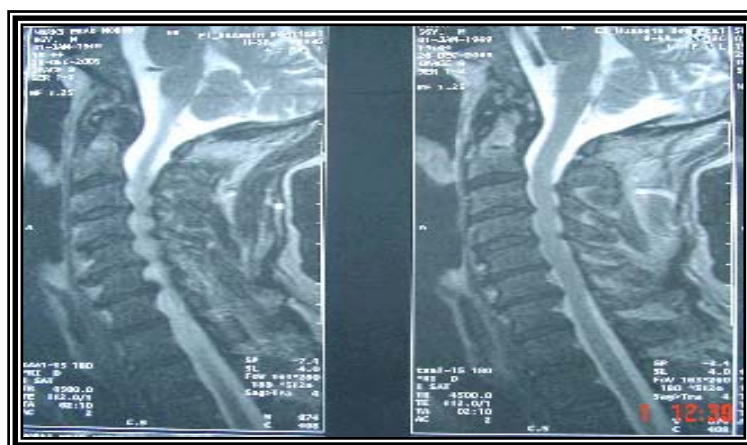

Fig. (2): MRI of carpal tunnel with small diameter Posterior disc protrusion/osteophyte complex and degenerative.

## DISCUSSION

In this study the analyses of the effect of C.T.S. of focal median nerve injury on F wave and evaluated the relationship between MRI of carpal tunnel, cervical spine and F wave and severity of injury.

F-wave conduction time, F-wave conduction velocity, and F-ratio in the localization of level of lesion of peripheral motor neurons *Cvetkovic and Petkovic (2003)*.

The median nerve MRI imaging in the C.T.S. patients emitted a higher signal compared with the controls, and also, the differences in the amplitude and the distal latency of the median sensory branch, as well as in the amplitude and the F-wave latencies of the median motor branch than control group.  $p < 0.05$ .; There was no difference in the size of the carpal tunnel in women with idiopathic C.T.S. compared with healthy controls, as the focal narrowest point was equally located in both groups near the canal outlet (*Pierre-Jerome et al., 1997*).

The median orthodromic sensory latencies were prolonged and sensory nerve action potential amplitude abnormalities were seen in patients with carpal tunnel syndrome. Prolongation of the conduction across the wrist in the median nerve was seen correlate with MRI of the wrist joint (*Murthy & Meena 1999*).

*Anastasopoulos & Chroni (1997)*, give another explanation to F wave in which Slowing of median nerve proximal motor conduction in

patients with carpal tunnel syndrome (C.T. S) could be considered as an indicator of an additional proximal lesion (double crush syndrome) median nerve proximal conduction velocity slowing in patients with C.T.S. is restricted to the fibers that distally pass through the carpal tunnel and does not necessarily imply an additional proximal lesion

In C.T. S, we can determine the severity and duration of nerve compression and the degree of demyelization and axonal degeneration by comparing responses evoked by stimulation proximal and distal to lesion site

*Ferry, et al. (1998)*, reported that conduction block is a sign of demyelinating injury, and this finding suggests that a conservative treatment such as splinting or steroid injections could be a proper method for patient managing, but axonal loss (with prominent decrease in CMAP amplitude) is a clue to necessary surgical release of nerve

The results of *Fisher & Hoffen (1997)* study support indications and information about the type of affected nerve fibers of the median nerve and injury severity are important, it has significant correlation with axonal injury that we called "severe" injury. The different effect C.T.S. of demyelinating and axonal injury on F-waves and suggest physiological compensation in those hands with the more pronounced neuropathic dysfunction.

*Mesrati, & Vecchierini et al. (2004)* stated that F-waves are particularly useful for the diagnosis of polyneuropathies at a very early stage and for the diagnosis of proximal nerve lesions. F-wave recording is indeed one of the rare methods in routine examination allowing at the same time the functional assessment of motor fibers on their proximal segment, and contributing to the evaluation of motor-neuronal excitability. So, F wave determination, as a simple and valuable method, allows the discrimination between demyelinating injury and axonal degeneration and increases the diagnostic yield in C.T.S...

Results of our study supported the adding of F wave parameters study to standardize electrophysiological evaluation of C.T.S... It helps for distinguishing C.T.S. severity.

*Musluoglu et al. (2004)* stated that MRI provides anatomical information that correlate well with electrophysiological findings in regard of the severity of median nerve compression.

*Bak et al. (1997)*, neither symptoms nor electrophysiological findings in C.T.S. were related to specific MRI parameters

*Andre et al. (1999)*, there is discordance between clinical and EMG findings, MRI is helpful to identify patients who would benefit from surgical intervention.

*Zagnoli et al. (1999)*, support our results (When electrodiagnostic abnormalities suggest more severe disease than expected or are otherwise discordant with clinical findings, demonstration by magnetic resonance imaging of high median nerve signal and/or median nerve enlargement may help to select those patients most likely to benefit from surgical treatment.

*Horch et al. (1997)*, MRI is accurate and reliable for diagnosis and postoperative follow-up of carpal tunnel syndrome. In cases with obvious clinical symptoms and yet not measurably impaired median nerve conduction values, it may be helpful in making a decision for surgical decompression. The study concluded that F wave prolongation in association with axonal injury.

As a conclusion, F wave determination could show injury to proximal and also severe injury to distal parts of median nerve and especially axonal injury. According to abnormalities of this test and other symptoms and signs, the surgical release of nerve for prevention of irreversible changes could be considered.

## REFERENCES

- Anastasopoulos D, Chroni E (1997):** Effect of carpal tunnel syndrome on median nerve proximal conduction estimated by F-waves. *J. Clin Neurophysiol*; 14 (1):63-7
- Andre V, Zagnoli F, Andre M, Le Dreff P, Bellard S, Garcia JF (1999):** Clinical, electrophysiological and MRI correlations in carpal tunnel syndrome. *J. Radiol* 80 (7):721-6. (Abstract).
- Aurora SK, Ahmad BK, Aurora TK (1998):** Silent Period Abnormalities in Carpal Tunnel Syndrome. *Muscle Nerve* 21:1213-1215.
- Bak L, Bak S, Gaster P, Mathiesen F, Ellemann K, Bertheussen K, Zeeberg L (1997):** MR imaging of the wrist in carpal tunnel syndrome. *Acta Radiol. Nov* 38 (6):1050-2.
- Cvetkovic B, Petkovic S (2003):** Diagnostic value of the F-reaction in localization of the level of peripheral motor neuron lesions *Vojnosanit P. Nov-Dec* 60 (6):677-82 (abstract).
- Ferry S, Silman AJ, Pritchard T, Keenan J, Croft P (1998):** The association between different patterns of hand symptoms and objective evidence of median nerve compression: a community-based survey. *Arthritis Rheum* 41:720-724.
- Fisher MA, Hoffen B (1997):** F-wave analysis in patients with carpal tunnel syndrome. *Electromyogr Clin Neurophysiol* 37 (1):27-31.

- Horch RE, Allmann KH, Laubenberger J, Langer M, Stark GB (1997):** Median nerve compression can be detected by magnetic resonance imaging of the carpal tunnel. *Neurosurgery* 1; 41 (1):76-82; discussion 82-3.
- Jablecki CK, Andary MT, Floeter MK, Miller RG, Quartly CA, Vennix MJ, Wilson JR (2002):** American association of Electrodiagnostic Medicine; American Academy of Neurology; American Academy of Physical Medicine and Rehabilitation. Practice parameter: Electrodiagnostic studies in carpal tunnel syndrome. *Neurology* 58:1589-1592.
- Jablecki CK, Andary MT, So YT (1993):** Practice parameters for electrodiagnostic studies in carpal tunnel syndrome: Summary statement. *Neurology* 1993; 43: 2404-2405.
- Kimura J (1989):** Electro diagnosis in diseases of nerve and muscle principles and practice. 2nd Edition Philadelphia, FA Davis, 105-109
- Kostera-Pruszczyk A, Rowinska-Marcinska K, Owsiak S, Jezierski P, Emeryk-Szajewska B (2004):** F-wave amplitude in peripheral nervous system lesions *Neurol Neurochir Pol.* Nov-Dec 38 (6):465-70 (abstract).
- Mesrati F, Vecchierini MF, F-waves: neurophysiology and clinical value (2004):** *Neurophysiol Clin.* Dec 34 (5):217-43. Epub Oct 19.
- Murthy J, Meena M (1999):** Carpal tunnel syndrome - electrodiagnostic aspect of fifty seven symptomatic hands. Volume 47: 4 P: 272-5
- Musluoglu L, Celik M, Tabak H, Forta H (2004):** Clinical, electrophysiological and magnetic resonance imaging findings in carpal tunnel syndrome. *Electromyogr Clin Neurophysiol.* 2004 Apr-May 44 (3):161-5.
- Oh SJ (2004):** *Clinical Electromyography, Nerve Conduction Studies.* 3rd ed. Lippincott-Williams and Wilkins. 003; p 88.
- Ozge A, Comelekoglu U, Tataroglu C, Yalcinkaya DE, Akyatan MN (2002):** Subtypes of carpal tunnel syndrome: median nerve F wave parameters. *Clin Neurol Neurosurg.* Sep 104 (4):322-7.
- Pierre-Jerome C, Bekkelund SI, Mellgren SI, Nordstrom R (1997):** Quantitative MRI and electrophysiology of preoperative carpal tunnel syndrome in a female population. *Ergonomics.* Jun 40 (6):642-9.
- Preston DC (1999):** Distal median neuropathies. *Neurol Clin* Aug 17 (3): 407-24
- Sharma KR, Rotta F, Romano J, Ayyar DR (2001):** Early diagnosis of carpal tunnel syndrome: comparison of digit 1 with wrist and distoproximal ratio. *Neurol Clin Neurophysiol.* (2):2-10.
- Zagnoli F, Andre V, Le Dreff P, Garcia JF, Bellard S (1999):** Idiopathic carpal tunnel syndrome. Clinical, electrodiagnostic, and magnetic resonance imaging correlations. *Rev Rheum Engl Ed.* Apr 66 (4):192-200

## تقييم الحزمة الموجية اف باستخدام جهاز رسم العضلات فى حالات متلازمة إختناق العصب الأوسط مقارنة مع الرنين المغناطيسي للفقرات العنقية

محمد إسماعيل عبد الكريم ، سامي عبد الحكيم مصطفى، حجازي مجاهد التميمي و  
عبدالله نظير ياسين \*

قسمي الروماتيزم والتأهيل و الأشعة التشخيصية\*، كلية الطب، جامعة الأزهر

**الغرض من البحث:** تحديد تأثير إصابة العصب الأوسط على الحزمة الموجية اف وتقييم العلاقة بينها و إصابة العصب الأوسط مقارنة مع الرنين المغناطيسي للفقرات العنقية ومفصل الراسخ.

**طريقة البحث:** أجرى هذا البحث على مائة وأربعة مريضا يعانون من إختناق العصب الأوسط وتم دراسة الأعصاب الفسيولوجية وتقييم الحزمة الموجية اف (طبيعية، طويلة وغير موجودة) وتم عمل الرنين المغناطيسي للفقرات العنقية ومفصل الراسخ وتم تقييم الحزمة الموجية اف بعد دراسة الأعصاب الفسيولوجية إلى بسيطة، متوسطة ومتقدمة.

**النتائج:** وجد أن الحزمة الموجية اف غير موجودة في ثمانية مرضي وطويلة في تسعة مرضي وطبيعية في سبعة وثمانين مريضا. توجد علاقة ذات قيمة إحصائية بين الحزمة الموجية اف الطويلة و متلازمة إختناق العصب الأوسط المتقدمة.