

Haematological Manifestations in Systemic Lupus Erythematosus

Nahid Janoudi and Ekhlas Samir Bardisi
*KFSH&RC Jeddah
Saudi Arabia*

1. Introduction

Systemic lupus erythematosus (SLE) is the most common multisystem connective tissue disease. It is characterised by a wide variety of clinical features and presence of numerous auto-antibodies, circulating immune complexes and widespread immunologically determined tissue damage [1]. Hematological abnormalities are common in SLE. All the cellular elements of the blood & coagulation pathway can be affected in SLE patients.

The major hematological manifestations of SLE are anemia, leucopenia, thrombocytopenia, and antiphospholipid syndrome (APS). Hematological abnormalities in patients with this disease require careful long-term monitoring and prompt therapeutic intervention.

Throughout the chapter we will analyze each abnormality, enumerate and explain the causes of each one and discuss an approach to the management.

2. Anemia in systemic lupus erythematosus

Anemia is found in about 50% of SLE patients, many mechanisms contribute to the development of anemia, including inflammation, renal insufficiency, blood loss, dietary insufficiency, medications, haemolysis, infection, hypersplenism, myelofibrosis, myelodysplasia, and aplastic anemia that is suspected to have an autoimmune pathogenesis [2-9] table 1.

2.1 Anemia of chronic disease

A frequent cause of anemia in SLE is suppressed erythropoiesis from chronic inflammation (anemia of chronic disease or anemia of chronic inflammation), being the most common form (60 to 80 %) [5]. this type of anemia is normocytic and normochromic with a relatively low reticulocyte count. Although serum iron levels may be reduced, bone marrow iron stores are adequate and the serum ferritin concentration is elevated. In the absence of either symptoms attributable to anemia (eg: dyspnea on exertion, easy fatigability) or renal insufficiency, anemia of chronic inflammation does not require specific treatment.

Patients with symptoms due to anemia of chronic inflammation, who have no other definite indication for glucocorticoid or other immunosuppressive therapy, may be given a trial of an agent that promotes erythropoiesis. The following two agents are an example:

Anemia of chronic disease
Blood loss
Gastrointestinal loss, menorrhagias
Nutritional deficiencies
Iron, folate, B12
Immune mediated
Haemolysis, red cell aplasia, haemophagocytosis, aplastic anaemia, pernicious anaemia
Myelofibrosis
Uremia
Treatment induced
Microangiopathic haemolysis
Disseminated intravascular coagulation, thrombotic thrombocytopenic purpura, drugs
Hypersplenism
Infection
Myelodysplasia

Table 1. Causes of anemia in patients with SLE

- Epoetin alfa (recombinant human erythropoietin)
- Darbepoetin alfa, a unique molecule that stimulates erythropoiesis with a longer half-life than recombinant human erythropoietin.

In one study that assessed the response to erythropoietin in patients with SLE and anemia of chronic inflammation, 58 percent had an adequate response to erythropoietin supplementation [7].

Patients who are symptomatically anemic, having signs of active inflammations, and do not respond to an agent that promotes erythropoiesis, often improve when glucocorticoids are used in high doses (1 mg/kg per day of prednisone or its equivalent in divided doses). If, after approximately one month of treatment, the response is unsatisfactory (eg, hemoglobin still <11 g/dL) the dose of glucocorticoids should be rapidly reduced, and discontinued if there is no other indication for their use. If there is a response, the dose should be tapered as rapidly as possible to the lowest dose that maintains the improvement. Immunosuppressive agents also may help, but carry a risk of further bone marrow suppression.

2.2 Renal insufficiency

An inappropriately low level of erythropoietin is a hallmark of anemia due to renal insufficiency. The primary cause of anemia in this setting is typically deficient production of erythropoietin by the diseased kidneys. In the patient with SLE, anemia, and renal insufficiency who does not have other evidence of active inflammation, administration of

erythropoiesis-stimulating agents may be indicated when the anemia is causing symptoms or the hemoglobin concentration is <11 gm/dL.

2.3 Iron deficiency anemia

Anemia may reflect acute or chronic blood loss from the gastrointestinal tract, usually secondary to medications (nonsteroidal antiinflammatory drugs or steroids), or may be due to excessive menstrual bleeding. Iron deficiency anemia is not uncommon, especially among teenagers or young women. Long-term anemia of chronic inflammation can also lead to iron deficiency, since, hepcidin, the key inducer of the anemia of chronic inflammation, inhibits iron absorption from the gastrointestinal tract.

Pulmonary hemorrhage is a rare cause of anemia in SLE. Not all patients have hemoptysis. Other symptoms of alveolar hemorrhage are dyspnea and cough. The presence of alveolar infiltrates on a chest radiograph or ground-glass opacities on chest CT are suggestive of alveolar hemorrhage.

2.4 Red cell aplasia

Red cell aplasia, probably due to antibodies directed against either erythropoietin or bone marrow erythroblasts, has been observed, although it is rare [5,6,10]. This form of anemia usually responds to steroids, although cyclophosphamide and cyclosporine have been successfully employed.

Even rarer are isolated case reports of aplastic anemia, presumably mediated by auto antibodies against bone marrow precursors; immunosuppressive therapy also may be effective in this setting [11-13].

In addition, bone marrow suppression can also be induced by medications, including antimalarials and immunosuppressive drugs.

2.5 Autoimmune hemolytic anemia

Overt autoimmune hemolytic anemia (AIHA), characterized by an elevated reticulocyte count, low haptoglobin levels, increased indirect bilirubin concentration, and a positive direct Coombs' test, has been noted in up to 10 percent of patients with SLE [2-4,8,14]. The presence of hemolytic anemia may be associated with other manifestations of severe disease such as renal disease, seizures, and serositis [14].

Other patients have a positive Coombs' test without evidence of overt hemolysis. The presence of both immunoglobulin and complement on the red cell is usually associated with some degree of hemolysis, while the presence of complement alone (eg, C3 and/or C4) is often not associated with hemolysis [1-4].

AIHA responds to steroids (1 mg/kg per day of prednisone or its equivalent in divided doses) in 75 to 96 percent of patients [15, 16]. Once the hematocrit begins to rise and the reticulocyte count falls, steroids can be rapidly tapered. If there is no response, we can consider pulse steroids (eg, 1000 mg methylprednisolone intravenously daily for three days) [15], azathioprine (up to 2 mg/kg per day) [17], cyclophosphamide (up to 2 mg/kg) [18], or splenectomy. Success rates for splenectomy as high as 60 percent have been reported [19], although others have found no benefit [20].

Other described approaches to patients with refractory AIHA include intravenous immune globulin [18], danazol [21-23], mycophenolate mofetil [24], and rituximab [25].

2.6 Microangiopathic hemolytic anemia

Lupus has also been associated with a thrombotic microangiopathic hemolytic anemia [26] as manifested by a peripheral blood smear showing schistocytes and elevated serum levels of lactate dehydrogenase (LDH) and bilirubin. Many affected patients also have thrombocytopenia, kidney involvement, fever, and neurologic symptoms. This pentad of features is compatible with a diagnosis of thrombotic thrombocytopenic purpura (TTP). However, the pathogenesis of TTP in these patients is likely heterogeneous, as it may reflect vasculitis or antiphospholipid syndrome as well [27, 28].

Whether the occurrence of both SLE and TTP in an individual patient is a coincidence or represents a true association is an unsettled question.

Other patients with microangiopathic red cell destruction do not have fever or neurologic disease, producing a pattern of hemolytic-uremic syndrome. The pathogenesis of this syndrome is not completely understood. In one report of 4 patients plus 24 others identified from a literature review, antiphospholipid antibodies (aPL) were searched for in eight and found in five [26].

The presence of aPL in SLE patients with severe hemolytic anemia, renal dysfunction, and central nervous system involvement has also been reported [31].

In a review of 28 reported patients, those treated with plasma infusions or plasmapheresis, glucocorticoids alone, or no therapy had mortality rates of 25, 50, and 100 percent, respectively [26]. However, in another series of 15 patients with SLE and microangiopathic hemolytic anemia, all responded to treatment with high-dose glucocorticoids and none were treated with plasmapheresis [32]. In a retrospective study [27] in which 70 percent of patients with SLE and TTP underwent plasma exchange, the response rate of 74 percent was comparable to that observed in patients with idiopathic TTP.

Patients with SLE, severe microangiopathic hemolytic anemia, and other major organ dysfunction should be treated with plasmapheresis and plasma infusion as in other cases of thrombotic thrombocytopenic purpura or the hemolytic-uremic syndrome. Those with less severe disease may be treated with high-dose glucocorticoids and observed carefully with the addition of plasmapheresis should they deteriorate or fail to improve with steroid treatment alone.

3. An approach to lupus patient with anaemia

After the detailed analysis and discussion of each type of anemia associated with SLE, here is a simple approach to anemic SLE patient with an easy mechanism to the diagnosis.

Anaemia can be divided into those conditions with impaired red cell production (marrow suppression, nutrient deficiency) and those with increased red cell destruction (haemolysis, hypersplenism) or blood loss. Measurement of reticulocyte production (reticulocyte index) usually used to make this distinction and it is the major step for determination of causes of anaemia. IDA is defined by serum ferritin level below: 20 µg/dl. Pernicious anemia (PA) is defined by serum vitamin B12 of less than: 180 pmol/l together with one or more of the following: an abnormal Schilling test result or the presence of anti-intrinsic factor antibody in the blood.

It is also important to mention that the examination of the peripheral blood smear is a mandatory step in the initial evaluation of all SLE patients with hematologic disorders. The examination of blood films stained with Wright's stain frequently provides important clues in the diagnosis of anemias and various disorders of leukocytes and platelets and we can

discover a life threatening conditions like TTP early on. For example, some of the abnormalities suspicious for the presence of hemolysis in blood smear include the following:

- Spherocytes (microspherocytes and elliptocytes) indicate autoimmune hemolytic anemia
- Fragmented RBC (schistocytes, helmet cells) indicating the presence of microangiopathic hemolytic anemia (thrombotic thrombocytopenic purpura-hemolytic uremic syndrome)
- Acanthocytes (spur cells) in patients with liver disease.
- Blister or "bite" cells due to the presence of oxidant-induced damage to the red cell and its membrane (G-6-PD).
- RBCs with inclusions, as in malaria, babesiosis, and Bartonella infections (" non-immune hemolytic anemia due to systemic disease", ").
- Teardrop RBCs with circulating nucleated RBC and early white blood cell forms, indicating the presence of marrow involvement, as in primary myelofibrosis or tumor infiltration.

So at a practical level, when you are faced with SLE anaemia, it will be easy to differentiate among the possible mechanisms with only a few tests. If the reticulocytes are increased, a haemolytic process or acute bleeding should be the probable cause. If the reticulocytes are inadequate, you should rule out a nutritional deficiency of iron, vitamin B12, or folate. Ferritin determination suffices for diagnosing IDA. If the ferritin concentration is greater than 20 µg/dl, IDA is virtually never present and a bone marrow examination may be considered, but we have to mention that ferritin is an acute phase reactant and it can be elevated in any patients with inflammatory process due to any cause, although the diagnostic yield may be very low and anaemia of chronic disease is the most common diagnosis of exclusion (figure 1).

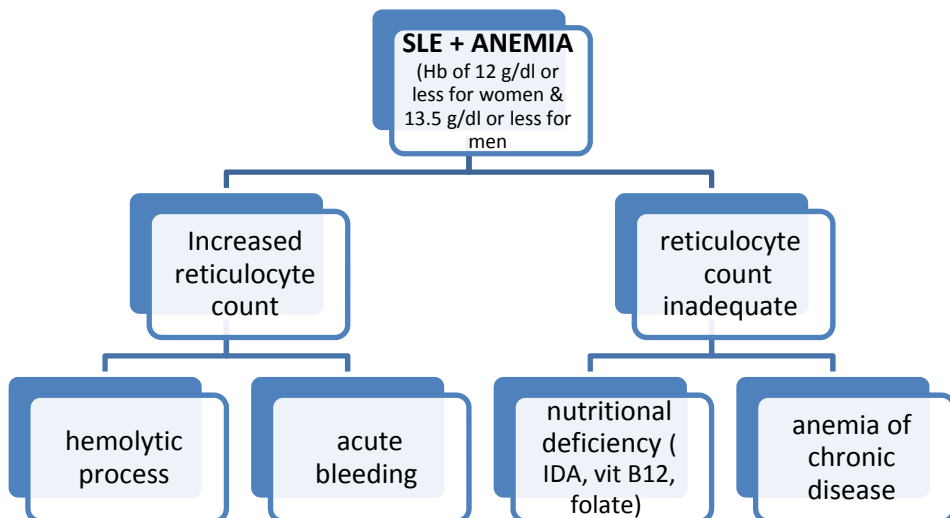


Fig. 1.

4. Leukopenia in systemic lupus erythematosus

Leukopenia is common in SLE and usually reflects disease activity. A white blood cell count of less than 4500/microL has been noted in approximately 50 percent of patients, especially those with active disease [3, 4], while lymphocytopenia occurs in approximately 20 percent [3]. In comparison, a white blood cell count below 4000/microL (an American College of Rheumatology criterion for SLE) occurs in only 15 to 20 percent of patients [3, 33]. Neutropenia, lymphocytopenia, and decreased circulating eosinophils and basophils may all contribute to leukopenia.

4.1 Neutropenia

Neutropenia in patients with SLE can result from: immune mechanisms, medications (eg, cyclophosphamide or azathioprine), bone marrow dysfunction, or hypersplenism [3,4,33,34]. Other clinical features that may be associated with moderate to severe neutropenia (absolute neutrophils <1000/microL) include infection, anemia, thrombocytopenia, and a history of neuropsychiatric involvement [34].

4.2 Lymphocytopenia

Lymphocytopenia (lymphocytes less than 1500/microL), especially involving suppressor T cells, has been observed in 20 to 75 percent of patients, particularly during active disease [1-3, 37, 38]. This finding is strongly associated with IgM, cold reactive, complement fixing, and presumably cytotoxic antilymphocyte antibodies; such antibodies were noted in 26 of 29 patients with SLE and the antibody titer correlated directly with the degree of lymphopenia [39].

4.3 Decreased eosinophils and basophils

Steroid therapy may result in low absolute eosinophil and monocyte counts [41]. The number of basophils may also be decreased in SLE, particularly during active disease [42].

4.4 Leukopenia

In SLE rarely needs treatment. An exception is the patient with neutropenia and recurrent pyogenic infections. One problem is the toxicity of the usual therapies. Prednisone (10 to 60 mg/day) can raise the white blood cell count but can also result in an increased risk of infections; immunosuppressive agents such as azathioprine or cyclophosphamide have the potential to cause worsening of the leukopenia via bone marrow suppression, respectively [43].

Cautious use of azathioprine, with careful monitoring of the white blood cell count, may be considered in this setting.

5. Leukocytosis in systemic lupus erythematosus

Leukocytosis (mostly granulocytes) can occur in SLE. When present, it is usually due to infection or the use of high doses of glucocorticoids [43], but may occur during acute exacerbations of SLE. A shift of granulocytes to more immature forms (a "left" shift) suggests infection.

6. Thrombocytopenia in systemic lupus erythematosus

Mild thrombocytopenia (platelet counts between 100,000 and 150,000/microL) has been noted in 25 to 50 percent of patients; while counts of less than 50,000/microL occur in only 10 percent [1, 3,4,33]. There are several potential causes of thrombocytopenia in patients with SLE. Immune mediated platelet destruction is most often the cause, but platelet consumption may also occur in association with microangiopathic hemolytic anemia (see 'Microangiopathic hemolytic anemia' above) or could be due to impaired platelet production as a result of the use of cytotoxic, immunosuppressive, or other drugs.

The major mechanism is immunoglobulin binding to platelets followed by phagocytosis in the spleen, as in idiopathic thrombocytopenic purpura (ITP) [47]. Membrane glycoproteins (GP) are most often the target of such antibodies (eg, GP IIb/IIIa) but anti-HLA specificity also occurs [48].

Antigen-dependent B cell development in lymphoid tissues is influenced by binding of CD40 on B cells to CD40-ligand on activated T cells. The finding of autoantibodies to CD40-ligand in patients with SLE, APS, and ITP, but not in the serum of healthy blood donors suggests that interference with T cell and B cell interaction may play a role in the development of thrombocytopenia [49].

Other important mechanisms in selected patients include bone marrow suppression by immunosuppressive drugs (other than corticosteroids), increased consumption due to a thrombotic thrombocytopenic purpura [TTP] [26], the antiphospholipid syndrome, or antibodies that block the thrombopoietin receptor on megakaryocytes or their precursors.

ITP may be the first sign of SLE, followed by other symptoms as long as many years later. It has been estimated that 3 to 15 percent of patients with apparently isolated ITP go on to develop SLE [50].

Evans syndrome (ie, both autoimmune thrombocytopenia and autoimmune hemolytic anemia) also may precede the onset of SLE. Severe bleeding from thrombocytopenia is only experienced by a minority of patients; however, SLE patients with thrombocytopenia are more likely to have associated significant organ damage, such as heart and kidneys and the CNS [51].

6.1 Medical therapy

Platelet counts between 50,000/microL and 20,000/microL rarely cause more than a prolonged bleeding time, while counts of less than 20,000/microL may be associated with petechiae, purpura, ecchymoses, epistaxis, gingival, and other clinical bleeding.

Treatment of thrombocytopenia is usually recommended for symptomatic patients with counts of less than 50,000/microL and for all patients with counts of less than 20,000/microL.

The treatment of ITP in SLE is the same as that in patients without lupus.

Briefly, the mainstay of treatment is glucocorticoid therapy. Older studies used prednisone (1 mg/kg per day in divided doses) [54, 55]. However, treatment with four to eight cycles of oral high dose dexamethasone (40 mg per day for four days) at intervals of two weeks to four weeks may result in similar remission rates and better long-term responses than those observed in historical controls treated with daily prednisone [56].

Most patients respond to glucocorticoid therapy within one to eight weeks [57]. If there is no significant increase in the platelet count within one to three weeks or side effects are intolerable, the following options may be considered and used depends upon the severity of the thrombocytopenia and the presence or absence of other manifestations of SLE:

- Azathioprine
- Cyclophosphamide [58].
- Intravenous immune globulin is very effective and may be preferred to azathioprine or cyclophosphamide when a rapid rise in platelet count is necessary (as in the patient who is actively bleeding or requires emergent surgery) [59].
- Mycophenolate mofetil may be useful in the patient refractory to other medical therapy [60].
- Rituximab has been used to treat ITP in patients without SLE who were refractory to other treatments and this B lymphocyte depleting approach may be beneficial for other manifestations of lupus [25].

6.2 Splenectomy

Splenectomy can raise the platelet count but it does not reliably produce a durable remission of thrombocytopenia. Relapse following splenectomy may occur and has been noted at varying times from 1 to 54 months after surgery [62].

6.3 Thrombocytopenia following splenectomy

Patients with persistent thrombocytopenia after splenectomy may subsequently respond to azathioprine, cyclophosphamide, rituximab, intravenous immunoglobulin, or danazol [23,63,64]. If possible, splenectomy should be preceded by immunization with pneumococcal vaccine to reduce the risk of pneumococcal sepsis.

7. Thrombocytosis in systemic lupus erythematosus

Thrombocytosis is a less frequent finding in patients with SLE and it might be occurring as an acute phase reactant and a sign of active disease.

8. Pancytopenia in systemic lupus erythematosus

Although peripheral destruction of red cells, leukocytes, and platelets may occur together and lead to clinically significant pancytopenia, depression of all three cell lines also suggests bone marrow failure, as in the case in aplastic anemia. Thus, bone marrow examination is the most important diagnostic test to perform.

Causes of marrow failure include drugs and coincidental diseases including: the acute leukemias, large granular lymphocyte leukemia, the myelodysplastic syndromes, marrow replacement by fibrosis or tumor, severe megaloblastic anemia, paroxysmal nocturnal hemoglobinuria (PNH), and overwhelming infection. In addition, unexplained cytopenia can be associated with bone marrow necrosis, dysplasia, and distortion of the bone marrow architecture [70].

Among patients with SLE an unusual cause of pancytopenia is the **macrophage activation syndrome**. The clinical characteristics of 12 patients with SLE-associated macrophage activation syndrome included [71]:

Fever (100%), weight loss (80%), arthritis (50%), pericarditis (42%), rash (66%) myocarditis (33%), nephritis (33%), splenomegaly (27%), hepatomegaly (13%), lymphadenopathy (73%), anemia (100%), leukopenia (87%), hyperferritinemia (100%), anti-DNA antibodies (80%), low CRP (<30 mg/L) (90%), hypocomplementemia (60%).

The demonstration of hemophagocytosis in the bone marrow or in material obtained from peripheral lymph nodes is a characteristic finding.

The few reported cases of macrophage activation syndrome in patients with SLE have usually responded to treatment with glucocorticoids and immunosuppressive agents. Optimal treatment is uncertain.

9. Lymphadenopathy and splenomegaly in systemic lupus erythematosus

Enlargement of lymph nodes occurs in approximately 50 percent of patients with SLE. The nodes are typically soft, nontender, discrete, varying in size from 0.5 to several centimeters, and usually detected in the cervical, axillary, and inguinal areas. Lymphadenopathy is more frequently noted at the onset of disease or in association with an exacerbation. Biopsies reveal areas of follicular hyperplasia and necrosis, the appearance of hematoxylin bodies is highly suggestive of SLE, although unusual [1].

Lymph node enlargement can also be due to infection or a lymphoproliferative disease in SLE. When infections are present, the enlarged nodes are more likely to be tender.

Prominent lymphadenopathy may also be a manifestation of **angioimmunoblastic T cell lymphoma**. This disorder has other clinical features (arthritis, Coombs-positive hemolytic anemia, skin rash, fever, and weight loss) that are suggestive of systemic lupus erythematosus or systemic onset juvenile rheumatoid arthritis (Still's disease). Enlargement of the spleen occurs in 10 to 46 percent of patients, particularly during active disease. Splenomegaly is not necessarily associated with a cytopenia. Pathologic examination of spleen reveals an onion skin appearance of the splenic arteries, a lesion that is thought to represent healed vasculitis.

In view of the frequent presence of lymphadenopathy and splenomegaly in SLE, the possibility of a **lymphoproliferative malignancy** may be considered. The risk of non-Hodgkin lymphoma appears to be increased four- to five fold in patients with lupus.

A lymph node biopsy may be warranted when the degree of lymphadenopathy is out of proportion to the activity of the lupus.

One of the rare diseases that reported to be associated with SLE is:

9.1 Kikuchi-Fujimoto's disease (KFD)

Also called histiocytic necrotizing lymphadenitis which is a rare benign and self limited disease, of unknown etiology, affects mainly young women [77]. It presents with localized lymphadenopathy, predominantly in the cervical region, less commonly include axillary and mesenteric lymphadenopathy accompanied by fever and leucopenia in up to 50% of the cases [78, 79]. KFD has been reported in association with systemic lupus erythematosus (SLE), the relation between Kikuchi's disease and SLE is not yet completely understood and remains complex. The reports imply that SLE may be present before, at the same time, or after the clinical appearance of KFD [77-79].

KFD can be a complication of prolonged and multiple immunosuppressant use in SLE patients, There is a published case report in 2011 of KFD that diagnosed based on a lymph node biopsy in a 31 year old Saudi female patient with an established diagnosis of stage IV lupus nephritis. She presented with fever, axillary lymphadenopathy and neutropenia. The patient is known to have SLE for 16 years prior to the presentation with history of prolonged use of many immunosuppressive medications. The patient treated with intravenous antibiotic as a case of febrile neutropenia and recovered spontaneously. They

concluded that in most of the cases the diagnosis of KFD was made before or at the same time of the diagnosis of SLE. In this case report the diagnosis of KFD was made years after the diagnosis of SLE. They also noted that the patient received prolonged courses of immunosuppressant medications including mycophenolate mofetil, and then 6 cycles of cyclophosphamide, she was placed then on azothioprine and hydroxychloroquine. So they consider the prolonged use of immunosuppressant medications a risk factor for KFD in a well established SLE with lupus nephritis.

10. Antibodies to clotting factors and anti-phospholipids syndrome in systemic lupus erythematosus

Antibodies to a number of clotting factors, including VIII, IX, XI, XII, and XIII have been noted in patients with SLE [1,2,33]. These antibodies may not only cause abnormalities of in vitro coagulation tests but may also cause bleeding.

Much more common are aPL (antiphospholipid antibodies), the presence of which has been associated with a prolongation of the partial thromboplastin time (PTT) (lupus anticoagulant activity) and an increased risk of arterial and venous thrombosis, thrombocytopenia, and fetal loss [72, 73]. Antibodies to other phospholipids and to phospholipid binding proteins (eg, anticardiolipin antibodies) in moderate or high levels may also be associated with these clinical phenomena. When aPL occurs in association with one or more of these clinical features in a patient with SLE it suggests the presence of the APS.

10.1 Antiphospholipid syndrome

The antiphospholipid syndrome (APS) is defined by two major components:

1. The occurrence of at least one clinical feature: vascular event or pregnancy morbidity AND
2. The presence of at least one type of autoantibody known as an antiphospholipid antibody (aPL).

In addition, there are aPL-related clinical manifestations that are not part of the APS Classification Criteria, such as livedo reticularis, thrombocytopenia, cardiac valve disease, or aPL-nephropathy.

APL is directed against serum proteins bound to anionic phospholipids and may be detected by a: Lupus anticoagulant tests, Anticardiolipin antibody ELISA and Anti- β 2 glycoprotein-I ELISA.

The full clinical significance of other autoantibodies, including those directed against prothrombin, annexin V, phosphatidylserine, and phosphatidylinositol, remain unclear.

APS occurs as a primary condition or in the setting of an underlying systemic autoimmune disease, particularly SLE [72].

- **Classification criteria** have been developed for research purposes. They may be helpful to clinicians, but not all the classification criteria need to be met to make a clinical diagnosis of APS.

Definite APS is considered present if at least one of the following clinical criteria and at least one of the following laboratory criteria are satisfied:

- Clinical: one or more episodes of venous, arterial, or small vessel thrombosis and/or morbidity with pregnancy.

- Thrombosis: unequivocal imaging or histological evidence of thrombosis in any tissue or organ, OR
- Pregnancy morbidity : otherwise unexplained death at ≥ 10 weeks gestation of a morphologically normal fetus, OR
- One or more premature births before 34 weeks of gestation because of eclampsia, preeclampsia, or placental insufficiency, OR
- Three or more embryonic (< 10 week gestation) pregnancy losses unexplained by maternal or paternal chromosomal abnormalities or maternal anatomic or hormonal causes.
- Laboratory : the presence of aPL, on two or more occasions at least 12 weeks apart and no more than five years prior to clinical manifestations, as demonstrated by one or more of the following: IgG and/or IgM aCL in moderate or high titer), antibodies to $\beta 2$ -GP-I of IgG or IgM isotype at a high titer. LA activity detected according to published guidelines [72, 75].

10.1.1 Pathology

The characteristic pathologic finding in the APS is a bland thrombosis with minimal vascular or perivascular inflammation. This change is not specific for the APS, as it also occurs in the kidney in a variety of other disorders including the hemolytic-uremic syndrome/thrombotic thrombocytopenic purpura, systemic sclerosis (scleroderma), and malignant hypertension. Larger vessels, both arteries and veins, may develop in situ thrombosis or be sites from or into which emboli originate or lodge.

10.1.2 Clinically

- The APS is characterized by venous or arterial thromboses, morbidity occurring in the setting of pregnancy, and/or aPL-related clinical manifestations that are not part of the APS Classification Criteria, such as livedo reticularis, thrombocytopenia, cardiac valve disease, or aPL-nephropathy [73, 74].

In a series of 1000 patients with either primary or secondary APS, the various disease features were [74]:

Deep vein thrombosis (32%), Thrombocytopenia (22%), Livedo reticularis (20%), Stroke (13%), Superficial thrombophlebitis (9%), Pulmonary embolism (9%), Fetal loss (8 %), TIA (7%), Hemolytic anemia (7%).

In rare patients, APS results in multi-organ failure because of multiple blood vessel occlusions, a condition referred to as "catastrophic antiphospholipid syndrome".

In addition to those already mentioned above, other possible aPL-related clinical manifestations include migraine headache, Reynaud phenomenon, pulmonary hypertension, avascular necrosis, cutaneous ulcers that resemble pyoderma gangrenosum, adrenal insufficiency due to hemorrhagic infarction, and cognitive deficits [72-75].

- **Thrombosis:** the risk of both venous and arterial thrombosis and/or thromboembolism is increased in individuals with positive tests for LA activity or medium or high levels of aCL. The risk of recurrent thrombosis or thromboembolism may be further enhanced in those with positivity to three aPL activities (LA, aCL, and $\beta 2$ -glycoprotein-I) upon repeated testing [74].

Initial site: venous thromboses are more common than arterial thromboses in the APS [73, 74]. The most common site of DVT is the calf, but the renal veins, the hepatic, axillary,

subclavian, and retinal veins, the cerebral sinuses, and the vena cava may also be involved. The most common site of arterial thrombosis is the cerebral vessels, but coronary, renal, and mesenteric arteries and arterial bypass graft occlusions have also been noted.

To some degree, the site of thrombosis may be related to the type of aPL present. This was illustrated in a retrospective study of 637 patients with APS in which DVT and PE were more frequent among patients with LA, while coronary, cerebrovascular, and peripheral arterial events were more likely in those with elevated levels of IgG or IgM aCL.

- **Deep venous thrombosis:** APL can be detected in approximately 5 to 21 percent of all patients with DVT [72]. The incidence of DVT may correlate with the level of aCL. As an example, one study found that DVT occurred in 44% of patients with high titers of aCL, in 29% with low titers, and in only 10% of those without these antibodies [73].

Stroke: the APS is strongly linked to ischemic stroke [74, 80]. The occurrence of livedo reticularis in association with a stroke is known as **Sneddon's syndrome** [73]. In the great majority of cases, Sneddon's syndrome is associated with detectable aPL.

A thrombotic stroke occurring in a young patient with no overt risk factors for cerebrovascular disease is the classic setting to suspect the APS. In one study, aPL was found in 25% of patients younger than 45 years of age who presented with a stroke of unclear etiology [81]. In another report, 20 percent of stroke victims under the age of 50 had aPL [74]. Ischemic stroke may be a manifestation in situ thrombosis or due to embolism arising from a valvular heart disease. If routine transthoracic echocardiography is normal, transesophageal echo may be indicated to assess for vegetations due to nonbacterial endocarditis.

Several studies have evaluated the risk of stroke associated with the presence of aPL:

In a review of 2000 healthy male subjects, the relative risk of stroke at 15 years of follow-up was 2.2 in subjects with aPL []. Events were observed primarily in subjects who had both β 2-GP-I and IgG aCL (ie, β 2-GP-I dependent aCL).

In the Stroke Prevention in Young Women study, the presence of LAs and aCL was evaluated in 160 cases and 340 controls [74]. After adjustment for potential confounders, the relative odds of stroke for women with an aCL of any isotype or an LA was 1.87 (95% CI 1.2 to 2.8). Similar findings of an increased risk of ischemic stroke associated with aCL limited to women were noted in a report from the Framingham Cohort and Offspring Study (hazard ratio for women 2.6; 95% CI 1.3 to 5.4) [73].

Neurologic syndromes besides stroke: strong associations are now recognized between the presence of aPL and the occurrence of cognitive deficits and/or white matter lesions. However, the link with the APS is less strong for other neurological associations.

White matter lesions: see chapter of neurology in SLE.

Other neurological associations: epilepsy, depression, psychosis, chorea and hemiballismus, transverse myelopathy, sensorineural hearing loss, orthostatic hypotension, migraine.

Recurrent thrombotic events: are common in APS. Most but not all observers have noted that an initial arterial thrombosis tends to be followed by an arterial event, and that an initial venous thrombosis is usually followed by a venous event [72].

Pregnancy loss and preeclampsia: the presence of APS may be related to several types of morbidity during pregnancy. These include fetal death after 10 weeks gestation, premature birth due to severe preeclampsia or placental insufficiency, or multiple embryonic losses (<10 weeks gestation).

In patients with preeclampsia or HELLP syndrome, the possibility of the catastrophic APS must be considered, particularly in patients with histories of thrombosis or spontaneous abortions [73].

Hematologic manifestations: prominent hematologic manifestations of APS include thrombocytopenia, microangiopathic hemolytic anemia and, in rare cases, bleeding:

Thrombocytopenia: a review of 13 studies of 869 patients with SLE, found that thrombocytopenia was more common in those with LA (55 percent) and aCL (29 PERCENT) than in those without these antibodies [50]. Conversely, patients with thrombocytopenia associated with autoimmune disorders frequently have aPL (eg, 70 to 82 percent of patients with SLE and thrombocytopenia, and 30 to 40 percent of those with ITP [26, 49, 50].

Thrombotic microangiopathy: APL has been implicated in some cases of TTP/HUS that occur in SLE. See hematological manifestations in SLE.

Bleeding episodes: the presence of antibodies to prothrombin should be suspected when a patient with a known LA also has a low prothrombin level and develops bleeding complications rather than thrombosis.

Pulmonary disease: pulmonary embolism occurs in approximately one-third of patients with the APS who develop DVT. Other recognized pulmonary complications of the APS include [26, 48-50]: Pulmonary arterial thrombosis with or without thromboembolic pulmonary hypertension and alveolar hemorrhage.

In addition, fibrosing alveolitis, adult respiratory distress syndrome, and nonthromboembolic pulmonary hypertension have been reported in association with aPL [50, 72]. However, the relationship to these disorders to aPL is unclear

Cardiovascular disease: patients with aPL commonly have cardiac disease, including valvular thickening, mitral valve nodules, and nonbacterial vegetations. Involvement of the mitral and aortic valves can lead to valvular regurgitation and rarely to stenosis.

APL have also been incriminated in intracardiac thrombi, pericardial effusion, cardiomyopathy, emboli in those with or without infective endocarditis, premature restenosis of vein grafts for coronary bypass, and peripheral vascular disease [50].

Cutaneous: APL has been associated with many cutaneous abnormalities including splinter hemorrhages, livedo reticularis, cutaneous necrosis and infarction, [49, 50].

Gastrointestinal disease: patients with aPL may have ischemia involving the esophagus, stomach, duodenum, jejunum, ileum, or colon resulting in gastrointestinal bleeding, abdominal pain, an acute abdomen, esophageal necrosis with perforation, or giant gastric or atypical duodenal ulceration [73]. Splenic or pancreatic infarction may also occur. In addition, the liver may be involved; hepatic or portal venous thrombosis may result in the Budd-Chiari syndrome, hepatic-veno-occlusive disease, hepatic infarction, portal hypertension, and cirrhosis. [72].

Ocular manifestations: amaurosis fugax, retinal venous and arterial occlusion, and anterior ischemic optic neuropathy have occurred in patients with aPL [72].

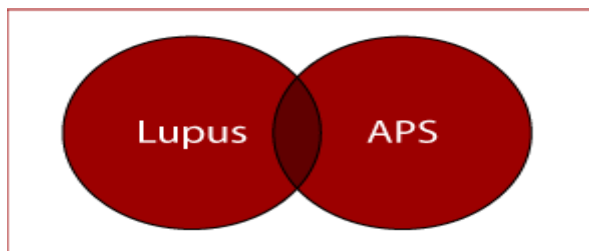
Catastrophic APS: a small subset of patients with APS has widespread thrombotic disease with multiorgan failure, which is called "catastrophic APS." Preliminary criteria proposed for classification purposes have been published and validated (Among 1000 patients with the APS followed for a mean of seven years, only 8 (0.8 percent) developed catastrophic APS [73, 74]. In the majority of these patients, multiorgan involvement was present at the time of diagnosis of APS.

Patients with catastrophic APS may have laboratory features such as elevated fibrin degradation products, depressed fibrinogen levels, or elevated D-dimer concentrations that are more typically found with disseminated intravascular coagulation (DIC).

Catastrophic APS is frequently fatal, with a reported mortality rate approaching 50 percent despite anticoagulant and immunosuppressive treatment [74].

10.1.3 Primary APS versus SLE

The antiphospholipid syndrome was first described as a complication of the disease 'SLE'. However, in many cases – indeed probably the vast majority did **NOT** have any evidence of lupus. This gave rise to the term 'Primary Antiphospholipid Syndrome' (PAPS). For those patients where the clotting tendency is secondary to another disease such as lupus, the condition is often called 'Secondary Antiphospholipid Syndrome'. It should be stressed that the majority of patients with 'Primary' APS (Hughes Syndrome) do **NOT** go on to develop lupus in later life. The inter-relationship between lupus and APS (Hughes Syndrome) is highlighted in this diagram below:



some data suggest that the clinical manifestations of primary APS and APS associated with SLE are similar [73]. In contrast, a subsequent study of 122 patients noted that the frequency of arterial thromboses, venous thromboses, and fetal loss was greater in patients with APS and SLE than in those with primary APS [72].

A separate issue is the frequency of evolution of APS into SLE or lupus-like disease. Three studies involving 70 to 128 patients with APS found a variable rate of development of SLE over time:

Zero percent at five years, 4 percent at 6.5 years, 13 percent at nine years.

10.1.4 Mortality

The presence of aPL in the serum of patients with SLE has been identified as an independent risk factor for premature death. There was an increased risk of premature death in patients with aPL, thrombocytopenia, and arterial occlusion. Other factors associated with premature death were the intensity of anticoagulation treatment, renal involvement, pleuritis, and disease activity.

10.1.5 Management and recommendation

Current therapies for the APS include the following medications: low molecular weight heparin, unfractionated heparin, warfarin, antiplatelet agents, aspirin, clopidogrel, hydroxychloroquine (see below).

Initial approach to thrombosis:

treatment for venous thromboembolic disease is part of the American College of Chest Physicians (ACCP) Evidence-Based Clinical Practice Guidelines (8th Edition), as the following: for patients with objectively confirmed deep vein thrombosis (DVT) or pulmonary embolism (PE), we recommend anticoagulant therapy with subcutaneous (SC) low-molecular-weight heparin (LMWH), monitored IV, or SC unfractionated heparin (UFH), unmonitored weight-based SC UFH, or SC fondaparinux (all Grade 1A). For patients with a

high clinical suspicion of DVT or PE, we recommend treatment with anticoagulants while awaiting the outcome of diagnostic tests (Grade 1C).

For patients with confirmed PE, we recommend early evaluation of the risks to benefits of thrombolytic therapy (Grade 1C); for those with hemodynamic compromise, we recommend short-course thrombolytic therapy (Grade 1B); and for those with nonmassive PE, we recommend against the use of thrombolytic therapy (Grade 1B).

In acute DVT or PE, we recommend initial treatment with LMWH, UFH or fondaparinux for at least 5 days rather than a shorter period (Grade 1C); and initiation of vitamin K antagonists (VKAs) together with LMWH, UFH, or fondaparinux on the first treatment day, and discontinuation of these heparin preparations when the international normalized ratio (INR) is $>$ or $=$ 2.0 for at least 24 h (Grade 1A).

For patients with DVT or PE secondary to a transient (reversible) risk factor, we recommend treatment with a VKA for 3 months over treatment for shorter periods (Grade 1A). For patients with unprovoked DVT or PE, we recommend treatment with a VKA for at least 3 months (Grade 1A), and that all patients are then evaluated for the risks to benefits of indefinite therapy (Grade 1C).

We recommend indefinite anticoagulant therapy for patients with a first unprovoked proximal DVT or PE and a low risk of bleeding when this is consistent with the patient's preference (Grade 1A), and for most patients with a second unprovoked DVT (Grade 1A). We recommend that the dose of VKA be adjusted to maintain a target INR of 2.5 (INR range, 2.0 to 3.0) for all treatment durations (Grade 1A).

For prevention of post-thrombotic syndrome (PTS) after proximal DVT, we recommend use of an elastic compression stocking (Grade 1A). For DVT of the upper extremity, we recommend similar treatment as for DVT of the leg (Grade 1C). Selected patients with lower-extremity (Grade 2B) and upper-extremity (Grade 2C). DVT may be considered for thrombus removal, generally using catheter-based thrombolytic techniques. For extensive superficial vein thrombosis, we recommend treatment with prophylactic or intermediate doses of LMWH or intermediate doses of UFH for 4 weeks (Grade 1B).

The optimal duration of anticoagulation for venous thromboembolic disease following a first event is uncertain. However, given the high likelihood of recurrence in the untreated patient and the potentially devastating nature of recurrent thromboembolic events, we recommend lifelong anticoagulation for patients with the APS (Grade 1B) [86-89].

Prophylaxis of the asymptomatic patient

In the absence of symptoms or a history of symptoms attributable to the APS, we do not recommend the use of aspirin as prophylaxis (Grade 2B). For patients with SLE and aPL but no APS manifestations, the combination of low-dose aspirin and hydroxychloroquine may be considered (Grade 2C)[80-89].

11. Acknowledgments

The work to produce this chapter was supported by Alzaidi's Chair of research in rheumatic diseases - Umm Alqura University.

12. References

Laurence, J, Wong, JE, Nachman, R. The cellular hematology of systemic lupus erythematosus. In: Systemic Lupus Erythematosus, 2d ed, Lahita, RG (Ed), Churchill Livingstone, New York 1992.


- Shoenfeld, Y, Ehrenfeld, M. Hematologic manifestations. In: *The Clinical Management of Systemic Lupus Erythematosus*, 2d ed, Schur, PH (Ed), Lippincott, Philadelphia 1996.
- Nossent JC, Swaak AJ. Prevalence and significance of haematological abnormalities in patients with systemic lupus erythematosus. *Q J Med* 1991; 80:605.
- Keeling DM, Isenberg DA. Haematological manifestations of systemic lupus erythematosus. *Blood Rev* 1993; 7:199.
- Liu H, Ozaki K, Matsuzaki Y, et al. Suppression of haematopoiesis by IgG autoantibodies from patients with systemic lupus erythematosus (SLE). *Clin Exp Immunol* 1995; 100:480.
- Habib GS, Saliba WR, Froom P. Pure red cell aplasia and lupus. *Semin Arthritis Rheum* 2002; 31:279.
- Voulgarelis M, Kokori SI, Ioannidis JP, et al. Anaemia in systemic lupus erythematosus: aetiological profile and the role of erythropoietin. *Ann Rheum Dis* 2000; 59:217.
- Giannouli S, Voulgarelis M, Ziakas PD, Tzioufas AG. Anaemia in systemic lupus erythematosus: from pathophysiology to clinical assessment. *Ann Rheum Dis* 2006; 65:144.
- Schett G, Firdas U, Füreder W, et al. Decreased serum erythropoietin and its relation to anti-erythropoietin antibodies in anaemia of systemic lupus erythematosus. *Rheumatology (Oxford)* 2001; 40:424.
- Hara A, Wada T, Kitajima S, et al. Combined pure red cell aplasia and autoimmune hemolytic anemia in systemic lupus erythematosus with anti-erythropoietin autoantibodies. *Am J Hematol* 2008; 83:750.
- Winkler A, Jackson RW, Kay DS, et al. High-dose intravenous cyclophosphamide treatment of systemic lupus erythematosus-associated aplastic anemia. *Arthritis Rheum* 1988; 31:693.
- Brooks BJ Jr, Broxmeyer HE, Bryan CF, Leech SH. Serum inhibitor in systemic lupus erythematosus associated with aplastic anemia. *Arch Intern Med* 1984; 144:1474.
- Roffe C, Cahill MR, Samanta A, et al. Aplastic anaemia in systemic lupus erythematosus: a cellular immune mechanism? *Br J Rheumatol* 1991; 30:301.
- Jeffries M, Hamadeh F, Aberle T, et al. Haemolytic anaemia in a multi-ethnic cohort of lupus patients: a clinical and serological perspective. *Lupus* 2008; 17:739.
- Jacob HS. Pulse steroids in hematologic diseases. *Hosp Pract (Off Ed)* 1985; 20:87.
- Gomard-Mennesson E, Ruivard M, Koenig M, et al. Treatment of isolated severe immune hemolytic anaemia associated with systemic lupus erythematosus: 26 cases. *Lupus* 2006; 15:223.
- Corley CC Jr, Lessner HE, Larsen WE. Azathioprine therapy of "autoimmune" diseases. *Am J Med* 1966; 41:404.
- Murphy S, LoBuglio AF. Drug therapy of autoimmune hemolytic anemia. *Semin Hematol* 1976; 13:323.
- Coon WW. Splenectomy for cytopenias associated with systemic lupus erythematosus. *Am J Surg* 1988; 155:391.
- Rivero SJ, Alger M, Alarcón-Segovia D. Splenectomy for hemocytopenia in systemic lupus erythematosus. A controlled appraisal. *Arch Intern Med* 1979; 139:773.
- Chan AC, Sack K. Danazol therapy in autoimmune hemolytic anemia associated with systemic lupus erythematosus. *J Rheumatol* 1991; 18:280.

- Ahn YS, Harrington WJ, Mylvaganam R, et al. Danazol therapy for autoimmune hemolytic anemia. *Ann Intern Med* 1985; 102:298.
- Letchumanan P, Thumboo J. Danazol in the treatment of systemic lupus erythematosus: a qualitative systematic review. *Semin Arthritis Rheum* 2011; 40:298.
- Alba P, Karim MY, Hunt BJ. Mycophenolate mofetil as a treatment for autoimmune haemolytic anaemia in patients with systemic lupus erythematosus and antiphospholipid syndrome. *Lupus* 2003; 12:633.
- Looney RJ. B cell-targeted therapy in diseases other than rheumatoid arthritis. *J Rheumatol Suppl* 2005; 73:25.
- Nesher G, Hanna VE, Moore TL, et al. Thrombotic microangiographic hemolytic anemia in systemic lupus erythematosus. *Semin Arthritis Rheum* 1994; 24:165.
- Matsuyama T, Kuwana M, Matsumoto M, et al. Heterogeneous pathogenic processes of thrombotic microangiopathies in patients with connective tissue diseases. *Thromb Haemost* 2009; 102:371.
- George JN, Vesely SK, James JA. Overlapping features of thrombotic thrombocytopenic purpura and systemic lupus erythematosus. *South Med J* 2007; 100:512.
- Musio F, Bohlen EM, Yuan CM, Welch PG. Review of thrombotic thrombocytopenic purpura in the setting of systemic lupus erythematosus. *Semin Arthritis Rheum* 1998; 28:1.
- Manadan AM, Harris C, Schwartz MM, Block JA. The frequency of thrombotic thrombocytopenic purpura in patients with systemic lupus erythematosus undergoing kidney biopsy. *J Rheumatol* 2003; 30:1227.
- Sultan SM, Begum S, Isenberg DA. Prevalence, patterns of disease and outcome in patients with systemic lupus erythematosus who develop severe haematological problems. *Rheumatology (Oxford)* 2003; 42:230.
- Dold S, Singh R, Sarwar H, et al. Frequency of microangiopathic hemolytic anemia in patients with systemic lupus erythematosus exacerbation: Distinction from thrombotic thrombocytopenic purpura, prognosis, and outcome. *Arthritis Rheum* 2005; 53:982.
- Budman DR, Steinberg AD. Hematologic aspects of systemic lupus erythematosus. Current concepts. *Ann Intern Med* 1977; 86:220.
- Martínez-Baños D, Crispín JC, Lazo-Langner A, Sánchez-Guerrero J. Moderate and severe neutropenia in patients with systemic lupus erythematosus. *Rheumatology (Oxford)* 2006; 45:994.
- Perez HD, Lipton M, Goldstein IM. A specific inhibitor of complement (C5)-derived chemotactic activity in serum from patients with systemic lupus erythematosus. *J Clin Invest* 1978; 62:29.
- Abramson SB, Given WP, Edelson HS, Weissmann G. Neutrophil aggregation induced by sera from patients with active systemic lupus erythematosus. *Arthritis Rheum* 1983; 26:630.
- Rivero SJ, Díaz-Jouanen E, Alarcón-Segovia D. Lymphopenia in systemic lupus erythematosus. Clinical, diagnostic, and prognostic significance. *Arthritis Rheum* 1978; 21:295.
- Vilá LM, Alarcón GS, McGwin G Jr, et al. Systemic lupus erythematosus in a multiethnic US cohort, XXXVII: association of lymphopenia with clinical manifestations, serologic abnormalities, disease activity, and damage accrual. *Arthritis Rheum* 2006; 55:799.

- Winfield JB, Winchester RJ, Kunkel HG. Association of cold-reactive antilymphocyte antibodies with lymphopenia in systemic lupus erythematosus. *Arthritis Rheum* 1975; 18:587.
- Amasaki Y, Kobayashi S, Takeda T, et al. Up-regulated expression of Fas antigen (CD95) by peripheral naive and memory T cell subsets in patients with systemic lupus erythematosus (SLE): a possible mechanism for lymphopenia. *Clin Exp Immunol* 1995; 99:245.
- Isenberg DA, Patterson KG, Todd-Pokropek A, et al. Haematological aspects of systemic lupus erythematosus: a reappraisal using automated methods. *Acta Haematol* 1982; 67:242.
- Camussi G, Tetta C, Coda R, Benveniste J. Release of platelet-activating factor in human pathology. I. Evidence for the occurrence of basophil degranulation and release of platelet-activating factor in systemic lupus erythematosus. *Lab Invest* 1981; 44:241.
- Boumpas DT, Chrousos GP, Wilder RL, et al. Glucocorticoid therapy for immune-mediated diseases: basic and clinical correlates. *Ann Intern Med* 1993; 119:1198.
- Euler HH, Harten P, Zeuner RA, Schwab UM. Recombinant human granulocyte colony stimulating factor in patients with systemic lupus erythematosus associated neutropenia and refractory infections. *J Rheumatol* 1997; 24:2153.
- Hellmich B, Schnabel A, Gross WL. Treatment of severe neutropenia due to Felty's syndrome or systemic lupus erythematosus with granulocyte colony-stimulating factor. *Semin Arthritis Rheum* 1999; 29:82.
- Starkebaum G. Chronic neutropenia associated with autoimmune disease. *Semin Hematol* 2002; 39:121.
- Pujol M, Ribera A, Vilardell M, et al. High prevalence of platelet autoantibodies in patients with systemic lupus erythematosus. *Br J Haematol* 1995; 89:137.
- Michel M, Lee K, Piette JC, et al. Platelet autoantibodies and lupus-associated thrombocytopenia. *Br J Haematol* 2002; 119:354.
- Nakamura M, Tanaka Y, Satoh T, et al. Autoantibody to CD40 ligand in systemic lupus erythematosus: association with thrombocytopenia but not thromboembolism. *Rheumatology (Oxford)* 2006; 45:150.
- Karpatkin S. Autoimmune thrombocytopenic purpura. *Blood* 1980; 56:329.
- Ziakas PD, Giannouli S, Zintzaras E, et al. Lupus thrombocytopenia: clinical implications and prognostic significance. *Ann Rheum Dis* 2005; 64:1366.
- DAMESHEK W, REEVES WH. Exacerbation of lupus erythematosus following splenectomy in idiopathic thrombocytopenic purpura and autoimmune hemolytic anemia. *Am J Med* 1956; 21:560.
- BEST WR, DARLING DR. A critical look at the splenectomy-S.L.E. controversy. *Med Clin North Am* 1962; 46:19.
- George JN, Woolf SH, Raskob GE, et al. Idiopathic thrombocytopenic purpura: a practice guideline developed by explicit methods for the American Society of Hematology. *Blood* 1996; 88:3.
- Blanchette V, Freedman J, Garvey B. Management of chronic immune thrombocytopenic purpura in children and adults. *Semin Hematol* 1998; 35:36.
- Mazzucconi MG, Fazi P, Bernasconi S, et al. Therapy with high-dose dexamethasone (HD-DXM) in previously untreated patients affected by idiopathic thrombocytopenic purpura: a GIMEMA experience. *Blood* 2007; 109:1401.

- Goebel KM, Gassel WD, Goebel FD. Evaluation of azathioprine in autoimmune thrombocytopenia and lupus erythematosus. *Scand J Haematol* 1973; 10:28.
- Boumpas DT, Barez S, Klippel JH, Balow JE. Intermittent cyclophosphamide for the treatment of autoimmune thrombocytopenia in systemic lupus erythematosus. *Ann Intern Med* 1990; 112:674.
- Maier WP, Gordon DS, Howard RF, et al. Intravenous immunoglobulin therapy in systemic lupus erythematosus-associated thrombocytopenia. *Arthritis Rheum* 1990; 33:1233.
- Vasoo S, Thumboo J, Fong KY. Refractory immune thrombocytopenia in systemic lupus erythematosus: response to mycophenolate mofetil. *Lupus* 2003; 12:630.
- Braendstrup P, Bjerrum OW, Nielsen OJ, et al. Rituximab chimeric anti-CD20 monoclonal antibody treatment for adult refractory idiopathic thrombocytopenic purpura. *Am J Hematol* 2005; 78:275.
- Hall S, McCormick JL Jr, Greipp PR, et al. Splenectomy does not cure the thrombocytopenia of systemic lupus erythematosus. *Ann Intern Med* 1985; 102:325.
- You YN, Tefferi A, Nagorney DM. Outcome of splenectomy for thrombocytopenia associated with systemic lupus erythematosus. *Ann Surg* 2004; 240:286.
- Vesely SK, Perdue JJ, Rizvi MA, et al. Management of adult patients with persistent idiopathic thrombocytopenic purpura following splenectomy: a systematic review. *Ann Intern Med* 2004; 140:112.
- West SG, Johnson SC. Danazol for the treatment of refractory autoimmune thrombocytopenia in systemic lupus erythematosus. *Ann Intern Med* 1988; 108:703.
- Cervera H, Jara LJ, Pizarro S, et al. Danazol for systemic lupus erythematosus with refractory autoimmune thrombocytopenia or Evans' syndrome. *J Rheumatol* 1995; 22:1867.
- Aviña-Zubieta JA, Galindo-Rodriguez G, Robledo I, et al. Long-term effectiveness of danazol corticosteroids and cytotoxic drugs in the treatment of hematologic manifestations of systemic lupus erythematosus. *Lupus* 2003; 12:52.
- Ahn YS, Harrington WJ, Seelman RC, Eytel CS. Vincristine therapy of idiopathic and secondary thrombocytopenias. *N Engl J Med* 1974; 291:376.
- Castellino G, Govoni M, Prandini N, et al. Thrombocytosis in systemic lupus erythematosus: a possible clue to autosplenectomy? *J Rheumatol* 2007; 34:1497.
- Voulgarelis M, Giannouli S, Tasidou A, et al. Bone marrow histological findings in systemic lupus erythematosus with hematologic abnormalities: a clinicopathological study. *Am J Hematol* 2006; 81:590.
- Lambotte O, Khellaf M, Harmouche H, et al. Characteristics and long-term outcome of 15 episodes of systemic lupus erythematosus-associated hemophagocytic syndrome. *Medicine (Baltimore)* 2006; 85:169.
- Somers E, Magder LS, Petri M. Antiphospholipid antibodies and incidence of venous thrombosis in a cohort of patients with systemic lupus erythematosus. *J Rheumatol* 2002; 29:2531.
- Shah NM, Khamashta MA, Atsumi T, Hughes GR. Outcome of patients with anticardiolipin antibodies: a 10 year follow-up of 52 patients. *Lupus* 1998; 7:3.
- Vlachoyiannopoulos PG, Toya SP, Katsifis G, et al. Upregulation of antiphospholipid antibodies following cyclophosphamide therapy in patients with systemic lupus erythematosus. *J Rheumatol* 2008; 35:1768.

- Esdaile JM, Abrahamowicz M, Joseph L, et al. Laboratory tests as predictors of disease exacerbations in systemic lupus erythematosus. Why some tests fail. *Arthritis Rheum* 1996; 39:370.
- Vilá LM, Alarcón GS, McGwin G Jr, et al. Systemic lupus erythematosus in a multiethnic cohort (LUMINA): XXIX. Elevation of erythrocyte sedimentation rate is associated with disease activity and damage accrual. *J Rheumatol* 2005; 32:2150.
- Charalabopoulos K, Papalimneou V, Charalabopoulos A, Chaidos A, Bai M, Bourantas K, Agnantis N Kikuchi-Fujimoto disease in Greece. A study of four cases and review of the literature. *In vivo* 2002;16:311-316
- Yasar Kucukardali, Emrullah Solmazgul, Erdogan Kunter, Oral Oncul, Sukru Yildirim, Mustafa Kaplan. Kikuchi-Fujimoto Disease: analysis of 244 cases *Clin. Rheumatol* 2007;26: 50-54
15. Alex Santana, Bruno Lessa, Liliana Galra, Isabella Lima, Mittermayer Santiago Kikuchi-Fujimoto's disease associated with systemic lupus erythematosus: case report and review of the literature. *Clin Rheumatol* 2005;24: 60-63
- Ansell J, Hirsh J, Poller L, et al. The pharmacology and management of the vitamin K antagonists: the Seventh ACCP Conference on Antithrombotic and Thrombolytic Therapy. *Chest* 2004; 126:204S.
- Weitz JI. Low-molecular-weight heparins. *N Engl J Med* 1997; 337:688.
- Segal JB, Streiff MB, Hofmann LV, et al. Management of venous thromboembolism: a systematic review for a practice guideline. *Ann Intern Med* 2007; 146:211.
- Koopman, MM, Prandoni, P, Piovella, F, et al. Treatment of venous thrombosis with intravenous unfractionated heparin administered in the hospital as compared with subcutaneous low-molecular-weight heparin administered at home. *N Engl J Med* 1996; 334:682.
- Levine M, Gent M, Hirsh J, et al. A comparison of low-molecular-weight heparin administered primarily at home with unfractionated heparin administered in the hospital for proximal deep-vein thrombosis. *N Engl J Med* 1996; 334:677.
- Boccalon H, Elias A, Chalé JJ, et al. Clinical outcome and cost of hospital vs home treatment of proximal deep vein thrombosis with a low-molecular-weight heparin: the Vascular Midi-Pyrenees study. *Arch Intern Med* 2000; 160:1769.
- O'Shaughnessy D, Miles J, Wimperis J. UK patients with deep-vein thrombosis can be safely treated as out-patients. *QJM* 2000; 93:663.
- Grau E, Tenias JM, Real E, et al. Home treatment of deep venous thrombosis with low molecular weight heparin: Long-term incidence of recurrent venous thromboembolism. *Am J Hematol* 2001; 67:10.
- Dunn A, Bioh D, Beran M, et al. Effect of intravenous heparin administration on duration of hospitalization. *Mayo Clin Proc* 2004; 79:159.
- Douketis JD. Treatment of deep vein thrombosis: what factors determine appropriate treatment? *Can Fam Physician* 2005; 51:217.



Systemic Lupus Erythematosus

Edited by Dr Hani Almoallim

ISBN 978-953-51-0266-3

Hard cover, 554 pages

Publisher InTech

Published online 21, March, 2012

Published in print edition March, 2012

This book provides a comprehensive overview of the basic and clinical sciences of Systemic Lupus Erythematosus. It is suitable for basic scientists looking for detailed coverage of their areas of interest. It describes how advances in molecular biology have increased our understanding of this disease. It is a valuable clinical resource for practicing clinicians from different disciplines including rheumatologists, rheumatology fellows and residents. This book provides convenient access to information you need about cytokines, genetics, Fas pathway, toll like receptors and atherogenesis in SLE. Animal models have been reviewed as well. How to avoid delay in SLE diagnosis and management, in addition to various clinical manifestations including pregnancy and SLE have all been explained thoroughly in this book.

How to reference

In order to correctly reference this scholarly work, feel free to copy and paste the following:

Nahid Janoudi and Ekhlas Samir Bardisi (2012). Haematological Manifestations in Systemic Lupus Erythematosus, Systemic Lupus Erythematosus, Dr Hani Almoallim (Ed.), ISBN: 978-953-51-0266-3, InTech, Available from: <http://www.intechopen.com/books/systemic-lupus-erythematosus/haematological-manifestations-in-systemic-lupus-erythematosus>

INTECH
open science | open minds

InTech Europe

University Campus STeP Ri
Slavka Krautzeka 83/A
51000 Rijeka, Croatia
Phone: +385 (51) 770 447
Fax: +385 (51) 686 166
www.intechopen.com

InTech China

Unit 405, Office Block, Hotel Equatorial Shanghai
No.65, Yan An Road (West), Shanghai, 200040, China
中国上海市延安西路65号上海国际贵都大饭店办公楼405单元
Phone: +86-21-62489820
Fax: +86-21-62489821

© 2012 The Author(s). Licensee IntechOpen. This is an open access article distributed under the terms of the [Creative Commons Attribution 3.0 License](#), which permits unrestricted use, distribution, and reproduction in any medium, provided the original work is properly cited.