

## Role of various methods in management of ear lobule keloids A prospective clinical study

Dr. Malini. P<sup>1</sup>, Dr. Sreenivasa Rao Pavuluri<sup>2</sup>, Dr. Rasheeqa Gulreez<sup>3</sup>,  
Dr. Jaypal Rathod<sup>4</sup>

<sup>1</sup>:Assistant Professor, Department of Dermato Venerology, Osmania General Hospital, Hyderabad 500001, India

<sup>2</sup>:Assistant Professor, Department of Plastic Surgery, Osmania General Hospital, Hyderabad 500001, India

<sup>3</sup>:Senior Resident, Department of Plastic Surgery, Osmania General Hospital, Hyderabad 500001, India

<sup>4</sup>:Post Graduate, Department of Plastic Surgery, Osmania General Hospital, Hyderabad 500001, India.

### Abstract:

**Background:** Keloids are the most commonly encountered cases for a plastic surgeon. They result from an abnormal fibrous wound healing process in which tissue repair and regeneration-regulating mechanism control is lost. These abnormal fibrous growths present a major therapeutic dilemma and challenge to the plastic surgeon because they are disfiguring and frequently recur.

**Objective:** To study the various methods of management of keloids of the ear lobe like intra-lesional triamcinolone injections, surgery or in combination and their outcome in patients of plastic surgery and dermatovenereology department at Osmania General Hospital, Hyderabad, Telangana, India between the years 2012-2015.

**Results:** Out of 30 patients, 26 patients had keloids less than 2cms and they subsided with intra lesional triamcinolone injections (6 doses) alone. 4 cases had keloids more than 2 cms and were pretreated with 4 doses of intra-lesional triamcinolone combined with surgery and then treated again with intra lesional triamcinolone injections after 14 days post op. Almost 100% reduction in size of the keloids was noted in all cases which were followed up upto 24 months in both the departments with no recurrences. One case was lost in follow up after 3 months.

**Conclusions:** Intra lesional injections of triamcinolone for the management of keloids is considered as a gold standard and is accepted universally as the best method of management of keloids. If the lesions are big, combinations of intra lesional injections of triamcinolone, surgery and post op injections into the margins have shown very good results and can be used as a management protocol in cases of ear lobule keloids.

**Key words:** Keloids, Intra lesional triamcinolone.

### I. Introduction

Keloids are the most commonly encountered cases for a plastic surgeon. They result from an abnormal fibrous wound healing process in which tissue repair and regeneration-regulating mechanism control is lost. These abnormal fibrous growths present a major therapeutic dilemma and challenge to the plastic surgeon because they are disfiguring and frequently recur.<sup>1</sup> Especially in the ear, these lesions are conspicuous and not easy for patients to conceal. Patients typically present with cosmetic concerns, although keloids can also cause pruritus, pain, or pressure.<sup>2</sup> These are abnormal wound responses in predisposed individuals and represent a connective tissue response to ear piercing, trauma, inflammation, or burns.<sup>3</sup> Keloids continue to evolve over time, without a quiescent or regressive phase.<sup>4</sup> Since the mid-1960s intralesional steroid injections have gained popularity as one of the most common approaches to attenuate keloid formation.<sup>5</sup> Most of the known effects of corticosteroids are thought to result primarily from its suppressive effects on the inflammatory process in the wound, and secondarily from diminished collagen and glycosaminoglycan synthesis, inhibition of fibroblast growth and enhanced collagen and fibroblast degeneration.<sup>6</sup> This study discusses about the keloids of the ear lobe and the various modalities of the management.

**Objective-** To study the various methods of management of keloids of the ear lobe like intra-lesional triamcinolone injections, surgery or in combination and their outcome in patients of plastic surgery and dermatovenereology department at Osmania General Hospital, Hyderabad, Telangana, India between the years 2012-2015.

## II. Materials and methods

This prospective study was done at Osmania General Hospital which is a tertiary in Hyderabad. The sample consists of 30 patients with 40 ear lobule keloids. The patients had ages ranging from 9-55 years, the mean age being 20 years. All Patients were females in our study. Of the 40 lesions, only one was of posttraumatic origin, the rest were following ear piercing, seven were recurrent following earlier surgical excision (two of them recurred twice after subsequent surgical excisions). The recurrence of six out of these seven lesions was within a year from the time of surgery.

### Protocols adopted

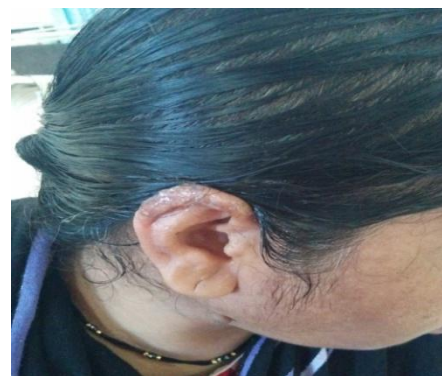
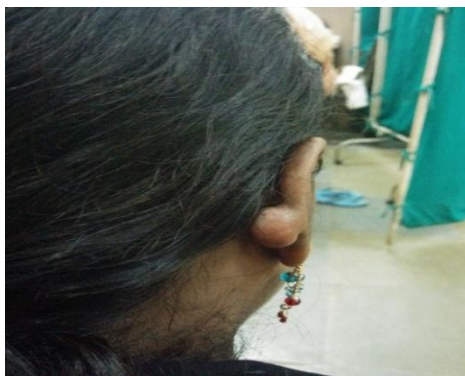Before starting the treatment protocol, all patients were meticulously counseled about the etio pathogenesis of the keloids, the treatment plan and its duration, likely complications of all modalities of treatment options. They were warned not to plan pregnancy for a period of two years from the time of consultation and not to miss follow-up as well as of the probability of treatment failure. Contact details of every patient were recorded and all patients were advised to contact the surgeon for an early appointment if they found any recurrence

**Protocol A:** 6 Doses of intralesional triamcinolone injections (at a dose of 40mg/ml) alone with interval of 3 weeks between each injection. Advised to follow up monthly after finishing of all doses to both departments.

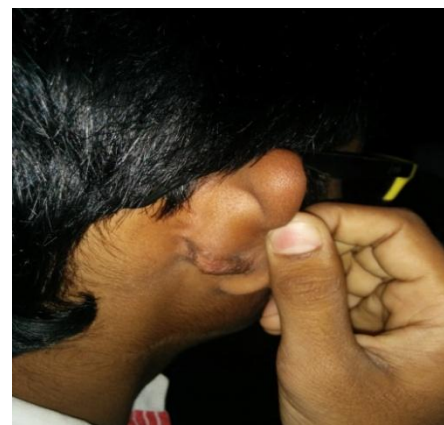
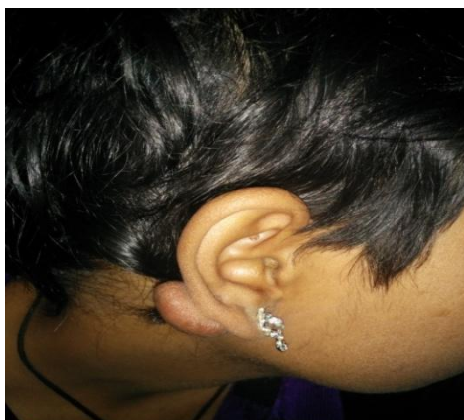
**Protocol B:** 4 doses of intra-lesional triamcinolone combined with surgery and then treated again with 2 doses of intra lesional triamcinolone injections after 14 days post op and then advised followup monthly. The maximum dose used in adults was never more than 120 mg.

## III. Results

Out of 30 patients, 26 patients had keloids less than 2cms and they subsided with intra lesional triamcinolone injections (6 doses) alone. 4 cases had keloids more than 2 cms and were pretreated with 4 doses of intra-lesional triamcinolone combined with surgery and then treated again with intra lesional triamcinolone injections after 14 days post op. Almost 100% reduction in size of the keloids was noted in all cases which were followed up upto 24 months in both the departments with no recurrences. One case was lost in follow up after 3 months.



case 1



Case 2

**Table 1 Analysis of patients and results**

1	Toatal number	30 Patients with 40 ear lobule keloids
2	Age	9-55 years with mean age 20
3	Sex	All are females
4	Unilateral / Bilateral	Unilateral-20 ,Bilateral-10
5	Recurrent lesions	7
6	Location	Lobule of ear-15, Cartilaginous pinna-25
7	Duration of keloids	1-13 Years(mean 4.2 yrs)
8	Etiology of lesions	Post trauma- 1, Piercing -29
9	Age of piercing	<10- 5 Cases 11-15- 16 Cases 16-20- 9 Caes
10	Treatment given	26 Patients- only intralesional steroid 4 patients- steroid+surgery+steroid
11	Recurrence	No Recurrence

#### IV. Discussion

Twenty five out of 31 patients in this series got their ears pierced after the age of ten years. This correlates well with the fact that the risk of keloids increases with each subsequent piercing, especially when the piercing is after ten years of age<sup>10</sup>. From the small fraction of recurrent keloids in this series, it is evident that 6/7 recurrences were within the first year of the postoperative period<sup>9</sup>. Six of these patients were not operated on by Plastic Surgeons (more than half of them were operated by GPs) and were not followed regularly by the treating doctor due to various reasons. This explains the high recurrence rates during the 1st postoperative year, the cause for recurrence being either improper surgical technique or irregular follow-up<sup>7,8</sup>.

In our study, we have included the patients with <2cms lesion size for intralesional steroids only and also the improvement levels are good and patients with lesions >2cms were included for surgery with pre and post operative steroid injections which gives us good results with evidence of no recurrence after 24 months of follow-up period except one patient who lost the follow up. This emphasizes that surgical excision is a sure and predictable way of removing the lesion in toto and needs to be combined with other modalities. Meticulous surgical technique was used for all the cases in this series and care was taken against five proven factors (incomplete removal of keloid/scar tissue, haematoma, infection, tension on suture line and poor vascularity to wound edges) that cause undesirable scars<sup>8,11</sup>. The length of the wound was not taken into consideration as it does not bear any relation with the incidence of recurrence<sup>11</sup>.

#### V. Conclusions

Intralesional injections of triamcinolone for the management of keloids is considered as a gold standard and is accepted universally as the best method of management of keloids. If the lesions are big, combinations of intralesional injections of triamcinolone, surgery and post op injections into the margins have shown very good results and can be used as a management protocol in cases of ear lobule keloids.

#### References

- [1]. Dolores Wolfram, MD, Alexandar Tzankov, MD, Petra Pu` Lzl, MD, And Hildegunde Piza-Katzer, MD. Hypertrophic Scars and KeloidsFA Review of Their Pathophysiology, Risk Factors, and Therapeutic Management: *Dermatol Surg* 2009; 35:171–181
- [2]. Segev F, Jaeger-Roshu S, Gefen-Carmi N, Assia EI. Combined mitomycin C application and free flap conjunctival autograft in pterygium surgery. *Cornea* 2003; 22:598–603.
- [3]. English RS, Shenefelt PD. Keloids and hypertrophic scars. *Dermatol Surg* 1999; 25:631–8.
- [4]. Nemeth AJ. Keloids and hypertrophic scars. *J Dermatol Surg Oncol* 1993; 19:738–46.
- [5]. Jalali M, Bayat A. (2007) Current use of steroids in management of abnormal raised skin scars. *Surgeon*. 5:175–80.
- [6]. Boyadjiev C, Popchristova E, Mazgalova J. (1995) Histomorphologic changes in keloids treated with Kenacort. *J. Trauma*. 38:299–302.
- [7]. Berman B. Departments of Dermatology and Internal Medicine, University Of Miami School of Medicine eMedicine - Keloid and hypertrophic scar. Available from: <http://www.emedicine.com/derm/topic205.htm> - 105k.
- [8]. Ogawa R, Mitsuhashi K, Hyakusoku H, Miyashita T. Postoperative electron-beam irradiation therapy for keloids and hypertrophic scars: Retrospective study of 147 cases followed for more than 18 months. *Plast Reconstr Surg* 2003;111:547-53.
- [9]. Ragoowansi R, Cornes PG, Moss AL, Glees JP. Treatment of keloids by surgical excision and immediate postoperative singlefraction radiotherapy. *Plast Reconstr Surg* 2003;111:1853-9.
- [10]. Barclay L, Lie D. Medscape-ear piercing at age 11 years or older may result in keloid formation in some children CME. Available online at <http://www.medscape.com/viewarticle/504386> [Accessed on 12 January 2008].
- [11]. Kim DY, Kim ES, Eo SR, Kim KS, Lee SY, Cho BH. A surgical approach for earlobe keloid: Keloid P llet B ap. *Plast Reconstr Surg* 2004;113:1668-74.