

Brief report

Restored flexor carpi ulnaris function after mere tenotomy explains the recurrence of spastic wrist deformity

M. Kreulen^{a,*}, M.J.C. Smeulders^a, J.J. Hage^b

^a Department of Plastic, Reconstructive and Hand Surgery, Academic Medical Centre, Suite G4-226, P.O. Box 22660, 1100 DD Amsterdam, The Netherlands

^b Antoni van Leeuwenhoek Hospital, Amsterdam, The Netherlands

Received 1 September 2003; accepted 11 December 2003

Abstract

Objective. To prove that fibrous restoration of the continuity of a cut tendon may cause recurrence of flexion deformity of the wrist after mere tenotomy of the spastic flexor carpi ulnaris muscle.

Background. Mere tenotomy of the flexor carpi ulnaris tendon is insufficient to prevent recurrence of acquired spastic flexion deformity of the wrist. Subsequent restoration of the continuity of the tendon by fibrous interposition may result in the recurrence. We examined whether a previously tenotomised muscle is strong enough to cause the deformity.

Methods. Active and passive force–length characteristics of the flexor carpi ulnaris muscle were measured intraoperatively in a patient with recurrent spastic flexion wrist deformity. The observed characteristics were compared with the average in vivo force–length characteristics of 14 spastic flexor carpi ulnaris muscles that had not previously been operated.

Results. The previously tenotomised flexor carpi ulnaris muscle was able to maximally exert 110 N force. Its active force–length curve and passive force at maximal extension were similar to those of non-operated spastic flexor carpi ulnaris muscles.

Conclusions. A previously tenotomised flexor carpi ulnaris muscle is strong enough to cause recurrence of spastic flexion deformity of the wrist in case functional fibrous restoration of the tendon occurs after mere tenotomy.

Relevance

The surgical routine of mere tenotomy should probably be modified by including the dissection of the distal muscle belly and the excision of a segment of the tendon to avoid its restoration.

© 2003 Published by Elsevier Ltd.

Keywords: Spastic deformity; Flexor carpi ulnaris muscle; Tenotomy; Force–length curve; Tendon regeneration

1. Introduction

Tenotomy to release the deforming force of a muscle has been widespread employed since Dr. Louis Stromeyer performed a subcutaneous tenotomy of the Achilles tendon to correct a clubfoot in 1834 (Schleichorn, 1987). Mere tenotomy of the flexor carpi ulnaris (FCU) tendon is generally accepted as a means to improve the position of the wrist during functional activities in patients with mild spastic flexion deformity of the wrist in whom active extension is still possible (Tonkin and Gschwind, 1992; Tonkin, 2000; Zancolli

et al., 1983). During repeat surgery for recurrent flexion deformity after mere tenotomy, however, we repeatedly found formation of a fibrous interposition to have restored the continuity of the tendon. Because we accept the restored continuity to lead to the recurrence, we hypothesise that the previously tenotomised muscle is sufficiently strong to cause the deformity.

We now have a reliable technique for in vivo measurements of force–length relationship on human muscle, as well as reliable data to establish average values for spastic FCU muscle that have not previously been operated (Smeulders et al., 2004). This offers a unique opportunity to test, during repeat surgery, whether previous tenotomy of the FCU alters the muscle's mechanical properties. In this paper we present the results of in vivo force–length measurements of a FCU

* Corresponding author.

E-mail address: mkreulen@xs4all.nl (M. Kreulen).

muscle 7 years after tenotomy and compare these results to those obtained in non-operated spastic FCU muscles.

2. Methods

2.1. Patient

In 1995, a then 16-year-old girl presenting with spastic flexion deformity of the wrist caused by cerebral palsy underwent tenotomy of the FCU tendon as described by Zancolli et al. (1983). Using a transverse incision in the palmar crease of the wrist, the FCU tendon and its paratenon were cut completely resulting in abrupt retraction of the proximal end and a satisfactory release of the flexion deformity. In 2002, the result of the tenotomy had become insufficient to balance the flexion and extension forces around the wrist and the flexion deformity had recurred. A tight strand could be palpated on the ulnovolar side of the distal forearm during active flexion, indicating that FCU function was restored. It was decided to re-operate and the patient gave informed consent for intraoperative force–length measurements in accordance with a protocol that had been approved by the Medical Ethical Committee of the Academic Medical Centre in Amsterdam (Smeulders et al., submitted for publication).

At surgical exploration, the continuity of the previously cut FCU tendon was found to be restored by strong interposing longitudinal fibrous fibres that only slightly adhered to the surrounding soft tissues (Fig. 1). Repeat transection of the restored tendon again corrected the flexion deformity and, immediately following tenotomy, the FCU force–length characteristics were

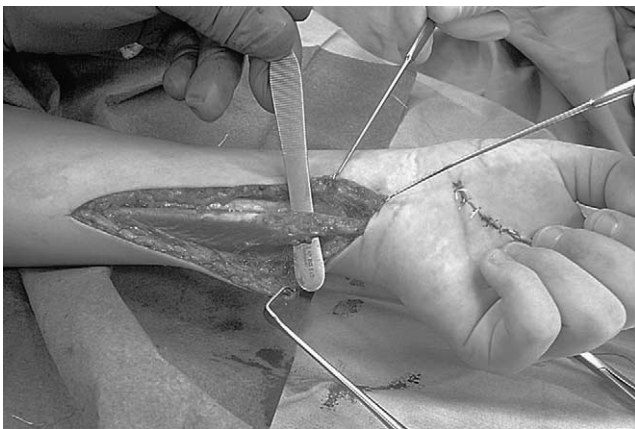


Fig. 1. Complete restoration of the continuity of the distal FCU-tendon, 7 years after tenotomy. The FCU had been only dissected until the distal tendon and its paratenon was released. Note that the muscle belly appears to barely have retracted. Additional procedure was a release of the adductor pollicis muscle, which has no influence on the wrist joint.

intraoperatively measured (see below). Because the muscle still showed to be a suitable motor for transposition surgery, the cut FCU was dissected and transposed subcutaneously to be fixed to the extensor carpi radialis brevis tendon. After 6 weeks of immobilisation by a plaster cast, an exercise program was started. Currently, at 12 months of follow-up, a satisfactory correction of the flexion deformity of the wrist is still present.

2.2. Measurement of force–length characteristics

Our method of in vivo measurement of active and passive force–length curves of the FCU has previously been validated and described in detail (Smeulders et al., 2004). In short, a series of maximal tetanic contractions of the FCU were induced at subsequent muscle lengths by supra-maximal transcutaneous electrical stimulation of the ulnar nerve (140 mA, 50 Hz, 0.1 ms pulse duration 1000 ms stimulus duration), using two gel-filled skin electrodes that were pasted on the skin directly overlying the cubital tunnel of the elbow. A strain gauge was attached to a metal ring sutured on the distal tendon of the tenotomised FCU and to a metal bar that was attached to a Kirschner-wire in the medial epicondyle. The strain gauge was kept aligned with the FCU. Just prior to and during stimulation, the strain gauge signal was A/D-converted and stored in a computer. Force measurements were obtained at a series of muscle lengths, varying from that corresponding to well shorter than the length at maximal flexion of the wrist, to that corresponding to well beyond the length at maximal wrist extension.

2.3. Data analysis

The muscle's operating length range, defined as the range of the length of the FCU from maximal passive flexion to maximal passive extension of the wrist was calculated and compared to the operating length range of 14 spastic FCU muscles that had not previously been operated (Smeulders et al., submitted for publication).

The re-tenotomised muscle's passive and active force–length characteristics were plotted (Smeulders et al., 2004) to be compared with the average force–length characteristics of the muscles that had not previously been operated (Smeulders et al., submitted for publication).

3. Results

3.1. Operating length range

Seven years after tenotomy, the FCU operating length range of the patient was 1.4 cm, with the range of motion

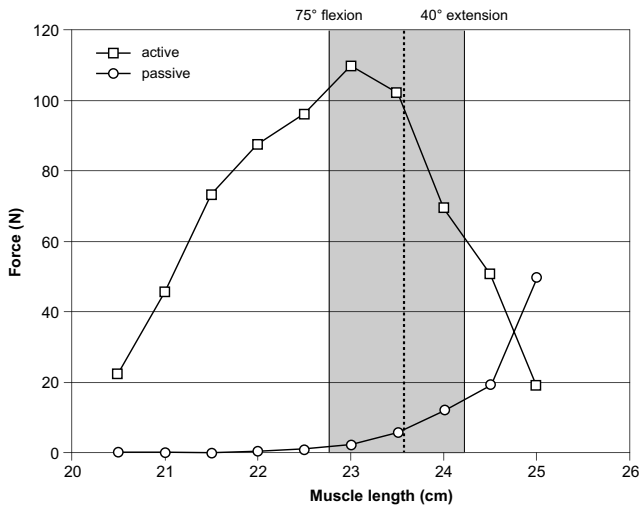


Fig. 2. Active and passive force-length curve of the spastic FCU after previous tenotomy was restored. The marked area shows the operating length range of the FCU during range of motion (from 75° flexion to 40° extension). The black dashed line indicates the FCU length at neutral position of the wrist.

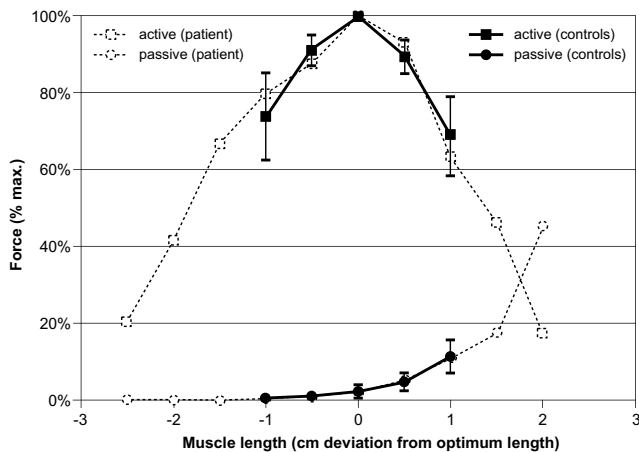


Fig. 3. Compound graphic of the force-length curve observed after previous tenotomy in our patient (---), and the average force-length curve obtained from non-operated spastic FCU muscles (—), including the 95% confidence interval error bars. Force is normalized for maximum active force, length is expressed as deviation from optimum length.

of the wrist ranging from 75° flexion to 40° of extension. The operating length range was situated mainly on the descending part of the active force-length curve (Fig. 2), and overlapped with the average operating length range of the non-operated spastic muscles (Fig. 3).

3.2. Passive force-length characteristics

At maximum extension of the wrist, the passive force was approximately 15 N (Fig. 2). The passive force curve fell within the 95% confidence interval of the

average curve of the non-operated spastic FCU muscles (Fig. 3).

3.3. Active force-length characteristics

The patient’s FCU was able to exert 60–110 N of force within its operating length range (Fig. 2). The shape of the active force-length curve of the previously tenotomised FCU was similar to that of the average curve of the non-operated spastic FCU muscles and its values fell within the 95% confidence interval of the average (Fig. 3).

4. Discussion

We proved the force of a spastic FCU not to have decreased by mere tenotomy in our patient and, provided the severed tendon has restored, this may explain a disappointing long-term result of the tenotomy. Functional restoration by formation of a fibrous interposition between the two stumps of a severed tendon is not exceptional and conservative treatment of closed traumatic rupture of tendons even relies on it to happen (Leppilahti and Orava, 1998; Morrey et al., 1985). Previously we showed that the gap between the stumps of a cut FCU tendon remained small after mere tenotomy in spastic patients and that the muscle retracted less than 1 cm even when the muscle was electrically stimulated to actively retract (Kreulen et al., 2003). The surrounding fascial connections of the long muscle belly apparently retain the muscle fibres at their functional length and prevent the muscle to shorten to a length at which it can only exert little force. After subsequent fibrous interposition between the stumps, therefore, the result of mere tenotomy may be compared to that of limited lengthening of the tendon.

The tenotomy gap may be increased by dissection of the distal one-third of the muscle belly as this allows the muscle to retract some 2 cm (Kreulen et al., 2003). Hence, we advise additional proximal dissection of the FCU muscle rather than mere tenotomy, to allow the gap between the tendon stumps to increase. Excision of part of the FCU tendon will further diminish the risk of tendon regeneration. On the basis of these unique measurements of intraoperative force-length characteristics of the functionally restored spastic FCU in a patient with recurrence of flexion deformity of the wrist we conclude that similar measurements in additional cases may prove mere tenotomy to be inadequate and, therefore, obsolete.

References

Kreulen, M., Smeulders, M.J.C., Hage, J.J., Huijting, P.A., 2003. Biomechanical effects of dissecting flexor carpi ulnaris. *J. Bone Joint Surg.* 85-B, 856–859.

- Leppilähti, J., Orava, S., 1998. Total Achilles tendon rupture, a review. *Sports Med.* 25, 79–100.
- Morrey, B.F., Askew, L.J., An, K.-N., Dobyns, J.H., 1985. Rupture of the distal tendon of the biceps brachii, a biomechanical study. *J. Bone Joint Surg.* 67A, 418–421.
- Schleichkorn, J., 1987. The sometime physician; William John Little—pioneer in treatment of cerebral palsy and orthopedic surgery. State University of New York, New York.
- Smeulders, M.J.C., Kreulen, M., Hage, J.J., Huijting, P.A., van der Horst, C.M.A.M., 2004. Intraoperative measurement of force-length characteristics of human forearm muscle. *Clin. Orthop. Rel. Res.* 418.
- Smeulders, M.J.C., Kreulen, M., Hage, J.J., Huijting, P.A., van der Horst, C.M.A.M., submitted for publication. Does overstretching of sarcomeres cause muscle contracture in cerebral palsy?
- Tonkin, M.A., 2000. The upper limb in cerebral palsy. In: Gupta, A., Kay, S.P.J., Scheker, L.R. (Eds.), *The Growing Hand*. Harcourt Publishers Ltd., London, pp. 447–459.
- Tonkin, M.A., Gschwind, C., 1992. Surgery for cerebral palsy: part 2. Flexion deformity of the wrist and fingers. *J. Hand Surg.* 17B, 396–400.
- Zancolli, E.A., Goldner, L.J., Swanson, A.B., 1983. Surgery of the spastic hand in cerebral palsy: report of the committee on spastic hand evaluation. *J. Hand Surg.* 8A, 766–772.