

Madelung Disease: MR Findings

Daniel W. Williams III,¹ Lawrence E. Ginsberg,¹ Dixon M. Moody,¹ and Brenda L. McCain²

Summary: Two cases of Madelung disease (benign symmetrical lipomatosis) are presented. The MR findings in this striking condition are demonstrated. Short-repetition-time/short-echo time sequences nicely show the relationship of the cervical lipomatous accumulations to the airway and major neurovascular structures in the carotid spaces. Fat-suppression techniques add no additional information in the radiologic evaluation of these patients.

Index terms: Lipoma; Neck, neoplasms; Neck, abnormalities and anomalies; Neck, magnetic resonance; Fat, magnetic resonance

Madelung disease, also known as benign symmetrical lipomatosis, is a rare disorder characterized by the massive deposition of adipose tissue in the neck, shoulders, and upper thorax (1–3). To date, approximately 200 cases have been reported, primarily in the internal medicine, dermatologic, and otolaryngologic literature (4–6). The computed tomographic findings in this disorder have been previously described (7). In this paper, we report the magnetic resonance (MR) appearance of Madelung disease in two patients.

Case Report

Case 1

A 48-year-old white woman presented with marked swelling of her neck and upper thorax, especially the upper back. She had noted an increasing neck size for approximately 8 years before presentation and had undergone two prior resections of fatty tumors of the cervical region. Histologically, the tissue removed was normal adipose tissue. At 42 years of age the patient underwent an endocrine workup for possible Cushing disease which was unremarkable. The patient denied alcohol abuse. Sagittal and axial T1-weighted MR revealed massive accumulations of fat within the subcutaneous tissues of the neck and upper thorax (Fig 1). There was no evidence for compression of the airway or neurovascular structures within the carotid spaces. Mild esophageal compression was evident (Fig 1C),

although the patient experienced no symptoms of dysphagia. The patient subsequently underwent excision of lipomatous tissue from the neck and upper thorax without complications.

Case 2

A 27-year-old white woman, unrelated to but residing in the same community as the first patient, presented with marked neck, shoulder, and upper trunk swelling (Fig 2A). She reported that even as a child she had a “round, fat face” and a “buffalo hump.” She had undergone negative endocrine workup for possible Cushing disease and did not use alcohol. Liposuction of the neck and upper back had been performed previously although without long-term success. Sagittal and axial T1-weighted MR studies demonstrated marked accumulations of fat within the neck and upper thorax (Figs 2B, and 2C). T1-weighted axial images with fat suppression (Fig 2D) were also obtained but were felt to be of little diagnostic use (because of asymmetric fat suppression and marked signal loss). This patient underwent a combination of liposuction and excision of cervical fatty accumulations.

Discussion

Benign symmetrical lipomatosis was first described by Brodie in 1846 (1). The condition is referred to by a variety of synonyms but is most commonly called Madelung disease, after Otto Madelung, who collected a series of cases and described the “horse collar” cervical involvement by adipose tissue (2). The main characteristics of the disease were defined by Launois and Bensaude in 1898 (3).

Madelung disease occurs most frequently in men, especially those living in the Mediterranean region. Enzi et al have established the incidence to be approximately one in 25,000 men in the Italian population (8). Although familial cases have been reported, the disease seems to be primarily sporadic. There is a relatively strong association with excessive alcohol intake, which

Received July 20, 1992; revision requested September 3, received October 1, and accepted October 21.

Departments of ¹Radiology and ²Plastic Surgery, Bowman Gray School of Medicine, Wake Forest University, Winston-Salem, NC 27157-1088. Address reprint requests to Daniel W. Williams III, MD.

AJNR 14:1070–1073, Sep/Oct 1993 0195-6108/93/1405–1070 © American Society of Neuroradiology

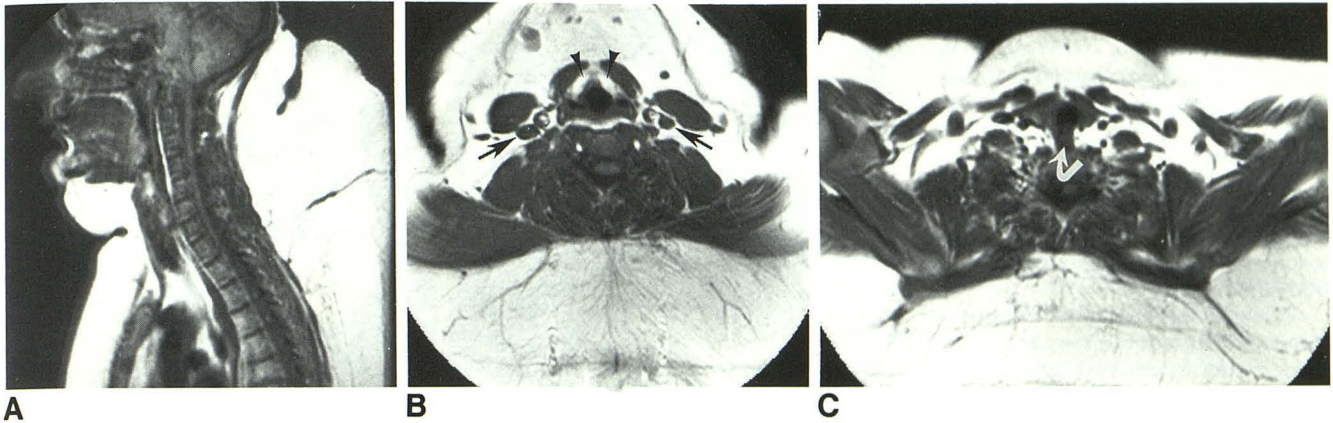


Fig. 1. Case 1: 48-year-old woman.

A, Sagittal MR image (517/20) (repetition time/echo time) demonstrates massive fat deposition in the neck, upper thorax, and submental regions.

B, Axial MR image (517/20) at level of supraglottic larynx. Despite massive adipose tissue deposition there is no significant compression of carotid space neurovascular structures (*arrows*) or airway (*arrowheads*).

C, Axial MR image (517/20) at level of thyroid gland. Note mild esophageal compression (*arrow*) by paraesophageal fat, but no compromise of the airway.

has been present in between 60% and 90% of patients with this condition (5). A variety of inconsistently associated metabolic abnormalities also have been reported. These include reduced glucose tolerance, hyperuricemia, and increased lipoprotein lipase activity. Although these metabolic abnormalities may be related to excessive fat deposition itself, many are thought to be secondary to excessive alcohol intake (4, 5).

Patients with Madelung disease have a characteristic appearance that usually suggests the diagnosis. The cosmetically disfiguring lipomatous accumulations typically bring the patient to medical attention. Fat deposition is symmetrical and occurs in the neck, upper thorax, lower face, and shoulders. Patients often have a "hamster cheek" or "pseudo-athletic" appearance. Lipomatous tissue also can infiltrate the upper mediastinum, producing venous stasis of the chest wall (4, 7). Furthermore, respiratory symptoms have been reported secondary to tracheal or laryngeal compression and false vocal cord infiltration (4, 9, 10). Most patients with Madelung disease also demonstrate signs and symptoms of an often severe peripheral motor and sensory neuropathy (4, 11).

The etiology of Madelung disease is obscure. Histologic examination of the lipomatous material reveals normal unencapsulated adipose tissue (4, 5, 6, 12). The formation of the massive fatty accumulations appears to be secondary to lipocyte hyperplasia, which occurs in response to a defect in adrenergic-stimulated lipolysis (13). A

second though less accepted theory proposes that hypertrophy of brown fat in response to "functional sympathetic denervation" is responsible for the massive fatty deposition in this condition (14, 15).

The radiologic findings in symmetrical lipomatosis as depicted on plain films, computed tomography, and MR imaging include: lipomatosis involving the characteristic locations; tracheal narrowing or deformity; calcification or ossification within the lipomatous masses; chest wall venous stasis; and lack of pericardial, intraabdominal, retroperitoneal, and pelvic lipomatosis (4, 6, 7, 9, 16, 17). Fat is exquisitely demonstrated on MR imaging because of its very high signal intensity on short-repetition-time, short-echo-time-weighted images. MR imaging performed on the two patients in this study revealed cervical and upper thorax fatty accumulation including involvement of the tissue planes of the deep neck. Neither patient demonstrated tracheal or vascular compression (Figs 1 and 2). Prominent paraesophageal fat did produce mild esophageal narrowing in one patient, although this was not clinically significant (Fig 1C). Fat suppression images were less useful because of asymmetric fat suppression accompanied by marked overall signal loss (the patient nearly disappeared) (Fig 2D). Asymmetric fat suppression and signal loss are artifacts frequently observed on fat-suppressed images and are felt to be secondary to local field inhomogeneities (18, 19). Fat suppression artifacts can be particularly troublesome with

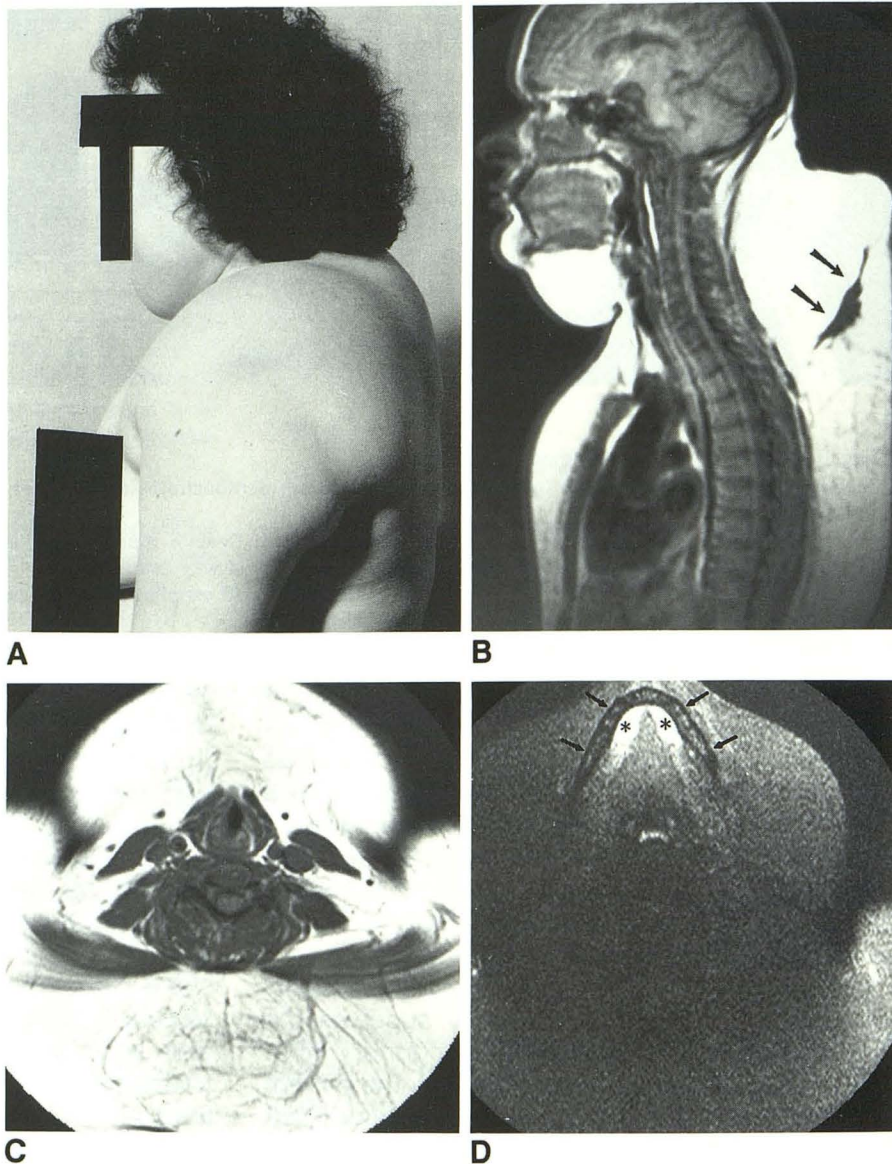
Fig. 2. Case 2: 27-year-old woman.

A, Photograph of patient demonstrates marked lipomatosis involving upper thorax, neck, and face, giving the so-called pseudo-athletic and hamster-cheek appearance.

B, Sagittal MR image (517/20) demonstrates massive fat deposition in neck and upper trunk. Area of low signal posteriorly (arrows) may represent scarring from prior surgery.

C, Axial MR image (717/20) at level of larynx. Note lack of airway and carotid space neurovascular structure compression.

D, Axial fat-suppressed MR image (700/33) at level of floor of mouth. Patient is difficult to find. Mandible (arrows) and anterior sublingual spaces (asterisks) are demonstrated. Note asymmetric fat suppression with marked overall signal loss, especially posteriorly.



the selection-gradient reversal technique of fat suppression used by our Picker Vista MR scanner (Picker International, Cleveland, Ohio) (20). Note that the overall loss of signal is more noticeable posteriorly (Fig 2D). This is probably due to increasingly severe local field inhomogeneity at greater distances from the scanner isocenter.

The standard treatment of Madelung disease is surgical debulking, although liposuction has been tried in the past with various degrees of success (5, 6, 16, 21, 22). The prognosis is guarded, and recurrences are frequent due to the difficulty in total surgical resection of these infiltrative lipomatous accumulations. Surgery is therefore regarded as palliative (6, 22). We have found only a single case of malignant degeneration within the lipomatous tissue reported (23).

References

1. Brodie BC. *Clinical lectures on surgery delivered at St. George's Hospital*. Philadelphia: Lea & Blanchard, 1846:275
2. Madelung OW. Ueber den Fetthals. *Arch Klin Chir* 1888;37:106-130
3. Launois PE, Bensaude R. De l'adenolipomatose symetrique. *Bull Mem Soc Med Hôp Paris* 1898;1:298
4. Enzi G. Multiple symmetric lipomatosis: an updated clinical report. *Medicine (Baltimore)* 1984;63:56-64
5. Ruzicka T, Vieluf D, Landthaler M, Braun-Falco O. Benign symmetric lipomatosis Launois-Bensaude. Report of ten cases and review of the literature. *J Am Acad Dermatol* 1987;17:663-674
6. Boozan JA, Maves MD, Schuller DE. Surgical management of massive benign symmetric lipomatosis. *Laryngoscope* 1992;102:94-99
7. Enzi G, Biondetti PR, Fiore D, Mazzoleni F. Computed tomography of deep fat masses in multiple symmetrical lipomatosis. *Radiology* 1982;144:121-124
8. Enzi G, Angelini C, Negrin P, Armani M, Pierobon S, Fedele D. Sensory, motor, and autonomic neuropathy in patients with multiple symmetric lipomatosis. *Medicine (Baltimore)* 1986;64:388-393

9. Birnholz JC, Macmillan AS Jr. Advanced laryngeal compression due to diffuse, symmetric lipomatosis (Madelung's disease). *Br J Radiol* 1973;46:245-249
10. Moretti JA, Miller D. Laryngeal involvement in benign symmetric lipomatosis. *Arch Otolaryngol* 1973;97:495-496
11. Pollock M, Nicholoso G, Nukada H, Cameron S, Frankish P. Neuropathy in multiple symmetric lipomatosis - Madelung's disease. *Brain* 1988;111:1157-1171
12. Zancanaro C, Sbarbati A, Morroni M, et al. Multiple symmetric lipomatosis: ultrastructural investigation of the tissue and preadipocytes in primary culture. *Lab Invest* 1990;63:253-258
13. Enzi G, Inelmen EM, Baritussio A, Dorigo P, Prosdocimi M, Mazzoleni F. Multiple symmetric lipomatosis: a defect in adrenergic-stimulated lipolysis. *J Clin Invest* 1977;60:1221-1229
14. Sully L, McGrouther DA. Brown fat in benign symmetrical lipomatosis. *Br J Plast Surg* 1979;32:331-335
15. Kodish ME, Alsever RN, Block MB. Benign symmetric lipomatosis: functional sympathetic denervation of adipose tissue and possible hypertrophy of brown fat. *Metabolism* 1974;23:937-945
16. Lüscher NJ, Prein J, Spiess B. Lipomatosis of the neck (Madelung's disease). *Ann Plast Surg* 1986;16:502-508
17. Keller SM, Waxman JS, Kim U. Benign symmetrical lipomatosis. *South Med J* 1986;79:1428-1429
18. Anzai Y, Lufkin RB, Jabour BA, Hanafee WN. Fat-suppression failure artifacts simulating pathology on frequency-selective fat-suppression MR images of the head and neck. *AJNR: Am J Neuroradiol* 1992;13:879-884
19. Barakos JA, Dillon WP, Chew WM. Orbit, skull base, and pharynx: contrast-enhanced fat suppression MR imaging. *Radiology* 1991;179:191-198
20. Axel L, Glover G, Pelc N. Chemical-shift magnetic resonance imaging of two-line spectra by gradient reversal. *Magn Reson Med* 1985;2:428-436
21. Carlin MC, Ratz JL. Multiple symmetric lipomatosis: treatment with liposuction. *J Am Acad Dermatol* 1988;18:359-362
22. Argenta LC, McClatchey KD, Ferrell WJ, Newman MH. Benign symmetrical lipomatosis (Madelung's disease). *Head Neck Surg* 1981;3:240-243
23. Tizian C, Berger A, Vykoupil KF. Malignant degeneration in Madelung's disease (benign lipomatosis of the neck): case report. *Br J Plast Surg* 1983;36:187-189